

CASE REPORT

Early laparoscopic approach to pancreatic injury following blunt abdominal trauma

Adarsh Vijay¹, Husham Abdelrahman^{1,*}, Ayman El-Menyar^{2,3}, and Hassan Al-Thani¹

¹Section of Trauma Surgery, Department of Surgery, Hamad General Hospital, Doha, Qatar, ²Clinical Medicine, Weill Cornell Medical School, Doha, Qatar, and ³Clinical Research, Trauma Surgery, Hamad General Hospital, Doha, Qatar

*Correspondence address. Hamad General Hospital, PO Box 3050, Doha, Qatar. Tel: +974-44396152; Fax: +97444394031; E-mail: traumaresearch@hmc.org.qa

Abstract

The incidence of pancreatic injury following blunt abdominal trauma is rare. A timely accurate diagnosis of such injury is difficult and also the management remains controversial. Here, we reported the successful use of laparoscopy to diagnose, characterize and treat blunt pancreatic trauma in a 28-year-old male patient involved in a motor vehicle crash. An abdominal computed tomography scan showed peripancreatic fat stranding suggestive of pancreatic injury. With persistent clinical signs of peritonitis and laboratory investigations suggestive of pancreatitis, the patient underwent laparoscopic drainage of the lesser sac. The patient had an uneventful postoperative course. The management of patients with blunt pancreatic injuries should be tailored to individual situations. Our experience suggests that a timely laparoscopic management of traumatic pancreatic injury is safe approach in selected cases.

INTRODUCTION

Owing to its protected retroperitoneal location, pancreatic injury following blunt trauma is rare, with an incidence rate of <2% [1]. Blunt abdominal trauma accounts for 20% of all cases of traumatic pancreatitis [2]. Early and accurate identification of such injuries are imperative to avoid high morbidity and mortality associated with ductal injuries. A conservative management approach has been advocated when a ductal injury is not evident. However, proponents of early surgical intervention attributed to the delay in intervention to be related with increased rates of morbidity and mortality [1–3]. So, an early laparoscopic approach might play a role for the diagnosis and management of blunt pancreatic injuries. Here, we report a case of traumatic pancreatitis following blunt abdominal trauma managed successfully using laparoscopic techniques.

CASE REPORT

A 28-year-old male sustained with blunt trauma to the upper abdomen. He presented with pain over epigastrium and left lower ribs. Serum pancreatic amylase and lipase levels increased from 108 to 456 U/l on admission to 404 to 764 U/l in the first 24 h, respectively. An initial abdominal CT scan with IV contrast demonstrated pancreatic injury (Grade II) with peripancreatic fat stranding. Two hepatic lacerations were noted in addition to minimal subhepatic and left subdiaphragmatic free fluid (Fig. 1). Initially, the patient was managed conservatively and kept on nil per mouth using nasogastric decompression, intravenous fluids, analgesics and serial clinical assessment. He continued to complain of severe generalized abdominal pain with diffuse tenderness and guarding that required exploration to exclude other intra-abdominal injuries namely hollow viscus.

Received: October 15, 2014. Revised: October 22, 2014. Accepted: October 30, 2014

Published by Oxford University Press and JSCR Publishing Ltd. All rights reserved. © The Author 2014.

This is an Open Access article distributed under the terms of the Creative Commons Attribution Non-Commercial License (<http://creativecommons.org/licenses/by-nc/4.0/>), which permits non-commercial re-use, distribution, and reproduction in any medium, provided the original work is properly cited. For commercial re-use, please contact journals.permissions@oup.com

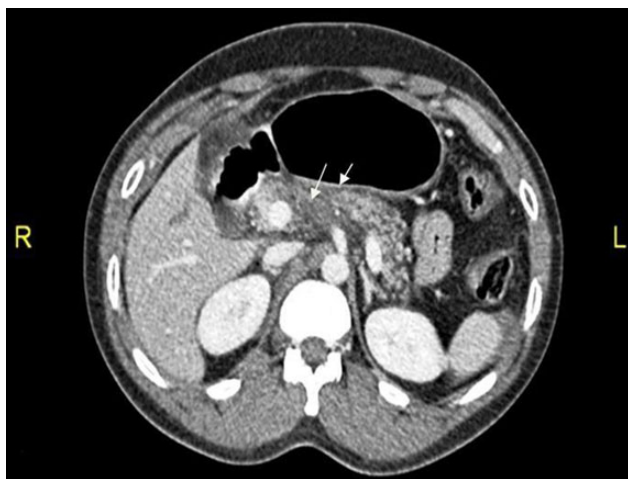

Figure 1: CT abdomen showing two hepatic lacerations in addition to minimal subhepatic and left subdiaphragmatic free fluid.

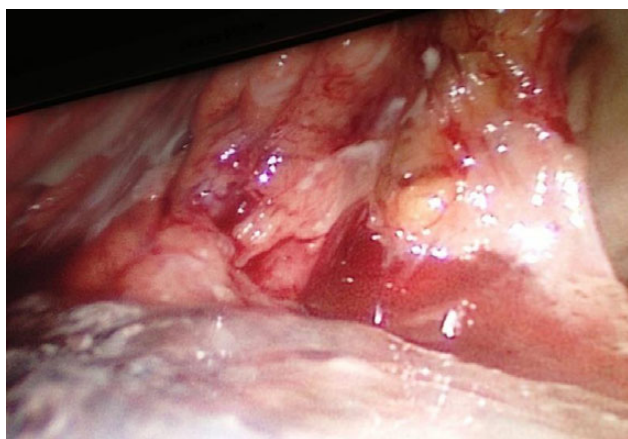

Figure 2: The intraoperative extension of the pancreatic necrosis that involves the entire gland.

Preoperative endoscopic retrograde cholangiopancreatography (ERCP) and magnetic resonance cholangiopancreatography (MRCP) were not performed at this stage. Exploratory laparoscopy showed moderate amount of free fluid (serosanguinous). Cytology and culture from the fluid revealed no organism growth; however, its pancreatic amylase level was 6062 U/l. Severe pancreatic reaction with saponification was seen over the thickened and contused greater omentum and bowel loops. A thorough exploration revealed no associated intra-abdominal injuries. During exploration of the lesser sac, pancreas was found to be hemorrhagic and necrotic, and the ductal injury could not be identified. Figure 2 shows the intraoperative extension of the pancreatic necrosis that involved the entire gland. Thorough lavage of the lesser sac and peritoneal cavity were done. Two drains were inserted into the lesser sac and pelvis following which the procedure was terminated without conversion.

The high serum amylase and lipase levels were normalized within 2 days postoperative. On the third postoperative day, clinical examination and chest X-ray demonstrated left-sided pleural effusion (Fig. 3). On the fifth day, nasojejunal tube feeding was introduced. Follow-up MRCP revealed complete transection of the pancreatic duct at the junction of pancreatic neck and body

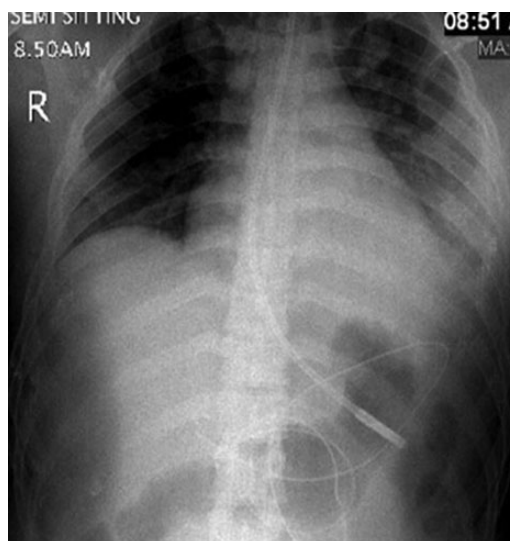


Figure 3: Chest X-ray demonstrated a large left-sided pleural effusion.

(Grade III). Output from the abdominal drains showed a gradual decline in the amount of drained fluid. On the 28th day, drains were dropped off successfully. Follow-up CT showed a small peri-pancreatic collection of ~4 cm. The patient was discharged on the 36th postoperative day.

A 6-month out-patient abdominal CT follow-up showed no fluid collection and the patient was asymptomatic.

DISCUSSION

Definite management of pancreatic injuries is not well defined yet. Moreover, the clinical and laboratory findings of blunt pancreatic injury are nonspecific, and therefore accurate diagnosis in its acute phase is usually delayed [1, 3]. Computed tomography scanning may fail to delineate the pathology, especially in the initial stage. Also, the ability for CT to demonstrate the integrity of pancreatic duct is limited (43%); however, multiple detector computed tomography may have better result [1, 4, 5].

MRCP allows direct imaging of the pancreatic duct and its disruption [1]. ERCP seems the most reliable diagnostic tool to accurately define the continuity of the main pancreatic duct following pancreatic trauma with a 100% sensitivity and specificity [6]. However, the need for a skilled endoscopist and the invasive nature of procedure may limit its use in unstable patients. Suspicion of concomitant traumatic intra-abdominal injuries prompts the surgeon to choose exploration over ERCP. Pancreatic lacerations not involving the duct (The American Association of Surgeons in Trauma Grade I and II) are considered minor injuries and are predominantly managed conservatively. Grade III–V injuries usually necessitate surgical exploration depending on the degree of injury and its proximity to the mesenteric vessels; where distal pancreatectomy is the most common approach [7]. Kantharia *et al.* [8] studied 17 cases with pancreatic trauma and found that contrast-enhanced CT as the useful tool for diagnosis and grading of the pancreatic injuries. Moreover, the majority of these cases responded well to the conservative treatment; however, higher grade pancreatic injury required surgical intervention but with higher mortality.

In patients with blunt pancreatic trauma, delayed morbidities include pancreatitis, fistula, abscess, pseudocysts and major duct strictures [9]. Therefore, we assume a valid role for early

laparoscopic approach for suspected injuries. This is particularly compelling when CT scan is inconclusive and patients show signs suggestive of peritonism. Intraoperative diagnosis of ductal injuries is seldom done owing to its complexity and retrograde pancreatography through a small duct is often difficult in trauma patients.

Our patient's clinical deterioration precluded the use of preoperative ERCP/MRCP. Clinical suspicion for hollow viscus injury prompted diagnostic laparoscopy. Necrotic and hemorrhagic pancreas precluded any intraoperative attempt to accurately characterize extent of ductal injury. Looking retrospectively, we acknowledge that, if we were able to diagnose ductal transection pre/intraoperatively, our management would have drastically deferred towards distal pancreatectomy.

In addition to being an exploratory, laparoscopy can be effectively used to characterize pancreatic injuries (grading) that informs the management with immediate drainage for the proximal pancreatic part or the resection of the distal injuries, whenever indicated [10]. Therefore, a laparoscopic approach provides a genuine alternative to the open abdominal surgery.

In conclusion, the management of blunt pancreatic injuries should be tailored to individual situations. In selected patients with worsening symptoms, a prompt trial of laparoscopy is an useful option. Although we chose a conservative drainage approach due to inconclusiveness on the integrity of pancreatic duct, we were able to achieve a favorable result. Further studies are needed to confirm our findings.

AUTHORS' CONTRIBUTIONS

A.V. was involved in study design, data collection and writing manuscript. H.A.: data analysis and interpretation, drafting and manuscript review; A.E.M.: data analysis and interpretation, drafting and manuscript review; H.A.T.: study design, data interpretation and review manuscript.

ACKNOWLEDGEMENTS

The authors thank all the trauma surgery staff for their cooperation. All authors read and approved the case report. This case report has been approved by the Medical Research Center (IRB no. 13311/13), Hamad Medical Corporation, Doha, Qatar.

CONFLICT OF INTEREST STATEMENT

None declared.

REFERENCES

1. Debi U, Kaur R, Prasad KK, Sinha SK, Sinha A, Singh K. Pancreatic trauma: a concise review. *World J Gastroenterol* 2013; **19**:9003–11.
2. Portis M, Meyers P, McDonald JC, Gholson CF. Traumatic pancreatitis in a patient with pancreas divisum: clinical and radiographic features. *Abdom Imaging* 1994; **19**:162–4.
3. Herman R, Guire KE, Burd RS, Mooney DP, Ehrlich PF. Utility of amylase and lipaseas predictors of grade of injury or outcomes in pediatric patients with pancreatic trauma. *J Pediatr Surg* 2011; **46**:923–6.
4. MacEneaney P, Mitchell MT, McDermott R. Update on magnetic resonance cholangiopancreatography. *Gastroenterol Clin North Am* 2002; **31**:731–46.
5. Lee PH, Lee SK, Kim GU, Hong SK, Kim JH, Hyun YS, et al. Outcomes of hemodynamically stable patients with pancreatic injury after blunt abdominal trauma. *Pancreatol* 2012; **12**:487–92.
6. Doctor N, Dooley JS, Davidson BR. Assessment of pancreatic duct damage following trauma: is endoscopic retrograde cholangiopancreatography the gold standard? *Postgrad Med J* 1995; **71**:116–7.
7. Moore EE, Cogbill TH, Malangoni MA, Jurkovich GJ, Champion HR, Gennarelli TA, et al. Organ injury scaling, II: pancreas, duodenum, small bowel, colon, and rectum. *J Trauma* 1990; **30**:1427–9.
8. Kantharia CV, Prabhu RY, Dalvi AN, Raut A, Bapat RD, Supe AN. Spectrum and outcome of pancreatic trauma. *Trop Gastroenterol* 2007; **28**:105–8.
9. Al-Ahmadi K, Ahmed N. Outcomes after pancreatic trauma: experience at a single institution. *Can J Surg* 2008; **51**:118–24.
10. Iqbal CW, Levy SM, Tsao K, Petrosyan M, Kane TD, Pontarelli EM, et al. Laparoscopic versus open distal pancreatectomy in the management of traumatic pancreatic disruption. *J Laparoendosc Adv Surg Tech A* 2012; **22**:595–8.