

Biological Characteristics of a Cerebellar Mass Regrowing after Removal in a Patient with Lhermitte-Duclos Disease: Emission Tomography Studies

Hideo Saito Kuniaki Ogasawara Takaaki Beppu Hideki Matsuura
Kazunori Terasaki

Department of Neurosurgery and Cyclotron Research Center, Iwate Medical University,
Morioka, Japan

Key Words

Lhermitte-Duclos disease · ^{99m}Tc -ethyl cysteinate dimer · ^{123}I -iomazenil · ^{15}O -gas

Abstract

Lhermitte-Duclos disease is a rare disorder characterized by a slowly enlarging mass in the cerebellum. The exact nature of this lesion remains unclear, but it has been variously characterized as hypertrophy, hamartoma or benign neoplasm. Single-photon emission computed tomography (SPECT) with ^{123}I -iomazenil and ^{99m}Tc -ethyl cysteinate dimer (ECD) display central benzodiazepine receptors that are widely distributed in the normal brain cortex, a combination of brain perfusion, enzymatic activity and blood-brain barrier function, respectively. This report describes the case of a 30-year-old man who developed Lhermitte-Duclos disease. The mass regrew after a subtotal removal 13 years earlier. The cerebellar lesion exhibited hyperperfusion and hypermetabolism on blood flow and a metabolic rate of oxygen imaging on ^{15}O -gas positron emission tomography (PET), as well as a hyperactivity and a defect in the uptake on ^{99m}Tc -ECD and ^{123}I -iomazenil SPECT imaging, respectively. The present Lhermitte-Duclos lesion might have the biological characteristics of both hypertrophy and neoplasm, from the perspective of results from ^{15}O -gas PET, ^{99m}Tc -ECD and ^{123}I -iomazenil SPECT.

© 2014 S. Karger AG, Basel

Kuniaki Ogasawara, MD
Department of Neurosurgery, Iwate Medical University
19-1 Uchimaruru
Morioka 020-8505 (Japan)
E-Mail kuogasa@iwate-med.ac.jp

Introduction

Lhermitte-Duclos disease is a rare disorder characterized by a slowly enlarging mass in the cerebellum. The mass rarely regrows after surgical removal. The exact nature of the lesion is unclear, but it has variously been characterized as hypertrophy, hamartoma or benign neoplasm [1–4].

Positron emission tomography (PET) with ^{15}O can be used to obtain information regarding cerebral blood flow and oxygen metabolism [5]. In addition, ^{123}I -iomazenil and $^{99\text{m}}\text{Tc}$ -ethyl cysteinyl dimer (ECD) single-photon emission tomography (SPECT) display central benzodiazepine receptors that are widely distributed in the normal brain cortex [5, 6] and a combination of brain perfusion, enzymatic activity and blood-brain barrier function [7, 8], respectively. These forms of emission tomography imaging can thus offer valuable assistance in studying the biological characteristics of brain tumors [1–4, 7, 8].

We previously reported a case involving a patient with Lhermitte-Duclos disease in which a cerebellar lesion exhibited hyperperfusion on ^{15}O -water PET and hyperactivity on $^{99\text{m}}\text{Tc}$ -ECD SPECT, suggesting that the lesion may represent hypertrophy or hamartoma rather than neoplasm [4]. The lesion in the present case regrew more than 10 years after surgical removal. We herein describe the biological characteristics of the regrowing lesion as evaluated using ^{15}O -gas PET, $^{99\text{m}}\text{Tc}$ -ECD and ^{123}I -iomazenil SPECT.

Case Report

A 17-year-old man underwent a subtotal removal of a cerebellar mass lesion (Lhermitte-Duclos disease) via craniectomy [4]. Thirteen years later, the patient presented with headaches. Neurological examination showed a slightly ataxic gait. MRI revealed a regrowing mass lesion with an abnormal laminated pattern of cortical architecture in the left cerebellar hemisphere, extending to the vermis (fig. 1).

Brain blood flow and metabolic rate of oxygen were calculated by the steady-state method using a PET scanner and ^{15}O -gas [5]. Both $^{99\text{m}}\text{Tc}$ -ECD and ^{123}I -iomazenil SPECT studies were performed at 3 and 7 days after PET, respectively, using the same procedures applied in previous studies [4, 5]. The study protocol was approved by the local ethics committee. Written informed consent was obtained from the subject prior to undergoing these studies.

In the cerebellar region, increases in both blood flow and metabolic rate of oxygen were detected on ^{15}O -gas PET imaging (fig. 2). While the lesion exhibited hyperactivity on $^{99\text{m}}\text{Tc}$ -ECD SPECT imaging, where the contrast was similar to that of blood flow PET imaging, ^{123}I -iomazenil SPECT showed a defect in uptake within the lesion (fig. 2).

The lesion was partially resected through a suboccipital craniectomy. Histological examination revealed typical features of Lhermitte-Duclos disease.

Discussion

Oxygen metabolic activity in brain tumors, including gliomas, is usually reduced and their metabolism is anaerobic (nonoxidative) [9]. In contrast, several studies using ^{18}F -fluorodeoxyglucose PET have shown a hypermetabolism in Lhermitte-Duclos lesions [1–3], and the lesion in the present case exhibited increases in both blood flow and the metabolic rate of oxygen on ^{15}O -gas PET. Such findings suggest that Lhermitte-Duclos lesions

aerobically metabolize glucose, and that this pathology may constitute of a hypertrophy rather than of a neoplasm.

As a lipophilic agent, ^{99m}Tc -ECD penetrates the normal blood-brain barrier and is retained by a conversion of lipophilic molecules into hydrophilic compounds. The tracer is hydrolyzed to polar metabolites by de-esterification [4, 7, 8]. Slow or absent de-esterification leads to a lack of tracer retention, resulting in hypoactivity in ^{99m}Tc -ECD SPECT, regardless of the increased blood flow [4, 7, 8]. Defective or decreased uptake of ^{99m}Tc -ECD in almost all brain tumors thus indicates that this enzymatic process within the tumor tissues is usually absent or reduced [7, 8]. In contrast, in the present case, hyperactivity was detected in the lesion by ^{99m}Tc -ECD SPECT, which provided an imaging contrast similar to that in blood flow PET. These findings were also similar to those obtained prior to resection of the original lesion 13 years earlier [4], suggesting that the Lhermitte-Duclos lesion is enzymatically active and shows a blood-tissue barrier function equivalent to that of the normal neural tissue, and that these biological characteristics of hypertrophy in the Lhermitte-Duclos lesion can remain unchanged for 10 years or more.

Central benzodiazepine receptors are widely distributed in the normal brain cortex, including the cerebellum, and their distribution is displayed on ^{123}I -iomazenil SPECT [5, 6]. Our data demonstrated the absence of central benzodiazepine receptors in the lesion, suggesting that Lhermitte-Duclos lesions may represent a neoplasm rather than hamartoma or hypertrophy.

In conclusion, the present case of a Lhermitte-Duclos lesion regrowing 13 years after the initial removal might have shown the biological characteristics of both hypertrophy and neoplasm, from the perspective of results from ^{15}O -gas PET, ^{99m}Tc -ECD and ^{123}I -iomazenil SPECT.

Acknowledgments

This work was partly supported by a Grant-in-Aid for Strategic Medical Science Research Center of Ministry of Education, Culture, Sports, Science and Technology, Japan, by the Core Research for Evolutional Science and Technology of the Japan Science and Technology Agency and by the SENSHIN Medical Research Foundation.

Disclosure Statement

The authors declare no conflict of interest.

References

- 1 Goto Y, Hashimoto N, Okita Y, Goto T, Rabo C, Hirayama H, Horikawa Y, Kinoshita M, Kagawa N, Yoshimine T: A surgically treated case of Lhermitte-Duclos disease with a precise natural history and high uptake of FDG on PET. *J Neurooncol* 2010;97:445–450.
- 2 Hayasaka K, Nishashi T, Takebayashi S, Bundoh M: FDG PET in Lhermitte-Duclos disease. *Clin Nucl Med* 2008;33:52–54.
- 3 Nakagawa T, Maeda M, Kato M, Terada N, Shimizu S, Morooka Y, Nakano H, Takeda K: A case of Lhermitte-Duclos disease presenting high FDG uptake on FDG-PET/CT. *J Neurooncol* 2007;84:185–188.
- 4 Ogasawara K, Yasuda S, Beppu T, Kobayashi M, Doi M, Kuroda K, Ogawa A: Brain PET and technetium-99m-ECD SPECT imaging in Lhermitte-Duclos disease. *Neuroradiology* 2001;43:993–996.
- 5 Chida K, Ogasawara K, Kuroda H, Aso K, Kobayashi M, Fujiwara S, Yoshida K, Terasaki K, Ogawa A: Central benzodiazepine receptor binding potential and cerebral blood flow images on SPECT correlates with oxygen

- extraction fraction images on PET in patients with chronic unilateral middle cerebral or internal carotid artery occlusive disease. *J Nucl Med* 2011;52:511–518.
- 6 Nakagawara J, Sperling B, Lassen NA: Incomplete brain infarction of reperfused cortex may be quantitated with iomazenil. *Stroke* 1997;28:124–132.
 - 7 Hirano T, Suzuki H, Higuchi T, Watanabe N, Oriuchi N, Shibasaki T, Tamura M, Endo K: Grade II astrocytoma visualized by technetium-99m-ECD SPECT. *J Nucl Med* 1996;37:272–275.
 - 8 Papazyan JP, Delavelle J, Burkhard P, Rossier P, Morel C, Maton B, Otten P, Pizzolato GP, Rufenacht DA, Slosman DO: Discrepancies between HMPAO and ECD SPECT imaging in brain tumors. *J Nucl Med* 1997;38:592–596.
 - 9 Lammertsma AA, Wise RJ, Cox TC, Thomas DG, Jones T: Measurement of blood flow, oxygen utilization, oxygen extraction ratio, and fractional blood volume in human brain tumours and surrounding oedematous tissue. *Br J Radiol* 1985;58:725–734.

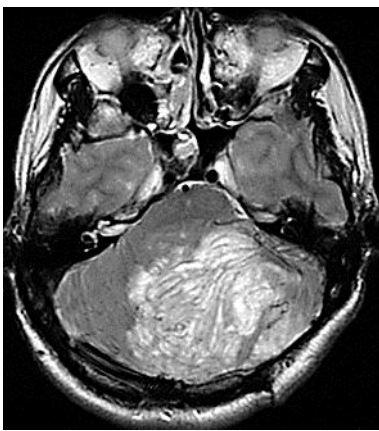


Fig. 1. T2-weighted MRI revealed a distinct tiger-striped appearance with abnormally oriented folia in the left cerebellar hemisphere, extending to the vermis.

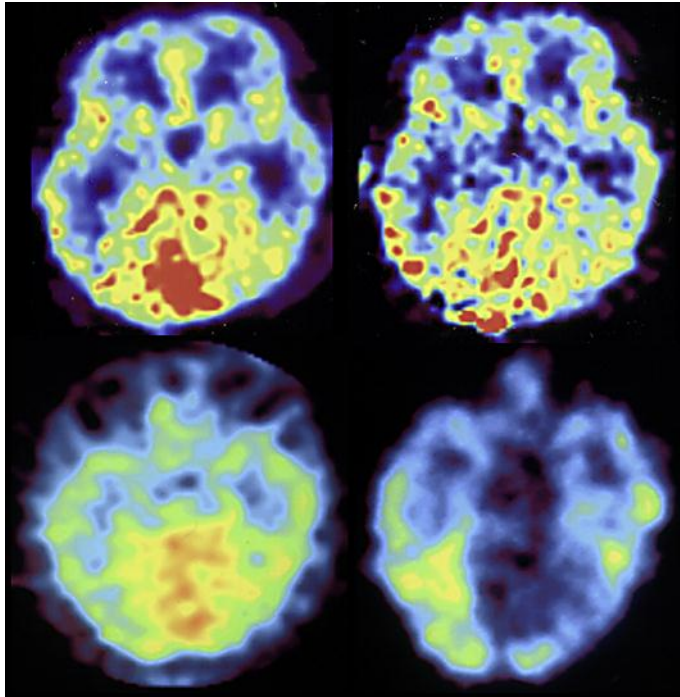


Fig. 2. The cerebellar lesion exhibited a hyperperfusion on blood flow imaging (upper left) and a hypermetabolism on the metabolic rate of oxygen imaging (upper right), respectively, on ^{15}O -gas PET. $^{99\text{m}}\text{Tc}$ -ECD (lower left) and ^{123}I -iomazenil (lower right) SPECT show hyperactivity and a defect in the uptake of the lesion.