

# Treatment of Intrabony Defects by DFDBA Alone or in Combination with PRP: A Split-Mouth Randomized Clinical and Three-Dimensional Radiographic Trial

Hengameh Khosropanah<sup>1</sup>, Shoaleh Shahidi<sup>2</sup>, Amar Basri<sup>3</sup>, Maral Houshyar<sup>3</sup>

<sup>1</sup>Associate Professor, Department of Periodontics, Faculty of Dentistry, Shiraz University of Medical Sciences, Shiraz, Iran

<sup>2</sup>Professor, Department of Radiology, Faculty of Dentistry, Shiraz University of Medical Sciences, Shiraz, Iran

<sup>3</sup>Postgraduate Student, Department of Periodontics, School of Dentistry, Shiraz University of Medical Sciences, Shiraz, Iran

## Abstract

**Objectives:** The efficacy of adding platelet-rich plasma (PRP) to demineralized freeze-dried bone allograft (DFDBA) in order to improve the clinical and radiographic results obtained in treatment of deep periodontal intrabony defects has yet to be fully elucidated.

**Materials and Methods:** This double blind, split-mouth randomized controlled clinical trial was conducted on 12 patients with two comparable bilateral intrabony defects. Each pair of defects was randomly treated with DFDBA+PRP (test) or DFDBA alone (control). Clinical attachment level (CAL), intrabony defect depth (IDD), distance from the stent to the alveolar crest and pocket depth (PD) as well as radiographic parameters including the radiographic defect depth, width and angulation were measured at baseline and six months post-operatively. The paired t-test was used to compare the pre and post-treatment values and the unpaired t-test compared the test and control groups.

**Results:** The mean reductions in PD and CAL were  $4.5 \pm 1.3$  mm and  $3.6 \pm 1.6$  mm in sites treated with DFDBA+ PRP, respectively ( $P < 0.01$ ); these reductions were  $4.1 \pm 1.4$  mm and  $3.5 \pm 1.3$  mm, respectively in DFDBA group ( $P < 0.01$ ). Radiographic evaluation revealed  $2.5 \pm 1.1$  mm reduction in the radiographic defect depth in the test and  $2.1 \pm 1.2$  mm in the control sites. The defect angulation increased at both sites. Statistically, there were no significant differences between the two treatment modalities ( $P < 0.01$ ).

**Conclusion:** This study showed that both treatments resulted in significant PD reduction, CAL gain and IDD reduction. Also, PRP failed to enhance the results obtained by DFDBA.

**Key words:** Cell- and Tissue-Based Therapy; Allografts; Cone-Beam Computed Tomography; Platelet-Rich Plasma

*Journal of Dentistry, Tehran University of Medical Sciences, Tehran, Iran (2015; Vol. 12, No. 10)*

Corresponding author:

H. Khosropanah, Department of Periodontics, School of Dentistry, Shiraz University of Medical Sciences, Shiraz, Iran

Khosropanah979@yahoo.com

Received: 16 March 2015

Accepted: 27 August 2015

## INTRODUCTION

Chronic periodontal disease is a major cause of tooth loss. It increases the risk of systemic diseases and adversely affects the quality of

life. Thus, treatment of this condition is necessary. Although in the past decades stopping or slowing the rate of disease progression was the aim of most treatment

modalities, nowadays, with the introduction of new procedures, restoring the lost structures is a priority. In this way, different materials are used in different ways. Allografts are autogenous bone substitutes used to eliminate the need for a second surgical procedure. Two popular forms of allografts are available namely freeze-dried bone allograft (FDBA) and DFDBA. Both have the same preparation procedure but DFDBA undergoes an additional demineralization step, conferring osteoinductivity to it when exposed to bone morphogenetic proteins (BMP) [1].

Growth factors are used to enhance the efficacy of periodontal regeneration; among which, PRP is the most effective because it is derived from the patient's own blood. No risk of infection transmission and absence of immunological reactions are among the advantages of PRP [2]. In addition, it is not expensive compared to recombinant growth factors.

Several studies have approved the role of PRP in enhancing bone regeneration and osseointegration [2-5]. It is effective for enhancing the soft tissue healing [6].

Different methods have been introduced to evaluate the efficacy of reconstructive surgeries each with merits and demerits. The clinical methods, using a periodontal probe, take a noninvasive approach to accurately compare the pre- and post-treatment states. By preparing a groove on a fixed stent, the location and direction of the probe would be reproducible. Different results obtained by various studies using the above-mentioned clinical method may be due to the subjectivity of the amount of force applied [7].

Thus, use of standardized radiography is necessary for assessing the interproximal bony changes after periodontal surgery. The three-dimensional (3D) radiography by cone beam computed tomography (CBCT) with lower radiation dose and higher quality than conventional computed tomography (CT) has

enhanced periodontal evaluation especially for diagnosis of fenestration, intrabony defects and periodontal cysts [8, 9]. Moreover, CBCT has superiority to subtraction techniques in evaluating the underlying bony changes [10].

Although several studies have shown that DFDBA leads to bone regeneration in intrabony defects, different amounts of bone fills have been reported [11-14]. Also, a consensus has been reached on the role of PRP in enhancing the outcome of application of DFDBA. Recently, a histological study showed that combination of PRP with purified bovine allograft had superior regeneration potential compared to each material alone [15]. However, a systematic review concluded that we are still far from having adequate knowledge about different aspects of using PRP in regenerative procedures and the best type of biomaterial, the best protocol of production and method of application require further investigations [16].

A number of researchers performed case-control studies on different subjects with variable levels of platelets and growth factors [17-19]. However, only a few studies have compared the effectiveness of PRP in a split-mouth design with the same level of platelets and to the best of our knowledge, there have been no studies comparing 3D radiography with the clinical outcome of regenerative therapy for intrabony defects. Therefore, the aim of this randomized controlled split-mouth prospective clinical and radiographic trial was to compare the extent of periodontal regeneration with the use of DFDBA alone and in combination with PRP.

## MATERIALS AND METHODS

The patients participated in this study were selected among those referred to the Department of Periodontology of Shiraz Dental School. Sixteen patients were screened by full mouth periapical series showing deeper than 4 mm angular bony defects in two quadrants and underwent non-surgical phase

of periodontal therapy, including oral hygiene instruction, scaling and root planning, caries removal, correcting the margins of restorations and occlusal adjustment if needed. Approximately four weeks after the completion of phase one, 12 patients with less than 15% plaque index were selected based on the following inclusion and exclusion criteria:

The inclusion criteria were: 1- Moderate to advanced periodontitis 2- At least two intrabony defects with more than 4mm depth based on clinical examination and 3- At least 3mm of keratinized tissue.

The exclusion criteria were: 1- Systemic diseases or pregnancy 2- Tobacco use 3- Antibiotic intake in the past three months 4- Taking anticoagulants for any reason and 5- History of periodontal therapy.

After obtaining the institutional and ethical approval (CT-90-5834) the consent forms were signed by the patients.

**Examiner calibration:** Eight patients in the maintenance phase were selected and 616 different sites were measured and the measurements were repeated two weeks later. The intraclass correlation coefficient was equal to 0.964 ( $P < 0.001$ ).

**Stent fabrication:** Two acrylic stents for each site were prepared and checked for proper stability: one for CAL and the other one for measuring the depth of interproximal bony defects during the surgical procedures. The calibrated examiner who was not involved in the treatment procedures performed all measurements at baseline and six months after surgery.

**PRP preparation:** Ten to 15 minutes before the surgical procedure, 15 cc of blood was taken and transferred into a sterile tube containing 0.5cc of 3.8% sodium citrate, which was then centrifuged at 460 g speed for eight minutes (BTi; PRGF system, Biotechnology Institute, Vitoria-Gasteiz, Spain). Three distinct layers (upper, middle and lower) with variable levels of platelets were detected in the tube.

One cc of plasma of the upper level (platelet poor) and 0.5 cc of the middle level (platelet medium) were removed by a 100-1000  $\mu\text{L}$  graded micropipette; 0.5 cc of the lower layer (right on top of the red blood cell layer), which was platelet-rich plasma was extracted carefully by a 20-200  $\mu\text{L}$  graded micropipette and transferred into a tube with 50  $\mu\text{L}$  of calcium chloride.

**Surgical procedure:** In order to achieve infiltration anesthesia, we administered 2% lidocaine with 1:100,000 epinephrine and elevated a simplified papilla-preservation flap [20]. For better soft tissue coverage, the site of incision was selected opposite to the site of angular bony defect. In other words, if the angular bony defects were at the buccal aspect of the teeth, the incision was made on the lingual side and vice versa.

The mucoperiosteal flap was extended more than 3mm beyond the margins of the bony defect. All the granulation tissue was removed and the root surface was debrided by appropriate fine hoes and Gracey curettes (Hufriedy, Chicago, IL, USA). According to the manufacturer's instructions, 20 minutes prior to its application, DFDBA (CenoBone, Kish Tissue Regeneration Corporation, Kish, Iran) was hydrated with sterile saline. The stent was inserted and the probe was located in the deepest point of the defect; after drawing the direction by a copy pencil, the stent was removed.

A groove was prepared by a fissure carbide bur on the stent. The same procedure was done for the coronal border of the defect and another groove was prepared. The number of bony walls was documented.

In this study, randomization was done using a two-step coin tossing method. The first step of coin tossing was performed to choose the right side (tails) versus the left side (heads) and in the second step of coin tossing, the tails indicated controls and the heads indicated the test group. This way, location and type of intervention were both randomized.

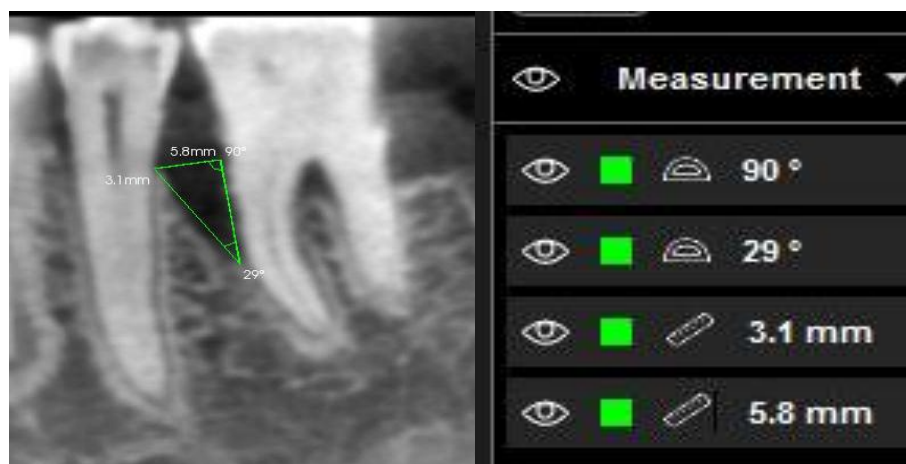

Fig. 1. Pre-treatment measurement of defect depth, width and angle

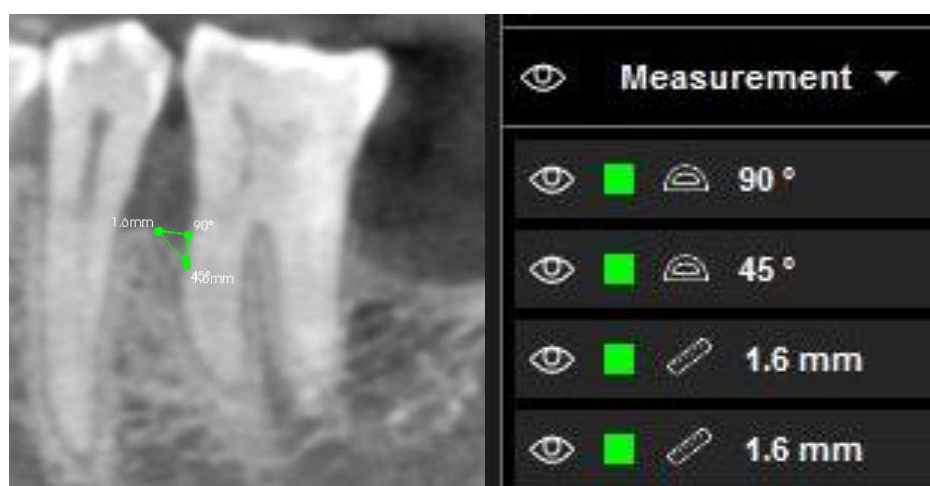


Fig. 2. Post-treatment measurement of defect depth, width and angle

In the test side, DFDBA+PRP and in the opposite side DFDBA alone was applied using a condenser. A periosteal releasing incision was made for coronal positioning of the flap. Then, the flap was closed by interrupted vertical mattress sutures (4-0 Vicryl Rapid), which were removed after 10 days. All patients received antibiotics (amoxicillin 500 mg tid for one week), analgesics (acetaminophen 325 mg prn) and 0.2% chlorhexidine mouthwash (bid).

#### **Radiographic examinations:**

After completing the first phase of treatment, CBCT was obtained from the surgical regions and repeated six months later.

Radiographs were taken at each stage by the same unit (9000, Kodak, Carestream Health Inc., Rochester, NY, USA) with the exposure settings of 60-90 kVp, 360-degree rotation around the patient, voxel size of  $76.5 \times 76.5 \times 76.5 \mu\text{m}$  and exposure time of 13.9 seconds. The obtained CBCT scans were evaluated at a slice thickness of  $200\mu\text{m}$ . The 3D evaluation of cross sectional and coronal images helped us determine the exact location of the defects in various directions (buccolingual, mesiodistal and apico-coronal). The coronal view was used for the measurement of the intrabony defect depth, width and angle in the region of the highest depth of the defect.

We draw one line from the defect depth parallel to root surface and another line perpendicular to the alveolar crest. A defect angle was defined as an angle between the vertical line and the apical point of the angular bony defect (Fig. 1).

All measurements, including defect height, defect width and angle at baseline and six months later were recorded by an expert radiologist who was blinded to the type of surgical procedure.

#### **Statistical analysis:**

The mean±standard deviation values were reported for clinical and radiographic parameters. Repeated measures ANOVA was used to assess these changes. SPSS version 15 (Microsoft, Chicago, IL, USA) was used for data analysis.  $P<0.05$  was considered statistically significant.

#### **RESULTS**

After the first stage of treatment, 12 subjects including five males and seven females with chronic advanced periodontitis and a mean age of  $45\pm 10.7$  years were enrolled in this split-mouth study. All participants had good cooperation and an uneventful healing and none of them were excluded from the study. During the course of treatment, plaque index had no change while bleeding on probing showed significant reduction from  $14.2\pm 1.0$  to  $13.5\pm 1.1$  ( $P<0.05$ ).

There were no statistically significant differences in terms of PD and CAL; furthermore, both clinically and radiographically, bone fills were found in both DFDBA+PRP and DFDBA groups at baseline and at six months. But both groups showed statistically significant changes in all parameters after treatment. The PD reduction and clinical attachment gain in both groups improved significantly. Reduction in the PD was  $4.5\pm 1.3$ mm in DFDBA+PRP group and  $4.1\pm 1.4$ mm in DFDBA group; which were both significant ( $P<0.001$ ).

The CAL was determined by the distance from the depth of pocket to the lower margin of the acrylic stent. Distance from the apical edge of the stent to the depth of lesion in the experimental group decreased from  $12.3\pm 2.3$  mm to  $9.1\pm 2.0$  mm, while this value in the control group decreased from  $11.9\pm 2.1$  mm to  $8.8\pm 2.4$  mm. At baseline, the distance between the alveolar crest and stent was  $6.8\pm 1.8$ mm in the DFDBA + PRP group and  $6.7\pm 2.4$ mm in the DFDBA group. This value increased to  $7.0\pm 1.6$ mm in the test group while the control group showed no change (Table 1).

In terms of soft tissue recession, the two groups displayed no significant differences. In radiographic evaluation, while the defect depths decreased, the angulations increased (Fig. 2). The width, however, showed no change. The CBCT scans revealed that the defect depth decreased from  $4.7\pm 1.6$  mm to  $2.1\pm 1.4$  mm in the test group and from  $5.0\pm 2.0$  mm to  $2.8\pm 1.3$  mm in the control group. After healing, reduction of defect height in each group was statistically significant ( $P=0.003$ ) but no significant difference was found between the control and test groups ( $P>0.05$ ).

We compared the widths of the defects before and after the treatment. The mean values of the width for the test and control groups were as follows: in the test group, it remained constant at  $2.9\pm 0.7$  mm after treatment whereas in the control, it changed from  $3.3\pm 0.9$  mm at baseline to  $2.6\pm 0.8$ mm. This result indicates that neither of the groups showed statistically significant changes in the width of the lesions.

The radiographic variations of the angle of lesions after six months compared to baseline in both groups showed a significant increase in the angle of the defects. After six months, the angle of the defects increased from  $32.2\pm 10.2^\circ$  to  $49.4\pm 14.2^\circ$  in the test group and from  $35.3\pm 11.6^\circ$  to  $51.0\pm 17.1^\circ$  in the control group. This increase in the angle was significant in both groups, when compared to baseline ( $P<0.01$ ).

**Table 1.** Clinical parameters (mean±standard deviation and mean changes) in the test and control sides measured by a periodontal probe (ANOVA)

Parameter	Groups	N	Baseline	At six months	P values
PD	Test	12	8.6±1.6	4.0±1.0	P <sub>group</sub> =0.280
	Control	12	7.8±1.4	3.6±0.6	P <sub>time</sub> <0.001
CAL	Test	12	8.7±1.6	5.0±1.8	P <sub>group &amp; time</sub> =0.481
	Control	12	7.9±1.9	4.4±1.5	P <sub>group</sub> =0.450
REC	Test	12	1.1±1.4	1.5±1.4	p <sub>time</sub> <0.001
	Control	12	0.3±0.8	1.2±1.2	p <sub>group &amp; time</sub> =0.792
					p <sub>group</sub> =0.131
					p <sub>time</sub> <0.337
					p <sub>group &amp; time</sub> = 0.021

PD: Probing depth; CAL: Clinical attachment level; REC: Recession

**Table 2.** Distance from stent to the deepest point of defect and to alveolar crest (mean ±standard deviation and mean changes) in the test and control sides (ANOVA)

Parameter	Groups	N	Baseline	At six months	P value
SDD	Test	12	12.3±2.3	9.1±2.0	P <sub>g</sub> =0.685
	control	12	11.9±2.1	8.8±2.4	P <sub>t</sub> = 0.020
SAC	Test	12	6.8±1.8	7.0±1.6	P <sub>gxt</sub> = 0.856
	control	12	6.7±2.4	6.7±2.4	P <sub>g</sub> =0.896
					P <sub>t</sub> = 0.762
					P <sub>g x t</sub> = 0.509

SDD: Distance from stent to the deepest point of defect

SAC: Distance from stent to the alveolar crest

**Table 3.** Comparison of defect angulations and clinical attachment level, probing depth and radiographic height

Parameter	Groups	Mean± SD	P value
CAL	<30°	3.7±1.5	0.624
	≥30°	3.4±1.4	
PD	<30°	4.5±1.2	0.431
	≥30°	4.1±1.5	
Height	<30°	3.1±1.1	0.003
	≥30°	1.7±0.9	

PD: Probing depth; CAL: Clinical attachment level; SD: Standard deviation

The percentage of hard tissue fills was clinically (but not significantly) more in DFDBA+PRP group ( $50\pm 10\%$  versus  $40\pm 10\%$ ).

Comparing the clinical and radiographic measurements in both groups, we found that the clinical attachment change was  $3.1\pm 1.2$  mm in the test group and  $3.0\pm 0.9$  mm in the control group; the radiographic difference was  $2.5\pm 1.1$  mm in the test and  $2.1\pm 1.2$  mm in the control group. However, statistically, no significant difference was observed (Table 2). Regardless of the treatment modality used (with or without PRP), the lesions were divided into two groups in terms of angulation:  $>30^\circ$  or  $\leq 30^\circ$ . Defect angulation reduction was significantly higher in the depth of  $\leq 30^\circ$  ( $3.1\pm 1.1$  mm) than in  $>30^\circ$  ( $1.7\pm 0.9$ ) (Table 3).

## DISCUSSION

There are some controversies about the effect of PRP alone or in combination with other materials. This study was designed to compare the efficacy of DFDBA alone and combined with PRP. Although there was no significant difference between the two treatment modalities, significant improvement was noticed in PD reduction, clinical attachment gain and intrabony defect fill.

Various results have been obtained from different studies using different commercial products of DFDBA. The main reason can be the activity and concentration of BMP in different allografts, which makes the results unpredictable. Allografts are often procured from cadavers and younger cadavers have higher level of BMP. Moreover, cortical and membranous bones have higher concentrations of BMP than trabecular and endochondral bone, respectively. Another reason can be suitable particle size of larger than  $250\mu\text{m}$ . In addition, even the method of sterilization by irradiation or ethylene oxide affects the amount of BMP and DFDBA properties. Hence, the fabrication, formulation and

different processing steps have a critical role in the quality and osteoconductive properties of DFDBA [21, 22].

The findings of this study showed superior results in the DFDBA group compared to other studies [11,13,17]. The major reason for these differences might be the source and methods of the preparation of allogeneic materials. Younger donors, cortical versus cancellous bone, site specificity and the particle size can all affect the results [23]. Materials used in this study were obtained from young volunteers who had received trauma to the bones caused by accidents. To the best of our knowledge, only a few studies have compared graft materials alone and in combination with PRP [17,19,24,25]. However, the main differences between the current study and the previous ones were that we used bone substitute from living tissue and employed BTI instead of Smart Prep 2. Hanna et al. used xenografts and showed that the reduction in PD and clinical attachment gain was greater in the DFDBA and PRP combination group [24]. We, however, found no significant difference between our study groups. They used Smart Prep 2 equipment with two rounds of centrifugation, first at 2400 rpm for 10 minutes and then at 3600 rpm for 15 minutes. Kevy and Jacobson compared Smart Prep 2 system with BTI (PRGF system, Biotechnology Institute, Vitoria-Gasteiz, Spain) and reported that Smart Prep 2 not only yielded a higher platelet concentration ( $774\pm 284\times 10^3 \mu\text{L}$  versus  $320\pm 35 \times 10^3\mu\text{l}$ ) but also more growth factors, such as platelet derived growth factor-AB (PDGF-AB), transforming growth factor (TGF) and vascular endothelial growth factor (VEGF) [26]. On the other hand, Han et al. found that the lowest effective concentration of TGF- $\beta$  is 50-100 ng/ $\mu\text{L}$ , but this concentration was around  $42\pm 9$  ng/ $\mu\text{L}$  using BTI (PRGF system, Biotechnology Institute, Vitoria-Gasteiz, Spain) [27]. For preparing PRP, Hanna et al. [24] used calcium chloride and thrombin but

in BTI system only calcium chloride was introduced as an anti-coagulation agent.

Some studies used DFDBA or hydroxyapatite (HA) and found better results in combination with PRP [17,18]. This might be due to the fact that they have utilized smart Prep 2 system.

On the contrary, there are some other researchers who reported that PRP had no positive effects on bone regeneration [24,27, 28].

Overall, it seems that the presence of thrombin, the method of preparation, the graft materials and the study design have considerable effects on the outcome of treatment in different studies. From the radiographic point of view, other studies used conventional radiography with the CEJ as the reference point [17,18]. Because of the superimposition of other structures, this technique did not determine the exact location of CEJ and dimensions of defects. In the current study, the intrabony defects on CBCT scans were detected by measuring the distance between the perpendicular lines from the alveolar crest to the teeth surfaces. Since the position of the alveolar crest showed no significant change compared to baseline, this finding can be used as a reference to measure the width and depth of the defects. Changes in bone height were  $2.5 \pm 1.1$  mm in the test and  $2.1 \pm 1.2$  mm in the control groups; these differences were significant in both groups. Using the conventional long cone parallel radiographic technique, Okuda and colleagues determined the height of lesions to be  $3.5 \pm 1.5$  mm in the HA + PRP and  $2.7 \pm 1.6$  mm in the HA group [18]. Piemontese et al. observed  $3.6 \pm 1.7$  mm pocket depth reduction in DFDBA+PRP and  $3.2 \pm 1.5$  mm in DFDBA group [17].

The changes recorded in our study were found to be lower than those in a previous study [27]; this may be due to the high accuracy of the 3D technique. In studies by Pappalardo and Guarnieri [15] and Roffi et al, [16], two

dimensional radiography may have caused overlapping of the teeth and root surfaces leading to overestimation of defect depth.

It seems that CBCT is able to show the actual depth of lesions before and after treatment.

In line with the findings of Markou et al, [28], our study revealed an increase in defect angle in both groups ( $17.1 \pm 10.1^\circ$  in the test and  $15.6 \pm 13.3^\circ$  in the control sites). This can be explained by the fact that osseous regeneration starts from the apical region of the root irrespective of the width of the defects, so the newly formed angle would be larger than the baseline angle.

We divided the radiographic defect angles into two groups:  $>30^\circ$  or  $\leq 30^\circ$ . The amount of defect height reduction was  $1.7 \pm 0.9$  mm in the greater than  $30^\circ$  group and  $3.1 \pm 1.1$  mm in the less than  $30^\circ$ ; this difference was statistically significant. Cortelini and Tonetti introduced  $<25^\circ$  as narrow and  $>37^\circ$  as wide defect angle and reported that more attachment was gained in narrow defects compared to wide type [29]. Ilgenli and colleagues showed that in defect angles less than  $18^\circ$  improvement of PD, CAL and alveolar crest to the base of the defect was significantly greater than those in  $33^\circ$  defect angle [25].

Markou et al. divided the defect angles into two groups of less and more than  $30^\circ$ . Unlike other studies, Markou et al. found that in defect angles greater than  $30^\circ$  the amount of defect fill was higher than that in defect angles smaller than  $30^\circ$ . The authors believe that this difference might be due to the small sample size [28].

In the current study, the results were comparable to those of other studies in that smaller defect angles showed greater improvement in periodontal parameters such as defect fill, clinical attachment gain and reduction of PD.

We suggest future studies with a larger sample size to increase the power of the study and assess the soft tissue healing process over a longer period of time. A more comprehensive



and detailed evaluation of different techniques for preparation of PRP should be done.

## CONCLUSION

By comparing the clinical and radiographic outcome of regenerative therapy using DFDBA + PRP and DFDBA alone, this study demonstrated that after six months, both groups showed significant improvement in clinical and radiographic parameters. However, the addition of PRP to DFDBA did not improve the treatment results compared to those obtained in the DFDBA group.

## ACKNOWLEDGMENTS

The authors thank the Vice-Chancellor of Research of Shiraz University of Medical Sciences for supporting this research (Grant #5834). This manuscript was part of a thesis by Dr. Amar Basri and Dr. Maral Hooshyar. The authors also thank Dr. Mehrdad Voosogh of the Center of Research of Dentistry for statistical analysis and Dr. Ehya Amalsaleh for improving the use of English in the manuscript.

## REFERENCES

- 1- Reynolds MA, Bowers GM. Fate of demineralized freeze-dried bone allografts in human intrabony defects. *J Periodontol.* 1996 Feb;67(2):150-7.
- 2- Marx RE, Carlson ER, Eichstaedt RM, Schimmele SR, Strauss JE, Georgeff KR. Platelet-rich plasma: Growth factor enhancement for bone grafts. *Oral Surg Oral Med Oral Pathol Oral Radiol Endod.* 1998 Jun;85(6):638-46.
- 3- Kassolis JD, Rosen PS, Reynolds MA. Alveolar ridge and sinus augmentation utilizing platelet-rich plasma in combination with freeze-dried bone allograft: case series. *J Periodontol.* 2000 Oct;71(10):1654-61.
- 4- Camargo PM, Lekovic V, Weinlaender M, Vasilic N, Madzarevic M, Kenney EB. Platelet-rich plasma and bovine porous bone mineral combined with guided tissue

regeneration in the treatment of intrabony defects in humans. *J Periodontal Res.* 2002 Aug;37(4):300-6.

5- Rodriguez A, Anastassov GE, Lee H, Buchbinder D, Wettan H. Maxillary sinus augmentation with deproteinated bovine bone and platelet rich plasma with simultaneous insertion of endosseous implants. *J Oral Maxillofac Surg.* 2003 Feb;61(2):157-63.

6- Suaid FF, Carvalho MD, Santamaria MP, Casati MZ, Nociti FH Jr, Sallum AW, et al. Platelet-rich plasma and connective tissue grafts in the treatment of gingival recessions: a histometric study in dogs. *J Periodontol.* 2008 May;79(5):888-95.

7- Fowler C, Garret S, Crigger M, Egelberg J. Histologic probe position in treated and untreated human periodontal tissues. *J Clin Periodontol.* 1982 Sep;9(5):373-85.

8- Kasaj A, Willershausen B. Digital volume tomography for diagnosis in periodontology. *Int J Comput Dent.* 2007 Apr;10(2):155-68.

9- Tyndall DA, Rathore S. Cone beam CT diagnostic applications: caries, periodontal bone assessment, and endodontic applications. *Dent Clin North Am.* 2008 Oct;52(4):825-41.

10- Vandenberghe B, Jacobs R, Yang J. Diagnostic validity (or acuity) of 2D CCD versus 3D CBCT-images for assessing periodontal breakdown. *Oral Surg Oral Med Oral Pathol Oral Radiol Endod.* 2007 Sep;104(3):395-401.

11- Rummelhart JM, Mellonig JT, Gray JL, Towte HJ. A comparison of Freeze-Dried bone allograft and Demineralized Freeze-Dried bone allograft in human periodontal osseous defects. *J Periodontol.* 1989 Dec;60(12):655-63.

12- Aichelmann-Reidy ME, Reynolds MA. Predictability of clinical outcomes following regenerative therapy in intrabony defects. *J Periodontol.* 2008 Mar;79(3):387-93.

13- Mellonig JT. Decalcified freeze dried bone allograft implant in human periodontal defects. *Int J Periodontics Restorative Dent.* 1984;4(6):40-55.

- 14- Hoidal MJ, Grimard BA, Mills MP, Schoolfield JD, Mellonig JT, Mealey BL. Clinical evaluation of demineralized freeze dried bone allograft with and without enamel matrix derivative for treatment of periodontal osseous defects in human. *J Periodontol.* 2008 Dec;79(12):2273-80.
- 15- Pappalardo S, Guarnieri R. Efficacy of Platelet-Rich-Plasma (PRP) and Highly Purified Bovine Xenograft (Laddec®) Combination in Bone Regeneration after Cyst Eucleation: Radiological and Histological Evaluation. *J Oral Maxillofac Res.* 2013 Oct 1;4(3):e3.
- 16- Roffi A, Filardo G, Kon E, Marcacci M. Does PRP enhance bone integration with grafts, graft substitutes, or implants? A systematic review. *BMC Musculoskelet Disord.* 2013 Nov 21;14:330.
- 17- Piemontese M, Aspriello SD, Rubini C, Ferrante L, Procaccini M. Treatment of periodontal intrabony defects with demineralized freeze-dried bone allograft in combination with platelet-rich plasma: a comparative clinical trial. *J Periodontol.* 2008 May;79(5):802-10.
- 18- Okuda K, Tai H, Tanabe K, Suzuki H, Sato T, Kawase T, et al. Platelet-rich plasma combined with a porous hydroxyl apatite graft for the treatment of intrabony periodontal defects in humans: a comparative controlled clinical study. *J Periodontol.* 2005; 76:890-98.
- 19- Demir B1, Sengün D, Berberoğlu A. Clinical evaluation of platelet-rich plasma and bioactive glass in the treatment of intra-bony defects. *J Clin Periodontol.* 2007 Aug;34(8): 709-15.
- 20- Cortollini P, Prato GP, Tonetti MS. The simplified papilla preservation flap. A novel surgical approach for the management of soft tissues in regenerative procedures. *Int J Periodontics Restorative Dent.* 1999 Dec;19 (6):589-99.
- 21- Lynch SE, Marx RE, Nevin M, Wisner-Lynch LA. *Tissue engineering: Application in oral and maxillofacial surgery and periodontics.* 2<sup>nd</sup> edition; Quintessence Publishing; 2008:165-66.
- 22- Misch CE. *Contemporary implant dentistry; Soft and hard tissue rehabilitation,* 3<sup>rd</sup> edition. St. Louis, Mosby; 2008:208-19.
- 23- Bosshardt DD, Sculean A. Does periodontal tissue regeneration really work? *Periodontol 2000.* 2009;51:208-19.
- 24- Hanna R, Trejo PM, Weltman RL. Treatment of intrabony defects with bovine-derived xenograft alone and in combination with platelet-rich plasma: A Randomized clinical trial. *J Periodontol.* 2004 Dec;75(12): 1668-77.
- 25- Ilgenli T, Dündar N, Kal BI. Demineralized freeze-dried bone allograft and platelet-rich plasma vs platelet-rich plasma alone in infrabony defects: a clinical and radiographic evaluation. *Clin Oral Investig.* 2007 Mar;11(1):51-9.
- 26- Kevy SV, Jacobson MS. Comparison of methods for point of care preparation of autologous platelet gel. *J Extra Corpor Technol.* 2004 Mar;36(1):28-35.
- 27- Han J, Meng HX, Tang JM, Li SL, Tang Y, Chen ZB. The effect of different platelet-rich plasma concentrations on proliferation and differentiation of human periodontal ligament cells in vitro. *Cell Prolif.* 2007 Apr;40(2):241-52.
- 28- Markou N, Pepelassi E, Vavouraki H, Stamatakis HC, Nikolopoulos G, Vrotsos I, et al. Treatment of periodontal endosseous defects with platelet-rich plasma alone or in combination with demineralized freeze-dried bone allograft: a comparative clinical trial. *J Periodontol.* 2009 Dec;80(12): 1911-9.
- 29- Cortellini P, Tonetti M. Radiographic defect angle influences the outcome of GTR therapy in intrabony defects. *J Dent Res* 1999 Dec; 78:381.