

## PARANASAL SINUS PATHOSES ON CONE BEAM COMPUTED TOMOGRAPHY

### *Konik Işınlı Bilgisayarlı Tomografide Paranasal Sinüs Patolojileri*

Esin BOZDEMİR, Özlem GÖRMEZ, Derya YILDIRIM, Ayşe AYDOĞMUŞ ERİK

Received: 10/09/2015

Accepted: 09/12/2015

#### ABSTRACT

**Purpose:** The aim of this study was to investigate paranasal sinus pathoses detected on cone-beam computed tomography (CBCT) in an adult population. **Patients and Methods:** Three observers retrospectively inspected 353 consecutive CBCT scans obtained in a dentomaxillofacial radiology department for paranasal sinus pathoses. Descriptive statistics and chi-square tests were used to determine the prevalence of categorical parameters. **Results:** The age of the patients ranged from 18 to 85 years (mean 41.27±16.76). There were 172 (48.7%) females and 181 (51.3%) males. There was a significant difference between the genders ( $p=0.02$ ), with males (53.5%) having more sinus pathoses than females (46.5%). When the left and right sinuses were considered together, pathoses were most commonly seen in the maxillary sinuses (57.1%), followed by the ethmoid (53.7%), frontal (22.6%), and sphenoid sinuses (15.8%). Mucosal thickening was the most frequently observed abnormality (51.7%), followed by hypoplasia (17.5%) and sinusitis (17.3%). **Conclusion:** CBCT is a preferable imaging method for evaluation of paranasal sinuses. Dentomaxillofacial radiologists should examine the whole volume of CBCT images to ensure they do not overlook paranasal sinus pathoses.

**Keywords:** Cone-beam computed tomography; paranasal sinuses; maxillofacial region; sinusitis

#### ÖZ

**Amaç:** Bu çalışmanın amacı yetişkin popülasyonda konik ışınli bilgisayarlı tomografide belirlenen paranasal sinus patolojilerini incelemektir. **Bireyler ve Yöntem:** Ağız, Diş ve Çene Radyolojisi kliniğinde 353 hastadan alınan konik ışınli bilgisayarlı tomografi kesitleri üç gözlemci tarafından paranasal sinus patolojilerini belirlemesi amacıyla incelendi. Tanımlayıcı istatistik ve ki-kare testi kategorik parametrelerin prevalansının belirlenmesi için kullanıldı. **Bulgular:** Hastaların yaş aralığı 18-85 iken, yaş ortalaması 41,27±16,76'dı. Çalışmada 172 kadın (%48,7) ve 181 (%51,3) erkek hasta vardı. Erkeklerde (%53,5) kadınlardan (%46,5) daha fazla sinüs patolojisi belirlendi ve cinsiyetler arasında önemli farklılık vardı ( $p=0.02$ ). Sağ ve sol sinüsler birlikte değerlendirildiğinde patolojiler en sık maksiller sinüste (% 57,1) görüldü, maksiller sinüsü ethmoid (%53,7), frontal (%22,6), ve sfenoid sinüsler (%15,8) izledi. Mukozal kalınlaşma (%51,7) en sık gözlenen patolojiydi, mukozal kalınlaşmayı hipoplazi (%17,5), sinüzit (%17,3) izledi. **Sonuç:** Konik Işınli Bilgisayarlı Tomografi paranasal sinüslerin değerlendirilmesi için tercih edilebilir bir görüntüleme yöntemidir. Ağız, diş ve çene radyolojisi uzmanları paranasal sinüs patolojilerini gözden kaçırmamak için konik ışınli bilgisayarlı tomografi kesitlerinin tamamını incelemelidir.

**Anahtar kelimeler:** Konik ışınli bilgisayarlı tomografi; paranasal sinüsler; maksillofasial bölge; sinüzit



## **Introduction**

The paranasal sinuses are air-filled spaces lined with soft, pink mucosa located within the bones of the skull and face. The mucosa lining the sinuses makes mucus that is cleared out of the sinus cavities and drains into the nasal passage. Normally, the sinuses are empty except for a thin layer of mucus (1). The paranasal sinuses are the four paired sets of air-filled cavities of the craniofacial complex composed of maxillary, frontal, and sphenoid sinuses and ethmoid air cells (2). The location of chronic sinusitis symptoms, such as facial congestion/fullness, facial pain, headache, and dental pain, may vary from the maxilla and maxillary teeth in maxillary sinusitis to the upper orbit and frontal process in frontal sinusitis, between and behind the eyes in ethmoid sinusitis, and at the junction of the hard and soft palate, occiput, and mastoid process in sphenoid sinusitis. However, the most common extraoral source of dental pain arises from the maxillary sinuses because of their proximity to the teeth and their associated structures (3). Hence, dentists should be aware of pathoses of the sinuses.

Part or all of the paranasal sinuses may appear on radiographs made for dental purposes, such as panoramic radiographs and cone beam computerized tomography (CBCT) (2). The multiplanar images acquired by CBCT provide precise three-dimensional (3D) visualization of dental and maxillofacial structures at a lower radiation dose than multislice computed tomography (CT). In contrast to traditional two-dimensional radiography, structural superimposition or image enlargement and distortion does not occur in CBCT. CBCT also enables mapping and acquisition of valuable information at different levels (4, 5). Thus, CBCT can be used by dentists and otolaryngologists to assess paranasal sinuses. Previous studies (6-10) reported frequently maxillary sinus pathoses in CBCT scans in patients referred for different oral and dental diagnostic purposes. However, all the sinus regions have not been evaluated in the same studies. The aim of this study was to investigate the prevalence, site, and type of pathoses in paranasal sinuses seen on CBCT and to assess the relationships of such pathoses with age, gender, and season (winter/spring/summer/fall).

## **Patients and Methods**

This retrospective study included CBCT images of 353 consecutive patients who were 18 years or older

and referred for different oral and dental diagnostic purposes. Among the 353 CBCT exams, 171 (48.6%) were from females and 181 (51.1%) from male patients. The patient's age range was 18–85 years, with a median age of 41.27±16.76. CBCT sections of patients came to clinic for routine examinations were used. Informed consent was taken from patients for CBCT imaging. For this study, radiation was not given to any patient. For statistical analysis, the patients were separated into the following age groups: 0–18, 19–25, 26–40, 41–60, and >60 years. The indications for CBCT examinations were implant planning or oral surgery procedure planning (removal of impacted third molars), a suspected tumor or cyst, intraosseous impaction of a foreign body, an oro-antral fistula, orthodontic planning, trauma, and fractures. For CBCT scanning, a Promax 3D® Mid CBCT device (Planmeca Oy, Helsinki, Finland) using a medium FOV (16 cm, 16 cm with stitching, voxel size 400µm) was used. The tube voltage was 90 KVp, tube current was 10 mA, and an exposure time of 13.7 seconds was used. Three oral and maxillofacial radiologists independently evaluated the presence of anatomic variations and lesions of the paranasal sinuses in the CBCT images. Each observer analyzed one-third of the datasets. Observers were calibrated by using five example images for each finding. Calibration of the observers took place in a group, and each finding was discussed. Romexis Viewer (Planmeca Oy, Helsinki, Finland) software was used to evaluate the resulting images in axial, coronal, and sagittal sections. Paranasal sinus pathoses evaluated in the present study were classified as shown in Table 1.

## *Statistical Analysis*

The descriptive statistics are presented as frequencies, and the corresponding 95% confidence intervals (CIs) were also calculated. Chi-square test were used to determine the prevalence of categorical parameters. Statistical analyses were performed by using SPSS for Windows software version 17.0 (SPSS Inc., Chicago, IL, USA). The level of significance was set at 0.05.

## **Results**

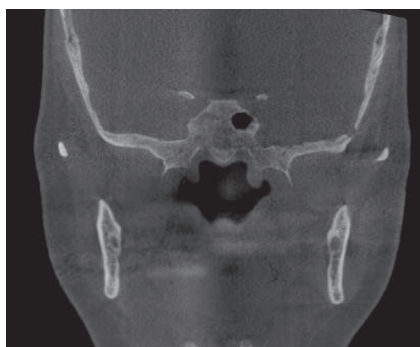In total, 312 (88.4%) patients had paranasal sinus pathoses. More sinus pathoses (38.1%) were found in patients aged 41–60 years. There was no significant difference between the age groups ( $p=0.17$ ). When

the left and right sinuses were considered together, pathoses were most commonly seen in the maxillary sinuses (57.1%), followed by the ethmoid (53.7%), frontal (22.6%), and sphenoid sinuses (15.8%). However, it was determined teeth in the maxillary sinuses of 19 patients (10 in the right maxillary sinus

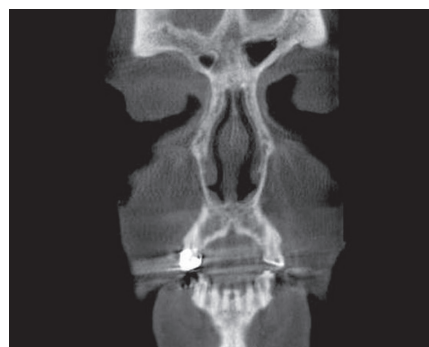
and 9 in the left maxillary sinus). Mucosal thickening was the most frequently observed pathoses (51.7%), followed by hypoplasia (17.5%) and sinusitis (17.3%). Hypoplasia was seen in the frontal sinuses more often than in the other sinuses (Table 2).

**Table 1.** Classification and definitions of paranasal sinus pathoses.

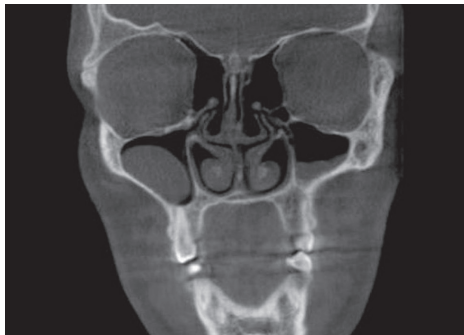Abnormality	Definition
Aplasia (Fig. 1)	The lack of pneumatization in the expected locations of paranasal sinus.
Hypoplasia (Fig. 2)	Underdevelopment or incomplete development of paranasal sinus.
Mucosal thickening (Mucositis) (Fig. 3)	Increase in thickness of the mucosal lining of the paranasal sinuses
Sinusitis (Fig. 4)	Generalized inflammation of the paranasal sinus mucosa
Polypoid lesions (a mucous retention cyst and/or antrochoanal polyp) (Fig. 3)	The thickened mucous membrane of a chronically inflamed sinus frequently forms into irregular folds called polyps. Mucous retention cysts are a result of enlargement of a mucous gland caused by blockage of a mucous gland duct in the floor of sinus.
Antrolith (Fig. 5)	Deposition of mineral salts, such as calcium phosphate, calcium carbonate, and magnesium around a nidus, which may be introduced into the sinus (extrinsic) or could be intrinsic, such as masses of stagnant mucous at sites of previous inflammation.
Oroantral fistula (Fig. 6)	A pathological communication between the oral cavity and the maxillary sinus.
Osteoma (Fig. 7)	A benign slow growing osteogenic lesion, characterized by the proliferation of compact or cancellous bone
Periostitis (Fig. 8)	Exudate from dental inflammatory lesions strip and elevate the periosteal lining of the cortical bone of the floor of the maxillary antrum, stimulating the periosteum to produce a thin elevated layer of new bone adjacent to the root apex of the involved tooth.
Benign odontogenic cysts and tumors (Fig. 9)	Odontogenic cysts are the most common group of extrinsic lesions that encroach on the maxillary sinuses.



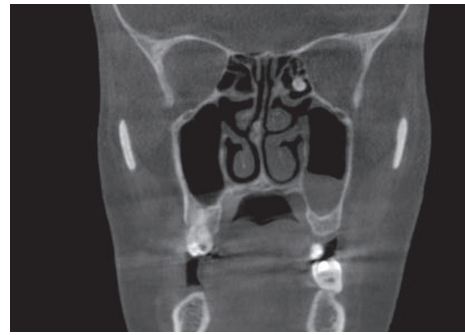
**Figure 1.** Aplasia of right sphenoid sinus.



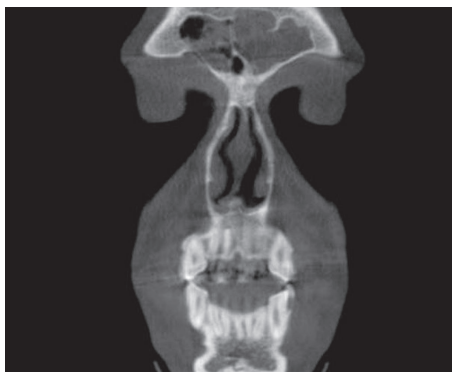**Figure 2.** Hypoplasia of right frontal sinus.



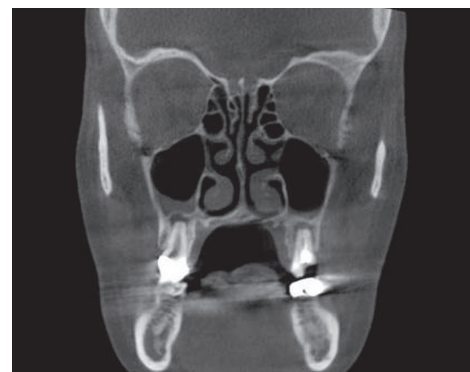**Figure 3.** Mucosal thickening on left maxillary sinus and mucous retention cyst on right maxillary sinus.



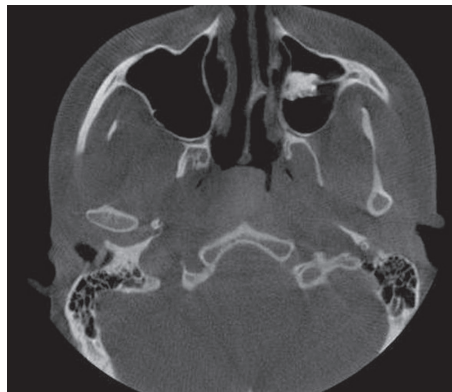
**Figure 7.** Osteoma on left ethmoid sinus.



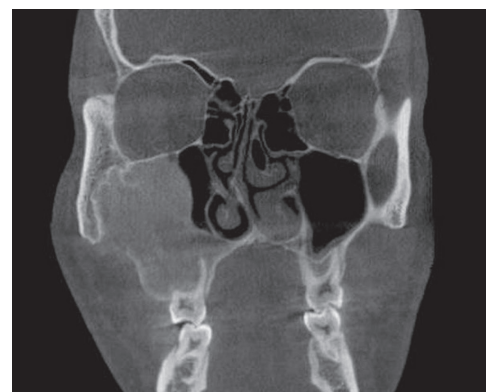
**Figure 4.** Sinusitis on frontal sinus.



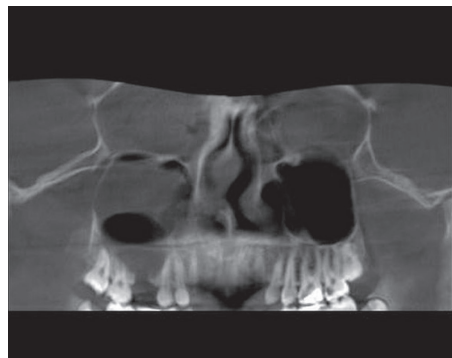
**Figure 8.** Periostitis on right maxillary sinus.



**Figure 5.** Antrolith on left maxillary sinus.



**Figure 9.** Benign odontogenic cyst on right maxillary sinus.



**Figure 6.** Oroantral fistula on right maxillary sinus.

Pathoses were observed bilaterally in 42.4% of maxillary sinuses, 16.9% of frontal sinuses, 48.3% of ethmoid sinuses, and 7.3% of sphenoid sinuses. Thirty-six (10.1%) patients in maxillary sinuses and 109 (30.8 %) patients in ethmoid sinuses had mucosal thickening. Seven patients had sinusitis of the maxillary sinuses, and forty four patients had sinusitis of the ethmoid sinuses.

There was a significant difference between the genders ( $p=0.02$ ), with males (53.5%) having more sinus pathoses than females (46.5%). When the incidence of pathoses was evaluated according to



CBCT scanners allow users to select the field of view (FOV) to minimize the radiation dose to patients. Therefore, an optimum FOV can be selected for each patient based on suspected disease presentation and region of interest. FOV or selected scan volume height can be categorized as follows: Localized region: approximately 5 cm or less (eg, dentoalveolar, temporomandibular joint) Single arch: 5 cm to 7 cm (eg, maxilla or mandible) Interarch: 7 cm to 10 cm (eg, mandible and superiorly to include the inferior concha) Maxillofacial: 10 cm to 15 cm (eg, mandible and extending to nasion) Craniofacial: greater than 15 cm (eg, from the lower border of the mandible to the vertex of the head) (2, 13). In this study, CBCT images with FOV greater than 15 cm (eg, from the lower border of the mandible to the vertex of the head) was evaluated, because all of paranasal sinuses cannot be observed in the other scan volume heights.

The percentage of patients with incidental findings in paranasal sinuses varied between 26.7% and 60.5% in studies that used CBCT (11-14). This prevalence varied from 24.7% to 64.8% in studies that employed different diagnostic techniques, such as CT or magnetic resonance imaging (15-20). In the present study, the percentage of paranasal sinus pathoses was 88.4%, which is greater than that reported in the above-mentioned studies. The difference in the prevalence found in this study compared with the existing literature may partly be explained by the use of different definitions and classifications of the pathological changes observed or the lack of a clear and unambiguous definition of pathoses in the paranasal sinuses. Different ages and the make-up of the patient groups may also explain the discord among studies. For instance, in some studies, the authors selected a different a cut-off value for "mucosal thickening." The researchers have chosen a cut-off value of >2 mm (21, 22), >3 mm (7, 23), ≥4 mm (24) in asymptomatic patients, ≥5 mm (19, 25) and >6 mm (26). Mucosal thickening is seen both in acute and chronic sinusitis and a mucosal thickening >3 mm is usually considered as a pathological condition (2). Thus, a cut-off value of ≥ 3 mm was chosen in all the paranasal sinuses evaluated in the present study.

Sinus pathoses were more frequent in males than in females in the current study ( $p < 0.05$ ). This finding is similar to that reported by some studies that evaluated paranasal sinuses (15, 19) or only maxillary sinuses (5, 9, 10, 27). Other studies (5, 10) reported a higher prevalence of sinus pathoses, especially in the maxillary sinuses, in older individuals. In the present

study, the patients aged 41–60 years also had more sinus pathoses. However, in accordance with that reported by Rege *et al.* (9), we found no significant difference between age groups ( $p = 0.17$ ). Contrary to the study of Tarp *et al.* (19), we did not find a positive correlation between the seasons and the incidence of pathoses. Although there were more pathoses detected in the winter period (36.8%), this finding was not statistically significant in the current study. Increased numbers of infections in the cold and wet season explain the number of pathoses. Conversely, the lowest incidence of pathoses was detected in the summer (9%). The incidence of pathoses in the spring (27.7%) and fall (26.5%) was close to that in the winter. This may be due to the inclusion of patients with an allergy to pollen, with high pollen counts in the spring and fall.

Similar to the present study, the most common finding in other research on paranasal sinuses was sinusitis or mucosal thickening (11, 12, 14). The incidence of mucosal thickening on CBCT varied from 14.2% to 55.1% in previous studies (11, 12, 14) that evaluated all the paranasal sinuses. In the present study, mucosal thickening was detected in 51.7% of the sinuses. However, the prevalence of mucosal thickening in maxillary sinuses was 24%. This is within the prevalence range reported for mucosal thickening in other studies where it varied from 7.5% to 38.1% (5-8, 10, 28). There is no consensus in the literature on the amount of mucosal thickening that is considered abnormal, with measurements ranging from 2 to 6 mm (7, 19, 21, 22, 24-26). We used a measurement of 3 mm. This could be the cause of the high prevalence of mucosal thickening in the present study.

In accordance with that reported by Jones *et al.* (29), the maxillary sinus was the most commonly affected sinus in the current study, followed by the ethmoid, frontal, and sphenoid sinuses. Maxillary sinuses could be more affected because of pathologies of odontogenic origin, such as periapical lesions, due to their proximity to the roots and the floor of the sinus. A number of studies reported that odontogenic pathologies may be an etiological factor in cases of maxillary sinusitis (30-33).

## Conclusion

Paranasal sinus pathoses were common incidental findings in CBCT of the maxillofacial area required for different dental diagnostic purposes. Because

of the high incidence of collateral pathologies and incidental findings, dentomaxillofacial radiologists should examine the whole volume of CBCT images to avoid under- or overestimation of a potential pathology and ensure a comprehensive evaluation of the possibility of underlying diseases.

Clinically, when paranasal sinus pathoses are discovered on CBCT images, patient should be referred to an otolaryngologist. In addition, dentists should not overlook sinus diseases as the cause of dental and facial pain.

#### Source of funding

None declared

#### Conflict of interest

None declared

#### References

- Porter RS, Kaplan JL. The Merck Manual. 19th ed. United State, Green. 2011.
- White SC, Pharoah MJ. Oral radiology: principles and interpretation. 6th ed. New Delhi, Mosby. 2009.
- Ingle JI, Bakland LK. Endodontics. 5th ed. Canada, BC Decker Inc. 2002.
- Donizeth-Rodrigues C, Fonseca-Da Silveira M, Goncalves-De Alencar AH, Garcia-Santos-Silva MA, Francisco-De-Mendonca E, Estrela C. Three-dimensional images contribute to the diagnosis of mucous retention cyst in maxillary sinus. *Med Oral Patol Oral Cir Bucal* 2013;18(1):e151-157.
- Gracco A, Incerti Parenti S, Ioele C, Alessandri Bonetti G, Stellini E. Prevalence of incidental maxillary sinus findings in italian orthodontic patients: A retrospective cone-beam computed tomography study. *Korean J Orthod* 2012;42(6):329-334.
- Caglayan F, Tozoglu U. Incidental findings in the maxillofacial region detected by cone beam ct. *Diagn Interv Radiol* 2012;18(2):159-163.
- Cha JY, Mah J, Sinclair P. Incidental findings in the maxillofacial area with 3-dimensional cone-beam imaging. *Am J Orthod Dentofacial Orthop* 2007;132(1):7-14.
- Pazera P, Bornstein MM, Pazera A, Sendi P, Katsaros C. Incidental maxillary sinus findings in orthodontic patients: A radiographic analysis using cone-beam computed tomography (cbct). *Orthod Craniofac Res* 2011;14(1):17-24.
- Rege IC, Sousa TO, Leles CR, Mendonca EF. Occurrence of maxillary sinus abnormalities detected by cone beam ct in asymptomatic patients. *BMC Oral Health* 2012;10:12-30.
- Ritter L, Lutz J, Neugebauer J, Scheer M, Dreiseidler T, Zinser MJ, Rothamel D, Mischkowski RA. Prevalence of pathologic findings in the maxillary sinus in cone-beam computerized tomography. *Oral Surg Oral Med Oral Pathol Oral Radiol Endod* 2011;111(5):634-640.
- Price JB, Thaw KL, Tyndall DA, Ludlow JB, Padilla RJ. Incidental findings from cone beam computed tomography of the maxillofacial region: a descriptive retrospective study. *Clin Oral Implants Res* 2012;23(11):1261-1268.
- Allareddy V, Vincent SD, Hellstein JW, Qian F, Smoker WR, Ruprecht A. Incidental findings on cone beam computed tomography images. *Int J Dent* 2012;2012:871532.
- Scarfè WC FA. What is cone-beam ct and how does it work? *Dent Clin N Am* 2008;52(707-730).
- Rheem S NIL, Oberoi S. Incidental findings in the maxillofacial region identified on cone-beam computed tomography scans. *Journal of Orthodontic Research* 2013;1(1):33-39.
- Havas TE, Motbey JA, Gullane PJ. Prevalence of incidental abnormalities on computed tomographic scans of the paranasal sinuses. *Arch Otolaryngol Head Neck Surg* 1988;114(8):856-859.
- Maly PV, Sundgren PC. Changes in paranasal sinus abnormalities found incidentally on mri. *Neuroradiology* 1995;37(6):471-474.
- Moser FG, Panush D, Rubin JS, Honigsberg RM, Sprayregen S, Eisig SB. Incidental paranasal sinus abnormalities on mri of the brain. *Clin Radiol* 1991;43(4):252-254.
- Porter MJ CH, Ambrose R, Leung SF, van Hasselt CA. Pathoses of the paranasal sinuses in patients with nasopharyngeal carcinoma: A computed tomographic study. *J Laryngol Otol* 1996;110(1):23-26.
- Tarp B, Fiirgaard B, Christensen T, Jensen JJ, Black FT. The prevalence and significance of incidental paranasal sinus abnormalities on mri. *Rhinology* 2000;38(1):33-38.
- Wani MK, Ruckenstein MJ, Parikh S. Magnetic resonance imaging of the paranasal sinuses: Incidental abnormalities and their relationship to

- patient symptoms. *J Otolaryngol* 2001;30(5):257-262.
21. Maillet M, Bowles WR, McClanahan SL, John MT, Ahmad M. Cone-beam computed tomography evaluation of maxillary sinusitis. *J Endod* 2011;37(6):753-757.
  22. Patel K, Chavda SV, Violaris N, Pahor AL. Incidental paranasal sinus inflammatory changes in a british population. *J Laryngol Otol* 1996;110(7):649-651.
  23. Gordts F, Clement PA, Buisseret T. Prevalence of sinusitis signs in a non-ent population. *ORL J Otorhinolaryngol Relat Spec* 1996;58(6):315-319.
  24. Rak KM, Newell JD, 2nd, Yakes WF, Damiano MA, Luethke JM. Paranasal sinuses on mr images of the brain: Significance of mucosal thickening. *AJR Am J Roentgenol* 1991;156(2):381-384.
  25. Lindbaek M, Johnsen UL, Kaastad E, Dolvik S, Moll P, Laerum E, Hjortdahl P. Ct findings in general practice patients with suspected acute sinusitis. *Acta Radiol* 1996;37(5):708-713.
  26. Katz RM, Friedman S, Diament M, Siegel SC, Rachelefsky GS, Spector SL, Rohr AS, Schoettler J, Dorris A. A comparison of imaging techniques in patients with chronic sinusitis (x-ray, mri, a-mode ultrasound). *Allergy Proc* 1995;16(3):123-127.
  27. Vallo J, Suominen-Taipale L, Huuonen S, Soikkonen K, Norblad A. Prevalence of mucosal abnormalities of the maxillary sinus and their relationship to dental disease in panoramic radiography: Results from the health 2000 health examination survey. *Oral Surg Oral Med Oral Pathol Oral Radiol Endod* 2010;109(3):e80-87.
  28. Drage N, Rogers S, Greenall C, Playle R. Incidental findings on cone beam computed tomography in orthodontic patients. *J Orthod* 2013;40(1):29-37.
  29. Jones NS. Ct of the paranasal sinuses: A review of the correlation with clinical, surgical and histopathological findings. *Clin Otolaryngol Allied Sci* 2002;27(1):11-17.
  30. Bomeli SR, Branstetter BFt, Ferguson BJ. Frequency of a dental source for acute maxillary sinusitis. *Laryngoscope* 2009;119(3):580-584.
  31. Mehra P, Jeong D. Maxillary sinusitis of odontogenic origin. *Curr Allergy Asthma Rep* 2009;9(3):238-243.
  32. Obayashi N, Arijii Y, Goto M, Izumi M, Naitoh M, Kurita K, Shimosato K, Arijii E. Spread of odontogenic infection originating in the maxillary teeth: Computerized tomographic assessment. *Oral Surg Oral Med Oral Pathol Oral Radiol Endod* 2004;98(2):223-231.
  33. Pokorny A, Tataryn R. Clinical and radiologic findings in a case series of maxillary sinusitis of dental origin. *Int Forum Allergy Rhinol* 2013;3(12):973-979.

**Corresponding Author:****Esin BOZDEMİR**

Department of Dentomaxillofacial Radiology  
 Faculty of Dentistry Süleyman Demirel University  
 32200-Çünür Isparta / TURKEY  
 Phone: +90 246 211 32 54  
 e-mail: dtesin@hotmail.com