

Neuroplastic Surgery Aboard USNS Comfort During the COVID-19 Pandemic in New York City

Gabriel F. Santiago, MD,* Danielle C. Anderson, DO,* and Scott L. Zuckerman, MD, MPH^{†‡}

Abstract: In December of 2019, a novel virus known as severe acute respiratory syndrome coronavirus 2 (SARS-CoV-2) produced a cluster of viral pneumonia cases in Wuhan, China. In the United States (US), New York City was particularly devastated, with the volume and acuity of patients placing an unprecedented strain on the hospital system and health care workers. In response to this crisis, USNS Comfort (T-AH 20) was deployed to New York City with a 1100 member medical team to augment local hospitals. Comfort's mission to New York City was dynamic, and required special adaptation to care for both COVID positive and COVID negative patients. Neuroplastic surgery procedures were indicated in both COVID positive and COVID negative patients, and lessons learned with regard to performance of complex surgery in an unfamiliar environment consisted of developing a thorough understanding of ones capabilities, and working with a highly skilled team of Navy surgeons, anesthesiologists, and surgical support staff, in order to provide high quality care in a deployment platform.

Key Words: Craniectomy, cranioplasty, neuroplastic surgery, sacroiliitis, USNS Comfort

In December of 2019, a novel virus known as severe acute respiratory syndrome coronavirus 2 (SARS-CoV-2) produced a cluster of viral pneumonia cases in Wuhan, China.^{1,2} Due to its efficient and sustainable transmissibility, the virus spread rapidly

From the *Department of Otolaryngology, Naval Medical Center Portsmouth, Portsmouth, VA; †Department of Neurological Surgery, Vanderbilt University Medical Center, Nashville, TN; and ‡Department of Orthopaedic Surgery, Columbia University Medical Center, New York, NY.

Received June 12, 2020.

Accepted for publication June 22, 2020.

Address correspondence and reprint requests to Gabriel F. Santiago, MD, LCDR, USN, Division Chief Neuroplastic and Reconstructive Surgery, Department of Otolaryngology, Naval Medical Center Portsmouth Assistant Professor in Surgery F. Edward Hebert School of Medicine Uniformed Services University of the Health Sciences, 620 John Paul Jones Circle, Portsmouth, VA 23708; E-mail: GabrielFSantiago@gmail.com

We are military service members. This work was prepared as part of our official duties. Title 17 U.S.C. 105 provides that "Copyright protection under this title is not available for any work of the United States Government." Title 17 U.S.C. 101 defines a United States Government work as a work prepared by a military service member or employee of the United States Government as part of that person's official duties.

The views expressed in this article reflect the results of research conducted by the authors and do not necessarily reflect the official policy or position of the Department of the Navy, Department of Defense, or the United States Government.

The authors report no conflicts of interest.
Copyright © 2020 by Mutaz B. Habal, MD
ISSN: 1049-2275
DOI: 10.1097/SCS.0000000000006886

amongst the population and to other countries, becoming a Public Health Emergency of International Concern by January 30th, 2020.³ Six weeks later, the World Health Organization declared the outbreak of coronavirus disease 2019 (COVID-19) a pandemic, as cases and fatalities surged globally.⁴

In the United States (US), New York City was particularly devastated. Within weeks, the burgeoning volume and acuity of patients placed an unprecedented strain on hospital systems and health care workers.⁵ With more than 60,000 people infected in New York State and 775 fatal cases, medical facility and supply shortages, provider fatigue, and compounding stress threatened the city's healthcare infrastructure.⁶ In response to this crisis, USNS Comfort (T-AH 20) was deployed to New York City with a 1100 member medical team to augment local hospitals.

Comfort arrived at Pier 90 in Manhattan on March 30th, and over a 30-day period treated a total of 182 patients⁷ (Fig. 1). The hospital ship has similar capabilities to land-based hospitals in the US with 1000 beds, 50 intensive care unit (ICU) beds, 10 operating rooms, and a 64-slice computed tomographic (CT) scanner, supporting a wide range of medical and surgical capabilities. The initial mission of Comfort was to treat non-COVID patients who were in need of urgent care; however, unanticipated circumstances dictated a change in the mission to treat both COVID-positive and COVID-negative patients.

Extensive craniofacial reconstruction has been an important capability of Comfort as was seen during Operation Unified Response in January 2010.⁸ In this mission to Haiti, following a devastating 7.0 magnitude earthquake, 35 patients underwent 95 craniofacial surgical procedures by the craniofacial service. Despite the unpredictable challenges intrinsic to a natural disaster response in a low-income country, the surgical team achieved remarkable outcomes in these cases.⁸



FIGURE 1. USNS Comfort Docked Pier side upon arrival in New York City.

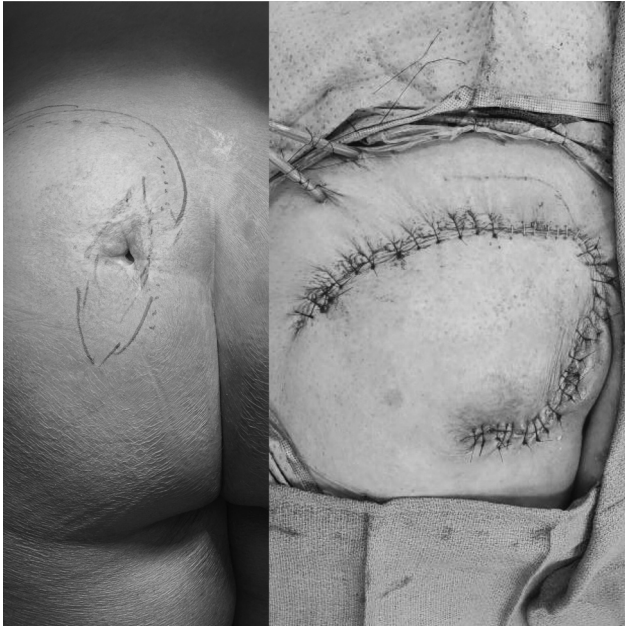

FIGURE 2. Pre- and Post-operative appearance of patient with sacral osteomyelitis requiring rotational flap.

Aboard Comfort was a full complement of surgeons consisting of orthopedic, vascular, general, oral-maxillofacial, cardiothoracic, neurosurgery, and an otolaryngologist—neuroplastic surgeon. Of the 52 surgical cases performed on board, 2 cases required collaboration between the neurosurgeon and neuroplastic surgeon and included a patient with sacral osteomyelitis and cutaneous fistula requiring local flap closure, and a cranioplasty.

CASE DESCRIPTIONS

Case 1

Briefly, the first case involved a 66-year-old female with history of sacral osteomyelitis leading to a cutaneous fistula for 2 to 3 months before admission. During this patient's shore based hospitalization for this wound, she tested positive for SARS-CoV-2 but had no respiratory symptoms. The patient was transferred to the ship for definitive treatment as this type of elective case was not able to be accomplished at the shore-based hospital at the time. After being on intravenous antibiotics for 5 weeks (meropenem and vancomycin), the wound had failed to heal and continued draining fluid. Though the patient's white blood cell count was normal, she did have low grade fevers during her admission. Due to the continued draining wound and persistent fevers, it was determined that a debridement, irrigation and definitive closure was indicated. The patient was ambulatory and had no mechanical pain despite the wound, and in the absence of obvious lumbosacral deformity, lumbopelvic fixation was not required. During surgery, the ulcer was ellipsed out, the right lateral sacrum, medial ilium, posterior inferior iliac spine (PSIS), and sacroiliac joint (SIJ) were debrided and irrigated to remove any active infection, and closure was accomplished with an inferior gluteal artery based fasciocutaneous flap (Fig. 2). Post-operatively, the wound healed, fevers resolved, and the patient began ambulating well. She was discharged on postoperative day 7 and sutures removed at post-operative day 21.

Case 2

The second patient requiring neuroplastic surgery care was a 55-year-old male with a history of hypertension, hyperlipidemia, and

diabetes who suffered a large right hemispheric stroke and underwent a right hemicraniectomy by a neurosurgical team at Bellevue Hospital (New York, NY). Because of his continued need for ventilation, the patient was transferred to Comfort so the ventilator could be used on a critically-ill COVID patient in need.

Comfort Admission

On post-craniectomy day 4, the patient was transferred to Comfort for further definitive care. While on board, the patient received physical therapy, local wound care to the scalp, as well as a tracheostomy due to an inability to protect his airway secondary to neurologic dysfunction, and to assist with secretion management. He was successfully weaned off the ventilator within 2 days of tracheostomy, and was placed on humidified room air during his ICU stay. After cessation of all sedation, the patient's serial neurologic exams showed improvement to the point where he was opening eyes spontaneously and following commands to toe wiggle in his right lower extremity. His post-stroke left sided hemiparesis remained stable throughout his stay. During his admission, serial head CT scans demonstrated resolution of cerebral edema to the point where the scalp flap began to sink. The patient's neurologic function remained stable, to where he consistently followed commands in his right lower extremity with improving alertness throughout the day. On postcraniectomy day 21, the patient's exam remained stable, his flap was sunken, and a final CT showed right hemispheric atrophy with increased cerebrospinal fluid (CSF) volume filling this space. At this time, the neurosurgeon (SZ) and neuroplastic surgeon (GS) discussed the possibility of performing a cranioplasty to reestablish brain protection and optimize the patient's CSF fluid dynamics, both of which have been demonstrated with *in vitro* and *in vivo* studies in post-cranioplasty patients.⁹⁻¹⁵

Surgical Case Preparation

As compared to land-based hospital, there are unique challenges that presented themselves with regard to performing complex reconstructive surgery on a hospital ship. One of these challenges is the fact that all members of the surgical team work primarily at other land-based hospitals. While preferences among surgeons can typically be accommodated for at most institutions, surgeons aboard Comfort neither had the opportunity to request their own surgical sets, nor were they fully aware of the equipment we had onboard for our respective specialties. As part of the preparation process for the mission, both the neurosurgeon and neuroplastic surgeon inspected their respective surgery sets and re-organized them while at sea on route to New York City. After a full inventory was taken, certain equipment was found to be available to perform cases, but some items were outdated or required modification to fit our needs. For example, an older high-speed drill used mostly for dental procedures could be used to make burr holes and osteotomies. Cranial plates were available; however, items such as mesh were only supplied in small sizes. While we had the ability to repair small cranial defects with such plates, larger operations, such as a cranioplasty, were not possible. Thus, a supply request was given to the ship supply chain, and 10 days later, a high-speed drill, along with other non-neuro related surgical equipment, was transported to the ship.

Compared to the humanitarian missions USNS Comfort typically responds to, in this situation, we were not responding to a resource poor nation, and therefore we felt that a surgical procedure should not be attempted onboard unless we had the ability to provide the same standard of care as the patient would otherwise have received on shore.

Once all surgeons, nurses, and surgical technicians felt the necessary equipment was available to safely perform the

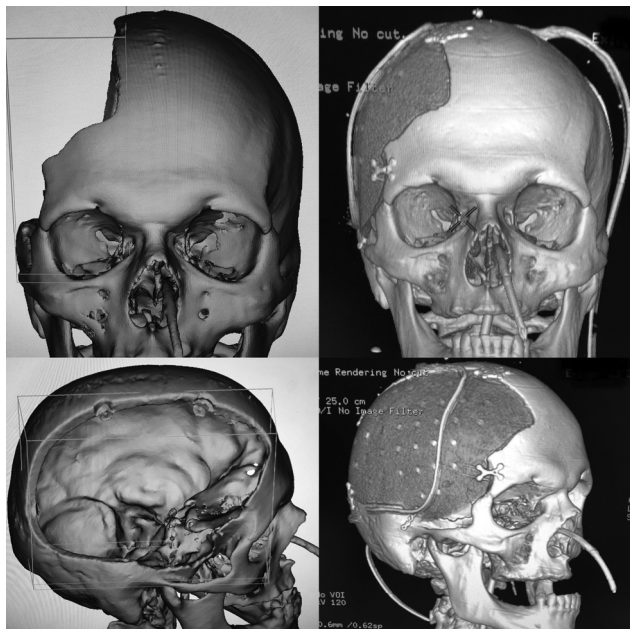


FIGURE 3. Pre- and post-operative 3D computed tomographic scans of hemi-craniectomy patient who underwent cranioplasty with customized cranial implant.

cranioplasty, we communicated with civilian medical supply representatives to manufacture and deliver of a customized cranial implant. The patient's most recent fine-cut was uploaded to the manufacturer's website. Virtual-surgical planning was done with the surgery team via video-teleconference in order to design our patient's right hemispheric polyether ether ketone (PEEK) cranial implant (Fig. 3). On post-craniectomy day 24, after the implant and all surgical equipment were obtained, a right cranioplasty was performed. The PEEK cranial implant was designed, and surgery proceeded as previously described by Gordon et al.^{16,17}

Surgical Case Description

The patient was positioned on a Mayfield horseshoe headrest, the head was shaved with clippers and the surgical prep was performed by the neuroplastic surgeon (GS). To hydrodissect the entire scalp off the underlying skull, 40 ml of tumescent lidocaine solution with epinephrine was used. The scalp was reopened with a combination of a knife and needle-tip bovie cautery to minimize blood loss. Some areas along the incision line required debridement to obtain fresh skin edges. The scalp was elevated in the subgaleal plane using the previously described pericranial-onlay technique.¹⁷ Since the initial surgery occurred only 3 weeks before cranioplasty, the pericranium had not fully healed to the dura. As a result, some dura was elevated with the scalp flap, which exposed 2 small areas of the cerebral cortex. To ensure a water-tight closure, hydrodissection with tumescent solution was injected in the deep aspect of the scalp in order to increase the ease of dissection. The 2 areas of dural violation were repaired with 4–0 neuroton sutures, and the dissected dural-pericranial flap. After all edges of the cranial defect were exposed, the custom cranial implant was brought in to make sure an appropriate fit was obtained and care was taken to ensure no gaps were present at the frontal and temporal areas of the implant-skull interface.

After the implant was secured, the wound was copiously irrigated. Two subgaleal drains were placed, the skin was closed with 3–0 nylon sutures and a head-wrap was applied.

Post-operative Course

Post-operatively, the patient's exam remained stable, opening eyes spontaneously and following commands consistently in his right lower extremity. A post-operative CT scan was obtained immediately after surgery (Fig. 3), and he was monitored in the ICU for 2 days. On POD2, his drains were removed, deep vein thrombosis (DVT) prophylaxis was started, and he was transferred to a local hospital on POD4 for recovery as the ship was set to depart New York City.

DISCUSSION

The circumstances of Comfort's mission to New York City were unique with regard to the type of humanitarian disaster the ship is typically called to respond to, and the need to mitigate the spread of a highly communicable disease onboard a ship with tight quarters. Mitigation of spread of SARS-CoV-2 from COVID+ to COVID– patients was accomplished by re-engineering air-circulation, and isolation of COVID+ wards from the rest of the ship. As a result, our cranioplasty patient remained COVID free (as confirmed by 5 negative SARS-CoV-2 PCR tests) over his 3-week admission. Second, mitigation of spread of SARS-CoV-2 from our COVID+ patient requiring sacral debridement by the neuroplastic surgery team was accomplished by requiring the patient to be masked with an N95 respirator when being transferred outside the COVID+ ward to the operating room, and use of rapid sequence induction anesthesia for intubation. Additionally, the authors utilized N95 respirators when rounding on all COVID+ patients. Lastly, while not typically available on Comfort missions, the ability to obtain a 3D printed custom cranial implant aboard allowed us to maximize our patient's treatment regimen. As a result, one might consider obtaining a 3D printer and implant design software for future humanitarian missions, which would allow surgeons to supply their own materials when the ability to resupply from shore is limited.

CONCLUSION

Comfort's mission to New York City was dynamic, and required special adaptation to care for both COVID positive and COVID negative patients. Neuroplastic surgery procedures were indicated in both COVID positive and COVID negative patients. Lessons learned with regard to performance of complex surgery in an unfamiliar environment consisted of developing a thorough understanding of one's capabilities, and working with a highly skilled team of Navy surgeons, anesthesiologists, and surgical support staff, to provide high quality care in a deployment platform.

REFERENCES

- Huang C, Wang Y, Li X, et al. Clinical features of patients infected with 2019 novel coronavirus in Wuhan, China. *Lancet* 2020;395:497–506
- Naming the coronavirus disease (COVID-19) and the virus that causes it. *World Health Organization (WHO)*. [https://www.who.int/emergencies/diseases/novel-coronavirus-2019/technical-guidance/naming-the-coronavirus-disease-\(covid-2019\)-and-the-virus-that-causes-it](https://www.who.int/emergencies/diseases/novel-coronavirus-2019/technical-guidance/naming-the-coronavirus-disease-(covid-2019)-and-the-virus-that-causes-it) Accessed 21 May 2020
- Statement on the second meeting of the International Health Regulations (2005) Emergency Committee regarding the outbreak of novel coronavirus (2019-nCoV). *World Health Organization (WHO)*. [https://www.who.int/news-room/detail/30-01-2020-statement-on-the-second-meeting-of-the-international-health-regulations-\(2005\)-emergency-committee-regarding-the-outbreak-of-novel-coronavirus-\(2019-ncov\)](https://www.who.int/news-room/detail/30-01-2020-statement-on-the-second-meeting-of-the-international-health-regulations-(2005)-emergency-committee-regarding-the-outbreak-of-novel-coronavirus-(2019-ncov)) 30 January 2020.
- WHO Director-General's opening remarks at the media briefing on COVID-19—11 March 2020. *World Health Organization*. <https://www.who.int/dg/speeches/detail/who-director-general-s-opening-remarks-at-the-media-briefing-on-covid-19—11-march-2020> 11 March 2020.

5. Flores S, Gavin N, Romney ML, et al. COVID-19: New York City pandemic notes from the first 30 days. *Am J Emerg Med* 2020;S0735-6757:30283–30287[published online ahead of print, 2020 Apr 21]
6. Chappell, Bill. Hospital Ship USNS Comfort Arrives in New York to Ease Coronavirus Pressure. National Public Radio. <https://www.npr.org/sections/coronavirus-live-updates/2020/03/30/823826987/hospital-ship-usns-comfort-arrives-in-new-york-to-ease-coronavirus-pressure>. March 20, 2020.
7. Fuentes, Gidget. Hospital Ship Comfort Ends NYC COVID-19 Mission After Treating 182 Patients. USNI News. <https://news.usni.org/2020/04/27/hospital-ship-comfort-ends-nyc-covid-19-mission-after-treating-182-patients>. April 27th, 2020.
8. Ray JM, Lindsay RW, Kumar AR. Treatment of earthquake-related craniofacial injuries aboard the USNS Comfort during operation unified response. *Plast Reconstr Surg* 2010;126:2102–2108
9. Suzuki N, Suzuki S, Iwabuchi T. Neurological improvement after cranioplasty. Analysis by dynamic CT scan. *Acta Neurochir (Wien)* 1993;122:49–53
10. Ashayeri K, M Jackson E, Huang J, et al. Syndrome of the trephined: a systematic review. *Neurosurgery* 2016;79:525–534
11. Yamaura A, Makino H. Neurological deficits in the presence of the sinking skin flap following decompressive craniectomy. *Neurol Med Chir (Tokyo)* 1977;17 (1 pt 1):43–53
12. Abdou A, Liu J, Carroll M, et al. Motor and neurocognitive recovery in the syndrome of the trephined: a case report. *Ann Phys Rehabil Med* 2015;58:183–185
13. Picard NA, Zanardi CA. Brain motion in patients with skull defects: B-mode ultrasound observations on respiration-induced movements. *Acta Neurochir (Wien)* 2013;155:2149–2157
14. Dujovny M, Fernandez P, Alperin N, et al. Postcranioplasty cerebrospinal fluid hydrodynamic changes: magnetic resonance imaging quantitative analysis. *Neurol Res* 1997;19:311–316
15. Calvi AR, Gliessing J, Eapen B. Syndrome of the trephined: improvement in neurolinguistic deficits and global aphasia after cranioplasty. *J Head Trauma Rehabil* 2015;30:E111
16. Zhong S, Huang GJ, Susarla SM, et al. Quantitative analysis of dual-purpose, patient-specific craniofacial implants for correction of temporal deformity. *Neurosurgery* 2015;11 Suppl 2:220–229
17. Gordon CR, Fisher M, Liauw J, et al. Multidisciplinary approach for improved outcomes in secondary cranial reconstruction: introducing the pericranial-onlay cranioplasty technique. *Neurosurgery* 2014;10 Suppl 2 (0 2):179–190