

Available online at www.sciencedirect.com

ScienceDirect

journal homepage: www.elsevier.com/locate/radcr

Case report

Endovascular treatment of arteriovenous fistula caused by ruptured iliac aneurysm and type II endoleak

Chengxu Sui¹, Yuanfang Yao¹, Ruojie Li, Jie Wu, Lei Song*

Department of Interventional Therapy, The Second Affiliated Hospital of Dalian Medical University, Dalian 116027, China

ARTICLE INFO

Article history:

Received 21 March 2021

Revised 9 June 2021

Accepted 12 June 2021

Available online 26 August 2021

Keywords:

Iliac aneurysm

Arteriovenous fistula

Type II endoleak

Endovascular treatment

ABSTRACT

Arteriovenous fistulas (AVFs) caused by an isolated iliac aneurysm rupture and postoperative type II endoleak are rare and life threatening. We report here a case of AVF caused by a ruptured iliac aneurysm and postoperative type II endoleak. The patient was successfully treated by implanting a covered stent to treat the ruptured iliac aneurysm. However, type II endoleak with AVF persisted after the operation and was treated with transiliac vein embolization. The patient recovered uneventfully during the 2-month follow-up period.

© 2021 Published by Elsevier Inc. on behalf of University of Washington.

This is an open access article under the CC BY-NC-ND license

(<http://creativecommons.org/licenses/by-nc-nd/4.0/>)

Introduction

Iliac arteriovenous fistula (AVF), which refers to the formation of an abnormal channel between the iliac artery and vein, is a rare vascular disease, with an incidence of less than 1% of all iliac arterial aneurysms and 27% of ruptured aneurysms [1]. An iliac AVF resulting from a ruptured iliac arterial aneurysm has a high mortality rate of 30%-50%, depending on early diagnosis and timely appropriate management [2]. Here, we report a case of iliac AVF resulting from the rupture of an iliac artery aneurysm. The patient received early diagnosis and timely endovascular treatment, including embolization of the type II endoleak via an iliac vein approach. The patient recovered un-

eventfully during the 2-month follow-up period, as confirmed by computerized tomography angiography (CTA).

Case report

A 64-year-old man was transferred to the emergency room of our hospital from a nearby hospital because of a suspected aneurysm. The patient reported experiencing pain in his right lower abdomen for 1 day and in his right lower limb for half a day. The pain persisted after he took over-the-counter painkillers. Physical examination showed that the

* Corresponding author.

E-mail address: songlei_1975@126.com (L. Song).¹ These authors contributed equally to this work.<https://doi.org/10.1016/j.radcr.2021.06.030>1930-0433/© 2021 Published by Elsevier Inc. on behalf of University of Washington. This is an open access article under the CC BY-NC-ND license (<http://creativecommons.org/licenses/by-nc-nd/4.0/>)

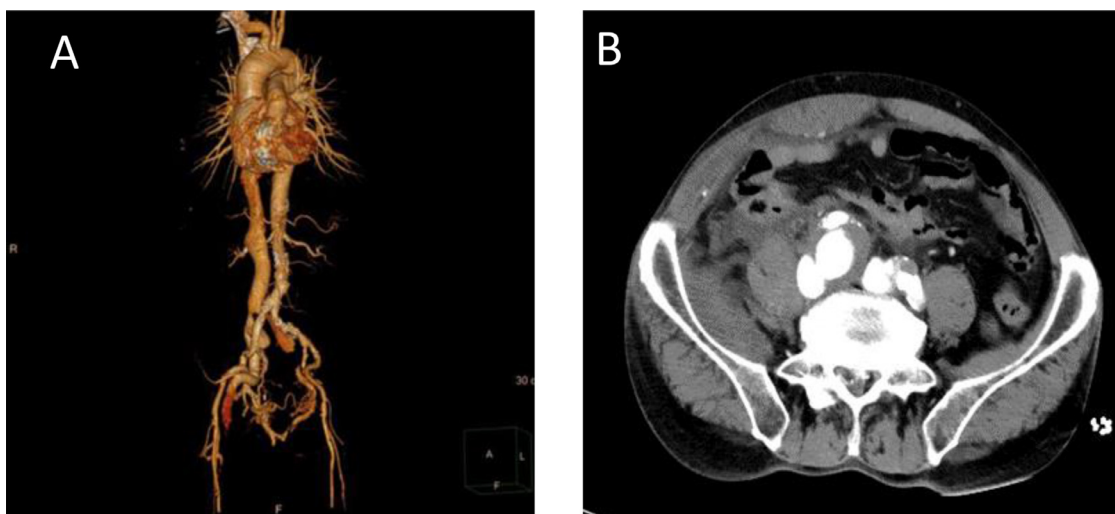


Fig. 1 – Initial CTA shows the right common iliac aneurysm, bilateral iliac vein, and inferior vena cava opacified at the same time, suggesting an arteriovenous fistula.

right lower abdomen had a pulsatile mass of about 5×5 cm with tremor, continuous vascular murmur, mild tenderness, and slight swelling of the right lower limb. The patient denied a history of other diseases except hypertension.

CTA revealed a right common iliac aneurysm and a right common iliac artery-common iliac vein fistula (Fig. 1). Additionally, lower extremity venous ultrasound showed thrombosis in the right femoral and popliteal vein which is shypochoic filling without blood flow signal. Laboratory tests showed a creatinine level of $268.96 \mu\text{mol/L}$, B-type natriuretic peptide level of 263.70 pg/ml , creatine kinase isoenzyme MB level of $16.80 \mu\text{g/L}$, and troponin I level of $1.255 \mu\text{g/L}$. The patient had a temperature of 36.2°C , a pulse of 88 beats/min, respiration of 20 breaths/min, and a blood pressure of 123/66 mm Hg. He also had a history of grade 3 hypertension. These findings suggested the possibility of an iliac aneurysm rupture and the formation of an iliac AVF that caused dysfunction of the heart and kidney while the lower extremity vein obstruction caused thrombosis in the lower extremity veins. Due to the results of the clinical examination, we believed emergency endovascular intervention was necessary. Based on the CTA findings, we planned to use endovascular treatment to repair the right iliac aneurysm and AVF under general anesthesia.

We punctured the bilateral femoral arteries, retained the 6F artery sheath (TERUMO), and pre-set two vascular suture devices (Abbott) on both sides, which were later exchanged with 8F short sheaths (TERUMO). Abdominal aorta and bilateral iliac arteriography were performed by feeding in a 5F pig tail catheter (main parameters: the diameter of the horizontal abdominal aorta at the lower edge of the renal artery was 19 mm, and the diameters of the right and left common iliac arteries were 9.5 mm, and 8.5 mm, respectively). An aneurysm with a size of 2.5×2.0 cm was visible at the origin of the right common iliac artery. During the operation, aortoiliac grafts could not be introduced to the aorta due to severe tortuosity in the bilateral iliac arteries. Since there was sufficient area

for proximal anchoring, a 12×80 mm Fluency covered stent (Bard) was placed in the right iliac artery (Fig. 2). The operation was successful, and the pseudoaneurysm was not observed after surgery. The visualization of the right iliac vein was still visible, but the visualization time was noticeably delayed and the blood flow velocity was slower, indicating a type II endoleak.

On the second day after the operation, the edema in the right lower limb was visibly relieved, the abdominal pain disappeared, no chest tightness and shortness of breath were observed, and the urine output was increased. On the fourth day after the operation, aortic CTA showed that the right iliac aneurysm was closed, but the iliac vein and inferior vena cava were still weakly opacified, suggesting the existence of a type II endoleak with AVF (Fig. 3). Embolization of the type II endoleak AVF was performed under local anesthesia. A 6F artery sheath (TERUMO) was passed through the right femoral vein and the left femoral artery, entering the 4F Cobra catheter (TERUMO) along the right femoral vein sheath. Angiography showed filling of the right iliac vein through the sac. From the venous side, the right internal iliac artery was selected with a 2.7 F microcatheter (TERUMO) and embolized with four $14 \text{ mm} \times 30 \text{ cm}$ microcoils (Interlock, Boston Scientific). The posterior microcatheter was retreated into the tumor cavity and two $14 \text{ mm} \times 30 \text{ cm}$ microcoils (Interlock, Boston Scientific) were implanted for embolization. Re-transabdominal aortography showed that the lumen of the right iliac aneurysm at the end of the artery was slightly opacified, the blood flow velocity was significantly slower, and the right iliac vein was not opacified (Fig. 4).

The patient recovered uneventfully after the operation, with no iliac aneurysm or AVF between the right iliac vein and inferior vena cava, as revealed by aortic CTA (Fig. 5), and no venous thrombosis of the lower extremities, as revealed by ultrasound after anticoagulant therapy. After 2 months of follow-up, no abnormality was revealed by aortic CTA. The patient

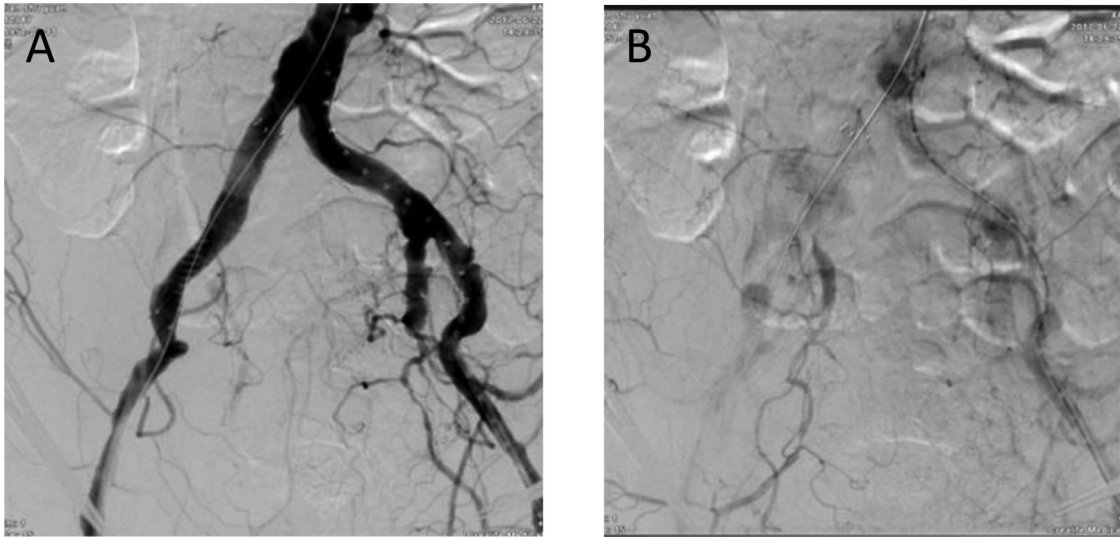


Fig. 2 – Arteriography after implantation of right iliac artery stent: the aneurysm cavity and the right iliac vein are still slightly opacified, which is considered a type II endoleak.

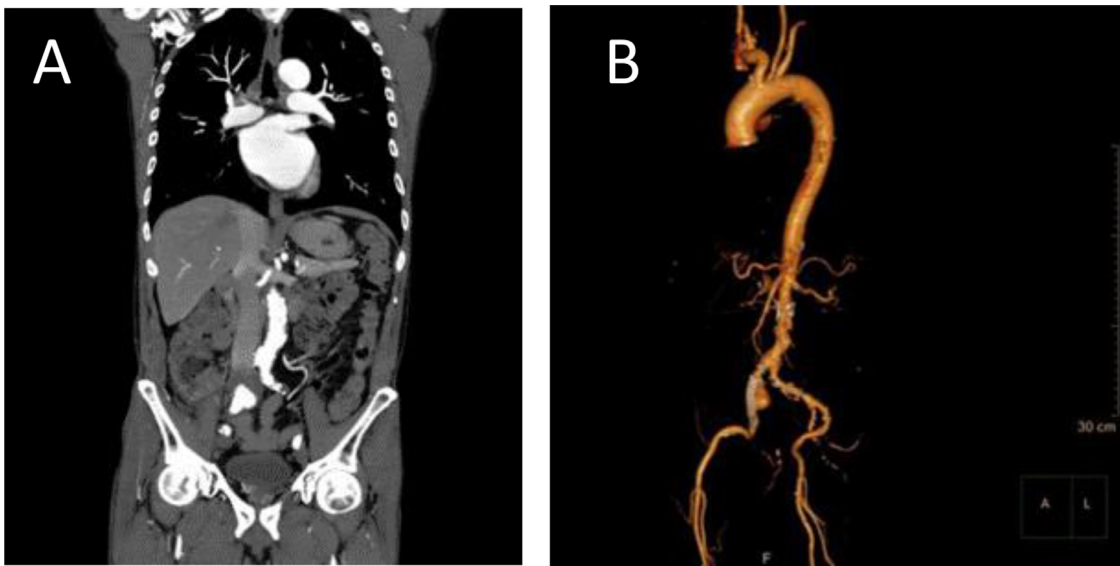


Fig. 3 – On the fourth day after the operation,CTA shows that the right common iliac aneurysm, iliac vein, and inferior vena cava were poorly opacified, suggesting type II endoleak with an arteriovenous fistula.

received regular reexamination as an outpatient for 2 years after the operation and was in good physical condition.

DISCUSSION

Previous studies have shown that more than 80% of iliac artery aneurysms are associated with abdominal aortic aneurysms [3,4]. Because iliac aneurysms occur in the deep in the pelvis, the early symptoms of isolated iliac aneurysms are atypical and thus early detection is very difficult. Enlargement of the aneurysm can place pressure on the surrounding tissues and organs or lead to a rupture. At present, there are no effective

drugs to control the growth of an aneurysm and no methods to predict exactly how close an aneurysm is to rupturing. The most common clinical manifestations of ruptured iliac aneurysms are hypotension and pain, the latter of which may occur in the abdomen, buttocks, or even lower limbs [5]. Typical clinical symptoms of iliac AVF include high-output heart failure, an abdominal pulsatile mass with tremor and continuous murmur, and unilateral lower limb edema or venous dilatation [6]. Other symptoms include shortness of breath, ascites, and unilateral lower limb edema [7–9]. Pulmonary embolism caused by venous thrombosis in the lower extremities has been reported as the first symptom in some patients with iliac AVF [10].

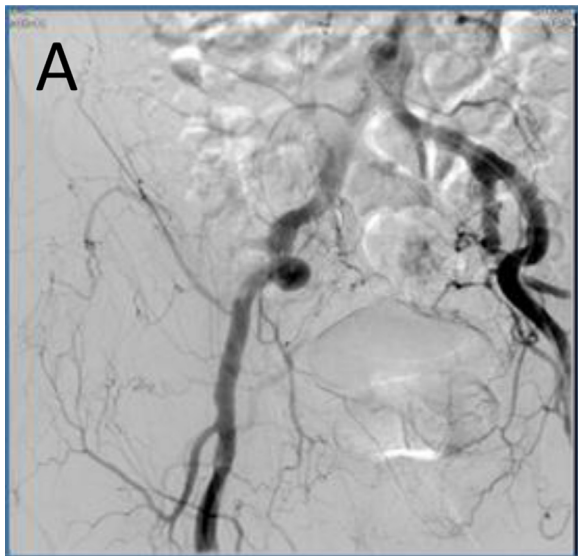


Fig. 4 – Embolization of the type II endoleak AVF, Embolization of the right internal iliac artery and lumen via the right femoral vein approach. Aortic angiography shows that the lumen of the right iliac aneurysm at the end of the artery is slightly opacified, the blood flow velocity is significantly slower, and the right iliac vein is not opacified.

For patients with ruptured aneurysms, an urgent operation is recommended regardless of the size of the aneurysm. Currently, two methods may be used to treat iliac aneurysms: open surgery and endovascular repair. Open surgery is the first choice because the proximal and distal arteries and veins of the AVF need to be blocked separately followed by repair of the fistula. Open surgery is effective with no serious complications for AVFs in a superficial location [11]. However, open surgery to treat deep iliac AVF is more technically challenging. Therefore, endovascular therapy is usually performed as an alternative [12]. In particular, in the event of a ruptured aneurysm, endovascular repair has the advantages of rapid control of bleeding, stabilization of circulation, and less trauma [13,14].

Endovascular treatment is mainly achieved through the selective use of endovascular covered stents, coils, and vascular plugs to close the fistula. Among the treatment methods available, the use of arterial covered stents is the most common and the best intravenous stent is Iliac Branch Device, but there is no commercial Iliac Branch Device stent available at that time. A bifurcated covered stent should be used when the proximal landing zone of the common iliac artery is smaller than 15 mm, while a cylindrical covered stent should be used when there is sufficient anchorage area in the proximal common iliac artery [14]. Intravenous stents can also be used in combination with coils, occluders, or vascular plugs to treat the disease [15]. In the current case, the proximal anchoring area was sufficiently large and we used a 12 x 80 mm Fluency covered stent for the treatment due to the diameter of the right common iliac artery.

Endoleaks are the complication after endovascular treatment of aneurysms and are defined as the persistence of blood

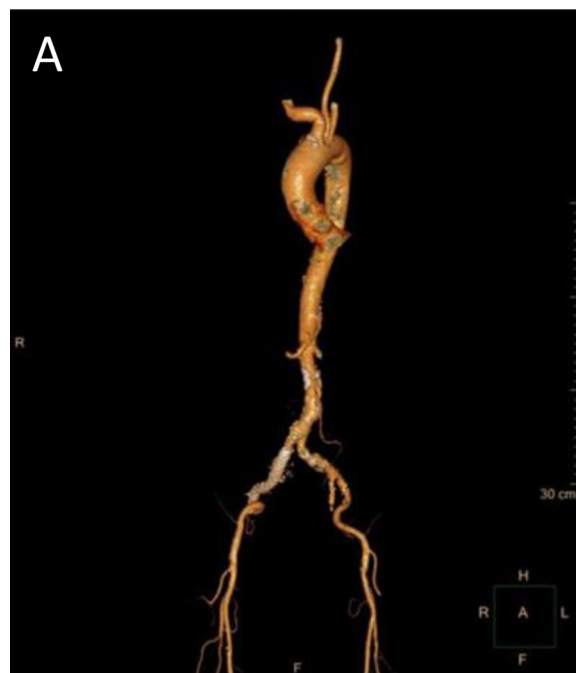


Fig. 5 – After two endovascular operations, No iliac aneurysm, right iliac vein, and inferior vena cava are found on aortic CTA.

flow outside the lumen of the endoluminal graft but within the aneurysmal sac [16]. Endoleaks are categorized into five groups [17]. In type I endoleaks, the blood flow originates from a graft attachment site, type II originates over retrograde filling of the aneurysm sac via collateral vessels, type III results from graft failure, type IV occurs due to porosity of the graft wall and type V is considered as endotension. Previously, Nakad et al [18] systematically reviewed 54 patients with abdominal large vascular AVF and found that the main complications that occur with covered stents are various types of endoleak, of which type II is the most common. The blood flow from type II endoleak mainly enters the isolated cavity after endovascular repair of the aneurysm through the collateral vessels. Consistent with the above report, the patient in this study opacified a type II endoleak with persistent AVF 4 days after the operation, indicating the potential risk of endoleak rupture. The treatment of endoleak depends on the visualization and outcome of the disease [19], endoleak can heal without treatment in approximately 21% of cases [20] and the rest may be treated with endovascular embolization or laparotomy. However, endoleak in some patients increases gradually with the progression of the aneurysm.

The femoral artery approach is often used in the embolization of superselective type II endoleak. However, after deployment of a graft, transarterial embolization often fails or cannot proceed because the connection channel is too small and the intervascular network is complex [21]. In this case, we successfully embolized the superselective type II endoleak through the femoral vein.

Declaration of Competing Interest

None declared.

REFERENCES

- [1] Ying Huang, Peter Gloviczki, Audra A Duncan, Manju Kalra, Tanya L.Hoskin, Gustavo S.Oderich, et al. Common iliac artery aneurysm: expansion rate and results of open surgical and endovascular repair. *J Vasc Surg* 2008;47(6):1203–1211.
- [2] Sandhu RS, Pipinos II. Isolated iliac artery aneurysms. *Semin Vasc Surg* 18:209–215
- [3] R.Fossaceca, G.Guzzardi, M.Terlizzi, et al. Long-term efficacy of endovascular treatment of isolated iliac artery aneurysms[J]. *La radiologia medica*, 2013, 118 (1):62–73.
- [4] N.E.Tabori, A.M.Fischman, R.S.Patel, et al. Endovascular repair of internal iliac artery aneurysms:single center 15-year experience[J]. *J Vasc Int Radiol* 2014, 25 (3):574–579.
- [5] Shah TR, Parikh P, Borkon M, et al. Endovascular repair of contained abdominal aortic aneurysm rupture with aortocaval fistula presenting with high-output heart failure. *VascEndovascular Surg* 2013,47(1):51–56.
- [6] Yan GW, Li HW, Yang GQ, et al. Iatrogenic arteriovenous fistula of the iliac artery after lumbar discectomy surgery: a systematic review of the last 18 years. *Quant Imaging Med Surg* 2019;9(6):1163–1175.
- [7] Yuminaga Y, Mohabbat W, Nguyen T, et al. Simultaneous endovascular repair of an iatrogenic carotidjugular fistula and a large iliocaval fistula presenting with multiorgan failure: a case report. *J Med Case Rep* 2012,24(6):33.
- [8] Tan G, Abdullah B, Kunanayagam S. Spontaneous internal ilio-iliac fistula in an elderly woman presenting as heart failure. *Biomed Imaging Interv J* 2006,2(2):e13.
- [9] Yilmaz YK, Çelikkbilek M, Sankaya S, et al. Iliac arteriovenous fistula presenting with ascites. *Turk J Gastroenterol* 2014,25(Suppl 1):210–212.
- [10] Shah TR, Parikh P, Borkon M, et al. Endovascular repair of contained abdominal aortic aneurysm rupture with aortocaval fistula presenting with high-output heart failure. *VascEndovascular Surg* 2013,47(1):51–56.
- [11] JHM Tordoir, MM Van Loon, N Peppelenbosch, et al. Surgical techniques to improve cannulation of hemodialysis vascular access. *Eur J Vasc Endovasc Surg* 2010;39(3):333–339
- [12] Chaikof EL, Dalman RL, Eskandari MK, et al. The Society for vascular surgery practice guidelines on the care of patients with an abdominal aortic aneurysm. *J Vasc Surg* 2018;67(1):2–77.
- [13] Wanhainen A, Verzini F, Van Herzelee I, et al. Editor's choice European Society for vascular surgery (ESVS) 2019 clinical practice guidelines on the management of abdominal aorto-iliac artery aneurysms. *Eur J Vasc Endovasc Surg* 2019;57:8–93.
- [14] Uberoi R, Tsctis D, Shrivastava V, et al. Standard of practice for the interventional management of isolated iliac artery aneurysms[J]. *Cardiovasc Intervent Radiol* 2011,34(1):3–13.
- [15] Patatas K, Robinson G, Shrivastava V, et al. A novel endovascular technique in the management of a large internal iliac artery aneurysm associated with an arteriovenous fistula. *Cardiovasc Revasc Med* 2013,14(1):62–65.
- [16] F.L.Moll, J.T. Powell, G. Fraedrich, et al., Management of abdominal aortic aneurysms clinical practice guidelines of the European society for vascular surgery, *Eur J V asc Endovasc Surg* 41(Suppl 1) (2011), S1–S58.
- [17] G. Barbiero, A. Baratto, F. Ferro, J. Dall'Acqua, C. Fitta, D. Miotto. Strategies of endoleak management following endoluminal treatment of abdominal aortic aneurysms in 95 patients: How, when and why, *Radiol Med* 113 (2008), 1029–1042.
- [18] Nakad G, AbiChedid G, Osman R. Endovascular treatment of major abdominal arterio-venous fistulas: a systematic review. *Vasc Endovascular Surg* 2014,(5-6):388–395.
- [19] Buck DB, Bensley RP, Darling J, et al. The effect of endovascular treatment on isolated iliac artery aneurysm treatment and mortality. *J Vasc Surg* 2015;62:331–335.
- [20] Schurink GW, Aarts NJ, Van Bockel JH. Endoleak after stent-graft treatment of abdominal aortic aneurysm: a meta-analysis of clinical studies. *Br J Surg* 1999,86:581–587.
- [21] Solis MM, Ayerdi J, et al. Mechanism of failure in the treatment of type II endoleak with percutaneous coil embolization[J]. *Vasc Surg* 2002;36(3):485–91.