

Niemann–Pick Disease Type C Associated with Fuchs Heterochromic Iridocyclitis

Abstract

In this study, we report a 26-year-old female case of Niemann–Pick disease type C in association with Fuchs heterochromic iridocyclitis who was admitted with the complaint of ocular pain and redness following trauma. She had mild inflammatory signs and also vertical ocular motility limitations.

Keywords: *Fuchs heterochromic iridocyclitis, Niemann–Pick disease type C, uveitis*

**Farzan Kianersi,
Seyed Ali
Sonbolestan**

*From the Department of
Ophthalmology, Eye Research
Centre, Isfahan University of
Medical Sciences, Isfahan, Iran*

Introduction

Niemann–Pick disease type C (NP-C) is a rare neurodegenerative disease.^[1] Abnormal saccadic eye movements (SEMs) are frequently the earliest neurological sign appreciated in NP-C. In most patients, the initial deficit is in the vertical plane; however, finally, the horizontal plane may be affected too.^[2,3]

Fuchs heterochromic iridocyclitis (FHI) is a chronic nongranulomatous disease. Its exact etiology is unknown; however, some associations with many other diseases such as toxoplasmosis, rubella vaccination, herpes simplex virus, cytomegalovirus, retinitis pigmentosa, Usher's syndrome, and previous trauma were explained previously.^[4]

In this study, we report one case of NP-C in association with FHI.

Case Report

A 26-year-old female with the complaint of ocular pain and redness (in the right eye) following trauma was admitted to ophthalmology emergency room. According to her mother's history, the patient had a medical history of developmental delay, auditory impairment, the history of generalized tonic–clonic seizures, and also ataxic gait since the toddler age and she had some school difficulties since childhood. Furthermore, according to her medical documents, the history of gastroesophageal reflux disease was noted but she had no history of pulmonary or splenic abnormalities.

Her ocular examination finding included of: best-corrected visual acuities were 4/10 and 8/10 (OD and OS, respectively), and in slit-lamp examination of the right eye, a subconjunctival hemorrhage, trace (0.5–1+) anterior chamber reaction, a mild posterior subcapsular cataract, diffuse fine keratic precipitates, and mild (1+) vitreous cells were identified. Mild iris atrophy was seen in the right eye. The slit-lamp examination of the left eye was normal. Intraocular pressure and fundus examination revealed no abnormal findings [Figures 1–5].

In ocular motility testing, limitation in vertical gazes (both up and down gazes) was found. According to the patient and her mother's history, this problem had existed from childhood, and over the years, it progressed, and she has had difficulties in reading [Figure 6].

The paraclinic findings included of complete blood count, serum electrolytes, lipid profile, serum copper and ceruloplasmin, erythrocyte sedimentation rate, C-reactive protein, serum transaminases, urea, creatinine, and blood urea nitrogen were in the normal range. Furthermore, serum antinuclear and antiphospholipid antibodies were negative. Purified protein derivative skin test, rapid plasma reagin test, and Venereal Disease Research Laboratory test were also negative. Chest X-ray was normal.

A magnetic resonance imaging (MRI) was done before in which cerebellar atrophy was reported [Figure 7].

This is an open access article distributed under the terms of the Creative Commons Attribution-NonCommercial-ShareAlike 3.0 License, which allows others to remix, tweak, and build upon the work non-commercially, as long as the author is credited and the new creations are licensed under the identical terms.

For reprints contact: reprints@medknow.com

How to cite this article: Kianersi F, Sonbolestan SA. Niemann–Pick Disease Type C Associated with Fuchs Heterochromic Iridocyclitis. *Adv Biomed Res* 2017;6:168.

Received: January, 2016. **Accepted:** July, 2016.

Address for correspondence:

*Dr. Seyed Ali Sonbolestan,
Feiz Hospital,
Isfahan University of Medical
Sciences, Isfahan, Iran.
E-mail: sonbolestan@edc.mui.
ac.ir*

Access this article online

Website: www.advbiores.net

DOI: 10.4103/2277-9175.221859

Quick Response Code:



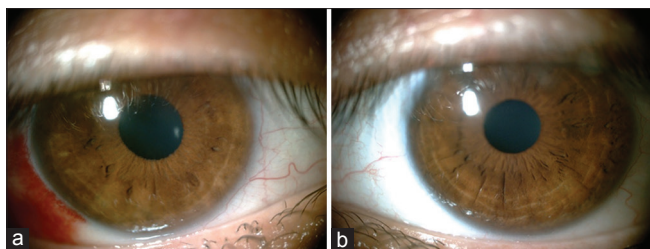


Figure 1: (a) The patient's right eye (×10). (b) The patient's left eye (×10)




Figure 2: The patient's right eye (×16), focus on the cornea, and the keratic precipitates could be seen




Figure 3: The patient's right eye (×16), focus on the iris




Figure 5: The patient's right eye (×16), focus on the anterior vitreous

Furthermore, it was cleared that her cousin had similar neurologic and ocular motility findings; however, no other similar findings were reported in her family. The patient's parents did not have any relationship.

Discussion

NP-C disease has several neurologic, cognitive, and ocular manifestations and is linked with the autosomal recessive inheritance of mutations of the genes, NPC1 and NPC2.^[5]

About the ophthalmic abnormalities, these patients do not have retinal pigment abnormalities or cherry-red spot. However, abnormal SEM is often present as the initial neurological abnormality in NP-C. In the majority of patients, the primary SEM deficit is in the vertical plane, which results in difficulties in downward, upward, and eventually both gazes. After that, the horizontal gazes are disturbed too. Subsequently, these changes cause complete supranuclear gaze palsy and so the limitation of patients

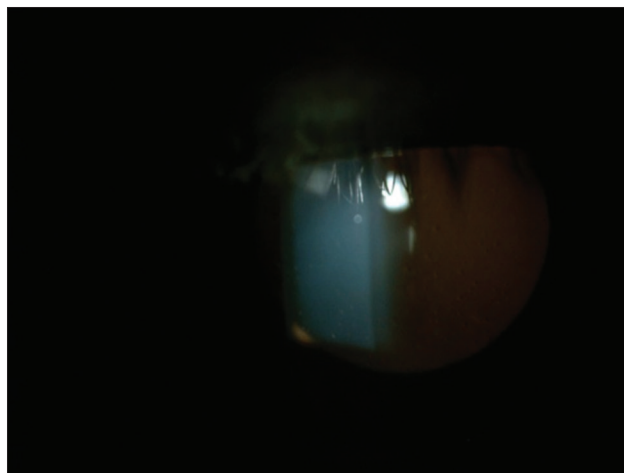

Figure 4: The patient's right eye (×16), focus on the lens

in reading and following the targets. According to the previous studies, vertical supranuclear gaze palsy is known as the prominent sign of NP-C which is usually diagnosed in the late infantile period and after that.^[2,3]

Neuropsychiatric manifestations are commonly diagnosed from the late infantile period and after that. Young patients (especially 6–15 years) sometimes have difficulties at school and/or behavioral problems as reported in our patient. In the majority of patients, the progressive cognitive decline is common. Some of the other neurologic problems included of abnormal muscle tone or posture, incoordination, limited working ability, and seizures or cataplexy are known.

Laboratory biochemistry profiles including blood biochemistry, plasma lipids, and unconjugated bilirubin are commonly normal in NP-C patients, but can be changed in those with hypersplenism or cholestatic liver disease. Low HDL-C is communal. A mild thrombocytopenia can occasionally be detected in patients with splenomegaly. Plasma transaminases are mostly normal; however, aspartate aminotransferase can be elevated but generally returns to normal.^[1]

Plasma chitotriosidase seems to be a marker for severity of the disorder; however, its usefulness is not proven and also it is neither sensitive nor specific. Anyway, laboratory tests for NP-C are not forthright. Many different biochemical and molecular approaches are suggested for diagnosis, but none of them is exact. In the meantime, the diagnosis is suggested on the basis of physical examination and signs of the disease and

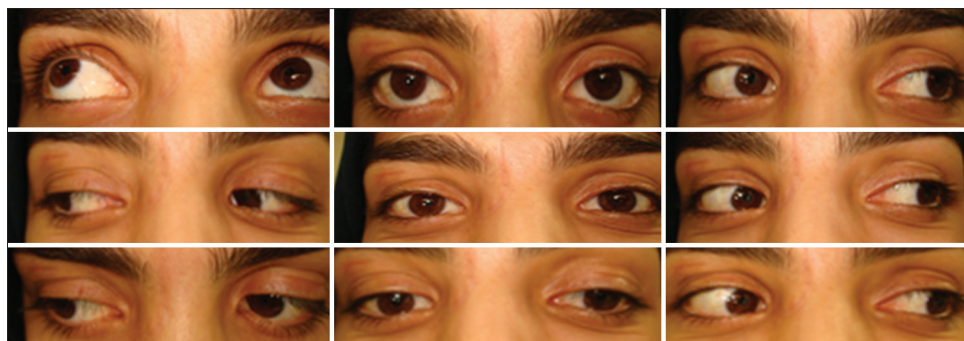

Figure 6: Ocular motility findings in the patient

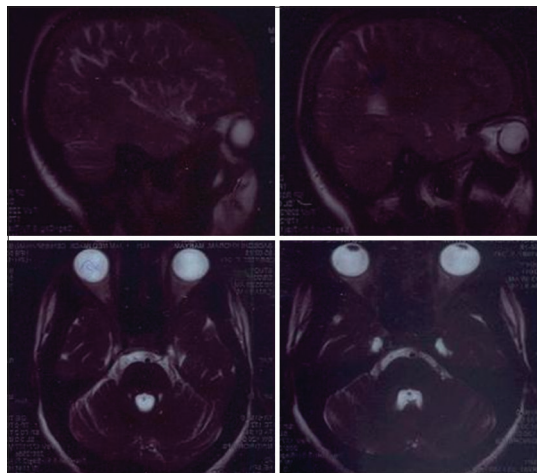


Figure 7: Magnetic resonance imaging scans of the patient

ruling out of other differential diagnoses. The exact diagnostic evaluations done in patients assumed to have NP-C can depend on the regional availability of resources and expertise.^[1]

MRI could reveal some findings such as cerebral atrophy and/or marked atrophy of the superior or anterior cerebellar vermis. Some of the patients may show some small degrees of cerebral atrophy or thinning of the corpus callosum. Furthermore, some of them may have white matter signal hyperintensity lesions in T2-weighted MRIs.^[6]

Until lately, there was no disease-modifying treatment for NP-C. Helpful therapies are variably effective for the lessening of clinical appearances of this disease. Palliative pharmacotherapy is used for dystonia, seizures, sleep disorders, gastrointestinal symptoms, and rarely, lung involvement.^[1] In the meantime, our patient was only treated by anticonvulsant therapy and sometimes proton pump inhibitors such as Omeprazole.

The incidence of FHI is about 0.2% and consists of about 6% of all uveitis patients.^[7] In this case, the patient had been followed for about 3 years, and all the immunologic and infectious evaluations were negative during this period. Hence, according to ocular signs and symptoms, the diagnosis of FHI was suggested. The patient was not treated for her FHI disease as it seemed to be controlled; however, reassurance was done about her traumatic findings.

Conclusion

Here, a case of NP-C disease who suffered also from FHI is presented, and hence, it could be added to the long list of FHI associations.

Declaration of patient consent

The authors certify that they have obtained all appropriate patient consent forms. In the form the patient(s) has/have given his/her/their consent for his/her/their images and other clinical information to be reported in the journal. The patients understand that their names and initials will not be published and due efforts will be made to conceal their identity, but anonymity cannot be guaranteed.

Financial support and sponsorship

Nil.

Conflicts of interest

There are no conflicts of interest.

References

1. NP-C Guidelines Working Group, Wraith JE, Baumgartner MR, Bembi B, Covanis A, Levade T, *et al.* Recommendations on the diagnosis and management of Niemann-Pick disease type C. *Mol Genet Metab* 2009;98:152-65.
2. Solomon D, Winkelman AC, Zee DS, Gray L, Büttner-Ennever J. Niemann-Pick type C disease in two affected sisters: Ocular motor recordings and brain-stem neuropathology. *Ann N Y Acad Sci* 2005;1039:436-45.
3. Lengyel D, Weissert M, Schmid L, Gottlob I. Eye movement abnormalities as a sign for the diagnosis in Niemann-Pick disease type C. *Klin Monbl Augenheilkd* 1999;214:50-2.
4. Babu K, Adiga M, Govekar SR, Kumar BR, Murthy KR. Associations of Fuchs heterochromic iridocyclitis in a South Indian patient population. *J Ophthalmic Inflamm Infect* 2013;3:14.
5. Millat G, Baïlo N, Molinero S, Rodriguez C, Chikh K, Vanier MT. Niemann-Pick C disease: Use of denaturing high performance liquid chromatography for the detection of NPC1 and NPC2 genetic variations and impact on management of patients and families. *Mol Genet Metab* 2005;86:220-32.
6. Sévin M, Lesca G, Baumann N, Millat G, Lyon-Caen O, Vanier MT, *et al.* The adult form of Niemann-Pick disease type C. *Brain* 2007;130(Pt 1):120-33.
7. Lichtinger A, Chowers I, Amer R. Usher syndrome associated with Fuchs' heterochromic uveitis. *Graefes Arch Clin Exp Ophthalmol* 2010;248:1481-5.