

# Sagittal Atlantoaxial Joint Inclination and Reduction Index Values for Diagnosis and Treatment of Irreducible Atlantoaxial Dislocation

## Abstract

**Background:** Irreducible atlantoaxial dislocation (IAAD) is a disorder of atlantoaxial joint instability with various causes. The diagnostic criteria for IAAD are variable. The diagnosis of IAAD is mainly based on preoperative and intraoperative traction results, as well as the physician's experience, with no relatively uniform guidelines for the selection of treatment. This study evaluates sagittal atlantoaxial joint inclination (SAAJI) and reduction index (RI) values for diagnosis and treatment of IAAD. **Materials and Methods:** 24 IAAD patients treated in our hospital from January 2008 to July 2014 were retrospectively analysed. Patients included were 13 males and 11 females, with a mean age of 43 years. The various causes for IAAD were atlantoaxial transverse ligament rupture (n=3), old dens fracture (n=15), occipitalization of the atlas (n=6). The patients were divided into two groups. group A underwent anterior release with posterior reduction and fixation; Group B underwent posterior reduction and fixation; 12 healthy individuals served as controls. SAAJI and atlas-dens interval (ADI) values before and after traction were measured, and RI was calculated. Imaging data were analyzed. **Results:** The mean SAAJI values were as follows: left,  $5.6 \pm 1.9^\circ$  and right,  $5.1 \pm 2.1^\circ$  in the control group; right,  $39.5 \pm 6.0^\circ$  and left,  $38.8 \pm 5.8^\circ$  in Group A; and right,  $23.1 \pm 7.0^\circ$  and left,  $23.9 \pm 6.1^\circ$  in Group B. There was no significant difference in the SAAJI values of the three groups ( $P < 0.05$ ). The mean RIs in Groups A and B were  $17.6 \pm 9.3\%$  and  $34.4 \pm 5.2\%$ , respectively, and the difference was statistically significant ( $P < 0.05$ ). There were obvious negative correlations between the SAAJI and RI values in Groups A and B. **Conclusions:** SAAJI and RI can be used as important imaging indicators to determine the reversibility of IAAD. If the RI value is  $>27.9\%$  and SAAJI value is  $<32.5^\circ$ , reduction and fixation can be achieved by the posterior approach alone; otherwise, a combination of anterior and posterior approaches would be necessary.

**Keywords:** Atlantoaxial joint, irreducible atlantoaxial dislocation, reduction index, sagittal inclination

**MeSH terms:** Atlas, cervical, axis, cervical vertebrae, dislocations

Shi-Long Yuan,  
Hong-Mei Xu,  
Lian-Chong Fu<sup>1</sup>,  
Jin Cao,  
Jian-Kun Yang,  
Yong-Ming Xi

Department of Orthopaedic Surgery, The Affiliated Hospital of Qingdao University, Qingdao 26600, <sup>1</sup>Department of Orthopaedic Surgery, Hanjing People's Hospital of Weifang, Weifang 261100, China

## Introduction

Irreducible atlantoaxial dislocation (IAAD) is a disorder of atlantoaxial joint instability with various causes. IAAD can lead to gradual forward and downward inclination, and even dislocation of the atlantoaxial joint, causing the atlas and axis to lose their normal cooperative relationship. With disease progression, contractures can develop in the surrounding muscles, ligaments, and joint capsules, thus generating much fibrous scarring and osteophyte formation and even joint locking.<sup>1-3</sup> The diagnostic criteria for IAAD are variable. According to Tan *et al.*,<sup>4</sup> if bone fusion and facet joint destruction can be ruled out by computed tomography (CT) reconstruction, a patient who cannot obtain satisfactory reduction, has an atlas-dens

interval (ADI)  $\geq 5$  mm, or has adequate space available for the cord  $\leq 13$  mm after continuous skull traction with 5 kg for 1–2 weeks can be considered to have IAAD. Salunke *et al.*<sup>5</sup> diagnosed IAAD when skull traction for 48–72 h, starting with 7%–8% of the patient's body weight, and increasing to as much as 20%, achieved no satisfactory reduction (ADI  $\geq 3$  mm in adults and  $\geq 5$  mm in children). There are various treatment methods, based on the current diagnostic criteria, including transoral fascia dentata and partial vertebral axis resection,<sup>6,7</sup> trans-oral pharyngeal release plus anterior plate fixation,<sup>8-10</sup> and anterior cervical release plus posterior fixation.<sup>11-14</sup> The diagnosis of IAAD is mainly based on preoperative and intraoperative traction results, as well as the physician's experience, with no relatively uniform guidelines for the selection of treatment;

### Address for correspondence:

Dr. Yong-Ming Xi,  
Department of Spinal Surgery,  
The Affiliated Hospital  
of Qingdao University,  
Qingdao 266003, China.  
E-mail: yongmingxi@163.com

### Access this article online

Website: [www.ijoonline.com](http://www.ijoonline.com)

DOI:  
10.4103/ortho.IJOrtho\_251\_16

### Quick Response Code:



**How to cite this article:** Yuan SL, Xu HM, Fu LC, Cao J, Yang JK, Xi YM. Sagittal atlantoaxial joint inclination and reduction index values for diagnosis and treatment of irreducible atlantoaxial Dislocation. Indian J Orthop 2018;52:190-5.

This is an open access article distributed under the terms of the Creative Commons Attribution-NonCommercial-ShareAlike 3.0 License, which allows others to remix, tweak, and build upon the work non-commercially, as long as the author is credited and the new creations are licensed under the identical terms.

For reprints contact: [reprints@medknow.com](mailto:reprints@medknow.com)

therefore, objective criteria for assessing recoverability and guiding treatment are needed. Many factors can affect atlantoaxial reduction; Salunke *et al.*<sup>5</sup> Chandra and Goyal<sup>15</sup> suggested that sagittal atlantoaxial joint inclination (SAAJI) in IAAD patients could change, but the extent to which this change would affect IAAD using precise data has not been reported. This study retrospectively analysis the SAAJI and reduction index (RI) data for IAAD patients treated in our hospital, to determine the values for these two parameters for use in evaluating irreducibility and guiding the selection of treatment.

## Materials and Methods

24 IAAD patients treated in our hospital using anterior release with posterior reduction and fixation, or posterior reduction and fixation alone, between January 2008 and July 2014 were included in this retrospective study. There were 13 males and 11 females, with a mean age of 43 years (range 20-62 years). Another 12 individuals with normal cervical structures were selected as the control group (cervical injury was ruled out by CT). All 24 patients were diagnosed with anterior AAD; the causes included atlantoaxial transverse ligament rupture (n=3) old dens fracture (n=15), combined atlantooccipital osteosis (with an identifiable anterior atlantoaxial arch) (n=6), and C2/3 vertebral fusion (n=1). All 24 patients had various degrees of occipitocervical discomfort, pain, and limited mobility, and 18 had symptoms of cervical spinal compression: numbness, weakness, unsteady gait, increased muscle tone, or tendon hyperreflexia. This study was conducted in accordance with the Declaration of Helsinki. This study was conducted with approval from the Ethics Committee of University. Written informed consent was obtained from all participants.

According to the surgical approaches employed, the patients were divided into Group A (n=10), with anterior release and posterior reduction fixation; and Group B (n=14), with posterior reduction and fixation alone. In addition, 12 normal individuals comprised the control group. All patients underwent routine preoperative and postoperative Japanese Orthopaedic Association (JOA) scoring<sup>16,17</sup> to calculate the postoperative improvement rate =  $(\text{postoperative score} - \text{preoperative score}) / (17 - \text{preoperative score}) \times 100\%$ ; the surgical results and recovery conditions were also monitored. All patients underwent preoperative, posttraction, and postoperative cervical normal and lateral imaging, as well as preoperative cervical dynamic imaging, cervical opening imaging, cervical three-dimensional (3D) CT reconstruction, and magnetic resonance imaging plane scanning to understand the extent of AAD, spinal compression, signal changes, and scar hyperplasia. All cervical CT plane scanning was performed in the neutral position. The control group also underwent cervical CT to exclude injuries. Indeed, we adopt the same standard recommended by Salunke *et al.*<sup>5</sup> for the patient; the criteria were the traction weight from 7% to 8% of body weight,

until one-fifth of the patients' weight, and maintain traction 48–72 h.

### Sagittal atlantoaxial joint inclination

Using cervical 3D CT reconstruction, two tangents (a, b) were constructed toward the atlantoaxial articular surface on the parasagittal view (bone window); the angle formed by these two tangents was  $\alpha$ ; the angle (angle  $\beta$ ) formed by the bisector (c) of angle  $\alpha$  with the horizontal line (d) was labeled the SAAJI. The bilateral sides of SAAJI were then measured [Figure 1].

### Atlas-dens interval

The vertical distance was measured from the posterior edge of the anterior atlantoaxial arch to the anterior edge tangent of the axial dens on lateral cervical imaging. RI could then be calculated according to the changes in ADI before and after skull traction [Figure 2].

The above imaging parameters were measured by at least three individuals using uniform standards and then averaged.

### Statistical analysis

SPSS 19.0 software (SPSS Inc, Chicago, IL, USA) was used for the data analysis; the *t*-test was used for the comparison and analysis of the JOA scores, the SAAJI and RI values, and correlations between different parameters, with  $P < 0.05$  being considered statistically significant. A receiver operating characteristic curve (ROC) was used; the maximum cutoff point of Youden's index was set as the critical point to define the optimum values of the parameters in Groups A and B.

## Results

### Comparison of sagittal atlantoaxial joint inclination

The average preoperative and postoperative JOA scores in Group A were  $8.8 \pm 2.8$  and  $13.7 \pm 1.8$ , respectively, and the average improvement rate was 60.9%; the average preoperative and postoperative JOA scores in Group B were  $8.9 \pm 1.7$  and  $13.8 \pm 1.7$ , respectively, and the average improvement rate was 59.1%, indicating that there was significant reduction in the symptoms in both, Group A and Group B after the operation; no significant difference was found in the symptom reduction rates of these two groups ( $t = 0.78, P > 0.05$ ).

The SAAJI data for Groups A and B and the control group (Group C) are shown in Table 1; statistical analysis showed no significant difference between left and right SAAJI in each group ( $P > 0.05$ ), but the intergroup comparison exhibited significant statistical differences ( $P < 0.05$ ).

### Comparison of reduction index

The average RI  $17.6 \pm 9.3\%$  in Group A and  $34.4 \pm 5.2\%$  in Group B, and the intergroup difference was not

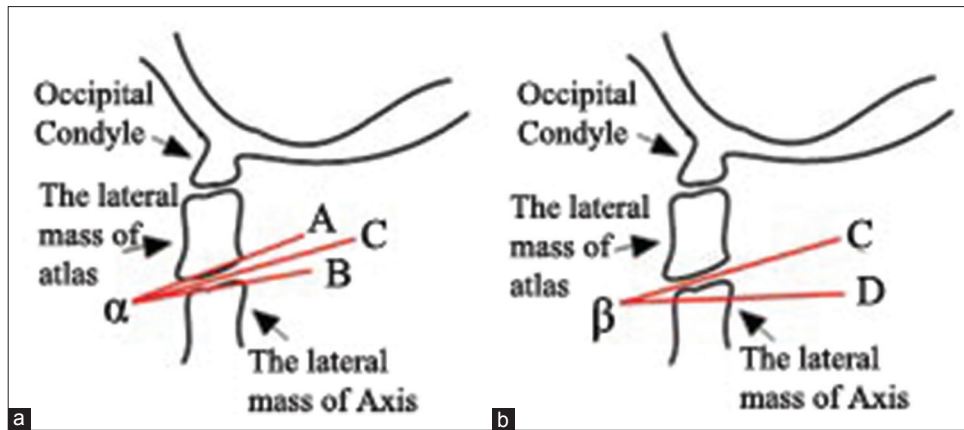


Figure 1: A line diagram of parasagittal view of cervical computed tomography (a and b). A was the lower articular surface tangent of lateral atlantoaxial mass, B was the upper articular surface tangent of lateral atlantoaxial mass; A and B formed the angle  $\alpha$ ; C was the bisector of the angle  $\alpha$ , and D was the horizontal line; the angle  $\beta$  formed by C and D was sagittal atlantoaxial joint inclination

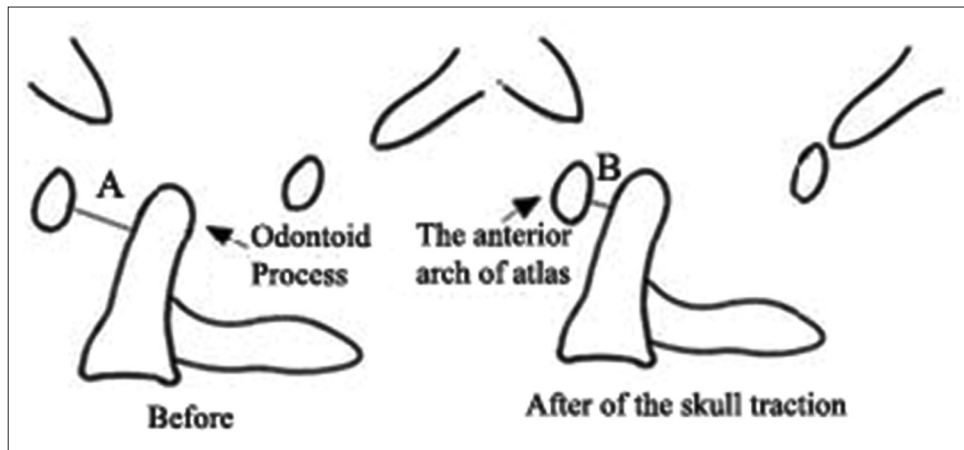


Figure 2: A line diagram showing Atlas-dens relation, Atlas-dens interval = A, B, reduction index =  $(A - B)/A \times 100\%$

**Table 1: Sagittal atlantoaxial joint inclination in the three groups ( $\bar{x} \pm s$ ) ( $^\circ$ )**

Group	Left	Right	All
A	38.8±5.8	39.5±6.0	39.2±5.7
B	23.9±6.1	23.1±7.0	23.5±6.4
C	5.6±1.9	5.1±2.1	5.3±2.0

**Table 2: Correlation between reduction index and sagittal C1-C2 inclination degrees**

Groups	Parameter	Correlation coefficient	P
A	Right sagittal inclination	-0.74	<0.05
	Left sagittal inclination	-0.89	<0.05
B	Right sagittal inclination	-0.85	<0.05
	Left sagittal inclination	-0.75	<0.05

significant ( $P > 0.05$ ). Further correlation analysis between SAAJI and RI values in Group A and B, respectively, revealed that these two radiographic parameters were significantly negatively correlated, i.e. the larger the SAAJI, the smaller the RI, indicating more difficulty in traction reduction for AAD [Table 2]. The ROC curves showed that

the optimal critical point of SAAJI in Group A and B was  $32.5^\circ$  (sensitivity 95%, specificity 89%), and the best RI was 27.9% (sensitivity 100%, specificity 80%).

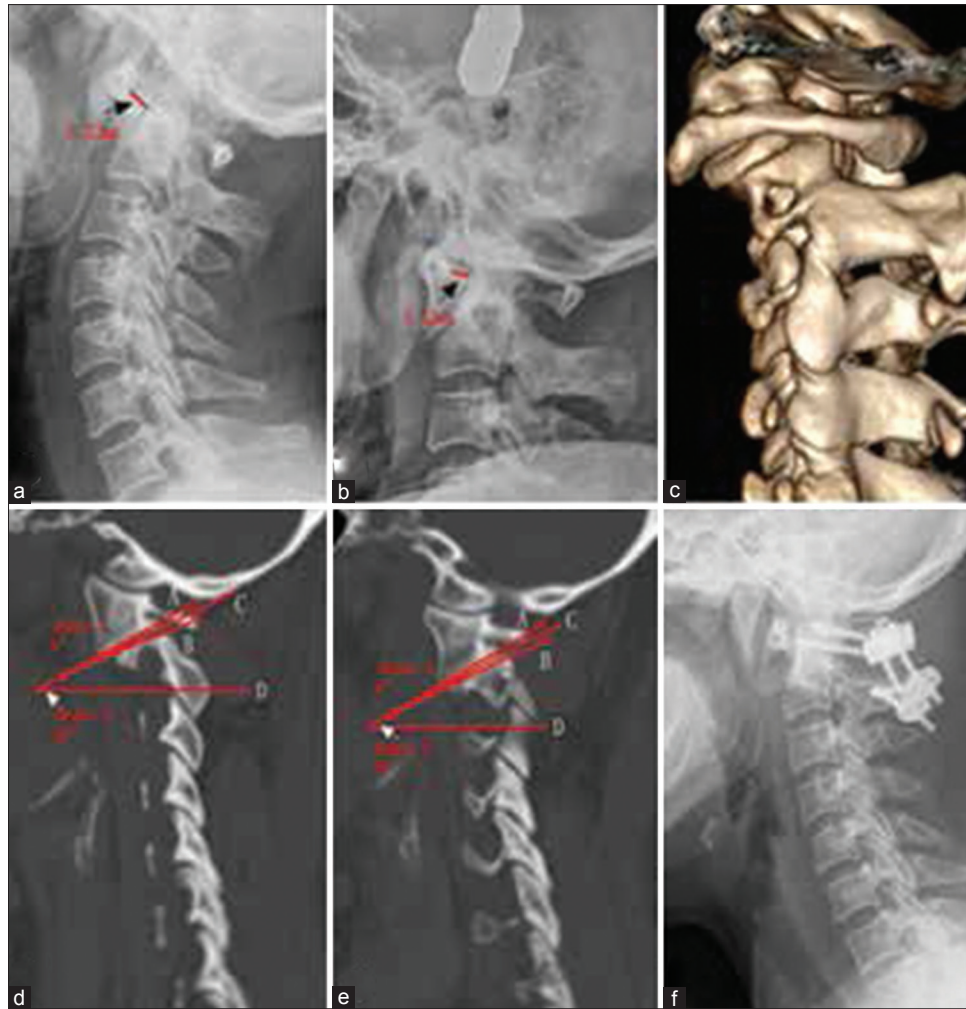
**Clinical cases**

Case 1, a 55-year-old female, had 3 years of progressive limb numbness. On imaging, RI and SAAJI were 34.29% and  $22^\circ$ , respectively; this patient underwent simple posterior atlantoaxial reduction plus bone graft internal fusion [Figure 3].

Case 2, a 62-year-old female, had 10 years of progressive limb numbness plus respiratory difficulty. RI was 12.93% and SAAJI was  $38^\circ$ ; the surgical method was trans-submandibular anterior release and posterior atlantoaxial reduction plus bone graft internal fusion [Figure 4].

**Discussion**

Atlantoaxial instability and dislocation can have various causes; commonly seen causes include dens fracture, congenital malformation, transverse ligament rupture, inflammation, and tumors.<sup>1,2,18,19</sup> AAD is divided into



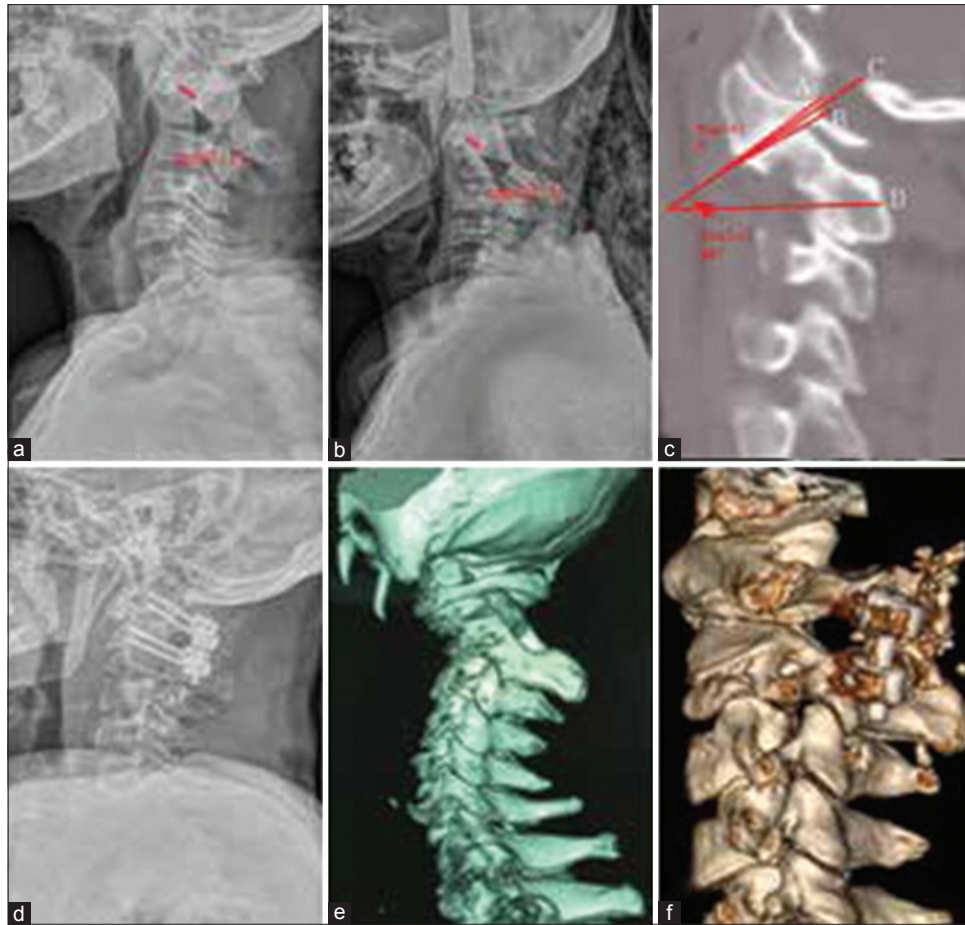
**Figure 3:** 55 years old female, performed simple posterior atlantoaxial reduction and bone graft internal fixation (a and b) X-ray cervical spine lateral view showing atlas-dens interval before and after the traction was 9.32 mm and 6.14 mm, respectively; reduction index was 34.29%; (c) 3-D reconstructed image cervical spine showing obvious forward and downward atlantoaxial dislocation toward axis before the traction (d and e) CT cervical spine paracervical sagittal view showing the left and right sagittal atlantoaxial joint inclinations were 22° and 24°, respectively (f) the postoperative X-ray cervical spine lateral view showing that atlas-dens interval was significantly reduced

reducible and nonreducible types, and reducible dislocation can be corrected through posture adjustment or appropriate skull traction, however, nonreducible dislocation cannot be reduced by appropriate traction or even soft tissue release. The latter cannot be corrected by long term traction or even heavy traction under anesthesia.<sup>20</sup>

The treatment methods for IAAD with clinical symptoms are based on effective spinal decompression of the medulla oblongata and spinal cord. However, the AAD is deeply located near the skull base, close to the medulla oblongata and the nerves, blood vessels, and glands in the anterior neck and is covered by the mandible; therefore, access and surgery are very difficult, with significant surgical risk.<sup>20,21</sup> The diagnostic criteria of IAAD vary,<sup>4,5,22</sup> and imaging standards that could guide the selection of surgical methods are lacking; specifically, no imaging standard has been devised to guide selection of a simple posterior approach or a combination with an anterior approach.

Anatomical factors affecting IAAD include local bone hyperplasia, joint space stenosis, morphological changes on the articular surface, and contracture of joint capsules, surrounding ligaments, and muscles, as well as disease duration.<sup>4</sup> By identifying the anatomical changes or soft tissue factors, their effects on the extent of irreducibility can be understood, thus providing references for the selection of surgical options. Salunke *et al.*<sup>5</sup> used the cervical CT parasagittal view to measure the angle between the tangent of the lower atlantoaxial articular surface and the tangent of the hard palate and reported that the larger the SAAJI, the more difficult the reduction. Chandra and Goyal<sup>15</sup> used the angle between the tangent of the upper sagittal atlantoaxial articular surface and the tangent of the posterior dens edge to analyze IAAD and reducible AAD and found significant differences between these two types.

In this study, we retrospectively analyzed the clinical data of patients treated with simple posterior reduction or anterior release plus posterior reduction and fixation



**Figure 4:** 62 years old female, with a history of 10-year atlantoaxial dislocation accompanied by spinal cord compression; after the skull traction, according to the reduction conditions, this had trans-submandibular anterior release, posterior atlantoaxial reduction plus bone graft and internal fixation, and the postoperative improvement rate was 75%; (a and b) X-ray cervical spine lateral view showing that atlas-dens interval before and after the traction was 11.08 mm and 9.65 mm, respectively, and reduction index was only 12.93% (c) the left parasagittal CT scan cervical spine showing that atlantoaxial joint inclination was 38°; (d) the postoperative x-ray cervical spine lateral view showing that atlas-dens interval was significantly reduced, and the fixation was firm (e and f) 3 D reconstructed CT scan cervical spine showing that sagittal atlantoaxial joint inclination was significantly improved before and after the surgery

and found significant differences in SAAJI between the two groups. Furthermore, RI was used as an overall rating index to evaluate the reducibility degree, and the larger the RI, the greater the reducibility. In addition, this study found that these two radiographic parameters were significantly negatively correlated ( $P < 0.05$ ): the greater the SAAJI, the smaller the RI, and the less the reducibility. The study found that RI in the group that underwent simple posterior reduction and fixation plus bone graft internal fusion was  $>27.9\%$ , and the SAAJI was  $<32.5^\circ$ ; the patient as shown in Figure 3 had a preoperative RI of 34.29% and SAAJI of  $<32.5^\circ$ , and simple posterior surgical treatment achieved good reduction effects. However, RI in the combined anterior and posterior approach group was  $<27.9\%$  and SAAJI was  $>32.5^\circ$ ; as shown in Figure 4 (RI = 12.93% and SAAJI  $>32.5^\circ$ ), anterior cervical release would first be necessary, followed by posterior reduction and fixation to achieve satisfactory outcomes. Therefore, the above two parameters might provide important reference values to guide physicians in selecting among surgical approaches.

Limitations of this study are as follows. (1) Because many factors can affect AAD, there were fewer observation indicators in this study, and the conclusions might not fully reflect the extent of irreducibility; in the future, these should be analyzed from a 3D perspective to validate the conclusions of this study. (2) This was a retrospective study; due to the limitations of data integrity, the measurement of SAAJI used the neutral position, which might change in the cervical dynamic position. Thus, improved imaging data are needed to investigate the correlations between SAAJI and the extent of irreducibility in the cervical dynamic position. (3) The sample size in this study was small, and more cases are needed in the future; prospective studies should be designed to further validate the research conclusions.

### Conclusion

SAAJI and RI can be used as important imaging indicators to determine the reversibility of IAAD. If the RI value is  $>27.9\%$  and SAAJI value is  $<32.5^\circ$ , reduction and fixation can be achieved by the posterior approach

alone; otherwise, a combination of anterior and posterior approaches would be necessary.

### Declaration of patient consent

The authors certify that they have obtained all appropriate patient consent forms. In the form the patient(s) has/have given his/her/their consent for his/her/their images and other clinical information to be reported in the journal. The patients understand that their names and initials will not be published and due efforts will be made to conceal their identity, but anonymity cannot be guaranteed.

### Financial support and sponsorship

Research grants from the hospital are received in this work.

### Conflicts of interest

There are no conflicts of interest.

### References

- Goel A, Shah A. Atlantoaxial facet locking: Treatment by facet manipulation and fixation. Experience in 14 cases. *J Neurosurg Spine* 2011;14:3-9.
- Hoshino C, Narita M. Craniovertebral junction tuberculosis: A case report and review of the literature. *J Infect Chemother* 2010;16:288-91.
- Salunke P, Sahoo SK, Savardekar A, Ghuman M, Khandelwal NK. Factors influencing feasibility of direct posterior reduction in irreducible traumatic atlantoaxial dislocation secondary to isolated odontoid fracture. *Br J Neurosurg* 2015;29:513-9.
- Tan M, Jiang X, Yi P, Yang F, Tang X, Hao Q, *et al.* Revision surgery of irreducible atlantoaxial dislocation: A retrospective study of 16 cases. *Eur Spine J* 2011;20:2187-94.
- Salunke P, Sharma M, Sodhi HB, Mukherjee KK, Khandelwal NK. Congenital atlantoaxial dislocation: A dynamic process and role of facets in irreducibility. *J Neurosurg Spine* 2011;15:678-85.
- Yang J, Ma X, Xia H, Wu Z, Ai F, Yin Q. Transoral anterior revision surgeries for basilar invagination with irreducible atlantoaxial dislocation after posterior decompression: A retrospective study of 30 cases. *Eur Spine J* 2014;23:1099-108.
- Yadav YR, Madhariya SN, Parihar VS, Namdev H, Bhatle PR. Endoscopic transoral excision of odontoid process in irreducible atlantoaxial dislocation: Our experience of 34 patients. *J Neurol Surg A Cent Eur Neurosurg* 2013;74:162-7.
- Xia H, Yin Q, Ai F, Ma X, Wang J, Wu Z, *et al.* Treatment of basilar invagination with atlantoaxial dislocation: Atlantoaxial joint distraction and fixation with transoral atlantoaxial reduction plate (TARP) without odontoidectomy. *Eur Spine J* 2014;23:1648-55.
- Ai FZ, Yin QS, Xu DC, Xia H, Wu ZH, Mai XH. Transoral atlantoaxial reduction plate internal fixation with transoral transpedicular or articular mass screw of c2 for the treatment of irreducible atlantoaxial dislocation: Two case reports. *Spine (Phila Pa 1976)* 2011;36:E556-62.
- Zheng Y, Wu ZH, Yin YH, Yin QS, Zhang K. Treatment of irreducible atlantoaxial dislocation using the transoral atlantoaxial pedicle screw technique. A report of 10 cases. *Orthopade* 2016;45:174-9.
- Kerschbaumer F, Kandziora F, Klein C, Mittlmeier T, Starker M. Transoral decompression, anterior plate fixation, and posterior wire fusion for irreducible atlantoaxial kyphosis in rheumatoid arthritis. *Spine (Phila Pa 1976)* 2000;25:2708-15.
- Srivastava SK, Aggarwal RA, Nemade PS, Bhosale SK. Single-stage anterior release and posterior instrumented fusion for irreducible atlantoaxial dislocation with basilar invagination. *Spine J* 2016;16:1-9.
- Wang C, Yan M, Zhou HT, Wang SL, Dang GT. Open reduction of irreducible atlantoaxial dislocation by transoral anterior atlantoaxial release and posterior internal fixation. *Spine (Phila Pa 1976)* 2006;31:E306-13.
- Ma H, Dong L, Liu C, Yi P, Yang F, Tang X, *et al.* Modified technique of transoral release in one-stage anterior release and posterior reduction for irreducible atlantoaxial dislocation. *J Orthop Sci* 2016;21:7-12.
- Chandra PS, Goyal N. In reply: The severity of basilar invagination and atlantoaxial dislocation correlates with sagittal joint inclination, coronal joint inclination, and craniocervical tilt: A description of new indices for the craniovertebral junction. *Neurosurgery* 2015;76:E235-9.
- Laguerre D, Wavasseur T, Vital JM, Vignes JR. A disabling cervical compressive myelopathy with normal JOA score. *Clin Neurol Neurosurg* 2013;115:1147-9.
- Hirabayashi K, Miyakawa J, Satomi K, Maruyama T, Wakano K. Operative results and postoperative progression of ossification among patients with ossification of cervical posterior longitudinal ligament. *Spine (Phila Pa 1976)* 1981;6:354-64.
- Zou MX, Li J, Lv GH, Wang XB, Wang B. Atlantoaxial rotatory dislocation due to spasmodic torticollis. *Spine J* 2016;16:e543-4.
- Ren XF, Xi YM, Zhang GQ, Yang WJ, Zhang X, Yang DL, *et al.* Single-stage combined anterior retropharyngeal and posterior approach for the resection and reconstruction of C2 metastatic tumors: A case report. *Exp Ther Med* 2014;7:887-90.
- Jain VK. Atlantoaxial dislocation. *Neurol India* 2012;60:9-17.
- Yin QS, Wang JH. Current trends in management of atlantoaxial dislocation. *Orthop Surg* 2015;7:189-99.
- Wang S, Wang C, Yan M, Zhou H, Jiang L. Syringomyelia with irreducible atlantoaxial dislocation, basilar invagination and Chiari I malformation. *Eur Spine J* 2010;19:361-6.