

Successful Treatment of Congenital Lymphangioma Circumscriptum of the Vulva with CO₂ and Long-Pulsed Nd:YAG Lasers

Ryosuke Sasaki^{a, b} Kei Negishi^c Hirotaka Akita^b Kayoko Suzuki^a
Kayoko Matsunaga^b

^aDepartment of Dermatology, Kariya Toyota General Hospital, Kariya, ^bDepartment of Dermatology, Fujita Health University School of Medicine, Toyoake, and ^cAoyama Institute of Women's Medicine, Tokyo Women's Medical University, Tokyo, Japan

Key Words

Lymphangioma circumscriptum · Long-pulsed Nd:YAG laser · CO₂ laser

Abstract

A 16-year-old girl presented with a 9-year history of vesicles on the vulva. She had initially taken a wait-and-see approach, but required treatment because of bleeding. Histological examination of a biopsied vesicle revealed dilated lymph channels in the upper dermis, suggesting lymphangioma circumscriptum (LC). The challenge for this pathology has been to find a conservative treatment with low morbidity and better results than those reported for surgical excision, which has been the mainstay of therapy. In this case, LC of the vulva was successfully treated using a 10,600-nm CO₂ laser and long-pulsed Nd:YAG laser. Use of the 10,600-nm CO₂ laser and long-pulsed Nd:YAG laser appeared effective for treating LC.

© 2014 S. Karger AG, Basel

Introduction

Lymphangioma circumscriptum (LC) is a relatively rare, benign, congenital disorder of the lymphatic channels with a nonspecific etiology. Surgical excision, cryotherapy, electrocoagulation and laser treatments for this pathology have all been reported, but surgical excision remains the mainstay of treatment. While initially effective in general, surgery is invasive and recurrence has been reported. Cryotherapy appears rather ineffective, with low

Ryosuke Sasaki, MD
Department of Dermatology, Kariya Toyota General Hospital
5–15 Sumiyoshi-cho
Kariya 448-8505 (Japan)
E-Mail r-sasaki@fujita-hu.ac.jp

remission and high recurrence rates. Several reports have described treatment of LC using CO₂ lasers [1]. However, no previous reports have described LC treated with long-pulsed Nd:YAG lasers, or successful treatment using different lasers for similar lesions. We selected different types of lasers for the treatment: CO₂ lasers with their confirmed effectiveness and Nd:YAG lasers.

Case Report

A 16-year-old Japanese girl presented with a 9-year history of vesicles on both sides of the vulva (fig. 1). These lesions had developed at around 7 years of age and no treatment had been administered. The patient sought treatment at our hospital because of increased lymphatic leakage. Clinical examination revealed grouped vesicular lesions on the vulva, giving it a typical ‘frog spawn’ appearance. The medical history of the patient showed no other dermatologic or systemic abnormalities, and no family history of similar lesions was evident. A biopsy was taken from the middle of the affected area. Histopathologic examination revealed multiple thin-walled, dilated lymphatic spaces that contained lymphocytes and erythrocytes in the papillary dermis (fig. 2). Clinical and pathologic findings were consistent with a diagnosis of LC.

We decided to use different kinds of lasers for the right and left lesions. Once a month, we treated the right-side vulval lesion with a CO₂ laser (SHARPLAN 30C, Lumenis, Yokneam, Israel) and the left-side lesion with a long-pulsed Nd:YAG laser from the Xeo™ multi-platform device (Cutera, Brisbane, Calif., USA) under local anesthesia with 1% lidocaine plus 1:100,000 epinephrine. The CO₂ laser was set to a wavelength of 10,600 nm at 4 W with a 1-mm spot size. Visually confirming cauterization of lymphatic channels on the surface, we treated the lesions little by little every month, as treatment of a wide area in a single session may lead to ulceration. The long-pulsed Nd:YAG laser was set to a wavelength of 1064 nm with a fluence of 80–100 J/cm² at 20 or 30 ms and a 7-mm spot size. Energy and pulse length were adjusted to achieve only partial coagulation.

After the fourth session, the region on the right vulva treated with the CO₂ laser was greatly improved, with no lesions visible to the naked eye. The region on the left vulva was greatly improved after only 3 treatments using the Nd:YAG laser. The patient preferred the results from the Nd:YAG laser as lymphatic fluid discharge was temporarily increased (for 1 week) after each CO₂ laser irradiation, but stopped after Nd:YAG laser irradiation. However, the second session of irradiation with the Nd:YAG laser resulted in the development of a 4-mm linear scar after 1 week, which appeared as a slight textural change that disappeared within 3 months.

After completion of the laser treatment (4 sessions), the patient no longer needed to use incontinence diapers and her quality of life improved considerably. No recurrence has been detected yet, 2 years after the last treatment, although follow-up is continuing (fig. 3).

Discussion

LC is a relatively rare, benign, congenital disorder of the lymphatic channels with a nonspecific etiology. The disorder is characterized by groups of thin-walled vesicles [2]. These vesicles may sometimes become filled with blood, resulting in a ‘frog spawn’ appearance. Surgical excision, cryotherapy, electrocoagulation and laser treatments have all been reported as treatment modalities for LC [3]. Surgical excision is initially effective in

general, but it is invasive and recurrence has been reported [3]. Cryotherapy appears rather ineffective, with low remission and high recurrence rates. In terms of laser treatments, Wang et al. [4] reported the effectiveness of pulsed dye lasers in 2005. Lapidoth et al. [5] and Treharne et al. [1] obtained favorable results using a 900-nm diode laser and a CO₂ laser, respectively, in 2006. We therefore chose different types of lasers for treatment: CO₂ lasers, with their confirmed effectiveness, and Nd:YAG lasers, which were expected to achieve efficacy at least equivalent to that of the CO₂ lasers.

The 10,600-nm wavelength of the CO₂ laser is highly absorbed by water and evaporates skin tissue. CO₂ lasers are effective for treating lesions that can be visually located to minimize the resultant scar, although excessive use can result in ulceration. In comparison, the long-pulsed Nd:YAG laser is moderately absorbed by hemoglobin, melanin and water, and has been used to treat deep or thick dermal lesions such as hemorrhagic malformations of the skin, although visual confirmation of applicable lesions is impossible and there is a risk of de-pigmentation and scarring due to over-irradiation. Although both lasers have specific advantages and disadvantages, we considered long-pulsed Nd:YAG lasers as more effective than either CO₂ lasers or dye lasers for targeting deep lymphatic channels to prevent recurrence. As no previous reports have described LC treated with long-pulsed Nd:YAG lasers, we decided to use and compare both CO₂ and Nd:YAG lasers. No previous reports have described successful treatment using different kinds of lasers for similar lesions, particularly Nd:YAG lasers for the treatment of LC. As we expected, Nd:YAG lasers allowed safe and effective treatment. Laser settings and treatment endpoints depend on the experience of the physician. Laser treatment, if wrongly used, may cause adverse effects. However, we believe that employing different kinds of lasers was useful in this case. One year has passed since the final treatment, and the patient has experienced no recurrence. Unlike the many cases of recurrence that have been reported after surgical excision, both long-pulsed Nd:YAG lasers and CO₂ lasers appear effective for the treatment of LC and are less invasive than surgery.

Disclosure Statement

A long-pulsed Nd:YAG laser from Xeo multi-platform devices was borrowed from Cutera Inc.

References

- 1 Treharne LJ, Murison MS: CO₂ laser ablation of lymphangioma circumscriptum of the scrotum. *Lymphat Res Biol* 2006;4:101–103.
- 2 Flanagan BP, Helwig EB: Cutaneous lymphangioma. *Arch Dermatol* 1997;113:24–30.
- 3 Roy KK, Agarwal R, Agarwal S, et al: Recurrent vulval congenital lymphangioma circumscriptum – a case report and literature review. *Int J Gynecol Cancer* 2006;16:930–934.
- 4 Wang LC, Kronic AL, Medenica MM, et al: Treatment of hemorrhagic lymphatic malformation of the tongue with a pulsed-dye laser. *J Am Acad Dermatol* 2005;52:1088–1090.
- 5 Lapidoth M, Ackerman L, Amitai DB, et al: Treatment of lymphangioma circumscriptum with combined radiofrequency current and 900 nm diode laser. *Dermatol Surg* 2006;32:790–794.

Sasaki et al.: Successful Treatment of Congenital Lymphangioma Circumscriptum of the Vulva with CO₂ and Long-Pulsed Nd:YAG Lasers

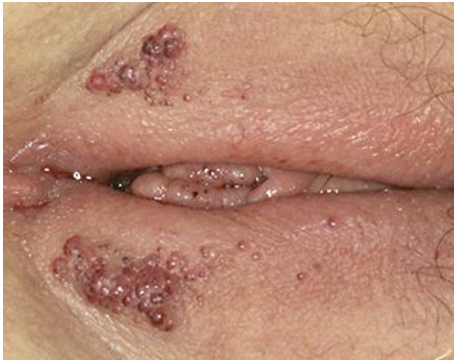

Fig. 1. Clinical appearance at initial presentation. Grouped vesicular lesions are visible on the vulva, showing a typical 'frog spawn' appearance.

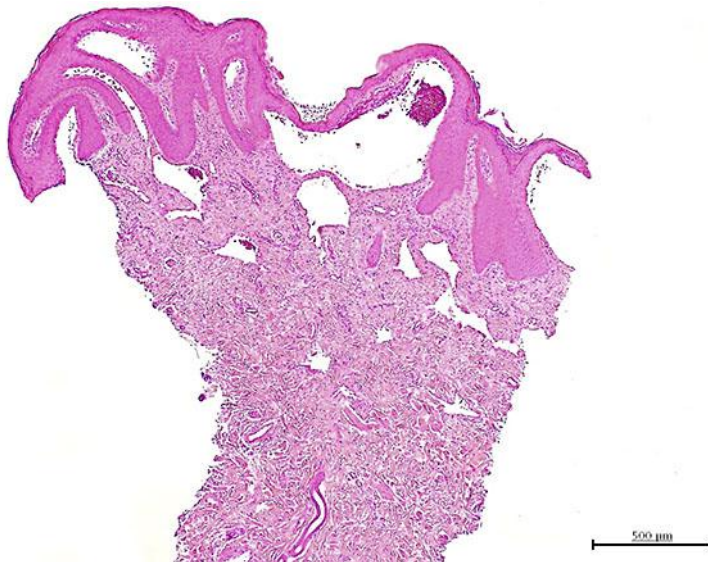


Fig. 2. Histopathologic analysis reveals multiple thin-walled, dilated lymphatic spaces within the papillary dermis. Hematoxylin and eosin staining at low magnification.

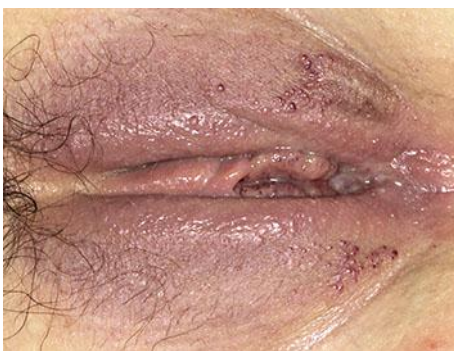

Fig. 3. Clinical appearance after final laser treatments. No recurrence has occurred after 2 years, but follow-up is continuing.