



HHS Public Access

Author manuscript

Indian J Ophthalmol Case Rep. Author manuscript; available in PMC 2021 July 26.

Published in final edited form as:

Indian J Ophthalmol Case Rep. 2021 ; 1(2): 383–385. doi:10.4103/ijo.ijo_1982_20.

Ophthalmic artery occlusion due to orbital compartment syndrome after a frontotemporal craniotomy

Lauren DeMaria¹, Ann Q Tran^{1,2}, Andrea A. Tooley^{1,2}, Aliaa Abdelhakim^{1,3}, Irina Belinsky¹, Eleanore Kim¹

¹Department of Ophthalmology, New York University, New York, NY, USA

²Department of Ophthalmology, Manhattan Eye, Ear, and Throat Hospital, Northwell Health, New York, NY, USA

³Department of Ophthalmology, Columbia University, New York, NY, USA

Abstract

A 32-year-old female with a right frontal lobe glioma underwent an elective frontotemporal craniotomy. One hour postoperatively, the patient developed a right orbital compartment syndrome (OCS) with unilateral acute vision loss, proptosis, afferent pupillary defect, and complete ophthalmoplegia. The patient underwent emergent lateral canthotomy and inferior cantholysis. Neuroimaging revealed extensive vascular congestion along the extraocular muscles at the orbital apex. Retinal imaging demonstrated an ophthalmic artery occlusion. OCS following a frontal or frontotemporal craniotomy relates to increased orbital venous congestion from direct compression of the myocutaneous flap and subsequent intraorbital pressure elevation, vascular compromise, and ocular ischemia.

Keywords

Craniotomy; frontotemporal craniotomy; ophthalmic artery occlusion; orbital compartment syndrome

Acute vision loss after a craniotomy is an uncommon event, occurring in about 10% of cases from orbital roof defects, manipulation of the optic nerve, or manipulation of the ophthalmic artery.^[1,2] In rare cases, irreversible vision loss can occur from orbital compartment syndrome (OCS).^[3–5] The etiology is related to the reflected myocutaneous flap

For reprints contact: WKHLRPMedknow_reprints@wolterskluwer.com This is an open access journal, and articles are distributed under the terms of the Creative Commons Attribution–NonCommercial–ShareAlike 4.0 License, which allows others to remix, tweak, and build upon the work non-commercially, as long as appropriate credit is given and the new creations are licensed under the identical terms.

Correspondence to: Dr. Lauren DeMaria, New York University, 222 East 41st Street, 3rd Floor, New York, NY - 10017, USA. lauren.demaria@nyumc.org.

Declaration of patient consent

The authors certify that they have obtained all appropriate patient consent forms. In the form the patient(s) has/have given his/her/their consent for his/her/their images and other clinical information to be reported in the journal. The patients understand that their names and initials will not be published and due efforts will be made to conceal their identity, but anonymity cannot be guaranteed.

Conflicts of interest

There are no conflicts of interest.

inadvertently compressing the orbit and inducing vascular congestion. Herein, the authors present an ophthalmic artery obstruction and unilateral OCS following a frontotemporal craniotomy with a bicoronal myocutaneous flaps. This case was reported in compliance with the Health Insurance Portability and Accountability Act and adheres to the Declaration of Helsinki.

Case Report

A 32-year-old female with a frontal lobe glioma underwent a right frontal craniotomy [Fig. 1a]. The patient's head was tilted to the right in a supine position using a Mayfield three-pin fixation device. Bicoronal myocutaneous flaps were reflected anteriorly and secured with fishhooks over the orbit. A wedge resection involving the superior frontal gyrus, orbital gyrus, and gyrus rectus was performed. The craniotomy was closed with titanium miniplates and screws and staples to the scalp with a Jackson-Pratt drain placed. The surgery lasted 8 h without direct manipulation to the optic strut, orbital roof, or orbital apex.

Upon awakening, the patient developed right ocular injection and mild extraocular restriction. Within an hour, the symptoms progressed to periorbital swelling, proptosis, complete ophthalmoplegia, and vision loss. The patient's visual acuity declined from hand motion to light perception. The intraocular pressure was 53 mmHg with a brisk relative afferent pupillary defect. Posterior examination demonstrated a perfused optic disc without frank edema. The patient underwent an inferior canthotomy and cantholysis and was given 1 g of intravenous acetazolamide, topical latanoprost, timolol, dorzolamide, and brimonidine [Fig. 2]. Computed tomography (CT) of the orbits illustrated extensive enlargement of the extraocular muscles extending to the right orbital apex [Fig. 1b]. Subsequent magnetic resonance imaging of the orbits revealed persistent swelling of the extraocular muscles and mild enhancement of the intraorbital optic nerve [Fig. 1c and d].

Despite 3 days of 1 g of intravenous methylprednisolone, the patient's vision deteriorated to no light perception (NLP). Repeat posterior examination 24 h later demonstrated a pale fundus with scattered dot–blot hemorrhages and blurred disc margins. Optical coherence tomography and fundus images demonstrated diffuse retinal edema that eventually progressed to retinal and choroidal atrophy over 3 months [Fig. 3a–c]. The right eye remained NLP with persistent complete ophthalmoplegia 3 months later.

Discussion

OCS after a craniotomy surgery is a rare and devastating event. The majority of cases describe bilateral OCS following a bifrontal craniotomy or unilateral OCS after an ipsilateral frontal or frontotemporal craniotomy.^[3–5] Patients at risk of postoperative OCS are those with a larger degree of preoperative proptosis and those undergoing aneurysm repair.^[6] In cases of OCS with aneurysm repairs, vision loss does not result from direct injury to the ophthalmic artery.^[6]

Previously, “orbital infarction syndrome” was thought to occur secondary to a sudden decrease in intracranial pressure and vasoregulatory mechanisms.^[7] This resulted in acute orbital hypoperfusion and vascular insult to the ophthalmic artery. Nonetheless, due to

anastomoses of the ophthalmic artery with the external carotid arteries, orbital ischemia usually develops from hypoperfusion of its terminal branches.^[5] Thus, posterior ischemic optic neuropathy and central retinal artery occlusion are possible consequences of this vascular compromise.^[4]

Recent studies have investigated causes of increased intraorbital pressure and vascular compromise from external surgical factors. Direct compression of the globe from the myocutaneous flap can increase orbital venous congestion, compromise perfusion pressure, and eventually cause compressive optic neuropathy and related artery occlusions.^[8] Specifically, venous congestion of the supraorbital vein from the coronal flap propagated to the superior ophthalmic vein leading to compression and hypoperfusion of the ophthalmic artery at the orbital apex. Additionally, the flap traction can compress orbital contents, impair venous outflow, and collapse intraorbital perfusion.^[6] Propagation of pericranial edema from the resulting flap may also play a role. In the authors' presented case, tension from the fishhooks stabilizing the bilateral myocutaneous scalp resulted in elevated intraorbital pressure and impaired orbital venous outflow. The patient's right head tilt in the supine position contributed to additional gravitational effects worsening the periorbital edema to the right side, explaining the possibility of why the left eye was unaffected. This resulted in rapidly engorged extraocular muscles, increased intraorbital pressure, and compressive effect of the optic nerve and ophthalmic artery. Although additional mechanisms contributing to ophthalmic artery occlusion were not ruled out, the clinical and radiographical evidence supports OCS as the main contributing factor for the patient's acute ocular deterioration.

Special consideration intraoperatively can help minimize the risk. Standard neurosurgical positioning precautions can decrease the tension on the orbit such as stretching the skin flap 30–45 degrees from the horizontal plane.^[6,9,10] Minimizing surgical hooks to retract the scalp can decrease the amount of intraorbital pressure. Frequent eye checks to assess intraorbital pressure should be considered. The use of an eye shield instead of a bulky gauze between the eye and the scalp can assure more adequate ocular protection.^[9]

Conclusion

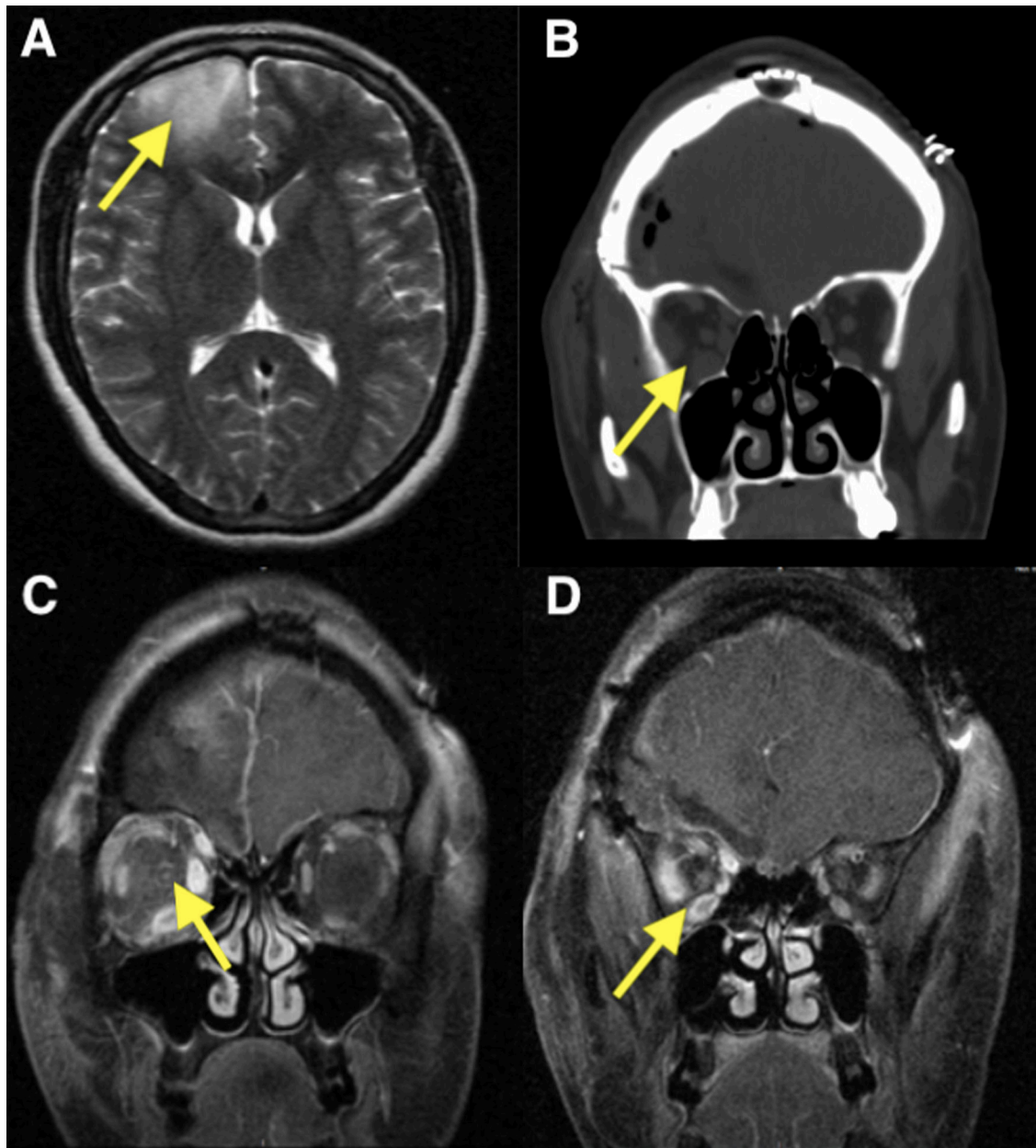
While unilateral or bilateral vision loss due to OCS is a rare sequela of a frontal or frontotemporal craniotomy, neurosurgeons and ophthalmologists should be aware of this possible complication. The authors present a unique case of unilateral vision loss and complete ophthalmoplegia that resulted from bicoronal myocutaneous flaps. Prevention measures should be taken to avoid direct ocular pressure from the myocutaneous scalp flap, minimize pericranial congestion from head positioning in a supine position, and ensure adequate intraoperative eye protection.

Acknowledgments

This research was supported in part by an Unrestricted Grant from Research to Prevent Blindness to NYU Langone Health Department of Ophthalmology.

References

1. Habets JGV, Haeren RHL, Lie SAN, Bauer NJC, Dings JTA. Acute monocular blindness due to orbital compression syndrome following pterional craniotomy. *World Neurosurg* 2018;114:72–5. [PubMed: 29545222]
2. Rizzo JF III. Visual loss after neurosurgical repair of paraclinoid aneurysms. *Ophthalmology* 1995;102:905–10. [PubMed: 7777297]
3. Takahashi Y, Kakizaki H, Selva D, Leibovitch I. Bilateral orbital compartment syndrome and blindness after cerebral aneurysm repair surgery. *Ophthalmic Plas Reconstr Surg* 2010;26:299–301.
4. Vahedi P, Meshkini A, Mohajernezhadfar Z, Tubbs RS. Post-craniotomy blindness in the supine position: Unlikely or ignored? *Asian J Neurosurg* 2013;8:36–41. [PubMed: 23741261]
5. Maier P, Felgen N, Lagreze WA. Bilateral orbital infarction syndrome after bifrontal craniotomy. *Arch Ophthalmol* 2007;125:442–3.
6. Pahl FH, de Oliveira MF, Dal Col Lucio JE, Souza E Castro EF. Orbital compartment syndrome after frontotemporal craniotomy: Case report and review of literature. *World Neurosurg* 2018;109:218–21. [PubMed: 28987826]
7. Beck RW, Greenberg S. Post-decompression optic neuropathy. *J Neurosurg* 1985;63:196–9. [PubMed: 4020442]
8. Gauden AJ, Hardy T, Mack HV, Danesh-Meyer HV, Kaye AH. Orbital compartment syndrome following aneurysm surgery. *J Clin Neurosci* 2012;19:1032–6. [PubMed: 22555128]
9. Kim TS, Hur JW, Park DH, Kang SH, Park JY, Chung YG, et al. Extraocular pressure measurement to avoid orbital compartment syndrome in aneurysm surgery. *World Neurosurg* 2018;118:e601–9. [PubMed: 29990603]
10. Choudhari KA, Pherwani AA. Sudden visual loss due to posterior ischemic optic neuropathy following craniotomy for a ruptured intracranial aneurysm. *Neurol India* 2007;55:163–5. [PubMed: 17558125]

**Figure 1:**

(a) Preoperative MRI highlighting the right frontal lobe glioma without involvement of the orbit. (b) Postoperative coronal CT revealing significantly enlarged right extraocular muscles at the orbital apex. (c) Postoperative T2 coronal MRI with contrast revealing enhancement of intraorbital portion of the right optic nerve and (d) engorged extraocular muscles at the right orbital apex

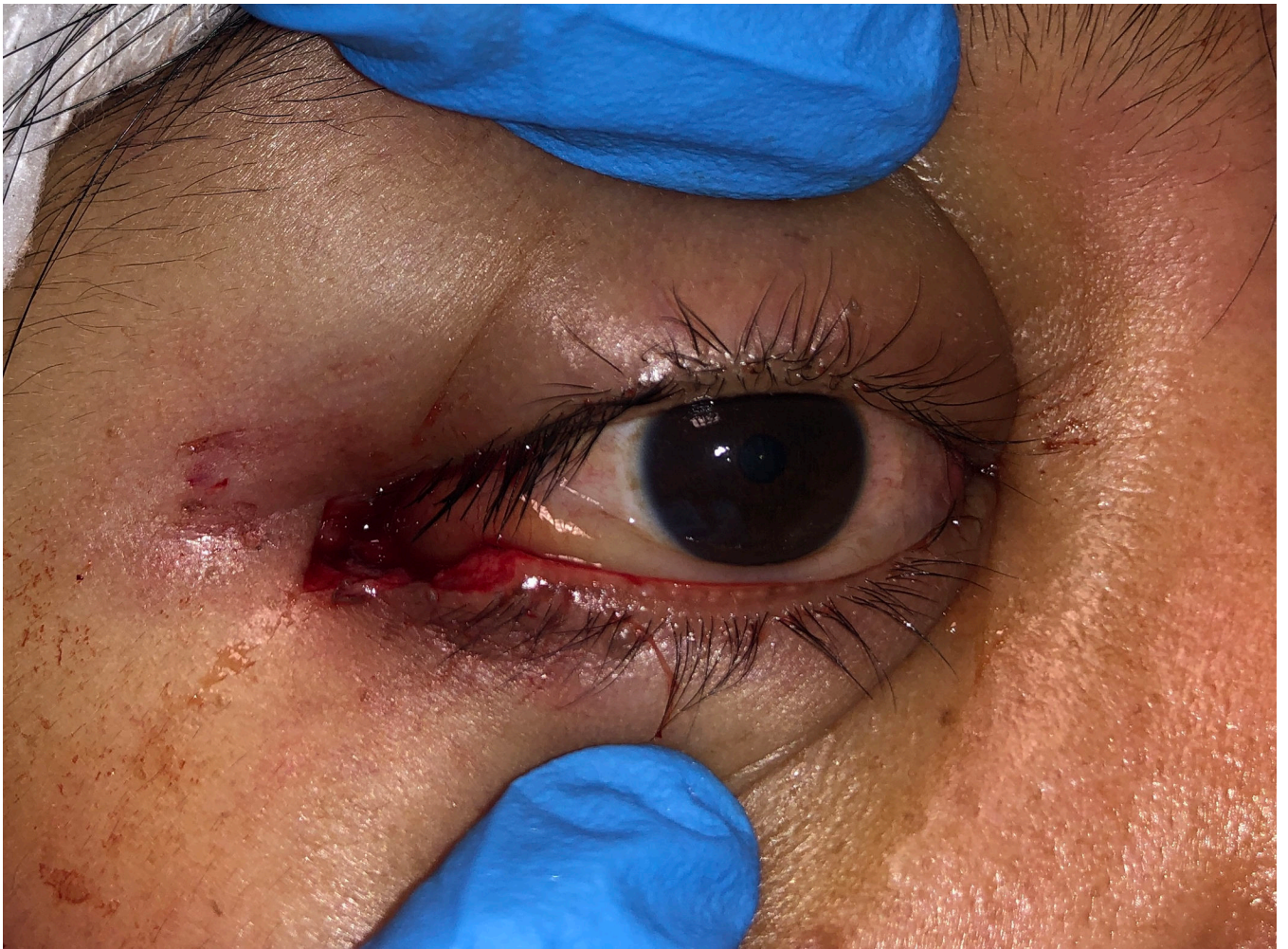

Figure 2:
External photography of the patient's right eye after canthotomy and inferior cantholysis, demonstrating periorbital swelling, proptosis, and ophthalmoplegia

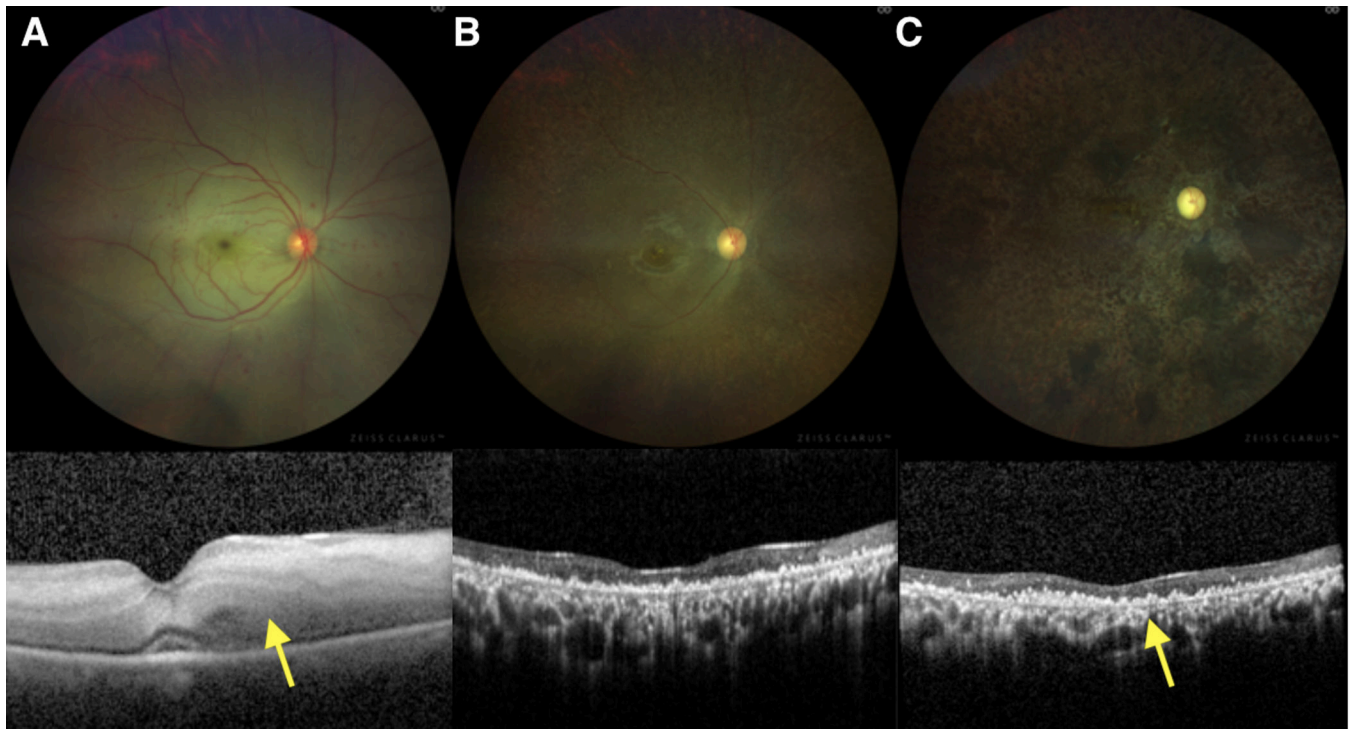


Figure 3: Fundus and OCT photos of the right eye at postoperative (a) week 1, (b) month 2, (c) and month 3 highlighting initial diffuse retinal swelling with eventual development of choroidal and retinal atrophy