

Chronic extensor hallucis longus tendon rupture treated with double-bundle autograft of extensor hallucis capsularis: A case report

SAGE Open Medical Case Reports
Volume 7: 1–6
© The Author(s) 2019
Article reuse guidelines:
sagepub.com/journals-permissions
DOI: 10.1177/2050313X19841962
journals.sagepub.com/home/sco



Toshinori Kurashige 

Abstract

The extensor hallucis capsularis is an accessory extensor tendon with varied occurrence. Here, we present the case of a 40-year-old man with chronic extensor hallucis longus tendon rupture treated using extensor hallucis capsularis tendon as a double-bundle autograft. He had dropped a knife proximal to the right hallux metatarsophalangeal joint 4 months ago. Computed tomography revealed the presence of extensor hallucis capsularis, with its width and thickness, and the point of divergence from the extensor hallucis longus tendon. Because direct suturing was considered difficult and the extensor hallucis capsularis tendon was sufficiently wide and long, double-bundle autograft transplantation of extensor hallucis capsularis was performed. At 1-year follow-up examination, the patient retained almost full function of his hallux. To the best of our knowledge, this is the first case to use this technique. Using the extensor hallucis capsularis tendon for grafting should be carefully considered because the variable width and length may limit the graft strength.

Level of evidence: IV

Keywords

Double-bundle autograft, extensor hallucis longus tendon, extensor hallucis capsularis, rupture, tendon graft

Date received: 21 November 2018; accepted: 14 March 2019

Introduction

The use of primary suturing for the treatment of chronic extensor hallucis longus (EHL) tendon ruptures is challenging owing to the contracture or degeneration of the ruptured tendon; therefore, reconstructive surgery using a tendon graft or tendon transfer has commonly been used. Typically, the extensor digitorum longus (EDL) tendon, semitendinosus, gracilis or peroneus longus have been used for tendon autografts, and the EDL tendon to the second toe is used for tendon transfer.^{1–6} However, these procedures are invasive because the original function is sacrificed.

The extensor hallucis capsularis (EHC) is an accessory extensor tendon that is frequently observed at the medial side of the EHL tendon.⁷ Most EHC tendons originate from the EHL tendon and insert into the first metatarsophalangeal (MTP) joint capsule. The use of the EHC tendon as a graft has been suggested in various orthopaedic reconstructive procedures.^{8–11} Here, we present the case of a 40-year-old man with chronic EHL rupture treated using EHC as a double-bundle autograft.

The work has been approved by the appropriate ethical committees related to the institution in which it was performed and that subject gave informed consent to the work.

Case report

A healthy 40-year-old male cook had been wounded by a kitchen knife dropped proximal to the right hallux MTP joint. He had received treatment at another facility and the treating physician had only closed the skin. The wound was infected and treated using oral antibiotics and repeated irrigations at another clinic. The wound had healed after 2 weeks. Approximately 3 months after the initial trauma, the patient noted dysfunction in dorsiflexion of the hallux and was referred to our department. An EHL tendon rupture was suspected (Figure 1). Both physical and ultrasound examinations confirmed an approximately 5 cm long defect in the tendon.

Magnetic resonance imaging (MRI) revealed the loosening of the EHL tendon (Figure 2). Unfortunately, we were unable to evaluate the EHC in the MRI because of the

Department of Orthopaedic Surgery, Chiba Aiyukai Memorial Hospital, Nagareyama, Japan

Corresponding Author:

Toshinori Kurashige, Department of Orthopaedic Surgery, Chiba Aiyukai Memorial Hospital, 1-1, Hiregasaki, Nagareyama City, Chiba 270-0161, Japan.
Email: to-kurashige@chibaaiyu-kai.com



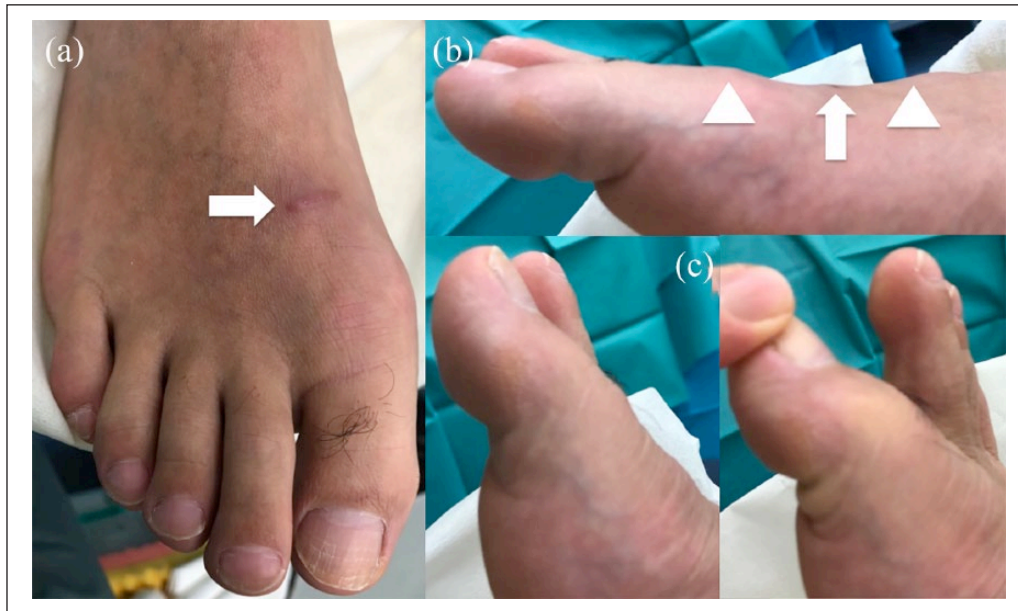


Figure 1. Preoperative macroscopic findings: (a) Injury scar immediately proximal to the metatarsophalangeal joint (arrow), (b) distal and proximal extensor hallucis longus stumps (arrow heads) and (c) insufficient extension of metatarsophalangeal and interphalangeal joints of the hallux.

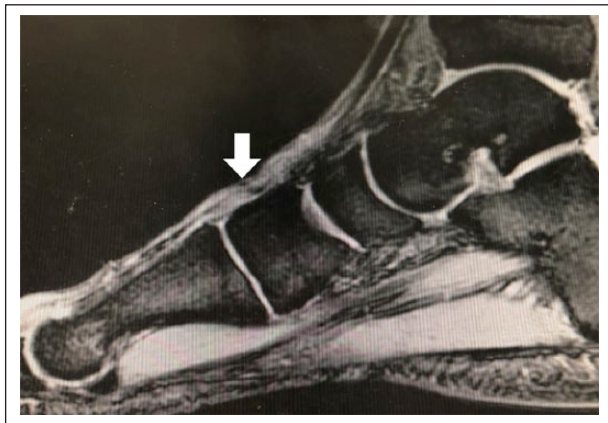


Figure 2. Preoperative magnetic resonance imaging (MRI) findings. Sagittal T2-weighted MRI revealed the loosening of the extensor hallucis longus tendon (arrow). Extensor hallucis capsularis was not evaluated in the forefoot and midfoot areas because of inappropriate MRI scan area.

inappropriate scan area. Computed tomography (CT) images revealed the presence of an EHC tendon medial to the proximal stump of the EHL tendon (Figure 3). Its width and thickness were approximately 3 and 2 mm, respectively. The point of divergence from the EHL appeared to be 2 cm distal to the first tarsometatarsal (TMT) joint.

In cases wherein direct suturing of the EHL is challenging to perform because of the large defect, performing tendon transplantation would be essential. However, tendon transfer necessitates the sacrifice of the healthy tendon. In addition, in cases wherein the infection recurred, the healthy tendon

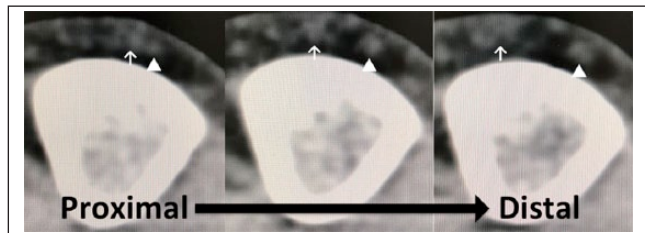


Figure 3. Preoperative computed tomography (CT) image findings. Coronal CT images revealed the extensor hallucis capsularis (EHC) (arrow heads) medial to the proximal stump of the extensor hallucis longus (EHL) tendon (arrow). The width and thickness of EHC were approximately 3 and 2 mm, respectively. The EHC tendon separated from the EHL tendon distal to the tarsometatarsal joint and travelled alongside. Preoperatively, this was considered the point of divergence of the EHC and EHL, but it was the adhesion intraoperatively.

might be wasted. Therefore, it was decided to attempt turn-down reconstruction of the EHL and reinforcement using EHC.¹² Surgery was performed approximately 4 months after the initial trauma.

Surgical technique

The patient was placed in the supine position. Although a thigh tourniquet was applied to the injured extremity, it was not used. A dorsal longitudinal incision was made and carried down to the tendon sheath along the route of the EHL from the level of the MTP joint to the proximal EHL stump. There was no sign of infection. The extensor hallucis brevis

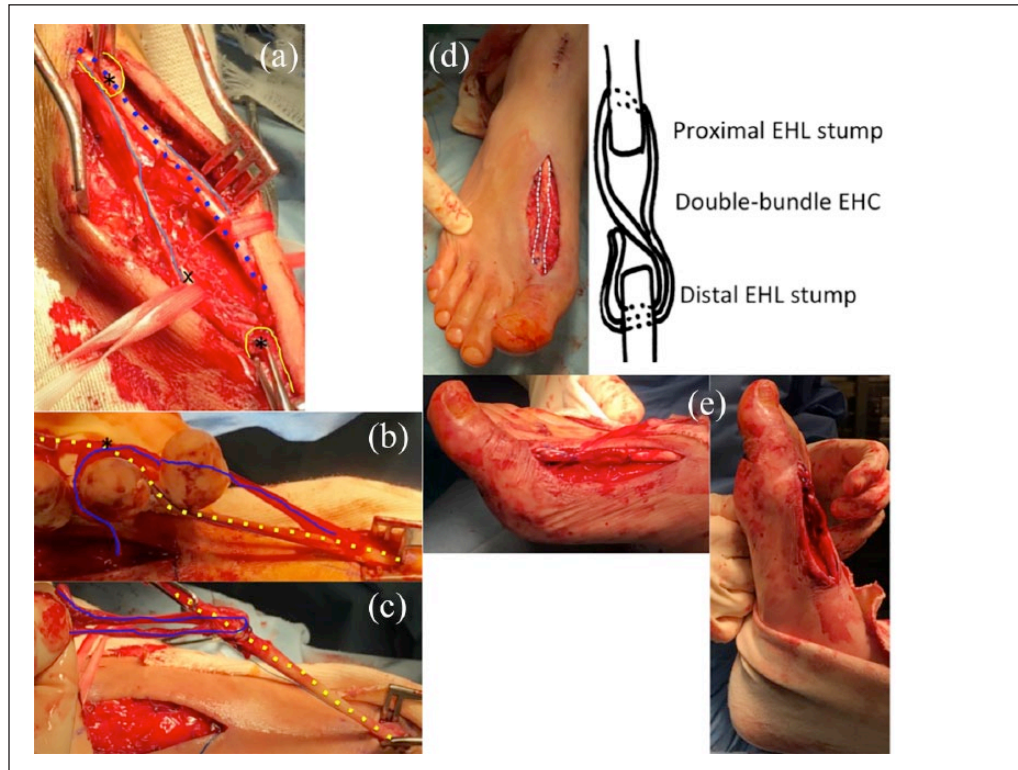


Figure 4. Intraoperative findings: (a) The proximal and distal extensor hallucis longus (EHL) stumps (asterisks) following the incision of the tendon sheath and the distal part of the inferior extensor retinaculum (solid lines). The gap between stumps was 5 cm. Thick extensor hallucis capsularis (EHC) (dotted line) was found medial to the EHL. The extensor hallucis brevis was intact (X). (b) Retrieved EHL (dotted line) and EHC (solid line) at the proximal wound. EHC arising from the distal end of the EHL muscle adhered to the EHL tendon (asterisk). (c) EHC (solid line) was resected from its origin and turned down at the point of adhesion to EHL (dotted line). (d) A double-bundle EHC autograft was sutured to the distal EHL stump in an interlacing manner. The double-bundle graft of EHC was slightly thinner than that of EHL; however, if we used a turn-down reconstruction of EHL, it must have been thinner than the double-bundle graft. Schematic diagram shows the design of the double-bundle EHC autograft for EHL reconstruction. (e) The first metatarsophalangeal and interphalangeal joints were slightly flexed at ankle dorsiflexion and slightly extended at ankle plantarflexion following suturing.

(EHB) tendon lateral to the EHL tendon sheath was intact. The distal EHL stump was easily visualized. After incising the distal part of the inferior extensor retinaculum, the proximal EHL stump was visualized adhered to the retinaculum. The gap between the stumps was 5 cm at that time (Figure 4(a)). After maximally mobilizing the proximal EHL, a 3 cm defect of the EHL was noted; this was difficult to treat using direct suturing. The EHC tendon was found medial to the EHL tendon and inserting the dorsomedial region of the first MTP joint capsule. On preoperative CT, it initially appeared to be originating from the EHL tendon under the inferior extensor retinaculum. On tightly pulling the proximal EHL stump, the location of the EHL tendon at the ankle was palpable. Another short longitudinal incision immediately anterior to the palpable tendon was made and carried down to the superior extensor retinaculum. Observation by slightly pulling out the EHL tendon in the proximal wound exposed an accessory tendon posterior to this tendon. After marking the distal EHL stump using 2-0 nylon, EHC tenotomy was performed at its insertion. EHL and EHC were retrieved at the

proximal wound. The end of the string was retained at the distal wound via the extensor retinaculum. The EHL tendon was pulled distally in the proximal wound, which revealed that the EHC arose from the distal end of the EHL muscle and adhered to the EHL tendon under the portion of the inferior retinaculum (Figure 4(b)). The EHC width was determined to be 3 mm distally and 4 mm proximally and its thickness and length was approximately 2–3 mm and 16 cm, respectively. The width and thickness of the EHL were approximately 5–6 and 3–4 mm, respectively. We considered that the EHC had sufficient width and length to use as a double-bundle autograft. Therefore, it was resected from its origin and turned down at the point of adhesion to the EHL (Figure 4(c)). The adhesion site was strengthened using knotted sutures. The tendons were passed via the extensor retinaculum to the distal wound using the marking string and sutured to the distal EHL stump in an interlacing manner. Thereafter, the EHC was sutured alongside as a double-bundle autograft (Figure 4(d)). The sutures were carefully placed in a manner that the first MTP and interphalangeal (IP) joints

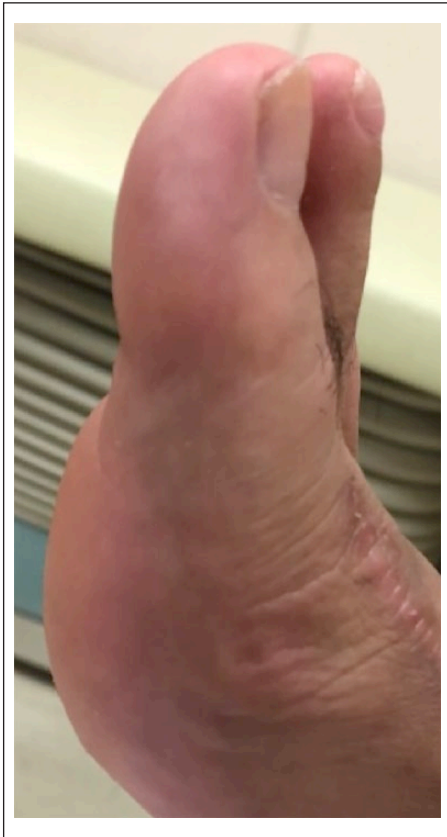


Figure 5. Postoperative macroscopic findings. The active range of dorsiflexion of the hallux 1 year after surgery.

were slightly flexed at ankle dorsiflexion and slightly extended at ankle plantarflexion (Figure 4(e)). The incisions were closed in layered fashion.

A lower leg cast was applied with the ankle in a neutral position with 20° of dorsiflexion of the first MTP joint. The patient was allowed to walk with crutches according to his tolerance postoperatively. To prevent tendon adhesion, passive dorsiflexion of the hallux was initiated on the next day of surgery. After 4 weeks, a short-leg splint was applied to avoid plantarflexion for another 2 weeks, and the patient was initiated on range of motion (ROM) exercises at the ankle, subtalar, first IP and MTP joint. However, he exhibited poor compliance to the rehabilitation of the tendon function. The patient removed the short-leg splint immediately and never visited the outpatient department on scheduled days postoperatively. In addition, discharge from the proximal wound continued for approximately 2 months, although cultures of the incision have been always negative. The wound was superficial and was treated using oral antibiotics. It was considered a superficial infection or a reaction to absorbable sutures. At 4 months after surgery, he visited our department and complained of severe tenderness at the middle point of the distal wound and numbness in the web space between the first and second toes. It was considered due to adhesion of the nerve and improved by single steroid and lidocaine injection following careful sterilization. At the 1-year follow-up

examination, the extension power of the hallux on the affected side was normal according to the manual muscle strength test. ROM was slightly decreased (Figure 5). The patient could extend 0° on the right and 5° on the left in IP joints. In MTP joint, active extension measured between metatarsal and proximal phalanx was 35° on the right and 45° on the left. The preoperative American Orthopaedic Foot and Ankle Society (AOFAS) hallux MTP scale¹³ was 74/100 and improved to 82/100 at the 1-year follow-up examination. In AOFAS scale, 'Pain' scores reported were 30 pre- and postoperatively, owing to occasional pain. The 'Footwear requirement' scores were 5 pre- and postoperatively due to slight tenderness on the scar; however, as the strength of EHL improved, 'Activity limitation' scores improved from 7 to 10 and 'MTP-IP stability' scores improved from 0 to 5 postoperatively. The patient experienced slight tenderness at the middle point of the distal wound but returned to his work without any difficulty at 1 year after surgery. He was satisfied with the result.

Discussion

In cases of chronic EHL tendon ruptures (≥ 6 weeks), primary suturing is challenging owing to the contracture or degeneration of the ruptured tendon; therefore, reconstructive surgery using a tendon graft or tendon transfer has commonly been used. EDL tendon, semitendinosus, gracilis, split peroneus longus or split EHL have been used for tendon autograft and EDL to the second toe for tendon transfer.¹⁻⁶ Although very few reports have been published regarding the reconstructing of chronic EHL tendon ruptures, almost all have demonstrated fair to good outcomes.^{1,4-6,12} However, the use of autograft could be associated with donor site morbidity that results in pain and dysfunction. Using the split EHL tendon lengthening technique, the width of autograft tendon will be half of that of the EHL tendon.^{4,12} In the tendon transfer involving the use of the EDL tendon to the second toe, the direction of the traction force would change. Furthermore, although allografts have advantages and disadvantages, their use in Japan is challenging owing to several restrictions.

The EHC is an accessory extensor tendon that is frequently observed at the medial side of the EHL tendon.⁷⁻¹¹ The reported occurrence of EHC varied in the literature, ranging from 81% to 98.3% in four studies published within the past 15 years.⁸⁻¹¹ Most EHCs (92%–93%) originated from the EHL tendon or muscle, whereas 3%–8% originated from the tibialis anterior tendon or muscle and 1% from the EHB tendon. EHC travels alongside the EHL tendon, passing beneath the superior and inferior extensor retinacula and entering the EHL tendon sheath together before the EHC turns medially. The EHC inserts into the dorsomedial region of the first MTP joint capsule in 99%–100% and into the base of the proximal phalanx in 1%.

Bibbo et al.⁸ have considered that EHC was absent in approximately 20% of specimens, and considering its small size, a clinically significant function of the tendon was

questionable. On the contrary, Bayer et al.¹⁰ have stated that EHC is believed to pull the MTP capsule away from the MTP joint during dorsiflexion to avoid capsular impingement.

The mean EHC widths range from 1.6 to 2 mm. Boyd et al.⁹ have reported that all EHC tendons were ≤ 4 mm in width, with only 16% being >2 mm wide. The reported mean EHC length was 11.3 ± 4.0 cm by Jarusriwanna et al.¹¹ and 10.8 cm by Boyd et al.⁹ According to Bayer et al.,¹⁰ the mean EHC thickness was 0.9 mm (range, 0.5–1 mm). In the current case, the width, length and thickness of the EHC were 3–4 mm, 16 cm and 2–3 mm, respectively.

EHC has been described in the orthopaedic literature as a possible source of graft material for autogenous tendon transfers, small ligament reconstructions and interpositional arthroplasty, particularly in surgeries related to hallux dysfunction.^{8–11} However, Boyd et al.⁹ have reported that up to 14% of the population may have an EHC tendon suitable for grafting in such surgeries. To the best of our knowledge, only one case by Eagand et al.¹⁴ has been reported. They treated a great toe claw deformity due to compartment syndrome. They transferred the resected EHB to the EHC to reinforce the z-lengthened EHL tendon. In the current case, the EHC had sufficient width, thickness and length that facilitated its use as a double-bundle autograft. To the best of our knowledge, this is the second report that used EHC for reconstruction of EHL function and the first report that used EHC as an autograft.

Compared with other graft and tendon transfer procedures, EHC autograft technique has certain advantages, such as no donor site morbidity, shorter operative time and few incisions. Unlike tendon transfer, the direction of the traction force would remain unchanged. Because the EHL tendon is retained, EHL may be used as a split tendon graft⁷ for reconstruction in cases of recurrence of rupture.

In previous reports, ROM after tendon graft or tendon transfer was from -22° to approximately the same compared with the healthy side in the MTP joint.^{1,4–6,12} Although few reports on ROM in the IP joints are available, Matsuda et al.¹² have reported it as -5° compared with the healthy side postoperatively. In the current case, at the 1-year follow-up examination, active extension measured between metatarsal and proximal phalanx was 35° and 45° on the affected and healthy sides, respectively, and that measured in the IP joints was 0° and 5° on the affected and healthy sides. Previous studies have reported that the extension power of the great toe after tendon graft or tendon transfer was from slightly decreased to full strength.^{1,4–6,12} In the current case, although both MTP and IP joints had flexion contractures, the extension power on the affected side was normal. These results were consistent with those of previous reports, despite the patient exhibiting poor compliance to rehabilitation exercises of the tendon function postoperatively.

The major issue associated with the EHC autograft technique is whether EHC can be used as a tendon graft. Preoperative knowledge of the tendon size may help surgeons decide whether to use EHC for cases wherein tendon graft is

required during foot surgery. Boyd et al.⁹ have evaluated six cadaver legs to determine the frequency of its occurrence and the width between the TMT joint and distal metatarsals using a 1.5T MRI scanner. They have concluded that the accurate prediction of the presence or absence of EHC using MRI varied according to EHC width of >2 mm. The wider the EHC tendon and greater its potential clinical relevance, the more likely it is to be identified on MRI. They did not investigate the origin and the point of divergence of the EHC from the EHL using MRI. In the current case, MRI was not useful for assessing EHC because of the inappropriate scan area. However, CT revealed the presence of EHC, with its width and thickness, and the point of divergence from the EHL tendon. MRI and CT may be useful modalities for evaluating the presence and width of EHC. However, both MRI and CT were unable to reveal the appropriate useful length of EHC preoperatively. Bibbo et al.⁸ have reported that the average free length of the EHC was 5.5 cm; however, the EHC and EHL tendons could be dissected from one another at a mean distance of 16.9 cm (range, 12.4–27.5 cm). Therefore, the length of EHC may be a less important factor to assess its use as an autograft. Our patient was 176 cm tall, and his EHC tendon was 16 cm in length from the origin to insertion. Therefore, we were able to use an 8 cm double-bundle autograft of EHC. In our opinion, this technique is limited for reconstruction of <5 cm defect of the EHL tendon. Further investigation is warranted to accurately evaluate the EHC preoperatively to facilitate its use as an autograft.

In conclusion, we present a case of a patient with chronic EHL rupture treated using EHC as a double-bundle autograft. At the 1-year follow-up examination, the patient retained almost full function of his hallux. To the best of our knowledge, this is the first report to use EHC as an autograft for the reconstruction of EHL tendon. CT revealed the presence of EHC, with its width and thickness, and the point of divergence from the EHL preoperatively, but not useful length. The application of the EHC tendon as an autograft should be carefully considered because the variable width and length may limit the graft strength.

Acknowledgements

The authors would like to thank Enago (www.enago.jp) for the English language review.

Declaration of conflicting interests

The author(s) declared no potential conflicts of interest with respect to the research, authorship and/or publication of this article.

Ethical approval

Ethical approval to report this case was obtained from Institutional Review Board.


Funding

The author(s) received no financial support for the research, authorship and/or publication of this article.

Informed consent

Written informed consent was obtained from the patient(s) for their anonymized information to be published in this article.

ORCID iD

Toshinori Kurashige  <https://orcid.org/0000-0001-9081-3272>

References

1. Park HG, Lee BK and Sim JA. Autogenous graft repair using semitendinosus tendon for a chronic multifocal rupture of the extensor hallucis longus tendon: a case report. *Foot Ankle Int* 2003; 24: 506–508.
2. Navadgi BC, Shah N, Jeer PJ, et al. Rupture of extensor hallucis longus tendon after ankle arthroscopy: an unusual complication. *Foot Ankle Surg* 2007; 13: 45–47.
3. Tuncer S, Aksu N and Isiklar U. Delayed rupture of the extensor hallucis longus and extensor digitorum communis tendons after breaching the anterior capsule with a radiofrequency probe during ankle arthroscopy: a case report. *J Foot Ankle Surg* 2010; 49(5): 490. e1–e3.
4. Joseph RM and Barhorst J. Surgical reconstruction and mobilization therapy for a retracted extensor hallucis longus laceration and tendon defect repaired by split extensor hallucis longus tendon lengthening and dermal scaffold augmentation. *J Foot Ankle Surg* 2012; 51(4): 509–516.
5. Lohrer H and Nauck T. Subcutaneous extensor hallucis longus tendon rupture: case report and literature review. *Foot Ankle Int* 2012; 33(10): 905–911.
6. So E, Black TE and Mehl B. Split peroneus longus free tendon autograft transplantation for the treatment of neglected extensor hallucis longus tendon laceration: a case report. *J Foot Ankle Surg* 2018; 57(1): 210–214.
7. Sarrafian SK and Kelikian AS. Extensor hallucis longus. In: SK Sarrafian and AS Kelikian (eds) *Sarrafian's anatomy of the foot and ankle: descriptive, topographic, functional*. 3rd ed. Philadelphia, PA: Lippincott Williams & Wilkins, 2011, pp. 224–228.
8. Bibbo C, Arangio G and Patel DV. The accessory extensor tendon of the first metatarsophalangeal joint. *Foot Ankle Int* 2004; 25(6): 387–390.
9. Boyd N, Brock H, Meier A, et al. Extensor hallucis capsularis: frequency and identification on MRI. *Foot Ankle Int* 2006; 27(3): 181–184.
10. Bayer T, Kolodziejcki N and Flueckiger G. The extensor hallucis capsularis tendon – a prospective study of its occurrence and function. *Foot Ankle Surg* 2014; 20(3): 192–194.
11. Jarusriwanna A, Thamphongsri K and Chuckpaiwong B. Frequency and characteristics of extensor hallucis capsularis: a cadaveric study. *J Med Assoc Thai* 2016; 99(11): 1215–1219.
12. Matsuda T, Taniguchi A, Hayashi K, et al. Obtaining adequate tension for extensor hallucis longus tendon rupture repair using wide-awake surgery: a case report. *J Foot Ankle Surg* 2018; 57(2): 414–417.
13. Kitaoka HB, Alexander IJ, Adelaar RS, et al. Clinical rating systems for the ankle-hindfoot, midfoot, hallux, and lesser toes. *Foot Ankle Int* 1994; 15: 349–353.
14. Eagan SL, Silver AG and Muzaffar AR. A practical correction of great toe claw deformity. *J Foot Ankle Surg* 2013; 52(4): 495–497.