

Hashimoto's encephalopathy

Joana Ramalho, MD, and Mauricio Castillo, MD

We report a case of Hashimoto's encephalopathy with atypical and partially reversible MRI findings. T2-weighted MRI images revealed bilaterally symmetric areas of increased signal in the mesial temporal lobes and basal ganglia. Despite clinical and imaging improvement after steroid therapy, some memory deficits and MRI abnormalities persisted.

Introduction

Hashimoto's encephalopathy (HE) is a controversial and poorly understood encephalopathy of presumed autoimmune origin. It was initially described by Lord Brain in 1966 (1), and its name reflects the association with Hashimoto's thyroiditis. Since this neurological disorder also appears to be associated with other autoimmune thyroid diseases, such as Grave's diseases (2), the name "encephalopathy associated with autoimmune thyroid diseases" seems more appropriate. Although Brain's original patient did not improve with corticosteroid treatment, most patients who were later described did improve. This led to the renaming of HE by some as "steroid-responsive encephalopathy associated with autoimmune thyroiditis" (SREAT) (3). The pathogenesis of HE is unknown; however, some evidence of a nonvasculitic process has been reported that supports the term "nonvasculitic autoimmune inflammatory meningoencephalitis" (NAIM) as another denomination of HE (4).

HE is characterized by an association of symptoms of acute or subacute encephalopathy with high levels of anti-

thyroid antibodies, often without clinical or biochemical evidence of thyroid dysfunction (5, 6). Neurological manifestations are heterogeneous, but two main types are usually seen: strokelike episodes with focal and transient neurological deficits, or a progressive cognitive decline leading to dementia or psychosis (7). Seizures may coexist in both types, and manifestations may overlap in the same patient. Accurate and prompt diagnosis is important, because appropriate treatment is almost always successful and permanent impairment can result if the condition is left untreated.

Case report

A 37-year-old Caucasian female presented with symptoms of depression of 6 months' duration. She was diagnosed with hypothyroidism and treated, but experienced no improvement. Antidepressant therapy was started, also without improvement. She was referred to our institution because of progressive short- and long-term memory loss and sleepiness. During the course of the disease, she reported approximately a 20-kg weight loss. She had previously been working but was now on short-term disability. On physical examination, she was alert and oriented. Her short-term memory was impaired, but long-term memory was judged to be intact. Attention and concentration were adequate. Neurological examination was otherwise normal.

Routine laboratory tests (full blood count, hemoglobin, erythrocyte sedimentation rate, platelets, creatinine, blood-urea nitrogen, glucose, transaminases, and proteins) were normal. Thyroid-stimulating hormone (TSH) values were within normal limits. Infectious serologies were negative, including those of Lyme disease, Rocky Mountain spotted fever, syphilis, HIV, and hepatitis A, B, and C. Serum copper, vitamin B12, and angiotensin-converting enzyme

Citation: Ramalho J, Castillo M. Hashimoto's encephalopathy. *Radiology Case Reports*. [Online] 2011;6:445.

Copyright: © 2011 The Authors. This is an open-access article distributed under the terms of the Creative Commons Attribution-NonCommercial-NoDerivs 2.5 License, which permits reproduction and distribution, provided the original work is properly cited. Commercial use and derivative works are not permitted.

Dr. Ramalho and Dr. Castillo are at the University of North Carolina at Chapel Hill hospital, Chapel Hill NC. Dr Ramalho is also at the Centro Hospitalar de Lisboa Central, Lisbon, Portugal. Contact Dr. Ramalho at joana-ramalho@netcabo.pt.

Competing Interests: The authors have declared that no competing interests exist.

DOI: 10.2484/rcr.v6i1.445

Hashimoto's encephalopathy

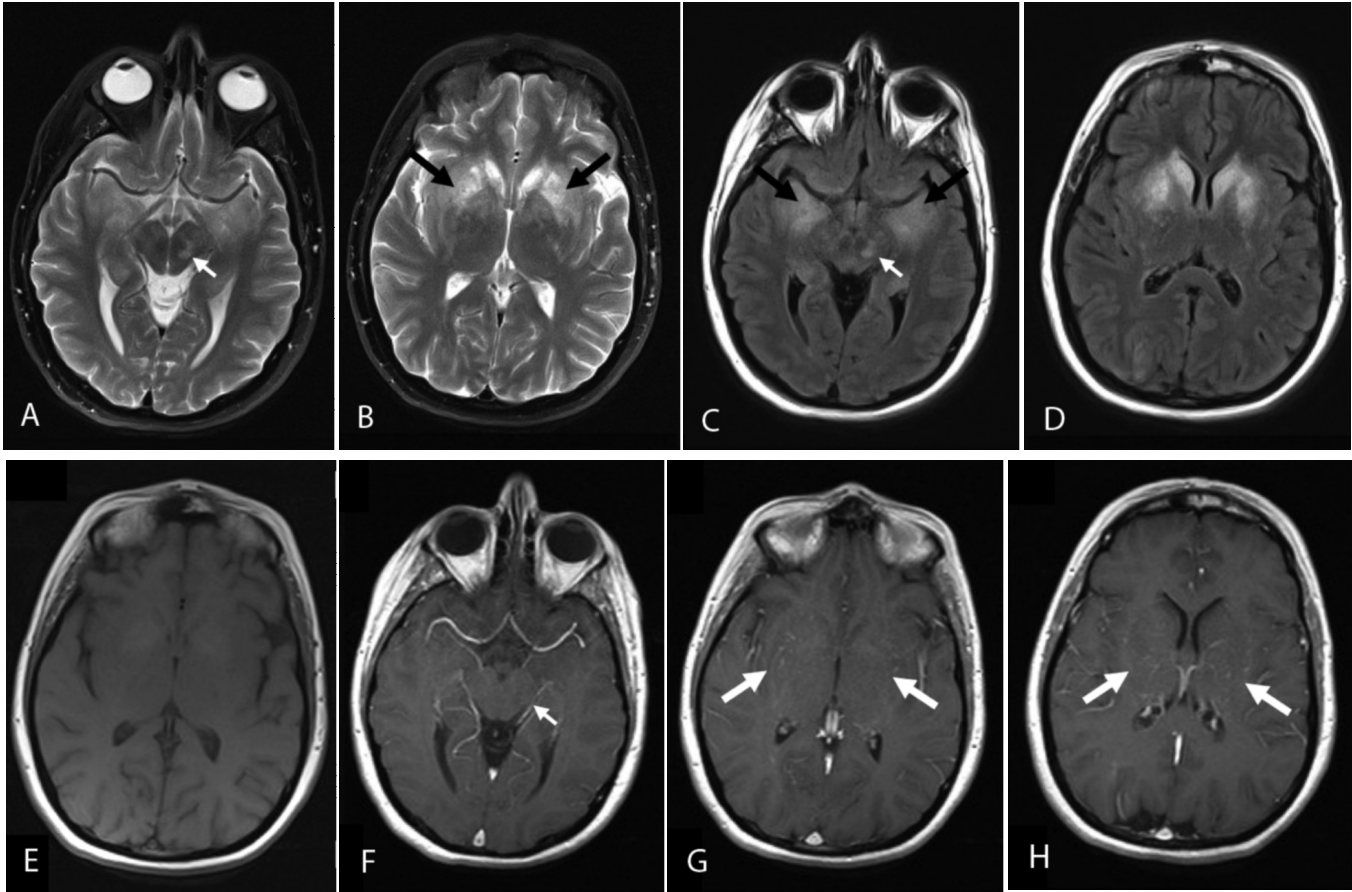


Figure 1. 37-year-old female with Hashimoto's encephalopathy. Brain MRI performed six months after the onset of symptoms. Axial T2 (A and B) and axial FLAIR (C and D) show symmetric and bilateral areas of abnormal high signal on T2-weighted and fluid attenuation inversion recovery (FLAIR) images involving the mesial temporal lobes, caudate nuclei, and putamina (black arrows). The basal ganglia lesions are minimally hyperintense on T1-weighted images (E). These lesions have fine serpiginous enhancement on T1-weighted postcontrast images (G and H) (white arrows). Additionally, a left midbrain lesion, hyperintense on T2-weighted and FLAIR images (A and C), shows no enhancement after gadolinium administration (F) (small arrows).

(ACE) levels were also normal. Total antinuclear antibodies (ANA), antineutrophil cytoplasmic antibodies (pANCA), double-stranded DNA (anti-dsDNA) antibodies, and anti-ribonucleoprotein (anti-RNP) antibodies were positive, while anti-Sjogren (anti-SSA, anti-SSB), anti-Scl-70, antichromatin antibodies, and rheumatoid factor were negative.

A lumbar puncture revealed 82 total nucleated cells, 99% lymphocytes, protein 84 mg/dl (15-45mg/dl), and glucose 62mg/dl (50-75mg/dl). CSF was tested for multiple atypical CNS infections, all of which proved to be negative. This included herpes simplex virus (HSV) polymerase chain reaction (PCR), varicella zoster virus (VZV) PCR, cytomegalovirus (CMV) PCR, human herpes virus 6 (HHV-6) PCR, and Epstein-Barr virus (EBV) PCR. Venereal disease research laboratory test (VDRL) and cryptococcal antigen were also negative. A CSF culture and arbovirus panel including eastern equine, western equine, St. Louis, LaCrosse, and west Nile were all negative. Angiotensin-converting enzyme (ACE) was negative. CSF oligoclonal

bands revealed 1 to 3 bands unique to the CSF. The immunoglobulin G (IgG)-CSF index was within the normal limits. A CSF paraneoplastic panel including collapsin response mediator protein-5 (CRMP-5), IgG, amphiphysin antibody, Purkinje cell cytoplasmic antibody (PCA) trotter antigen (TR), PCA-2, PCA-1, antiglial nuclear antibody (AGNA)-1, antineuronal nuclear antibody (ANNA)-3, ANNA-2, and ANNA-1 all returned negative. Voltage-gated potassium channel and NMDA (N-methyl D-aspartate) antibodies were also negative.

The possibility of Hashimoto's encephalitis was considered, and an antithyroid antibody test was requested. Anti-thyroglobulin (anti-TG) antibodies were greater than 500 IU/mL (normal < 4 IU/mL), and antithyroid peroxidase (anti-TPO) antibodies were 343.4 IU/mL (normal < 4 IU/mL).

Brain MRI revealed symmetric and bilateral areas of abnormally high signal on T2-weighted and fluid-attenuated inversion recovery (FLAIR) images involving the

Hashimoto's encephalopathy

mesial temporal lobes, caudate nuclei, and putamina. These lesions were slightly hyperintense on T1-weighted images, with fine serpiginous enhancement after gadolinium administration. Additionally, a left midbrain lesion, hyperintense on T2-weighted and FLAIR images, was seen. This lesion had no enhancement after gadolinium administration. No hemorrhage or mass effect was seen. No diffusion-weighted signal abnormality was identified (Fig. 1). MR angiograms of the circle of Willis and neck were normal. To exclude possible paraneoplastic limbic encephalitis, abdomen and pelvis CT scans were obtained and were normal.

Clinical history and laboratory findings were deemed consistent with HE, and the patient started prednisone (60 mg daily). A six-month followup brain MRI showed some improvement, with reduction in the extent of the high T2 signal lesions in the mesial temporal lobes, basal ganglia, and midbrain, and resolution of the gadolinium enhance-

ment. The high T1 precontrast signal in the basal ganglia present in the previous exam was more evident (Fig. 2). At this point, thyroglobulin antibody had decreased to 141IU/mL (normal < 4 IU/mL), and thyroid peroxidase antibody was 23IU/mL (normal < 4 IU/mL).

Discussion

HE is an extremely rare condition associated with autoimmune thyroid diseases. Since Brain's first description in 1966 (1), approximately 200 new cases have been reported in the literature, but few with associated MRI. The prevalence has been estimated to be 2.1/100,000 (4), but some benign forms may still be undiagnosed (7).

Hashimoto's encephalopathy, like autoimmune thyroid disease, is more common in women than in men and has been reported in pediatric, adult, and elderly populations throughout the world (4).

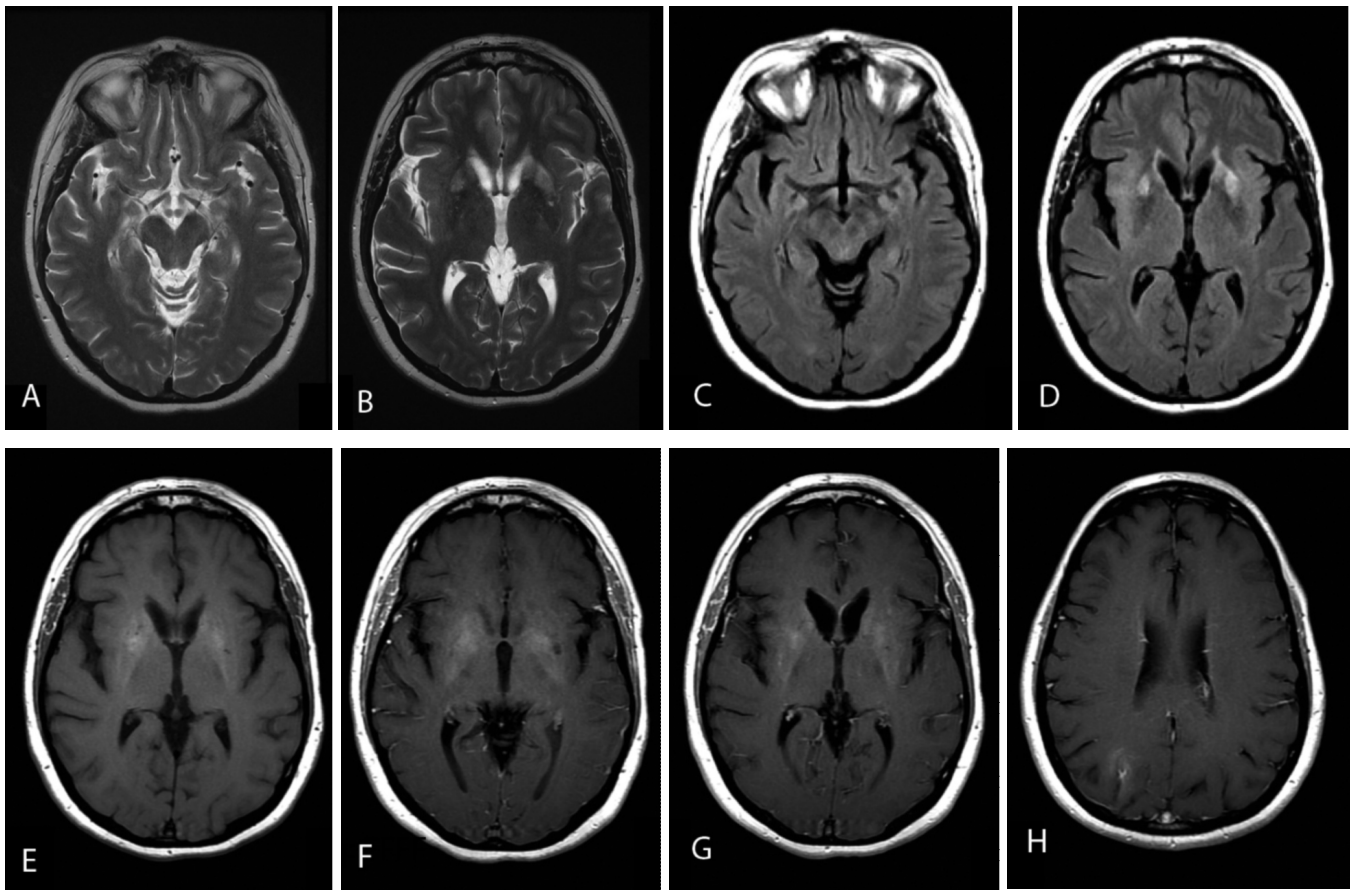


Figure 2. 37-year-old female with Hashimoto's encephalopathy. Six-month followup brain MRI. Axial T2 (A and B), axial FLAIR (C and D), axial T1 (E), and axial T1-weighted postcontrast (F, G, and H) weighted images show some improvement with reduction in the extent of the high T2/FLAIR signal lesions in the mesial temporal lobes and basal ganglia, with resolution of gadolinium enhancement. The high T1 precontrast signal in the basal ganglia is now much more evident (E). The left midbrain lesion present in the previous exam is currently not seen.

Hashimoto's encephalopathy

The clinical features of Hashimoto's encephalopathy can be quite varied. By definition, patients present with encephalopathy (100%). This nonspecific alteration of mental state is characterized by abnormal consciousness, impaired attention and cognition, and associated changes in behavior and personality. Although no particular pattern of cognitive dysfunction is specified, memory dysfunction is common. Seizures (66%), myoclonus (38%), neuropsychiatric symptoms (36%), and strokelike symptoms (27%) are also seen (6, 8). EEG findings are nonspecific. The most frequently reported abnormality is a slow wave background, associated with any encephalopathic process, often reflecting the severity of the clinical picture (4).

Diagnosis is made in the first instance by excluding other toxic, metabolic, inflammatory, ischemic, and infectious causes of encephalopathy as well as primary degenerative CNS diseases, as was done with our patient. Common differential diagnoses are Creutzfeldt-Jakob disease, other rapidly progressive dementias, central nervous system vasculitis, paraneoplastic and nonparaneoplastic limbic encephalitis, and primary psychiatric diseases.

In most cases of HE, routine blood investigations are normal. Nonspecific findings of inflammation, such as mild elevations of erythrocyte sedimentation rate, C-reactive protein, or liver aminotransferase levels have been reported. As with our patient, antibody markers of autoimmune diseases can also be detected. These investigations are often not helpful in the diagnosis of HE because they are also common and similar to other forms of autoimmune encephalopathy (6). Thyroid hormone studies are also not helpful, but they may identify subclinical thyroid dysfunction.

The diagnosis of HE is based on the detection of antithyroid antibodies, particularly antithyroid peroxidase (anti-TPO) antibody (also referred to as antimicrosomal antibody) and antithyroglobulin (anti-TG) antibodies. Antithyroid antibodies are present in 5% to 20% of the general population, and this percentage normally increases with age and female gender (4, 6). For that reason, high titers (usually 100-fold over normal), as found in our patient, are necessary for the diagnosis of HE. The pathogenic role of these antibodies is still debated. They can also be detected in paraneoplastic and nonparaneoplastic limbic encephalitis, as well as in other autoimmune disorders, suggesting that the antibodies are markers of autoimmune encephalitis rather than directly involved in the pathogenesis of HE. With our patient, the main differential diagnosis was limbic encephalitis, but specific serum antineuronal antibodies found in paraneoplastic and nonparaneoplastic limbic encephalitis were negative, as was a body CT scan.

Another controversial issue is whether the titer of antibodies correlates with the stage of the disease. Some studies describe a reduction of antibodies after remittance of symptoms, either spontaneously or induced by therapy as with our patient, while others describe the opposite (9).

Thyroid antibodies are also detected in paraneoplastic and nonparaneoplastic limbic encephalitis, as well as in a number of other autoimmune disorders. This suggests that

antithyroid antibodies may be bystanders rather than having a direct role (4). In HE, elevated CSF proteins are found in 80% of patients, and a mild lymphocytic pleocytosis in 20% to 80% (4). These findings were also present in our patient. Ferraci et al (5) identified antithyroid antibodies and circulating immune complexes in the CSF of six patients with HE. The data were consistent with the integrity of the blood-brain barrier (BBB) and intrathecal synthesis of auto-antibodies. The authors believe that this CSF finding may be useful in the diagnosis of HE in all patients with unexplained acute or subacute encephalopathy (5). In our case, CSF antithyroid antibody was not tested. Nevertheless, antithyroid antibodies are not always detected in CSF.

MRI is normal in approximately 50% of patients with HE. In the remaining patients, the most common findings reported are generalized cerebral atrophy, diffuse increased signal on T2-weighted and FLAIR images in subcortical white matter, and dural enhancement. Cerebellar T2 hyperintense lesions or atrophy are rarely seen (4, 10). With our patient, the location of the abnormalities, predominantly the mesial temporal lobes and basal ganglia, was unusual. Severe amnesic syndrome with similar bilateral mesial temporal lobe involvement has been reported in two cases (11, 12). However, as far as we know, bilateral basal ganglia involvement has not been previously described. These MRI findings illustrate the wide range of MRI appearances that can be seen in Hashimoto's encephalopathy and the fact that strong suspicion and adequate laboratory findings are essential in making the diagnosis. Some of the brain MRI changes may resolve with treatment (6). With our patient, some improvement was seen, but a number of MRI lesions persisted despite steroid therapy.

Diffusion-weighted MR imaging (DWI) in one HE patient showed restricted diffusion that resolved after therapy. The authors underlined the importance of including DWI in the evaluation of these patients not only to assess the possibility of vasculitis but also to provide a measure of response to treatment (8). MR spectroscopy in a patient with HE demonstrated reduction of N-acetyl-aspartate (NAA) and increased choline (Cho), which returned to normal after treatment. Since NAA and Cho are markers of the integrity of neurons and the myelin sheath, respectively, these data suggest a transient condition involving both neurons and oligodendrocytes (9). Single photon-emission computed tomography (SPECT) has demonstrated nonspecific patterns of reduced blood flow involving multiple regions in some patients with HE (4). Positron-emission tomography (PET) scans have shown some nonspecific hypometabolism (9). SPECT and PET did not correlate with EEG or neuroradiologic findings (9).

Different approaches to treatment have been recommended. A short course of high-dose intravenous corticosteroids or oral prednisone is the typical initial therapy. Most patients show a response to treatment within weeks, and some show a dramatic improvement after the first few doses. Discontinuation of treatment can be considered in patients who remain stable a year or more (6). Some cases

Hashimoto's encephalopathy

of HE are refractory or only partially responsive to corticosteroids. There is some evidence that azathioprine may be helpful, usually when combined with corticosteroids. Intravenous immune globulin and plasma exchange may also be effective as an initial treatment or when corticosteroids are not efficacious. Other treatments include cyclophosphamide and methotrexate, with variable degrees of success (4).

Conclusion

The term HE is loosely applied to a variety of encephalopathic patients who have elevated titers of antithyroid antibodies with various clinical presentations, neuroimaging findings, thyroid hormone levels, and cerebrospinal fluid findings. Its pathogenesis remains unclear, but good clinical response to corticosteroids and presence of elevated serum levels of antithyroid antibodies suggest an autoimmune pathogenesis.

Brain MRI is frequently normal. When it is abnormal, a wide range of MRI appearances may be seen. The most typical findings are generalized cerebral atrophy and changes in subcortical white matter and meninges. However, radiologists should be aware that atypical MRI findings as described here may be present. As far as we know, bilateral basal ganglia involvement has not been previously described.

Despite the suggestive laboratory and neuroimaging findings, at this time, Hashimoto's encephalopathy is still a diagnosis of exclusion based on elevation of serum antithyroid antibodies in the appropriate clinical context.

References

1. Brain L, Jellinek EH, Ball K. Hashimoto's disease and encephalopathy. *The Lancet*. (1966) 3:512-514 [[PubMed](#)]
2. Pozo-Rosich P, Villoslada P, Canton A, Simo R, Rovira A, Montallban X. Reversible white matter alterations in encephalopathy associated with autoimmune thyroid disease. *J Neurol* (2002) 249:1063-1065 [[PubMed](#)]
3. Chong JY, Rowland LP. What's a NAIM? Hashimoto encephalopathy, steroid-responsive encephalopathy associated with autoimmune thyroiditis, or nonvasculitic autoimmune meningoencephalitis? *Arch Neurol* (2006) 63:175-176 [[PubMed](#)]
4. Mocellin R, Walterfang M, Velakoulis D. Hashimoto's encephalopathy. Epidemiology, pathogenesis and management. *CNS Drugs* (2007) 21(10):799-811 [[PubMed](#)]
5. Ferracci F, Moretto G, Candeago RM, et al. Antithyroid antibodies in the CSF. Their role in the pathogenesis of Hashimoto's encephalopathy. *Neurology* (2003) 60:712-714 [[PubMed](#)]
6. Vernino S, Geschwind M, Boeve B. Autoimmune encephalopathies. *The Neurologist* (2007) 13(3):140-147 [[PubMed](#)]
7. Gini B, Lovato L, Cianti R, et al. Novel autoantigens recognized by CSF IgG from Hashimoto's encephalitis revealed by a proteomic approach. *Journal of Neuroimmunology* (2008) 196:153-158 [[PubMed](#)]
8. Grommes C, Griffin C, Downes KA, Lerner AJ. Steroid-responsive encephalopathy associated with autoimmune thyroiditis presenting with diffusion MR imaging changes. *AJNR Am J Neuroradiol* (2008) 29:1550-51 [[PubMed](#)]
9. Ferracci F, Carnevale A. The Neurological disorder associated with thyroid autoimmunity. *J Neurol* (2006) 253:975-984 [[PubMed](#)]
10. Song YM, Seo DW, Chang GY. MR findings in Hashimoto encephalopathy. *AJNR Am J Neuroradiol* (2004) 25:807-808 [[PubMed](#)]
11. McCabe JHD, Burke T, Connolly S, Hutchinson M. Amnesic syndrome with bilateral mesial temporal lobe involvement in Hashimoto's encephalopathy. *Neurology* (2000) 54(3):737 [[PubMed](#)]
12. Takahashi S, Mitamura R, Itoh Y, Suzuki N, Okuno A. Hashimoto encephalopathy: etiologic considerations. *Pediatr Neurol* (1994) 11:328-331 [[PubMed](#)]