

## Severe Malaria and Artesunate Treatment, Norway

**To the Editor:** Approximately 8,000 cases of imported falciparum malaria are reported in Europe each year (1). In a study from Belgium of 1,743 persons with fever acquired in the Tropics, only falciparum malaria resulted in deaths (2).

Until recently, the standard treatment of severe malaria was intravenous quinine (3). Frequent adverse effects, however, and reports of limited clinical efficacy in some falciparum malaria-endemic areas preclude its usefulness (4). In contrast, artesunate, a water-soluble artemisinin derivative extracted from the plant *Artemisia annua* (qinghao), is considered safe and highly efficacious (4,5). Artesunate has the advantage of rapidly killing malaria parasites only a few hours after invading the erythrocyte, and it also reduces cytoadherence (4). Resistance to artesunate at the Cambodia-Thailand border has been reported, but until now artesunate resistance has not been considered a problem in most malaria-endemic regions (5,6). On the basis of 6 randomized controlled trials comparing artesunate and quinine, a recent Cochrane review recommended artesunate as the first-line treatment in adults with severe malaria in such areas (7). Similar recommendations were issued by the World Health Organization (WHO) in 2006 (8). Also, the European surveillance network, TropNetEurope, and the Advisory Committee on Malaria Prevention in UK Travelers advocate artesunate as the first-line treatment for severe falciparum malaria in travelers (9,10). However, the manufacturers of intravenous (IV) artesunate have not achieved Good Manufacturing Practice certification; currently, the drug is not widely used outside Asia.

In March 2008, an inquiry for patients treated with IV artesunate for severe falciparum malaria was mailed

to all major departments of infectious diseases in Norway. All departments responded, and 9 patients treated from February 2006 to May 2008 were identified at 3 centers: 7 at Haukeland University Hospital in Bergen, 1 at Akershus University Hospital in Nordbyhagen, and 1 at Ullevål University Hospital in Oslo. Clinical and laboratory features were retrospectively obtained from the medical records. Artesunate was produced by Guilin Pharmaceutical, Guangxi, China, and provided from IDIS Pharmaceutical, Weybridge, United Kingdom.

With the exception of 1 patient who had become infected while in Myanmar, all patients acquired falciparum malaria in West Africa (Table). Four patients were Norwegian tourists or businessmen; 4 patients were visiting friends and relatives and had lived in Norway for 2, 15, 20, and 40 years, respectively. One patient was a pregnant (third trimester) immigrant. None of the patients had used antimalarial chemoprophylaxis. The patients' symptoms fulfilled up to 5 of the WHO criteria for severe malaria: 1 patient had cerebral malaria, 5 impaired consciousness, 5 jaundice, 2 shock, 2 renal failure, 2 hemoglobinuria, 1 hematemesis, and 8 hyperparasitemia (Table). The initial treatment consisted of IV artesunate plus doxycycline (n = 7), IV artesunate monotherapy (n = 1), or IV artesunate plus clindamycin (n = 1). The dosing of artesunate was 2.4 mg/kg at 0 h, 12 h, and 24 h and then daily thereafter. Patient 6 received a 1,200-mg loading dose of quinine before transfer to one of the study hospitals (Table). None of the patients needed exchange transfusions. No adverse effects were attributed to artesunate, and the pregnant patient delivered a healthy child at term. The parasitemia level fell below 1% in all patients within 1–2 days. Treatment was changed to oral antimalarial drugs (artemether-lumefantrine, mefloquine, proguanil-atovaquone, or quinine) within 2.1 days (mean); all patients recovered uneventfully and were

discharged from the hospital within 4.2 days (mean) (Table). No episodes of recrudescence were documented post-treatment at 4 weeks follow-up; 7 patients had a negative malaria slide and 2 patients were not examined for parasites but had no clinical recrudescence at follow-up.

Our findings support those of several randomized controlled trials performed in Asia and indicate that therapy with IV artesunate is safe, induces rapid parasite clearing, and usually results in swift clinical cure. Blood exchange transfusion, a labor-intensive and potentially hazardous procedure, was initially considered for 2 of our patients but was deemed unnecessary because of the rapid improvement after artesunate treatment. Artemisinins have short half-lives, and there is an increased risk for recrudescence if used alone. We gave concurrent IV doxycycline or clindamycin to all but 1 of our patients; all patients were treated with an oral drug after IV artesunate, and recrudescence was not noted.

A major obstacle for the use of IV artesunate is its poor availability outside Asia and the fact that its use is not approved in many countries. However, in the United States, artesunate for infusion may now be obtained as an investigational drug from the Centers for Disease Control and Prevention ([www.cdc.gov/malaria/features/artesunate\\_now\\_available.htm](http://www.cdc.gov/malaria/features/artesunate_now_available.htm)), and in the European Union, artesunate recently received the Orphan Medicinal Drug Designation from the European Medicines Agency ([www.emea.europa.eu/pdfs/human/comp/opinion/48693207en.pdf](http://www.emea.europa.eu/pdfs/human/comp/opinion/48693207en.pdf)) and may be obtained from IDIS Pharma ([www.idispharma.com](http://www.idispharma.com)).

If falciparum malaria is acquired at the Cambodia-Thailand border region, artesunate resistance should be considered; except for this region, where mefloquine resistance also is a problem, artesunate is considered to be an efficacious drug with limited reports of resistance. In conclusion, the current case series suggests that IV

Table. Epidemiologic, clinical, and laboratory data from 9 patients with severe falciparum malaria treated with intravenous artesunate, Norway, 2006–2008\*

Patient no. (gender/ age, y)	Reason for travel	Country of disease acquisition	WHO severe malaria criteria	Days from symptom onset to therapy	Initial treatment	Parasitemia level, %					Length of hospital stay, d
						Day 0	Day 1	Day 2	Day 3	Day 4	
1 (M/37)	Tourism	Ghana	Impaired consciousness, bilirubin† 53, hyperparasitemia	10	AS + D	4	<1	0‡			4
2 (M/45)	VFR	Mali	Hyperparasitemia	4	AS + D	5	<1‡	<1	NA	0	4
3 (M/25)	VFR	Ghana	Impaired consciousness, hematemesis, hemoglobinuria, lactate 3.2,§ hyperparasitemia	5	AS + D	15	7	<1	0‡		3
4 (M/41)	Tourism	Ghana	Coma, shock, hemoglobinuria, bilirubin 241, hyperparasitemia	5	AS + D	20	3	<1	NA	0‡	5
5 (F/32)	Immigration	Nigeria	Impaired consciousness, bilirubin 50, hyperparasitemia	3	AS + C (patient pregnant)	7	0	NA‡			3
6 (M/46)	Business	Nigeria	Impaired consciousness, creatinine† 309, bilirubin 58, hyperparasitemia	6	Quinine 1,200 mg loading dose, then AS + D	30	5	0.5‡	0		7
7 (M/35)	Tourism	Myanmar	Impaired consciousness, hyperparasitemia	10	AS	4	<1	0‡	0		5
8 (F/38)	VFR	Liberia	Shock	7	AS + D	1	<1‡	0	0		3
9 (M/55)	VFR	Guinea	Creatinine 315, bilirubin 118, hyperparasitemia	4	AS + D	6	<1	0‡			4

\*WHO, World Health Organization; AS, artesunate; D, doxycycline; VFR, visiting friends and relatives; NA, not available; C, clindamycin.

† $\mu\text{mol/L}$  (bilirubin reference range 5–25; creatinine reference range 60–105).

‡Day when intravenous artesunate was discontinued.

§ $\text{mmol/L}$  (reference range 0.5–2.2).

artesunate is an efficacious and safe treatment option in travelers returning from West Africa with severe falciparum malaria.

#### Acknowledgments

We thank Thomas Zoller for valuable comments. We are also indebted to Fredrik Koller Lund, Gunhild Holmaas, and Reidar Kvåle for supportive treatment of one of the patients in the study.

**Kristine Mørch, Øystein Strand,  
Oona Dunlop, Åse Berg,  
Nina Langeland,  
Rafael A.M. Leiva,  
Jørn-Åge Longva,<sup>1</sup>  
Håkon Sjursen, Steinar Skrede,  
Jon Sundal,  
and Mogens Jensenius**

Author affiliations: Haukeland University Hospital, Bergen, Norway (K. Mørch, N. Langeland, R.A.M. Leiva, J.-A. Longva, H. Sjursen, S. Skrede); Akershus University Hospital, Nordbyhagen, Norway (Ø. Strand); Ullevål University Hospital, Oslo, Norway (O. Dunlop, M. Jensenius); and Stavanger University Hospital, Stavanger, Norway (Å. Berg, J. Sundal)

DOI: 10.3201/eid1411.080636

#### References

- Jelinek T, Schulte C, Behrens R, Grobusch MP, Coulaud JR, Bisoffi Z, et al. Imported falciparum malaria in Europe: sentinel surveillance data from the European network on surveillance of imported infectious diseases. *Clin Infect Dis*. 2002;34:572–6. DOI: 10.1086/338235

- Bottieau E, Clerinx J, Schrooten W, Van den Enden E, Wouters R, Van Esbroeck M, et al. Etiology and outcome of fever after a stay in the tropics. *Arch Intern Med*. 2006;166:1642–8. DOI: 10.1001/archinte.166.15.1642
- World Health Organization. Severe falciparum malaria. *Trans R Soc Trop Med Hyg*. 2000;94(Suppl 1):1–90.
- Woodrow CJ, Haynes RK, Krishna S. Artemisinin. *Postgrad Med J*. 2005;81:71–8. DOI: 10.1136/pgmj.2004.028399
- Rosenthal PJ. Artesunate for the treatment of severe falciparum malaria. *N Engl J Med*. 2008;358:1829–36. DOI: 10.1056/NEJMct0709050
- Wongsrichanalai C, Meshnick SR. Declining artesunate-mefloquine efficacy against falciparum malaria on the Cambodia-Thailand border. *Emerg Infect Dis*. 2008;14:716–9.

<sup>1</sup>Current affiliation: Aalesund Hospital, Aalesund, Norway.

7. Jones KL, Donegan S, Laloo DG. Artesunate versus quinine for treating severe malaria. *Cochrane Database Syst Rev*. 2007;(4):CD005967.
8. World Health Organization. Guidelines for the treatment of malaria. 2006 [cited 2008 Sep 11]. Available from <http://www.who.int/malaria/docs/TreatmentGuidelines2006.pdf>
9. Jelinek T. Intravenous artesunate recommended for patients with severe malaria: position statement from TropNetEurop. *Euro Surveill*. 2005;10(11): p. E051124 5.
10. Laloo DG, Somgoda D, Pasvol G, Chiodini PL, Whitty CJ, Beeching NJ, et al. UK malaria treatment guidelines. *J Infect*. 2007;54:111–21. DOI: 10.1016/j.jinf.2006.12.003

Address for correspondence: Kristine Mørch, Department of Medicine, Haukeland University Hospital, 5021 Bergen, Norway; email: kristine.moerch@helse-bergen.no

## Bacteremia Caused by *Mycobacterium wolinskyi*

**To the Editor:** *Mycobacterium wolinskyi* is a rapidly growing mycobacterium that belongs to the *M. smegmatis* group, which includes *M. smegmatis* sensu stricto and 2 species described in 1999 (*M. goodii* and *M. wolinskyi*) (1). Only 9 cases of infection caused by *M. wolinskyi* have been reported (1–3), and these included 3 cases of bone infection and 1 case of infection of a hip prosthesis. All patients had a history of surgery after traumatic injury and all specimens were isolated from the surgical wound. In our study, we used molecular diagnostic tools and report a case of bacteremia caused by *M. wolinskyi*.

In November 2006, we diagnosed non-Hodgkin lymphoma in a 22-year-old woman. A venous port was implanted, and 4 courses of rituximab (anti-CD20 monoclonal antibody) plus additional chemother-

apy (cyclophosphamide, epirubicin, vicristine and prednisolone) were administered from December 2006 through May 2007. No unfavorable sequelae occurred after chemotherapy, and the tumor showed a complete response. In August 2007, we admitted the patient to our hospital because of a spiking high fever (up to 40°C), chills, and pain in the left knee. On physical examination, the patient had a tender, warm, erythematous, and swollen left knee. These symptoms progressed to other joints, including the left hip and ankle.

Laboratory data showed a normal leukocyte count ( $3.4 \times 10^9$  cells/L). The patient's C-reactive protein level increased from 1.13 mg/dL (on the day of admission) to 24.95 mg/dL (7 days after admission). We drew 2 sets of blood samples from a peripheral vein for culture and incubated these cultures (BACTEC 9240 Continuous Monitoring Blood Culture System; Becton Dickinson, Sparks, MD, USA) using BACTEC Aerobic Plus and Anaerobic Plus medium (Becton Dickinson). Within 3 days, the cultures tested positive for acid-fast bacilli.

The isolate was identified by 16S rRNA gene amplification of an 880-bp

region (corresponding to positions 27–907), as previously described (4,5). For amplification, we used broad-range primers 16S-27f (5'-AGA GTT TGA TCM TGG CTC AG-3') and 16S-907r (5'-CCG TCA ATT CMT TTR AGT TT-3'). For sequencing 16S rDNA, we used either the primer 16S-27f or 16S-519r (5'-GWA TTA CCG CGG CKG CTG-3'). We performed both forward and reverse (5' and 3') sequencing. For accurate analysis of the data, a 492-bp variable region (corresponding to positions 27–519) was carefully analyzed after it was compared with sequences of *Mycobacterium* spp. in the BLAST database ([www.ncbi.nlm.nih.gov](http://www.ncbi.nlm.nih.gov)), as described (6). The results showed 99% similarity between our isolate and *M. wolinskyi*.

A few days later, we obtained synovial fluid by needle biopsy and cultured samples in BACTEC Aerobic Plus and Anaerobic Plus medium (Becton Dickinson) and on trypticase soy agar. Within 3 days, these cultures were also positive for *M. wolinskyi*. Arthroscopically assisted arthrocentesis and debridement showed a turbid joint and the debrided tissue showed inflammatory processes within the synovial tissue and the presence of ac-

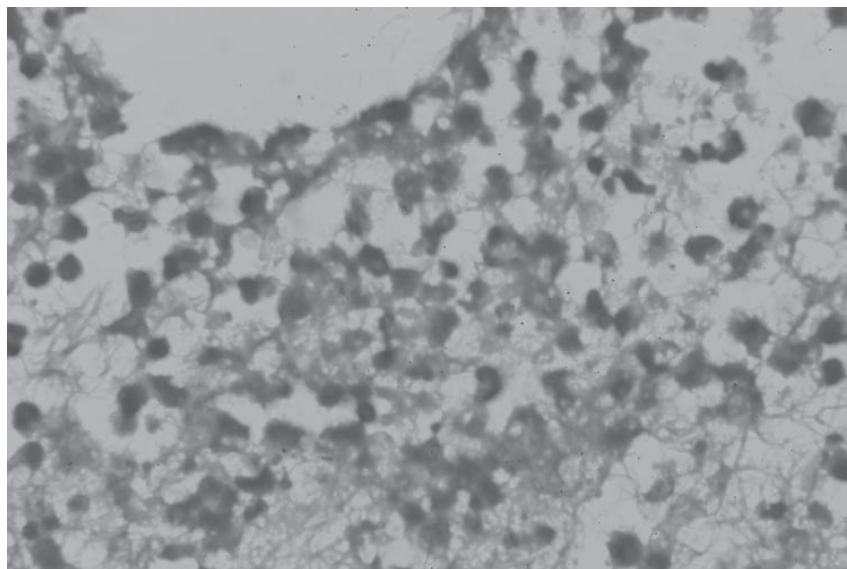


Figure. Histologic image of debrided tissue of the patient, showing inflammatory processes within the synovial tissue and the presence of an acid-fast bacillus (magnification  $\times 400$ , acid-fast stain).