

# Surgeon and Patient Upper Extremity Dominance Does Not Influence Clinical Outcomes After Total Shoulder Arthroplasty

Daniel P. Berthold,<sup>\*†‡</sup> MD, Lukas N. Muench,<sup>†‡</sup> MD, Cameron Kia,<sup>†</sup> MD, Connor G. Ziegler,<sup>†§</sup> MD, Samuel J. Laurencin,<sup>†</sup> MD, PhD, Daniel Witmer,<sup>†</sup> MD, Dale N. Reed,<sup>§</sup> MD, Mark P. Cote,<sup>†</sup> PT, DPT, Robert A. Arciero,<sup>†</sup> MD, and Augustus D. Mazzocca,<sup>†</sup> MS, MD

*Investigation performed at University of Connecticut Health Center, Farmington, Connecticut, USA*

**Background:** Surgeon- and patient-specific characteristics as they pertain to total shoulder arthroplasty (TSA) are limited in the literature. The influence of surgeon upper extremity dominance in TSA and whether outcomes vary among patients undergoing right or left TSA with respect to surgeon handedness have yet to be investigated.

**Purpose:** To determine whether surgeon or patient upper extremity dominance has an effect on clinical outcomes after primary TSA at short-term follow-up.

**Study Design:** Case series; Level of evidence, 4.

**Methods:** A retrospective chart review was performed on prospectively collected data from an institutional shoulder registry. Patients who underwent primary TSA for glenohumeral osteoarthritis from June 2008 to August 2012 were included in the study. Preoperative and postoperative American Shoulder and Elbow Surgeons (ASES), Simple Shoulder Test (SST), and visual analog scale (VAS) pain scores were evaluated. To determine the clinical relevance of ASES scores, the minimal clinically important difference (MCID), the substantial clinical benefit (SCB), and the patient acceptable symptom state (PASS) were used. Active forward elevation, abduction, and external rotation were recorded for each patient. Glenoid version was also evaluated preoperatively on standard radiographs.

**Results:** Included in this study were 40 patients (n = 44 shoulders; mean age, 69.0 ± 7.3 years) with a mean follow-up of 36.5 ± 16.2 months. Final active range of motion between patients who underwent dominant versus nondominant and left versus right TSA by a right-handed surgeon was not significantly different. Clinical outcomes including the ASES, SST, and VAS pain scores were compared, and no statistical significance was identified between groups. With regard to the ASES score, 89% of patients achieved the MCID, 64% achieved the SCB, and 60% reached or exceeded the PASS. No significant difference in preoperative glenoid version between groups could be found.

**Conclusion:** With the numbers available, neither patient nor surgeon upper extremity dominance had a significant influence on clinical outcomes after primary TSA at short-term follow-up.

**Clinical Relevance:** The influence of surgeon and patient upper extremity dominance on TSA outcomes is an important consideration, given the preferential use of the dominant extremity exhibited by most patients during activities of daily living. To this, operating on a right shoulder might be technically more demanding for a right-handed surgeon and vice versa, as it is considered in other subspecialties.

**Keywords:** total shoulder arthroplasty; handedness; hand dominance; shoulder replacement

The prevalence of total shoulder arthroplasty (TSA) in the United States has increased significantly, with an estimated 29,414 to 34,550 procedures performed from 2011 to 2014.<sup>9,33</sup> Outcomes after TSA have been promising, with reported implant survival rates of 93% at 10 years and 87%

at 15 years as well as patient satisfaction only declining from 92% to 83% over the long term.<sup>37</sup>

However, intraoperative and postoperative complications remain a common challenge, reportedly occurring in 5.4% and 7.8% of cases, respectively.<sup>27</sup> The most frequently reported long-term complication of TSA is glenoid loosening, accounting for approximately 24% of all TSA complications.<sup>15</sup> The cause of glenoid loosening is likely multifactorial and may be related to surgical technique, implant design, patient characteristics, rotator cuff

The Orthopaedic Journal of Sports Medicine, 8(7), 2325967120932106  
DOI: 10.1177/2325967120932106  
© The Author(s) 2020

This open-access article is published and distributed under the Creative Commons Attribution - NonCommercial - No Derivatives License (<https://creativecommons.org/licenses/by-nc-nd/4.0/>), which permits the noncommercial use, distribution, and reproduction of the article in any medium, provided the original author and source are credited. You may not alter, transform, or build upon this article without the permission of the Author(s). For article reuse guidelines, please visit SAGE's website at <http://www.sagepub.com/journals-permissions>.

integrity, or the presence of indolent infections.<sup>15</sup> As radiolucency of glenoid components at 10-year follow-up has been shown to occur more frequently in the patients' dominant extremity compared with the nondominant side, handedness of the patient may be an additional risk factor.<sup>5</sup> Additionally, the influence of surgeon upper extremity dominance in TSA and whether outcomes vary among patients undergoing right or left TSA with respect to surgeon handedness have yet to be investigated. Further, it remains unknown whether patients undergoing TSA on their dominant arm have better clinical outcomes compared with their nondominant arm. This is an important consideration, given the preferential use of the dominant extremity exhibited by most patients during activities of daily living.

Operating on a right shoulder might be technically more demanding for a right-handed surgeon and vice versa, as it is considered in total knee arthroplasty.<sup>26</sup> This effect of surgeon handedness on operative psychomotor performance has already been investigated in other subspecialties.<sup>3,17,19,30,35</sup> Even in the field of orthopaedic surgery, there have been significant differences in function and pain scores after total knee arthroplasty, based on which knee was undergoing surgery performed by a right-handed surgeon.<sup>26</sup> Thus, the purpose of this study was to determine if patient or surgeon upper extremity dominance has an effect on clinical outcomes after primary TSA. We hypothesized that for TSA performed on right-handed patients by a right-handed surgeon, short-term clinical outcomes would be significantly poorer when compared with the left side. Additionally, patients who underwent TSA on their nondominant side would have superior short-term clinical outcomes when compared to the dominant side.

## METHODS

Institutional review board approval was obtained before the initiation of the study. This is a retrospective case series of prospectively collected data between June 2008 and August 2012 from the practice at a single institution of 1 senior surgeon (A.D.M.; a fellowship-trained, academic orthopaedic surgeon who has been in practice for 6 years at the time of data collection). The senior surgeon (A.D.M.) was right-hand dominant. Inclusion criteria included patients with glenohumeral arthritis who had failed

previous nonoperative treatment. All patients were required to have an intact rotator cuff, be healthy enough to undergo the procedure, be willing to follow postoperative restrictions, and be willing to participate in a supervised physical therapy regimen. Exclusion criteria included patients who had a rotator cuff tear that prevented TSA, those with rotator cuff tear arthropathy, prior TSA, prior hemiarthroplasty, prior humeral or glenoid resurfacing, those not in sufficient health to undergo surgery, or those unwilling to complete appropriate follow-up and postoperative rehabilitation.

## Radiographic Imaging

All patients undergoing surgery had preoperative computed tomography scans as well as preoperative and postoperative radiographs of the involved shoulder, including standard anteroposterior, axillary lateral, and scapular lateral views. Glenoid version was measured on preoperative radiographs by 3 independent viewers with different levels of training (1 sports orthopaedic surgery fellow [C.G.Z.] and 2 second-year orthopaedic surgery residents [S.J.L., D.N.R.]). Magnetic resonance imaging was performed to ensure integrity of the rotator cuff preoperatively.

## Clinical Outcome Measures

American Shoulder and Elbow Surgeons (ASES), Simple Shoulder Test (SST), and visual analog scale (VAS) pain scores were collected preoperatively and at final follow-up.<sup>25,32</sup> Moreover, shoulder range of motion consisting of active forward elevation, abduction, and external rotation was recorded preoperatively and at final follow-up. To determine the clinical relevance of ASES scores, the minimal clinically important difference (MCID), the substantial clinical benefit (SCB), and the patient acceptable symptomatic state (PASS) were used.<sup>16,20</sup> The MCID and SCB were used to quantify the clinical significance of a change in scores on an outcome measure.<sup>20</sup> The PASS was used as a threshold score associated with patient satisfaction.<sup>20</sup> The MCID and SCB have been developed in shoulder arthroplasty and rotator cuff tear populations.<sup>3,16</sup> The SCB of the ASES score for TSA was a 20.7-point change, the PASS was an 81.9-point change, and the MCID was a 9.1-point change.<sup>16</sup>

\*Address correspondence to Daniel P. Berthold, MD, Department of Orthopaedic Sports Medicine, Technical University of Munich, Ismaninger Strasse 22, 81675 Munich, Germany (email: daniel.berthold@mri.tum.de).

<sup>†</sup>Department of Orthopaedic Surgery, University of Connecticut Health Center, Farmington, Connecticut, USA.

<sup>‡</sup>Department of Orthopaedic Sports Medicine, Technical University of Munich, Munich, Germany.

<sup>§</sup>New England Orthopedic Surgeons, Springfield, Massachusetts, USA.

Final revision submitted April 1, 2020; accepted April 20, 2020.

One or more of the authors has declared the following potential conflict of interest or source of funding: The University of Connecticut Health Center/UCConn Musculoskeletal Institute has received direct funding and material support from Arthrex; the company had no influence on the study design, data collection, or interpretation of the results or the final article. C.G.Z. has received educational support from Kairos Surgical and Smith & Nephew and hospitality payments from Smith & Nephew. D.W. has received hospitality payments from Smith & Nephew. D.N.R. has received educational support from Alpha Orthopedic Systems and Arthrex. R.A.A. has received educational support from Arthrex and DonJoy; has received consulting fees from Biorez, Biomet, and DePuy; and has stock/stock options in Biorez. A.D.M. has received consulting fees from Arthrex and Astellas Pharma, research support from Arthrex, and honoraria from ArthroSurface. AOSSM checks author disclosures against the Open Payments Database (OPD). AOSSM has not conducted an independent investigation on the OPD and disclaims any liability or responsibility relating thereto.

Ethical approval was obtained from the University of Connecticut Health Center (No. 003083).

## Surgical Technique

A standard deltopectoral approach was used to perform surgery. The subscapularis was peeled off the lesser tuberosity. After dislocation of the proximal humerus, the rotator cuff was inspected to ensure the maintenance of integrity. The anatomic neck of the proximal humerus was identified by removing all osteophytes to allow visualization of the native anatomy. The anatomic neck was then marked, and a cut was made using an oscillating saw according to the patient's anatomic version. Next, the glenoid was exposed, the labrum circumferentially removed in a 360° fashion, and the center marked under direct visualization. A glenoid guide was then used (Arthrex), and with a center pin set, minimal reaming was performed, taking care not to violate subchondral bone. The glenoid was prepared for an all-polyethylene keeled glenoid and then cemented into position. Attention was returned to the proximal humerus, which was reamed and broached, and a press-fit stem (Arthrex) was placed. Reduction was performed, final adjustments to version and inclination were made, and the humeral head was impacted into position. Subsequently, the subscapularis was repaired through bony tunnels in the proximal humerus, followed by closure of the wound. Before leaving the operating room, an abduction sling (Corflex) was placed.

Postoperatively, all patients wore a sling for 6 weeks. Physical therapy was started on postoperative day 1 while the patient was still in hospital. The primary restriction was external rotation based on the integrity of subscapularis repair intraoperatively. Additionally, all patients followed the same postoperative rehabilitation protocol, with an emphasis on range of motion and progressive strengthening.

## Statistical Analysis

Descriptive statistics to characterize differences between groups were reported using mean and standard deviation, range, or proportion, where appropriate. Mixed-effects regression was used to account for the 3 patients who contributed data for both the left and right sides. Differences in the amount of improvement between preoperative and postoperative time points were compared between the dominant and nondominant sides.

The change in the ASES score from preoperatively to postoperatively was used to determine which patients crossed the MCID and SCB thresholds. The final postoperative ASES score was used to determine whether patients met criteria for the PASS. Differences in the magnitude of improvement (absolute difference between preoperatively and postoperatively) and final postoperative clinical outcome scores were examined with an independent *t* test.

The intraclass correlation coefficient (ICC) was calculated to determine the reproducibility of glenoid version measurements by the 3 reviewers. A *P* value of <.05 was considered statistically significant. All statistical analyses were performed using Stata 12 (StataCorp).

TABLE 1  
Demographics, Clinical Outcome Scores,  
and Range of Motion for Patient Dominance<sup>a</sup>

	Dominant	Nondominant	<i>P</i>
Age, y	69.8 ± 7.2	69.2 ± 7.3	.82
Preoperative			
Forward elevation, deg	87.9 ± 24.2	89.5 ± 17.3	.96
Abduction, deg	85.3 ± 27.6	87.5 ± 19.7	.83
External rotation, deg	8.5 ± 17.8	6.5 ± 8.1	.73
VAS score	6.4 ± 2.4	6.5 ± 2.0	.90
ASES score	33.8 ± 21.7	32.9 ± 15.2	.82
SST score	2.4 ± 2.7	2.1 ± 1.3	.83
Postoperative			
Forward elevation, deg	151.2 ± 28.3	138.1 ± 41.3	.42
Abduction, deg	142.7 ± 33.1	134.1 ± 45.9	.68
External rotation, deg	52.2 ± 17.3	49.7 ± 22.7	.68
VAS score	2.4 ± 3.3	1.8 ± 3.1	.76
ASES score	77.3 ± 24.0	78.8 ± 29.5	.96
SST score	8.8 ± 2.9	8.4 ± 3.6	.94
Preoperative glenoid version, deg	20.8 ± 8.4	17.7 ± 7.1	.22

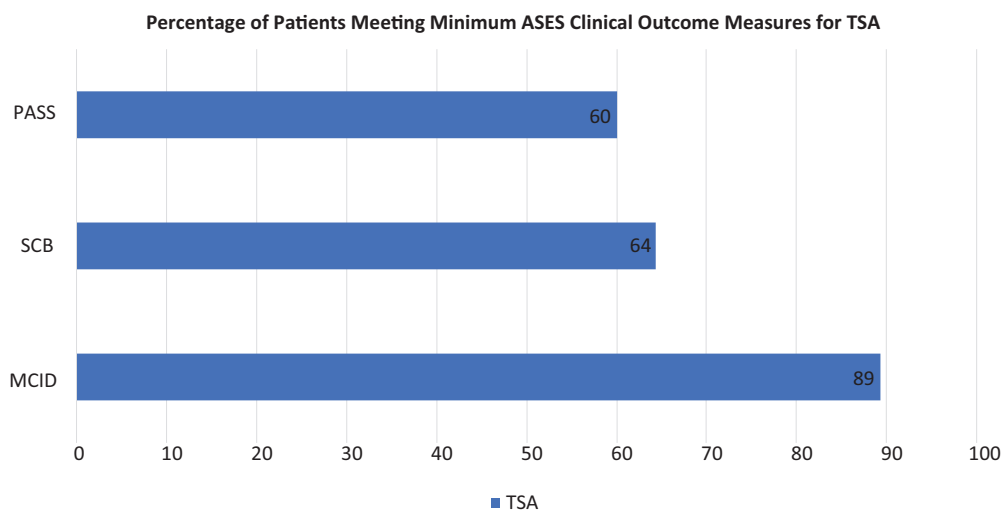
<sup>a</sup>Data are shown as mean ± SD. ASES, American Shoulder and Elbow Surgeons; SST, Simple Shoulder Test; VAS, visual analog scale.

## RESULTS

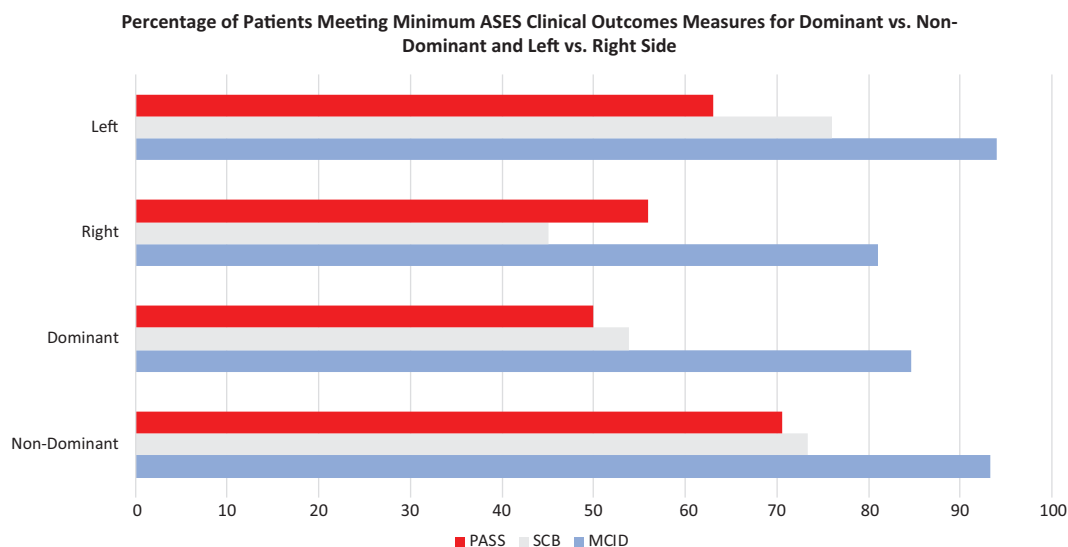
During this data collection period, 40 patients (44 shoulders) with a mean age of 69.0 ± 7.3 years (range, 58-84 years) met eligibility criteria and underwent primary TSA at the senior surgeon's institution. A total of 15 male and 25 female patients were included. The left shoulder was affected in 52.3% (n = 23) and the right shoulder in 47.7% (n = 21). There were 22 arthroplasty procedures on the dominant arm (50.0%) and 22 arthroplasty procedures on the nondominant arm (50.0%). There were 19 right hand-dominant patients. Postoperative outcomes at final follow-up were available for 42 of the 44 shoulders (95.5%). The mean follow-up period was 36.5 ± 16.2 months (range, 10-68 months).

Adequate preoperative radiographs for glenoid version measurements were available for 42 shoulders (95.5%). The mean preoperative retroversion for the dominant group was 20.8° ± 8.4° (range, 3°-40°) compared with 17.7° ± 7.1° (range, 2°-35°) for the nondominant group (Table 1). There was no statistically significant difference between these 2 groups (*P* = .22). The ICC for measuring glenoid version was found to be 0.87.

Overall, 89% of patients achieved the MCID, 64% achieved the SCB, and 60% reached or exceeded the PASS for the ASES score (Figure 1). When comparing outcomes of TSA on the dominant versus nondominant sides, there was no statistically significant difference in the percentage of patients meeting the MCID (85% vs 93%, respectively; *P* = .58), SCB (54% vs 73%, respectively; *P* = .43), or PASS (50% vs 71%, respectively; *P* = .30) thresholds (Figure 2). Similarly, when comparing outcomes from the left versus right shoulders, there was no significant difference in the



**Figure 1.** Percentage of patients after total shoulder arthroplasty (TSA) who met the minimal clinically important difference (MCID), substantial clinical benefit (SCB), and patient acceptable symptom state (PASS) thresholds for the American Shoulder and Elbow Surgeons (ASES) score.



**Figure 2.** Percentage of patients after total shoulder arthroplasty (dominant vs nondominant, left vs right shoulder) who met the minimal clinically important difference (MCID), substantial clinical benefit (SCB), and patient acceptable symptom state (PASS) thresholds for the American Shoulder and Elbow Surgeons (ASES) score.

percentage of patients meeting the MCID (94% vs 81%, respectively;  $P = .54$ ), SCB (76% vs 45%, respectively;  $P = .13$ ), or PASS (63% vs 56%, respectively;  $P = .74$ ) thresholds (Figure 2).

Additionally, for all patients there was a significant improvement in all secondary outcome measures from preoperatively to final follow-up. The ASES score improved from  $33.3 \pm 18.1$  preoperatively to  $78.1 \pm 26.4$  postoperatively, the SST score improved from  $2.3 \pm 2.1$  preoperatively to  $8.6 \pm 3.2$  postoperatively, and the VAS score improved from  $6.4 \pm 2.2$  preoperatively to  $2.1 \pm 3.2$  postoperatively ( $P < .01$  for all) (Table 2 and Figure 3). Further, for all patients

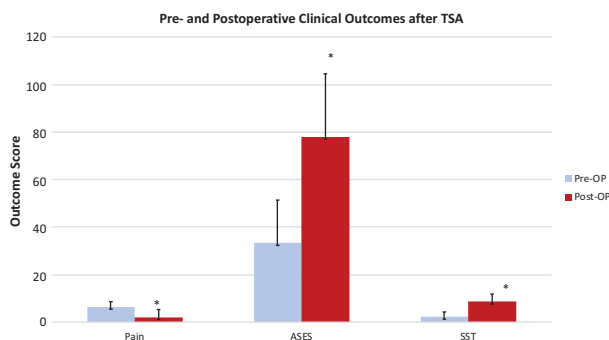
there was a significant improvement in active range of motion from preoperatively to postoperatively. Active forward elevation improved from  $88.8 \pm 20.5$  preoperatively to  $144.4 \pm 35.7$  postoperatively, active abduction improved from  $86.5 \pm 23.4$  preoperatively to  $138.1 \pm 40.0$  postoperatively, and active external rotation improved from  $7.4 \pm 13.3$  preoperatively to  $51.0 \pm 19.9$  postoperatively ( $P < .01$  for all) (Table 2 and Figure 4).

Comparing the dominant and nondominant groups, there was no statistically significant difference in postoperative forward elevation ( $P = .42$ ), abduction ( $P = .68$ ), or external rotation ( $P = .68$ ) (Table 1). Moreover,

**TABLE 2**  
Postoperative and Change in Clinical Outcome Scores and Range of Motion<sup>a</sup>

	Postoperative	P	Change From Pre- to Postoperative
ASES score	78.1 ± 26.4	<.01	44.8 ± 6.3 (34.5 to 60.1)
VAS score	2.1 ± 3.2	<.01	-4.3 ± 0.8 (-6.4 to -3.2)
SST score	8.6 ± 3.2	<.01	6.3 ± 0.7 (5.0 to 7.9)
Forward elevation, deg	144.4 ± 35.7	<.01	55.6 ± 8.1 (33.2 to 64.2)
Abduction, deg	138.1 ± 40.0	<.01	51.6 ± 5.7 (27.8 to 65.5)
External rotation, deg	51.0 ± 19.9	<.01	43.6 ± 9.5 (32.6 to 53.8)

<sup>a</sup>Data are shown as mean ± SD, with 95% CIs in parentheses. ASES, American Shoulder and Elbow Surgeons; SST, Simple Shoulder Test; VAS, visual analog scale.

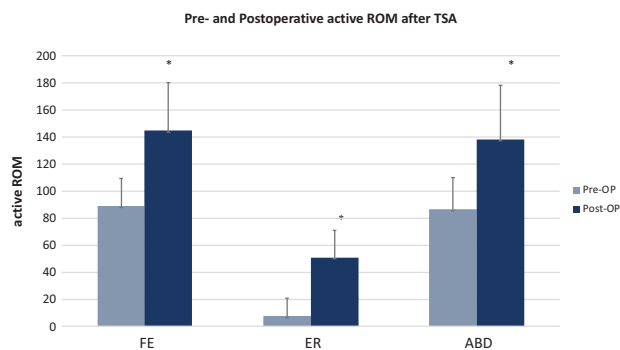


**Figure 3.** Preoperative and postoperative clinical outcome scores at final follow-up for all patients undergoing total shoulder arthroplasty (TSA). \*Significant improvement ( $P < .01$ ) compared with preoperatively. ASES, American Shoulder and Elbow Surgeons; SST, Simple Shoulder Test.

postoperative ASES, SST, and VAS scores showed no significant difference when comparing both groups ( $P = .96, .94, \text{ and } .76$ , respectively). For the subset of right-handed patients operated on by the right-handed surgeon, no significant difference was found in outcomes and range of motion TSA performed on the right shoulder versus the left (Table 3).

**DISCUSSION**

The most important finding of the present study was that the handedness of the surgeon and upper extremity dominance of patients were not found to have a significant influence on clinical outcomes after primary TSA at short-term follow-up. Patient age at the time of surgery, postoperative range of motion, and clinical scores, as they pertain to patient satisfaction reported in this study, were similar to those of prior investigations.<sup>31</sup> Additionally, the present study found that 64% of patients reached the SCB threshold for the ASES score while only 60% of patients met the PASS criteria.



**Figure 4.** Preoperative and postoperative active range of motion at final follow-up for all patients undergoing total shoulder arthroplasty. \*Significant improvement ( $P < .01$ ) compared with preoperatively. ABD, abduction; ER, external rotation; FE, forward elevation; ROM, range of motion; TSA, total shoulder arthroplasty.

**TABLE 3**  
Demographics, Clinical Outcome Scores, and Range of Motion for Shoulder Affected<sup>a</sup>

	Right Shoulder (n = 21)	Left Shoulder (n = 23)	P
Age, y	68.6 ± 6.6	70.2 ± 7.6	.48
Preoperative			
Forward elevation, deg	88.3 ± 25.8	89.1 ± 16.6	.76
Abduction, deg	86.0 ± 29.2	86.8 ± 19.1	.90
External rotation, deg	9.0 ± 18.9	6.4 ± 7.9	.76
VAS score	6.1 ± 2.5	6.6 ± 2.0	.54
ASES score	36.6 ± 21.5	31.1 ± 15.7	.35
SST score	2.6 ± 2.9	2.0 ± 1.2	.78
Postoperative			
Forward elevation, deg	148.7 ± 29.0	141.2 ± 40.5	.76
Abduction, deg	139.2 ± 33.8	137.4 ± 44.6	.96
External rotation, deg	52.8 ± 18.3	49.5 ± 21.5	.74
VAS score	2.4 ± 3.4	1.9 ± 3.0	.83
ASES score	77.0 ± 25.5	78.9 ± 27.9	.77
SST score	8.7 ± 3.0	8.5 ± 3.4	.96
Preoperative glenoid version, deg	21.1 ± 8.9	17.8 ± 6.8	.21

<sup>a</sup>Data are shown as mean ± SD. ASES, American Shoulder and Elbow Surgeons; SST, Simple Shoulder Test; VAS, visual analog scale.

Although hand dominance is known to have an impact in shoulder injuries, such as rotator cuff tears and anterior glenohumeral instability, little is known regarding the role of hand dominance after TSA.<sup>11,23</sup> Cvetanovich et al<sup>7</sup> showed greater postoperative range of motion in patients who underwent TSA of their dominant upper extremity compared with patients who had undergone TSA of their nondominant upper extremity. However, there was no significant difference in functional outcomes between both groups, which was the result found in the current study. Despite almost identical preoperative range of motion in forward elevation and

abduction in both groups, final postoperative forward elevation and abduction were both greater in the dominant group, as was the amount of overall change in motion from preoperatively to postoperatively. This, however, did not reach statistical significance, a finding that may be secondary to the small sample size in the groups compared. Moreover, preoperative external rotation was greater in the dominant group, which is in agreement with prior studies assessing range of motion and handedness.<sup>1,6,34</sup>

TSA has been reported to provide good to excellent results in more than 95% of patients, with an improvement in range of motion, low rates of surgical complications, more than 90% implant survivorship at 15 years, and high rates of patient satisfaction.<sup>1,2,5,6,9,12-14,18</sup> However, there is limited literature regarding patient-specific factors and their influence on clinical outcomes after TSA. Collin et al<sup>5</sup> showed significantly greater radiolucency in dominant extremity glenoid components compared with nondominant extremity components at 10-year follow-up, with radiographic glenoid loosening having a significant detrimental impact on shoulder function. In addition, younger age at the time of surgery and male sex have been reported to have a significantly negative impact on implant survivorship and an increased revision rate.<sup>4,5,13</sup>

Extremity dominance is an important consideration in shoulder replacement surgery. Preferential use of the dominant extremity has different underlying consequences, including neurological asymmetries in the motor cortex and cervical spinal pathways.<sup>22,29,36,38</sup> In handedness-related research on the electromyographic activity of muscles affected by the glenohumeral joint, reduced muscle activity on the dominant side during abduction has been shown to correlate with reduced energy consumption and dominance-related advantages in arm dynamics.<sup>10</sup> Similarly, ballistic activities and dynamic abduction in the scapular plane are characteristic of dominant-arm tasks.<sup>10,21</sup> Thus, preferential use of the dominant extremity may promote increased wear on glenohumeral implants.<sup>5</sup>

With respect to surgeon upper extremity dominance, we hypothesized that right-handed patients undergoing TSA on their right extremity would be at a higher risk for poor outcomes when operated on by a right-handed surgeon. Thus, a right-handed patient undergoing left TSA would potentially have a lower risk of adverse outcomes by minimizing the technical difficulty faced by a right-handed surgeon as well as by avoiding the potential for increased radiographic loosening.<sup>5</sup> However, among the right-handed patients operated on by the right-handed senior surgeon, there was no significant difference in functional outcomes between those who underwent right TSA and between those who underwent left TSA. In contrast, LeBlanc et al<sup>24</sup> reported worse clinical outcomes in patients who underwent hemiarthroplasty for the treatment of a proximal humerus fracture of their dominant side compared with patients with involvement of their nondominant side. Pennington et al<sup>28</sup> concluded that surgeon handedness influenced acetabular component positioning during total hip replacement. Mehta and Lotke<sup>26</sup> showed that right-hand dominance of the surgeon resulted in significantly higher clinical outcome scores in patients undergoing total

knee arthroplasty on their right knee compared with patients undergoing surgery on their left knee. To our knowledge, the current study is the first to report the influence of both patient and surgeon upper extremity dominance on clinical outcomes after TSA.

There were several limitations to the study. Although data were collected prospectively, the chart review was performed retrospectively, which could create selection bias. Second, the sample size of 44 shoulders was limited, as only patients with severe glenohumeral osteoarthritis and an intact rotator cuff were included in the study, thus raising the question of whether a larger patient population would have provided a more conclusive statistical analysis. As no studies have investigated the effect of upper extremity dominance on clinical outcomes in TSA so far, only a post hoc power analysis could be performed. To assess the impact of our results on future studies, we conducted sample size calculations using our data. With 80% power at an alpha level of .05, sample sizes required for variables evaluated in this study were approximated to range well over 60 to 91 per group. The large sample sizes needed affected to a degree the small, clinically irrelevant differences observed between the groups. Of note, the sample size estimation for postoperative forward elevation by hand dominance (60 per group) was substantially lower than the other variables. The difference in postoperative forward elevation of 13.1 favoring dominant-handed patients may be clinically meaningful, prompting increased attention toward a potential type II error. This may also reflect the preferential use of the dominant extremity and greater patient motivation to regain motion of the dominant extremity postoperatively.

In addition, with this study only reporting on outcomes of a single surgeon's practice, external validity may be limited in terms of both the patient population and the surgical technique. Last, this study was limited to its short mean follow-up period of 36.5 months. However, complications or poorer outcomes related to surgeon handedness may also occur at short-term follow-up. Yet, as the initial hypothesis was rejected, longer term follow-up periods are required to adequately investigate functional outcomes as affected by surgeon handedness. However, outcomes or complications at long-term follow-up may also be influenced by complex secondary findings such as prosthesis design (survival rate), patients' compliance, or glenoid abrasive wear.

## CONCLUSION

With the numbers available, surgeon and patient upper extremity dominance did not have a significant influence on functional outcomes after primary TSA with regard to patient-reported clinical scores and range of motion at short-term follow-up.

## REFERENCES

1. Barnes CJ, Van Steyn SJ, Fischer RA. The effects of age, sex, and shoulder dominance on range of motion of the shoulder. *J Shoulder Elbow Surg.* 2001;10(3):242-246.



2. Bryant D, Litchfield R, Sandow M, Gartsman GM, Guyatt G, Kirkley A. A comparison of pain, strength, range of motion, and functional outcomes after hemiarthroplasty and total shoulder arthroplasty in patients with osteoarthritis of the shoulder: a systematic review and meta-analysis. *J Bone Joint Surg Am*. 2005;87(9):1947-1956.
3. Canakci V, Cicek Y, Canakci CF, et al. Effect of handedness on learning subgingival scaling with curettes: a study on manikins. *Int J Neurosci*. 2004;114(11):1463-1482.
4. Cil A, Veillette CJ, Sanchez-Sotelo J, Sperling JW, Schleck CD, Cofield RH. Survivorship of the humeral component in shoulder arthroplasty. *J Shoulder Elbow Surg*. 2010;19(1):143-150.
5. Collin P, Tay AK, Melis B, Boileau P, Walch G. A ten-year radiologic comparison of two-all polyethylene glenoid component designs: a prospective trial. *J Shoulder Elbow Surg*. 2011;20(8):1217-1223.
6. Conte AL, Marques AP, Casarotto RA, Amado-Joao SM. Handedness influences passive shoulder range of motion in nonathlete adult women. *J Manipulative Physiol Ther*. 2009;32(2):149-153.
7. Cvetanovich GL, Chalmers PN, Streit JJ, Romeo AA, Nicholson GP. Patients undergoing total shoulder arthroplasty on the dominant extremity attain greater postoperative ROM. *Clin Orthop Relat Res*. 2015;473(10):3221-3225.
8. Cvetanovich GL, Gowd AK, Liu JN, et al. Establishing clinically significant outcome after arthroscopic rotator cuff repair. *J Shoulder Elbow Surg*. 2019;28(5):939-948.
9. Day JS, Lau E, Ong KL, Williams GR, Ramsey ML, Kurtz SM. Prevalence and projections of total shoulder and elbow arthroplasty in the United States to 2015. *J Shoulder Elbow Surg*. 2010;19(8):1115-1120.
10. Diederichsen LP, Norregaard J, Dyhre-Poulsen P, et al. The effect of handedness on electromyographic activity of human shoulder muscles during movement. *J Electromyogr Kinesiol*. 2007;17(4):410-419.
11. Edouard P, Degache F, Beguin L, et al. Rotator cuff strength in recurrent anterior shoulder instability. *J Bone Joint Surg Am*. 2011;93(8):759-765.
12. Edwards TB, Kadakia NR, Boulahia A, et al. A comparison of hemiarthroplasty and total shoulder arthroplasty in the treatment of primary glenohumeral osteoarthritis: results of a multicenter study. *J Shoulder Elbow Surg*. 2003;12(3):207-213.
13. Fox TJ, Cil A, Sperling JW, Sanchez-Sotelo J, Schleck CD, Cofield RH. Survival of the glenoid component in shoulder arthroplasty. *J Shoulder Elbow Surg*. 2009;18(6):859-863.
14. Godeneche A, Boileau P, Favard L, et al. Prosthetic replacement in the treatment of osteoarthritis of the shoulder: early results of 268 cases. *J Shoulder Elbow Surg*. 2002;11(1):11-18.
15. Gonzalez JF, Alami GB, Baque F, Walch G, Boileau P. Complications of unconstrained shoulder prostheses. *J Shoulder Elbow Surg*. 2011;20(4):666-682.
16. Gowd AK, Charles MD, Liu JN, et al. Single Assessment Numeric Evaluation (SANE) is a reliable metric to measure clinically significant improvements following shoulder arthroplasty. *J Shoulder Elbow Surg*. 2019;28(11):2238-2246.
17. Grantcharov T, Bardram L, Funch-Jensen P, Rosenberg J. Impact of hand dominance, gender, and experience with computer games on performance in virtual reality laparoscopy. *Surg Endosc*. 2003;17(7):1082-1085.
18. Haines JF, Trail IA, Nuttall D, Birch A, Barrow A. The results of arthroplasty in osteoarthritis of the shoulder. *J Bone Joint Surg Br*. 2006;88(4):496-501.
19. Hanna GB, Drew T, Clinch P, et al. Psychomotor skills for endoscopic manipulations: differing abilities between right and left-handed individuals. *Ann Surg*. 1997;225(3):333.
20. Harris JD, Brand JC, Cote MP, Faucett SC, Dhawan A. Research pearls: the significance of statistics and perils of pooling. Part 1: clinical versus statistical significance. *Arthroscopy*. 2017;33(6):1102-1112.
21. Healey JM, Liederman J, Geschwind N. Handedness is not a unidimensional trait. *Cortex*. 1986;22(1):33-53.
22. Jung P, Baumgartner U, Magerl W, Treede RD. Hemispheric asymmetry of hand representation in human primary somatosensory cortex and handedness. *Clin Neurophysiol*. 2008;119(11):2579-2586.
23. Keener JD, Steger-May K, Stobbs G, Yamaguchi K. Asymptomatic rotator cuff tears: patient demographics and baseline shoulder function. *J Shoulder Elbow Surg*. 2010;19(8):1191-1198.
24. LeBlanc JE, MacDermid JC, Faber KJ, Drosdowech DS, Athwal GS. Outcomes after hemiarthroplasty for proximal humerus fracture are significantly affected by hand dominance. *J Orthop Trauma*. 2015;29(8):379-383.
25. Lippitt S. A practical tool for evaluating shoulder function: the Simple Shoulder Test. In: *The Shoulder: A Balance of Mobility and Stability*. Rosemont, IL: American Academy of Orthopaedic Surgeons. 1993:501-518.
26. Mehta S, Lotke PA. Impact of surgeon handedness and laterality on outcomes of total knee arthroplasties: should right-handed surgeons do only right TKAs? *Am J Orthop (Belle Mead NJ)*. 2007;36(10):530-533.
27. Norris TR, Iannotti JP. Functional outcome after shoulder arthroplasty for primary osteoarthritis: a multicenter study. *J Shoulder Elbow Surg*. 2002;11(2):130-135.
28. Pennington N, Redmond A, Stewart T, Stone M. The impact of surgeon handedness in total hip replacement. *Ann R Coll Surg Engl*. 2014;96(6):437-441.
29. Pool EM, Rehme AK, Fink GR, Eickhoff SB, Grefkes C. Handedness and effective connectivity of the motor system. *Neuroimage*. 2014;99:451-460.
30. Pouw L, Tulloh B. Laparoscopic cholecystectomy for the left-handed surgeon. *Br J Surg*. 1995;82(1):138.
31. Radnay CS, Setter KJ, Chambers L, Levine WN, Bigliani LU, Ahmad CS. Total shoulder replacement compared with humeral head replacement for the treatment of primary glenohumeral osteoarthritis: a systematic review. *J Shoulder Elbow Surg*. 2007;16(4):396-402.
32. Richards RR, An KN, Bigliani LU, et al. A standardized method for the assessment of shoulder function. *J Shoulder Elbow Surg*. 1994;3(6):347-352.
33. Routman HD, Flurin PH, Wright TW, Zuckerman JD, Hamilton MA, Roche CP. Reverse shoulder arthroplasty prosthesis design classification system. *Bull Hosp Jt Dis (2013)*. 2015;73(suppl 1):S5-S14.
34. Sauers EL, Borsa PA, Herling DE, Stanley RD. Instrumented measurement of glenohumeral joint laxity and its relationship to passive range of motion and generalized joint laxity. *Am J Sports Med*. 2001;29(2):143-150.
35. Schueneman A, Pickleman J, Freeark R. Age, gender, lateral dominance, and prediction of operative skill among general surgery residents. *Surgery*. 1985;98(3):506-515.
36. Semmler JG, Nordstrom MA. Hemispheric differences in motor cortex excitability during a simple index finger abduction task in humans. *J Neurophysiol*. 1998;79(3):1246-1254.
37. Torchia ME, Cofield RH, Settergren CR. Total shoulder arthroplasty with the Neer prosthesis: long-term results. *J Shoulder Elbow Surg*. 1997;6(6):495-505.
38. Volkmann J, Schnitzler A, Witte OW, Freund H. Handedness and asymmetry of hand representation in human motor cortex. *J Neurophysiol*. 1998;79(4):2149-2154.