



NOTE

Surgery

Acute hemorrhagic diarrhea syndrome associated with contaminated foreign bodies (used feminine hygiene products) in a Golden Retriever dog

Seung-Il YANG^{1,2)}, Jung-Hyun KIM³⁾, Soon-Wuk JEONG²⁾ and Hyun-Jung HAN^{1)*}

¹⁾Department of Veterinary Emergency Medicine, Konkuk Veterinary Medical Teaching Hospital, Konkuk University, 120, Neungdong-ro, Gwangjin-gu, Seoul, 05029 Republic of Korea

²⁾Department of Veterinary Surgery, Konkuk Veterinary Medical Teaching Hospital, Konkuk University, 120, Neungdong-ro, Gwangjin-gu, Seoul, 05029 Republic of Korea

³⁾Department of Veterinary Internal Medicine, Konkuk Veterinary Medical Teaching Hospital, Konkuk University, 120, Neungdong-ro, Gwangjin-gu, Seoul, 05029 Republic of Korea

ABSTRACT. A one-year-old male Golden Retriever presented with acute onset of vomiting and hemorrhagic diarrhea since 2 days. The dog was depressed, showing abdominal pain, 12% dehydration, tachycardia, and a bounding pulse. Diagnostic imaging showed severe dilatation and fluid retention of the entire gastrointestinal tract with decreased motility. A foreign body was found in the gastroduodenal region, but there was no obstruction or plication. The dog was tentatively diagnosed with acute hemorrhagic diarrhea syndrome and rapidly recovered after supportive treatment. However, on the morning of day 4, anorexia and vomiting recurred, and diagnostic imaging revealed intestinal plication with free peritoneal fluid, not found on the previous image. An emergency laparotomy revealed the foreign body to be two used feminine hygiene products. These contaminated products were suspected to induce acute hemorrhagic diarrhea syndrome, and led to subsequent complication in this large dog.

KEY WORDS: acute hemorrhagic diarrhea syndrome, contaminated foreign bodies, dog, feminine hygiene product, tampon

J. Vet. Med. Sci.
80(4): 629–633, 2018
doi: 10.1292/jvms.17-0633

Received: 24 November 2017
Accepted: 7 February 2018
Published online in J-STAGE:
20 February 2018

Acute hemorrhagic diarrhea has numerous causes and includes idiopathic hemorrhagic gastroenteritis, known as acute hemorrhagic diarrhea syndrome (AHDS) [1, 9]. Although the etiology of AHDS is currently unclear, gastrointestinal infection (from specific pathogenic bacteria) is thought to be associated with AHDS in human and veterinary fields; certain enterotoxigenic strains of *Escherichia coli* lead to hemorrhagic enteritis in humans, and *Clostridium-related* toxins are associated with the pathogenesis of AHDS in dogs [2–4, 7, 10, 13, 15, 16].

In this case report, contaminated foreign bodies were strongly suspected to induce AHDS via intestinal bacterial dysbiosis. In particular, a tampon, identified as one of the contaminated foreign bodies in the dog, is highly infectious and can stimulate toxic shock syndrome toxin 1 (TSST-1) via *staphylococci* bacteria in human beings [6, 14].

This report describes the clinical signs, diagnosis, treatment, and outcome of AHDS associated with heavily contaminated foreign bodies (used feminine hygiene products) in a Golden Retriever dog. To the author's knowledge, there are currently no reports of AHDS associated with contaminated foreign bodies in small animals.

A one-year-old castrated male Golden Retriever weighing 27 kg presented with acute onset of vomiting and profuse hematochezia since 2 days. The owner found the dog rummaging through the garbage can in the bathroom; after three days, the dog had shown intermittent vomiting. The previous day, malodorous, watery, and bloody diarrhea followed the onset of vomiting. Upon physical examination, the dog was depressed and tachycardic (220 beats/min), with a bounding pulse and rapid capillary refill time (below one sec); the dog's temperature was normal at 39°C. The dog was 12% dehydrated, and showing abdominal pain and generalized tremor. Profuse, watery, and projectile hematochezia was detected during the examination (Fig. 1). The dog's history, clinical signs, and physical examination were indicative of hypovolemic shock, and fluid resuscitation was immediately started. The dog was stabilized with oxygen supplementation and large volume resuscitation with two 500 ml boluses of lactated ringer's solution. After resuscitation, a constant rate infusion at 130 ml/kg/day of lactated ringer's solution and butorphanol were

*Correspondence to: Han, H.-J.: ab1234@konkuk.ac.kr

©2018 The Japanese Society of Veterinary Science



This is an open-access article distributed under the terms of the Creative Commons Attribution Non-Commercial No Derivatives (by-nc-nd) License. (CC-BY-NC-ND 4.0: <https://creativecommons.org/licenses/by-nc-nd/4.0/>)

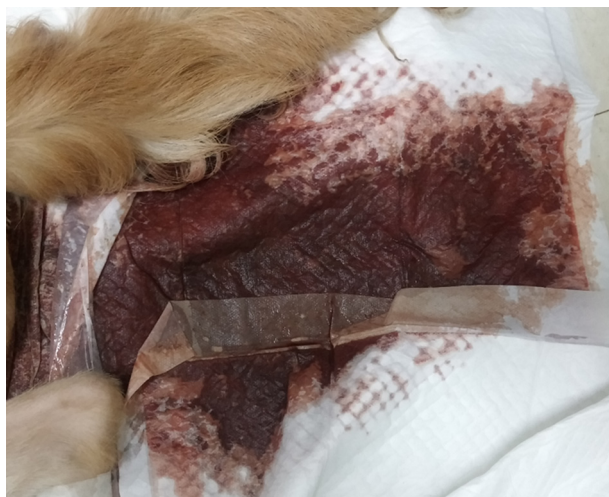

Fig. 1. Profuse, watery, and projectile hematochezia was detected as an initial clinical sign in the dog.

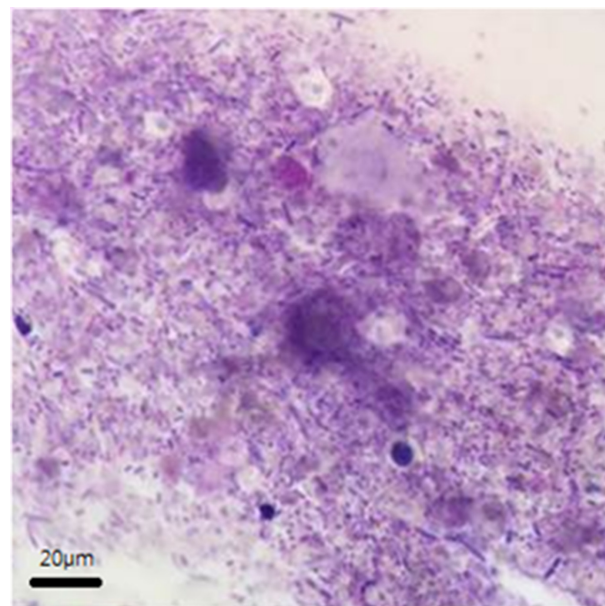


Fig. 2. A highly polymorphic, mixed bacterial flora was detected in fecal cytology at initial presentation.

administered intravenously.

Blood examination results were as follows: hemoconcentration, 65.5% (HCT reference range, 37.3–61.7%); hyperlactatemia, 5.26 mg/dl (reference range, 0.5–2.5 mg/dl); hypokalemia, 3.2 mmol/l (reference range, 3.5–5.8 mmol/l); hypochloremia, 108 mmol/l (reference range, 109–122 mmol/l); normal blood pH, 7.38 (reference range, 7.31–7.42). Increased alanine aminotransferase (140 U/l; reference range 10–100 U/l), aspartate aminotransferase (178 U/l; reference range, 0–50 U/l), alkaline phosphatase (227 U/l; reference range, 23–212 U/l) and hyperphosphatemia (8.5 mg/dl; reference range, 2.5–6.8 mg/dl) values were found. Prothrombin and activated partial thromboplastin times were delayed by 21 and 163 sec, respectively (reference ranges, 11–17 and 72–102 sec, respectively), and both C-reactive protein (100 mg/l; reference range, 0–35 mg/l) and D-dimer (0.4 mg/dl; reference range 0.1–0.3 mg/dl) values were increased.

On fecal examination, viral and parasitic infections were excluded; bacterial overgrowth was observed in fecal cytology, but specific pathogenic bacteria, including *Clostridium* and *Campylobacter* species, were not confirmed (Fig. 2).

Abdominal radiography and ultrasonography images revealed a fluid-filled and markedly distended stomach, small and large intestines with decreased gastrointestinal motility, and an approximately 44.5 mm hyperechoic foreign body in the proximal duodenum. There was no intestinal plication or obstruction due to the foreign body. To confirm the size and location of the foreign body, a computed tomography (CT) scan (LightSpeed; GE Medical System, Milwaukee, WI, U.S.A.) was obtained without general anesthesia (the owner expressly wished to avoid the high risk of anesthesia due to the dog's unstable condition; given the dog's quiet, depressed state, CT examination was possible without anesthesia). The CT scan revealed a 55 mm-long-linear-foreign-body located from the pylorus to the proximal duodenum, and the entire gastrointestinal tract was distended with gravity dependent fluid-attenuating materials (Fig. 3). The foreign body was not considered the cause of the hemorrhagic diarrhea at that time, as it was relatively small (for this size of the dog) and was not causing obstruction or plication. At this point, considering the small relative size of the foreign body, and the owner's decline for anesthetic procedures, including surgery or endoscopy, we decided to monitor the foreign body, rather than remove it. There was no evidence of pancreatitis on SNAP cPL test and ultrasound examination.

After excluding other possible causes of hemorrhagic diarrhea, based on clinical signs and examinations, the dog was tentatively diagnosed with AHDS, and treatment commenced accordingly. Treatment consisted of fluid therapy (lactated ringer's solution 130 ml/kg/day constant rate infusion), antiemetic therapy (maropitant 1 mg/kg SC, q 24 hr), gastric antacids (famotidine 0.5 mg/kg IV, q 8 hr), analgesics (butorphanol 0.4 mg/kg IV, q 6 hr, to q 8 hr), and antibiotics (amoxicillin 11 mg/kg IV, q 8 hr; metronidazole 15 mg/kg IV, q 12 hr). After alleviation of vomiting, oral medications including omeprazole (1 mg/kg q 24 hr) and sucralfate (1 g, q 12 hr) and a gastrointestinal diet were added.

The dog recovered rapidly after treatment onset. Clinical improvement was assessed by means of the 'AHDS index' (Table 1) [9]; on the day of presentation (day 1), the dog had severe AHDS with a high AHDS score of 17, followed an AHDS score of 8 on day 2, and 2 on day 3 (Table 1). All clinical signs were alleviated with normal appetite, no vomiting, and very moist but distinct log-shaped feces on day 3, and all abnormal laboratory parameters returned to normal. On fecal examination, the number of bacteria were markedly decreased. The dog was expected to be discharged on day 4.

However, on the morning of day 4, the dog showed anorexia and vomiting. Several laboratory parameters were again increased, including neutrophilic leukocytes (21.4×10^3 white cells/ μ l; reference range $5.05\text{--}16.76 \times 10^3$ white cells/ μ l) and C-reactive

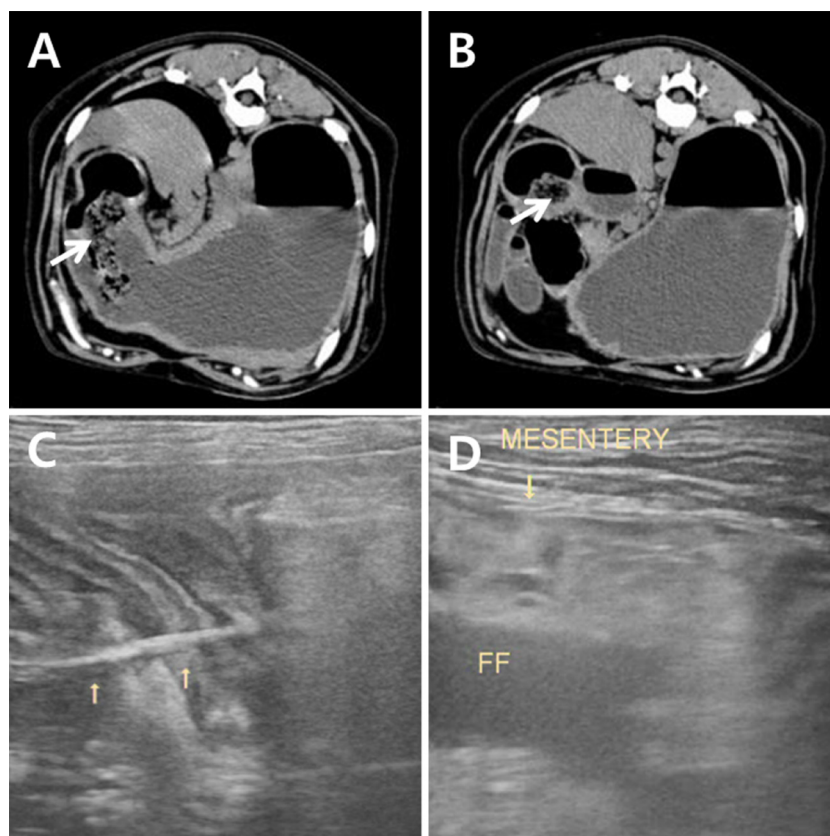


Fig. 3. (A) and (B) On the day of presentation, a computed tomography scan revealed an approximately 55-mm-linear-foreign-body (arrows) from the pylorus (A) to the proximal duodenum (B). There was no gastrointestinal plication or obstruction, except severe distention of the entire gastrointestinal tract with gravity dependent fluid-attenuating materials. (C) On day 4 of hospitalization, the linear foreign body (arrows) induced plication and obstruction of the gastroduodenum; (D) hyperechoic mesentery (arrow) and a small amount of free peritoneal fluid (FF) were detected in the right cranial abdomen.

Table 1. Clinical improvement of the dog was assessed by the acute hemorrhagic diarrhea syndrome (AHDS) index clinical severity score [9]

AHDS score	0	1	2	3	AHDS score at the day of hospitalization in this dog		
					Day 1	Day 2	Day 3
Activity	Normal	Mildly reduced	Moderately reduced	Severely reduced	3	2	0
Appetite	Normal	Mildly reduced	Moderately reduced	Severely reduced	3	2	0
Vomiting (times/day)	0	1	2–3	3<	2	0	0
Fecal consistency	Normal	Slightly soft	Very soft	Watery diarrhea	3	2	1
Defecation (times/day)	1	2–3	4–5	5<	3	2	1
Dehydration (%)	0	5<	5–10	10<	3	0	0
Total AHDS score					17	8	2

proteins (58 mg/l; reference range, 0–35 mg/l). Abdominal ultrasonography revealed several new findings, not detected in previous diagnostic imaging, including plication of the small intestine, hyperechoic mesentery, and a small amount of free peritoneal fluid in the right cranial abdomen (Fig. 3).

After consultation with the owners, an emergency laparotomy was performed under general anesthesia. During surgery, there was approximately 30 cm of intestinal plication with a palpable linear foreign body from the pylorus to the proximal jejunum, with evidence of multiple perforations in the duodenojejunal flexure region (Fig. 4). Through gastrotomy, duodenotomy, and duodenojejunal anastomosis, the foreign bodies, which comprised of fabric and strings that were later identified by the owners as a sanitary pad and tampon, were removed (Fig. 4). After omental flaps in the anastomosis region, prophylactic incisional gastropexy, and abdominal lavage, a routine abdominal closure was performed. The dog made an uneventful recovery postoperatively, and was

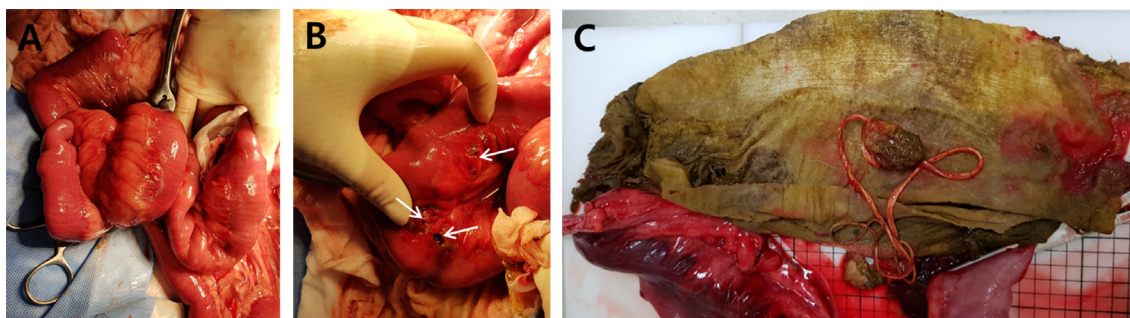


Fig. 4. (A) Approximately 30 cm of intestinal plication with a palpable linear foreign body was detected from the pylorus to proximal jejunum. (B) Multiple intestinal perforations (arrows) were found on the mesentery border of the duodeno-jejunal flexure region. (C) The linear foreign body was identified as a used tampon and sanitary pad.

discharged from the hospital with a normal condition.

To diagnose AHDS, other possible causes of acute hemorrhagic diarrhea, including drug administration (non-steroidal anti-inflammatory drugs, corticosteroids, doxycycline intoxication), gastrointestinal disease (neoplasia, intussusception, foreign body), infectious disease (nematode or protozoan parasites, parvovirus infection, infection of *Salmonella*, *Yersinia*, *Campylobacter* species), organ dysfunction (azotemia, liver failure, pancreatitis), coagulopathy, and systemic disease (Addison's disease, disseminated intravascular coagulation), should be excluded [9]. In this case report, clinical signs and lesions in the dog were similar to those reported in previous studies of AHDS, including acute profuse hemorrhagic diarrhea, hypovolemic shock, hemoconcentration due to severe dehydration, and intestinal fluid retention and dilatation without obstruction. All other potential causes of hemorrhagic diarrhea were excluded; we excluded the foreign body at initial presentation as it was not causing mechanical obstruction of the gastrointestinal tract at the time, and the dog's clinical signs were inconsistent with the location of the foreign body. Acute hemorrhagic diarrhea is not a typical clinical sign of a gastroduodenal foreign body; signs are usually non-specific, such as anorexia, vomiting, abdominal discomfort, lethargy, and, uncommonly, nonhemorrhagic diarrhea [5].

Thus, we focused on the associated infection. In human medicine, pathogenic bacteria and toxicity related to tampons are reported; specifically, tampons may retain toxic organisms, known as TSST-1, produced by staphylococci [6, 14]. During menstruation, the vagina provides a good environment for the growth for staphylococci producing TSST-1, and tampons may stimulate toxin production by exposing the vagina to additional oxygen [6, 14]. Therefore, tampons could be highly contagious, holding the staphylococci and related toxins, and thus able to induce gastrointestinal infection and dysbacteriosis. In addition, the foreign bodies were in the garbage can for some time, and therefore were likely to be more heavily contaminated. Thus, AHDS, caused by suspected pathogenic bacteria from the contaminated foreign bodies, was tentatively diagnosed in this dog, even though specific pathogenic bacteria were not confirmed. We suspect that these heavily contaminated foreign bodies could explain why AHDS occurred in this large breed dog, which is rarely affected, whilst it usually affects small breed dogs with unknown causes.

The treatment protocol for AHDS is well established and effective, including aggressive fluid therapy, antiemetics, gastric antacids, analgesics, and a gastrointestinal diet [9]. Rapid clinical improvement is usually observed during the first 48 hr after these supportive therapies, but the disease can rapidly progress to death if not treated promptly [15]. Among these therapies, the usefulness of antibiotics is debated. In dogs with intestinal diseases, antibiotics are indicated only in cases where enteropathogenic bacteria are identified in fecal or blood samples, there is a predisposition toward bacterial translocation (such as disruptions to the intestinal mucosal barrier), and there is increased possibility of sepsis due to a compromised host defense mechanism [18]. In dogs with AHDS, acute mucosal necrosis is confirmed, and a destroyed intestinal mucosal barrier may increase the risk of bacterial translocation and sepsis [17]. In addition, a more recent molecular study reported that an ongoing intestinal dysbacteriosis in dogs outlasted intestinal inflammation with AHDS [4]. The study presented an abundance of selected bacterial groups, indicating that intestinal dysbacteriosis were unchanged over time, whilst biomarkers of gastrointestinal inflammation and protein loss were significantly decreased by day 3 of treatment [4]. Dysbacteriosis may also increase the risk of bacterial translocation. Therefore, theoretically, antibiotics could be recommended for the treatment of AHDS due to the increased risk of bacterial translocation. However, in clinical studies of AHDS in dogs, antibiotics were not recommended as they were not found to affect the treatment outcome, recovery period, or mortality of dogs with AHDS; moreover, the incidence of bacteremia in dogs with AHDS was low [17, 18]. In addition, antibiotics may induce several complications, including disrupting protective intestinal flora, stimulating bacterial toxin production, such as *clostridium difficile* toxin A, and causing antibiotic resistance; however, these adverse effects have not yet been reported in dogs with AHDS [5, 17, 18]. In this case report, the dog recovered rapidly after symptomatic therapy. All clinical signs, including vomiting and hematochezia, resolved immediately after initial medical treatment, and abnormal laboratory parameters returned to normal by days 3. In this case, antibiotics from the initial treatment were administered. We considered that there was an increased possibility of dysbacteriosis due to the contaminated foreign bodies and bacterial translocation suggested by profuse hematochezia, indicative of acute intestinal mucosal destruction. Therefore, we used antibiotics prophylactically, and bacterial overgrowth was alleviated accordingly, with no adverse effects associated with antibiotic use. The association between specific pathogenic bacteria and AHDS was not clarified, and the risk of bacterial translocation in dogs with

AHDS may not be completely excluded; therefore, further studies are required to explore the use of antibiotics in dogs with AHDS, especially to identify which dogs are at high risk of bacterial translocation requiring antibiotic treatment.

In this dog, after successful treatment of AHDS, complications unrelated to AHDS occurred. At initial presentation, we anticipated that the foreign body could pass through the gastrointestinal tract without inducing gastrointestinal problems, given that it was relatively short and small for the dog's size. However, the foreign body belatedly induced gastrointestinal plication, as the tampon and sanitary pad became linear in shape and changed size as time passed after ingestion. This complication may have been associated with the initial shape of the foreign body, and increased gastrointestinal motility. Most users roll up tampons and sanitary pads prior to disposal, such that their shape and size is smaller. However, after recovery from AHDS, the rolled tampon/sanitary pads became unraveled, due to increased gastrointestinal motility, and thus larger and longer than their initial size at ingestion. They were approximately 44.5 to 55.0 mm in length on diagnostic imaging at initial presentation, and almost 300 mm in length in fact. Moreover, tampons are composed of a cotton body with attached string; in this case, the tampon became linear in shape as the cotton body became lodged at the pylorus and the string unraveled.

A limitation to this study is that no specific organism, considered to have induced AHDS, was confirmed, even though such organisms were thought to have originated from the contaminated foreign bodies. There are many difficulties in defining an apparent association between intestinal organisms and AHDS; for example, known pathogenic organisms, such as *Clostridium perfringens* and *Clostridium difficile*, have also been found in normal dogs [2, 8, 11–13, 19]. Therefore, further research is required to identify which pathogenic organisms cause AHDS, particularly those relevant to veterinary medicine.

In this study, AHDS was suspected after ingestion of contaminated foreign bodies, including a used tampon and sanitary pad. The foreign bodies did not cause mechanical obstruction of the gastrointestinal tract at initial presentation, and thus, were suspected of causing intestinal dysbacteriosis due to their high contagiousness. After successful treatment of AHDS, unrelated complications occurred; the tampon and sanitary pad became linear-shaped, inducing intestinal plication. This is the first case report of suspected AHDS associated with contaminated foreign bodies and unrelated complications.

REFERENCES

- Burrows, C. F. 1977. Canine hemorrhagic gastroenteritis. *J. Am. Anim. Hosp. Assoc.* **13**: 451–458.
- Busch, K., Suchodolski, J. S., Kühner, K. A., Minamoto, Y., Steiner, J. M., Mueller, R. S., Hartmann, K. and Unterer, S. 2015. *Clostridium perfringens* enterotoxin and *Clostridium difficile* toxin A/B do not play a role in acute haemorrhagic diarrhoea syndrome in dogs. *Vet. Rec.* **176**: 253. [Medline] [CrossRef]
- Cave, N. J., Marks, S. L., Kass, P. H., Melli, A. C. and Brophy, M. A. 2002. Evaluation of a routine diagnostic fecal panel for dogs with diarrhea. *J. Am. Vet. Med. Assoc.* **221**: 52–59. [Medline] [CrossRef]
- Heilmann, R. M., Guard, M. M., Steiner, J. M., Suchodolski, J. S. and Unterer, S. 2017. Fecal markers of inflammation, protein loss, and microbial changes in dogs with the acute hemorrhagic diarrhea syndrome (AHDS). *J. Vet. Emerg. Crit. Care (San Antonio)* **27**: 586–589. [Medline] [CrossRef]
- Hobday, M. M., Pachtinger, G. E., Drobatz, K. J. and Syring, R. S. 2014. Linear versus non-linear gastrointestinal foreign bodies in 499 dogs: clinical presentation, management and short-term outcome. *J. Small Anim. Pract.* **55**: 560–565. [Medline] [CrossRef]
- Jaulhac, B., De Buyser, M. L., Dilasser, F., Prevost, G. and Piedmont, Y. 1991. Screening of *staphylococci* for the toxic shock syndrome toxin-1 (TSST-1) gene. *Lett. Appl. Microbiol.* **13**: 90–92. [Medline] [CrossRef]
- Marks, S. L., Kather, E. J., Kass, P. H. and Melli, A. C. 2002. Genotypic and phenotypic characterization of *Clostridium perfringens* and *Clostridium difficile* in diarrheic and healthy dogs. *J. Vet. Intern. Med.* **16**: 533–540. [Medline] [CrossRef]
- Marks, S. L., Melli, A., Kass, P. H., Jang, S. S., Barkhoodarian, A. and Hirsh, D. C. 1999. Evaluation of methods to diagnose *Clostridium perfringens*-associated diarrhea in dogs. *J. Am. Vet. Med. Assoc.* **214**: 357–360. [Medline]
- Mortier, F., Strohmeyer, K., Hartmann, K. and Unterer, S. 2015. Acute haemorrhagic diarrhoea syndrome in dogs: 108 cases. *Vet. Rec.* **176**: 627. [Medline] [CrossRef]
- Sasaki, J., Goryo, M., Asahina, M., Makara, M., Shishido, S. and Okada, K. 1999. Hemorrhagic enteritis associated with *Clostridium perfringens* type A in a dog. *J. Vet. Med. Sci.* **61**: 175–177. [Medline] [CrossRef]
- Songer, J. G. 1996. Clostridial enteric diseases of domestic animals. *Clin. Microbiol. Rev.* **9**: 216–234. [Medline]
- Struble, A. L., Tang, Y. J., Kass, P. H., Gumerlock, P. H., Madewell, B. R. and Silva, J. Jr. 1994. Fecal shedding of *Clostridium difficile* in dogs: a period prevalence survey in a veterinary medical teaching hospital. *J. Vet. Diagn. Invest.* **6**: 342–347. [Medline] [CrossRef]
- Suchodolski, J. S., Markel, M. E., Garcia-Mazcorro, J. F., Unterer, S., Heilmann, R. M., Dowd, S. E., Kachroo, P., Ivanov, I., Minamoto, Y., Dillman, E. M., Steiner, J. M., Cook, A. K. and Toresson, L. 2012. The fecal microbiome in dogs with acute diarrhea and idiopathic inflammatory bowel disease. *PLoS One* **7**: e51907. [Medline] [CrossRef]
- Tang, Y. W., Himmelfarb, E., Wills, M. and Stratton, C. W. 2010. Characterization of three *Staphylococcus aureus* isolates from a 17-year-old female who died of tampon-related toxic shock syndrome. *J. Clin. Microbiol.* **48**: 1974–1977. [Medline] [CrossRef]
- Triolo, A. and Lappin, M. R. 2003. Acute medical diseases of the small intestine. pp. 195–210. In: *Handbook of Small Animal Gastroenterology*, 2nd ed. (Tams, T. R. ed.). Elsevier Science, Philadelphia.
- Unterer, S., Busch, K., Leipzig, M., Hermanns, W., Wolf, G., Straubinger, R. K., Mueller, R. S. and Hartmann, K. 2014. Endoscopically visualized lesions, histologic findings, and bacterial invasion in the gastrointestinal mucosa of dogs with acute hemorrhagic diarrhea syndrome. *J. Vet. Intern. Med.* **28**: 52–58. [Medline] [CrossRef]
- Unterer, S., Lechner, E., Mueller, R. S., Wolf, G., Straubinger, R. K., Schulz, B. S. and Hartmann, K. 2015. Prospective study of bacteraemia in acute haemorrhagic diarrhoea syndrome in dogs. *Vet. Rec.* **176**: 309. [Medline] [CrossRef]
- Unterer, S., Strohmeyer, K., Kruse, B. D., Sauter-Louis, C. and Hartmann, K. 2011. Treatment of aseptic dogs with hemorrhagic gastroenteritis with amoxicillin/clavulanic acid: a prospective blinded study. *J. Vet. Intern. Med.* **25**: 973–979. [Medline] [CrossRef]
- Weese, J. S., Staempfli, H. R., Prescott, J. F., Kruth, S. A., Greenwood, S. J. and Weese, H. E. 2001. The roles of *Clostridium difficile* and enterotoxigenic *Clostridium perfringens* in diarrhea in dogs. *J. Vet. Intern. Med.* **15**: 374–378. [Medline] [CrossRef]