

Bladder neck contracture—incidence and management following contemporary robot assisted radical prostatectomy technique

Jaspreet Singh Parihar¹, Yun-Sok Ha^{1,2}, Isaac Yi Kim¹

¹Section of Urologic Oncology, Rutgers Cancer Institute of New Jersey, Rutgers, The State University of New Jersey, New Brunswick, NJ, USA

²Department of Urology, Kyungpook National University Medical Center, Daegu, Korea

Purpose: Bladder neck contracture (BNC) is a well-recognized complication following robot-assisted radical prostatectomy (RARP) for treatment of localized prostate cancer with a reported incidence of up to 1.4%. In this series, we report our institutional experience and management results.

Methods: A prospectively collected database of patients who underwent RARP by a single surgeon from 2006 to 2012 was reviewed. Watertight bladder neck to urethral anastomosis was performed over 18-French foley catheter. BNC was diagnosed by flexible cystoscopy in patients who developed symptoms of bladder outlet obstruction. Subsequently, these patients underwent cold knife bladder neck incisions. Patients then followed a strict self regimen of clean intermittent catheterization (CIC). We identify the patient demographics, incidence of BNC, associated risk factors and success of subsequent management.

Results: Total of 930 patients who underwent RARP for localized prostate cancer was identified. BNC was identified in 15 patients, 1.6% incidence. Mean patient age and preoperative prostate-specific antigen was 58.8 years old and 7.83 ng/mL (range, 2.5–14.55 ng/mL) respectively. Mean estimated blood loss was 361 ± 193 mL (range, 50–650 mL). Follow-up was mean of 23.4 months. Average time to BNC diagnosis was 5.5 months. In three patients, a foreign body was identified at bladder neck. On multivariate analysis, estimated blood loss was significantly associated with development of BNC. All patients underwent cystoscopy and bladder neck incision with a 3-month CIC regimen. Out of 15 index patients, none had a BNC recurrence over the follow-up period.

Conclusions: BNC was identified in 1.6% of patients in our series following RARP. Intraoperative blood loss was a significant risk factor for BNC. In 20% of BNC patients a migrated foreign body was noted at vesicourethral anastomosis. Primary management of patients with BNC following RARP should be bladder neck incision and self CIC regimen.

Keywords: Prostate cancer, Bladder neck contracture, Robotics

INTRODUCTION

In the era of robot-assisted radical prostatectomy, the incidence of post-operative bladder neck contracture (BNC) is reported to be up to 1.4% [1-9]. In comparison, a higher variability of range of 5% to 32% has been observed with open retropubic prostatectomy techniques [2,3,6,10,11]. Usually

resulting from scar tissue at the anastomosis between bladder neck and membranous urethra, BNC can result in post prostatectomy bladder outlet obstruction. The diagnosis should be suspected in patients with poor urinary stream or prolonged unexplained incontinence. Associated morbidity of BNC may include urinary retention, urinary incontinence, urinary tract infection and need for further surgical interventions.

Corresponding author: Isaac Yi Kim

Section of Urologic Oncology, Rutgers Cancer Institute of New Jersey, Rutgers, The State University of New Jersey, 195 Little Albany Street, New Brunswick, NJ 08903, USA

E-mail: kimiy@cinj.rutgers.edu / Tel: +1-732-235-2043 / Fax: +1-732-235-6596

Submitted: 5 December 2013 / Accepted after revision: 3 February 2014

Copyright © 2014 Asian Pacific Prostate Society (APPS)

This is an Open Access article distributed under the terms of the Creative Commons Attribution Non-Commercial License (<http://creativecommons.org/licenses/by-nc/3.0/>) which permits unrestricted non-commercial use, distribution, and reproduction in any medium, provided the original work is properly cited.

<http://p-international.org/>
pISSN: 2287-8882 • eISSN: 2287-903X

Although pathophysiology of BNC is multifactorial, preventing anastomotic leak and hematoma is important. Achieving watertight closure and meticulous mucosal apposition during vesicourethral anastomosis is crucial in preventing postoperative urine leakage leading to accumulation of urine [9-13]. Prolonged urine leakage resulting from anastomotic gap may lead to healing by secondary intent, subsequent scarring and contracture at the bladder neck. Hematoma may contribute to development of BNC due to distraction or tissue ischemia of anastomosis [13-15].

Contemporary robot-assisted surgical techniques offer a magnified stereoscopic view of tissue planes and improved precision and dexterity, contributing to a decrease in the anastomotic complications [2]. Various management techniques of BNC have been proposed in open prostatectomy patients; however, ideal treatment of such complications in the minimally invasive era is less well understood. In this large series of single institutional data, we evaluate the patient demographics, perioperative outcomes, incidence of BNC, associated risk factors and our experience of subsequent management.

MATERIALS AND METHODS

1. Patient cohort

Patients were prospectively enrolled into a Institutional Review Board approved database consisting of men with clinically localized prostate cancer undergoing robot-assisted radical prostatectomy (RARP) by a single surgeon (I.Y.K) from 2006 to 2012. The results were reviewed retrospectively. Primary and secondary endpoints were the incidence of BNC and associated risk factors respectively. Our protocol and results of management are also reported.

2. Surgical technique

Using daVinci Surgical Systems (Intuitive Surgical, Sunnyvale, CA, USA), radical prostatectomy was performed in an intraperitoneal antegrade fashion with initial dissection of bladder neck latero-posteriorly followed by seminal vesicles. Nerve sparing when indicated was performed without the use of electrocautery. Hem-o-lok surgical clips, titanium clips, as well as suture ligation with Lapra-Ty were occasionally utilized for hemostatic control of vascular pedicles. Watertight bladder neck to urethral anastomosis was performed over an 18-French catheter using the Van Velthoven technique [16] with a double armed 3-0 monocryl suture in a running fashion. Bladder was stressed with up to 140 mL of saline routinely to ensure anastomotic closure. Intrapelvic drains were rarely placed with majority removed on the following postop-

erative day. Patients were discharged home on postoperative day one with an 18-French foley catheter to gravity drainage. Catheter was removed at first postoperative visit in seven days.

3. Postoperative BNC

BNC was diagnosed by flexible cystoscopy in patients who developed signs and symptoms of bladder outlet obstruction. Subsequently, these patients underwent endoscopic bladder neck incisions using cold knife urethrotomy under anesthesia. Incisions were performed at 12, 3, and 9 o'clock position until bleeding of healthy tissue was noted along with easy passage of 21 French rigid cystoscope. No patient received intraoperative steroid instillation. Patients were then prescribed a strict self regimen of clean intermittent catheterization (CIC) using 16-French catheter once daily for one month, then every other day for one month, and finally once a week for one month.

4. Statistics

Patient demographics, perioperative detail, BNC related complications and follow-up information is analyzed and presented. Statistical measure of central tendency including mean, median, range, and standard deviation of clinical parameters were calculated. Comparison of perioperative variables including age, body mass index (BMI), preoperative prostate-specific antigen (PSA), prostate weight, pathologic stage, grade, estimated blood loss, operative time was performed using the Student *t*-test. Significant risk factors were analyzed through multivariate logistic regression analysis. *P*-value of <0.05 was considered statistically significant. SPSS ver. 12.0 (SPSS Inc., Chicago, IL, USA) was utilized.

RESULTS

Total of 930 consecutive patients were identified who underwent robot-assisted radical prostatectomy for localized prostate cancer. Patients were followed clinically for mean of 23.4 months; median follow-up was 24 months. BNC was identified in 15 patients, an incidence rate of 1.6%. Patient demographics are listed in Table 1. The two groups were similar in terms of age, BMI, preoperative PSA, prostate weight, pathologic stage, grade, and operative time. Mean patient age was 58.8 years old with an average preoperative total PSA of 7.83 ng/mL (range, 2.5-14.55 ng/mL). Mean operative time was 200 minutes. Mean estimated blood loss was 361 ± 193 mL (range, 50-650 mL).

Intraoperative blood loss was significantly greater in the cohort who developed BNC (*P*=0.001) (Table 2). Using logistic regression model, a multivariate analysis of the preop-

Table 1. Patient demographics

Patient	Age (yr)	BMI (kg/m ²)	OR time (min)	Estimated blood loss (mL)	Pre-op PSA (ng/mL)	Pathology	Gleason score	Prostate wt (g)	Margin status	Presentation	Time to BNC (mo)	OR findings
1	51	27	150	500	8.0	T2c	3+4	81	Negative	Urinary retention	2.6	
2	58	35	215	650	4.7	T3a	3+4	46	Positive (right posterior)	Urinary retention	14.0	
3	63	27	240	500	4.7	T2c	4+3	53	Negative	Hematuria/clot retention	8.6	
4	63	26	230	400	9.8	T2c	5+4	42	Negative	Difficulty voiding	2.2	
5	51	31	200	500	4.1	T2b	3+3	59	Negative	Difficulty voiding	3.8	
6	57	29	205	600	12.8	T2c	3+4	39	Negative	Difficulty voiding	7.0	
7	63	31	215	300	9.2	T3a	4+5	42	Negative	Difficulty voiding	4.5	
8	54	26	215	200	8.6	T2c	3+4	45	Negative	Difficulty voiding	3.3	
9	66	28	160	50	5.1	T2c	3+4	35	Positive (Apex)	Difficulty voiding	12.0	
10	61	21	130	100	7.3	T2c	3+4	37	Negative	Difficulty voiding	3.3	
11	65	26	240	500	14.6	T2c	3+3	41	Negative	Urinary retention	2.6	Lapra-Ty
12	50	29	215	350	5.4	T2c	3+4	38	Negative	Difficulty voiding	1.5	
13	57	28	195	100	13.0	T2c	3+3	59	Negative	Difficulty voiding	4.2	
14	66	32	-	-	-	-	-	-	-	Difficulty voiding	7 Years	Titanium staple
15	57	28	170	300	2.5	T2c	3+3	48	Negative	Difficulty voiding	7.1	Hem-o-lock

BMI, body mass index; OR, operation; Pre-op, preoperative; PSA, prostate-specific antigen; BNC, bladder neck contracture.

Table 2. Comparison of baseline characteristics

Variable	BNC (n= 14)	No BNC (n= 916)	P-value
Age (yr)	58.3±5.4	59.5±6.8	0.513
Preoperative PSA (ng/mL)	7.8±3.7	6.8±13.3	0.763
Prostate weight (g)	47.5±12.3	46.2±15.3	0.754
Pathologic T stage			0.748
≤T2	12 (85.7)	704 (76.9)	
≥T3	2 (14.3)	212 (23.1)	
Gleason score			0.532
≤6	4 (28.6)	397 (43.3)	
7	8 (57.1)	426 (46.5)	
≥8	2 (14.3)	93 (10.2)	
Estimated blood loss (mL)	360.7±193.3	220.1±157.1	0.001
Operation time (min)	198.6±33.9	201.5±47.4	0.818
Body mass index (kg/m ²)	27.9±3.3	28.4±5.0	0.705

Values are presented as mean ± standard deviation or number (%). PSA, prostate-specific antigen; BNC, bladder neck contracture.

erative variables indicates that intraoperative blood loss is a significant predictor for BNC development ($P < 0.001$) (Table 3). None of the patients who developed BNC had prior history of transurethral resection of prostate (TURP). Excluding one subject who developed BNC after 7 years, the remaining patients presented within 5.5 months (mean) and range up to 14 months in the postoperative interval. As demonstrated in Table 4, there was no difference in BNC rate from the first 500 to the last 430 cases analyzed in this study.

BNC was treated with cystoscopy and bladder neck incision under general anesthesia (Figs. 1, 2). In three patients,

Table 3. Multivariate logistic regression analysis for prediction of bladder neck contracture

Variable	OR (95% CI)	P-value
Age (yr)	0.968 (0.890–1.052)	0.442
Preoperative PSA (ng/mL)	1.003 (0.975–1.031)	0.829
Prostate weight (g)	1.003 (0.970–1.037)	0.869
Pathologic T stage (≤T2 vs. ≥T3)	0.344 (0.070–1.699)	0.190
Gleason score		
≤6	1.000	
7	2.548 (0.735–8.833)	0.140
≥8	5.809 (0.866–38.962)	0.070
Estimated blood loss (mL)	1.005 (1.002–1.008)	<0.001
Operation time (min)	0.989 (0.973–1.004)	0.156
Body mass index (kg/m ²)	0.951 (0.830–1.089)	0.469

PSA, prostate-specific antigen; OR, odds ratio; CI, confidence interval.

Table 4. Surgeon volume and BNC rates after RARP

	Surgeon volume		Total	P-value
	Before 500	After 500		
Total cases	500	430	930	0.426
No BNC				
Cases	491	425	916	
% Within surgeon volume	98.2%	98.8%	98.5%	
BNC				
Cases	9	5	14	
% Within surgeon volume	1.8%	1.2%	1.5%	

BNC, bladder neck contracture; RARP, robot-assisted radical prostatectomy.

migrated foreign body was identified at bladder neck (Fig. 3). First patient had Hem-o-lock clip, second patient had Lapra-

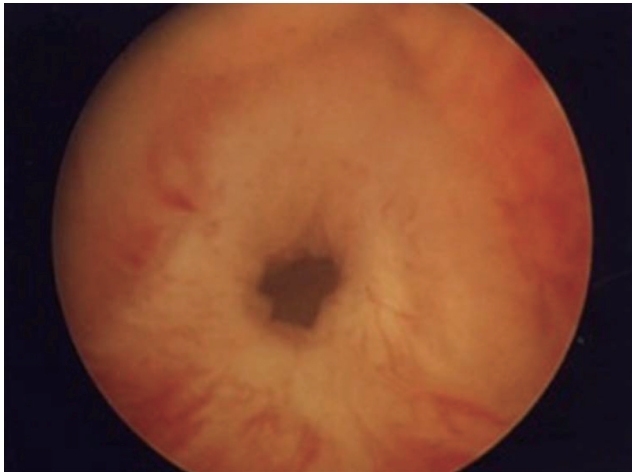


Fig. 1. Bladder neck contracture.

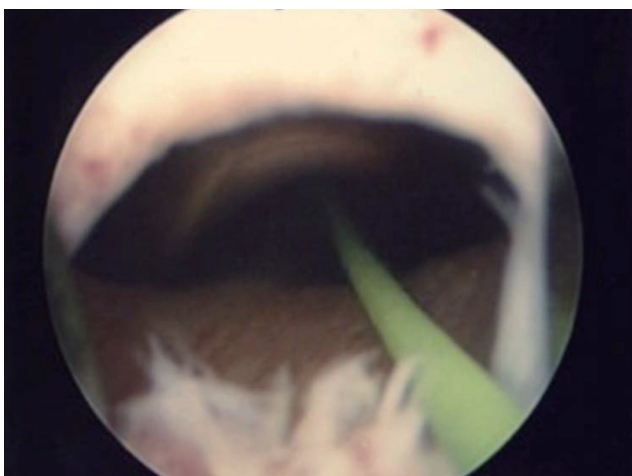


Fig. 2. BNC incised using cold knife urethrotomy.

Ty and third had a titanium surgical clip. Catheter was placed at the end of endoscopic urethrotomy procedure which was subsequently removed within one week post procedure. Patients were then provided with verbal and written instructions for CIC regimen for the next 3 months. Out of the 15 patients diagnosed with post prostatectomy BNC and further treated as described above, none had a recurrence over the follow-up period.

DISCUSSION

BNC has been encountered less frequently in the era of RARP (Table 5). Improved visual magnification and dexterity of robotic instruments have contributed to the observed difference [2,4]. Both surgical techniques and patient-related factors have been evaluated in contributing to development of BNC. Traditionally described risk factors include prior radiation,

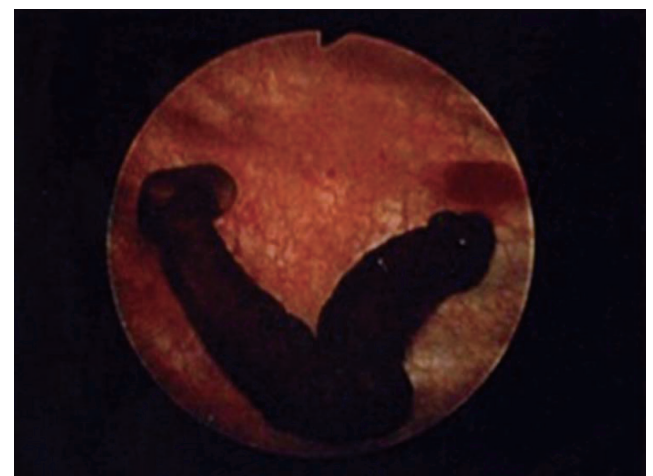

Fig. 3. Calcified Hem-o-lok clip identified during cystoscopy.

Table 5. Comparison of contemporary literature

Literature	Sample size	Follow-up period (mo)	Time to BNC (mo)	Surgical approach	BNC incidence	Management	Results
Webb et al. [9]	100	14.3	Median, 2.2	Robotic	None	-	-
Breyer et al. [2]	293	12.0	Median, 4.7; range (1–15)	Robotic	1.4%	Balloon dilation, rarely CKI	48% Required ≥ 2 treatments
Msezane et al. [3]	634	19.5	Mean, 4.8; range (3–12)	Robotic	1.1%	CKI	No recurrence
Carlsson et al. [4]	1253	19.0	<15	Robotic	0.2%	-	-
Hu et al. [5]	322	-	-	Robotic	0.6%	CKI	-
Menon et al. [6]	1,100	12.0	-	Robotic	0.8%	-	-
Coelho et al. [7]	2,500	Median 25	-	Robotic	0.1%	CKI	No recurrence
Zorn et al. [8]	300	17.3	-	Robotic	1.4%	CKI	No recurrence
Gonzalogo et al. [30]	246	13.7	4–6	Lap	1.2%	Dilation, CKI	No recurrence
Hu et al. [5]	358	-	-	Lap	2.2%	CKI	-
Rassweiler et al. [29]	180	Median 12	-	Lap	3.3%	Laser incision	-

BNC, bladder neck contracture; CKI, cold knife incision.

absence of mucosal eversion, poor vesicourethral mucosal apposition, urinary extravasation, increased blood loss, ischemia of bladder neck and excessive intraoperative narrowing at site of anastomosis [9,12].

In our series, out of 930 consecutive patients who underwent RARP for localized prostate cancer, BNC was noted in 15 patients, 1.6% incidence. Patients became symptomatic within mean of 5.5 months, excluding a single patient who became symptomatic of BNC at 7 years. Clinical history often included urinary symptoms of voiding difficulty, hesitancy, frequency, urgency or nocturia. Our findings are consistent with previously reported rates in literature [17] (Table 4).

In a retrospective analysis by Webb et al. [9], total of 200 consecutive patients were followed for mean of 39.8 months in the open radical prostatectomy (ORP) group and 14.3 months in the RARP group. Among the patients who underwent ORP ($n = 100$), 9 developed BNC. In the robot assisted arm ($n = 100$), none of the patients had similar complication. The time to occurrence of BNC in most patients was within 8 weeks.

Our results demonstrate that estimated blood loss is significantly associated with and is prognostic for the development of post robot-assisted radical prostatectomy BNC [17]. Excessive intraoperative bleeding can obscure vision of the operative field and may lead to imprecise dissection of tissue planes. This is particularly of greater consequence in laparoscopic and robot-assisted techniques where impaired visual cues may complicate the watertight mucosal apposition needed for vesicourethral anastomosis. Presence of hematoma or urinoma may lead to anastomotic ischemia and resultant scar formation. Garg and See [18] in their retrospective review of 294 radical retropubic prostatectomy patients reported that intraoperative blood loss greater than 1 L and urine leakage correlated to the formation of anastomotic stricture.

Elliott et al. [19] reviewed CaPSURE database to determine incidence of urethral strictures including BNC following primary treatment of clinically localized prostate cancer. Treatment modalities included watchful waiting, androgen deprivation therapy, radical prostatectomy, brachytherapy, external beam radiotherapy, cryotherapy and combination of these therapies. Among the 6,597 men with localized prostate cancer identified through the database, the overall stricture treatment rate was 5.2% (range, 1.1%–8.4% by prostate cancer treatment type). Radical prostatectomy was associated with the highest rate of stricture of 8.4%. In multivariate analysis, type of treatment (radical prostatectomy vs. watchful waiting; hazard ratio, 10.440 [95% confidence interval, 3.276–33.272]), BMI (obese vs. not overweight; hazard ratio, 2.254 [95% confidence interval, 1.566–3.244]) and age (≥ 70 years old vs. younger; hazard

ratio, 2.206 [95% confidence interval, 1.514–3.215]) were significant predictors of stricture treatment.

Although some series have identified prior TURP as a risk factor for BNC due to resulting fibrosis, it was not found to be the case in a large retrospective review by Borboroglu et al. [12]. Prior TURP, type of anastomotic suture used, size of catheter or duration of catheterization were not related to development of BNC. Interestingly, multivariate analysis of their results suggested current cigarette smoking as a strong predictor of BNC development ($P < 0.001$).

Treatment options must balance the therapies to promote bladder emptying while preserving urinary continence. Management can utilize self-dilation schedule, cystoscopic incision or resection, urethral stent, and bladder neck reconstruction for severe cases. Post prostatectomy BNC with mild degree of stenosis can be successfully treated with transurethral dilation or transurethral incision with a success range of 25% to 73% [12]. More fibrotic contractures may require bladder neck incision or even bladder neck resection. Popken et al. [10] retrospectively analyzed data from 340 radical prostatectomy patients over eight year period and found that 24 cases (7%) required transurethral endoscopic treatment. In their 12- to 72-month follow-up, no significant incontinence was observed. Most commonly, the site of stricture was located below the bladder neck musculature and above the distal urethral sphincter.

There is lack of a standardized protocol for managing patients with BNC. CIC has been popularized as a conservative tool for management of neurogenic bladders, benign prostatic hyperplasia, and BNC [20,21]. To our knowledge, data on specific role of CIC in BNC is scarce. Patel et al. [22] recommended CIC to ensure complete emptying and to maintain the patency after endoscopic incision to correct BNC among patients who had an orthotopic urinary diversion after radical cystectomy. Our experience suggests that endoscopic incision with cold-knife followed by a CIC regimen is associated with a very high success rate. Specifically, during the mean post prostatectomy follow-up period of 23.4 months, no patient experienced a BNC recurrence following our management protocol. Additionally, since no patients required a more aggressive management of BNC such as Urolume stent or radical resection, it is likely that the nature of BNC following RARP is limited and focal.

In three patients in our cohort, a migrated foreign body was identified at bladder neck. Individual case reports and retrospective case reviews exist in literature identifying Weck Hemo-lok, Lapra-Ty suture clip migration into bladder, bladder neck and even rectum [23-27]. In a cohort of 524 patients who

underwent RARP, Blumenthal et al. [28] reported that out of the 4 patients (0.76%) who developed BNC, 2 cases were associated with Hem-o-lok clip migration and erosion into the vesicourethral anastomosis. In addition, 1 patient was discovered to have clip migration into bladder. The authors also refer to similar cases reported to Food and Drug Administration Manufacturer and User Facility Device Experience database. Given our findings and the similar citations in literature, the use of such clips should be used with caution. We ensure and extract any loose clips during the surgery.

The study is limited by the design of a retrospective review of prospectively maintained institutional database. In addition, per institutional protocol, most patients returned to their primary urologist after the stabilization of urinary and sexual function. Thus extended follow-up in these patients were limited to communications with the initial referring urologists and hence BNC may be underrepresented in our results. Lastly, we did not perform any urodynamic procedures. Therefore, we could not investigate changes in urodynamic parameters before and after the treatment of BNC.

In conclusions, as the techniques of robot-assisted radical prostatectomy have improved, the incidence of BNC has declined. In our institutional experience, patients who underwent RARP for localized prostate cancer, the incidence of postoperative BNC was found to be 1.6%. Intraoperative blood loss is a significant predictor for BNC development. Surgical clips should be utilized judiciously as migration is a recognized phenomenon and can be associated with subsequent BNC. Subsequent management of BNC with cold-knife urethrotomy followed by a self CIC schedule leads to successful resolution of the bladder outlet obstruction related symptoms.

CONFLICT OF INTEREST

No potential conflict of interest relevant to this article was reported.

REFERENCES

1. Shalhav AL, Orvieto MA, Chien GW, Mikhail AA, Zagaja GP, Zorn KC. Minimizing knot tying during reconstructive laparoscopic urology. *Urology* 2006;68:508-13.
2. Breyer BN, Davis CB, Cowan JE, Kane CJ, Carroll PR. Incidence of bladder neck contracture after robot-assisted laparoscopic and open radical prostatectomy. *BJU Int* 2010;106:1734-8.
3. Msezane LP, Reynolds WS, Gofrit ON, Shalhav AL, Zagaja GP, Zorn KC. Bladder neck contracture after robot-assisted laparoscopic radical prostatectomy: evaluation of incidence and risk factors and impact on urinary function. *J Endourol* 2008;22:97-104.
4. Carlsson S, Nilsson AE, Schumacher MC, Jonsson MN, Volz DS, Steineck G, et al. Surgery-related complications in 1253 robot-assisted and 485 open retropubic radical prostatectomies at the Karolinska University Hospital, Sweden. *Urology* 2010;75:1092-7.
5. Hu JC, Nelson RA, Wilson TG, Kawachi MH, Ramin SA, Lau C, et al. Perioperative complications of laparoscopic and robotic assisted laparoscopic radical prostatectomy. *J Urol* 2006;175:541-6.
6. Menon M, Tewari A, Peabody JO, Shrivastava A, Kaul S, Bhandari A, et al. Vattikuti Institute prostatectomy, a technique of robotic radical prostatectomy for management of localized carcinoma of the prostate: experience of over 1100 cases. *Urol Clin North Am* 2004;31:701-17.
7. Coelho RF, Palmer KJ, Rocco B, Moniz RR, Chauhan S, Orvieto MA, et al. Early complication rates in a single-surgeon series of 2500 robotic-assisted radical prostatectomies: report applying a standardized grading system. *Eur Urol* 2010;57:945-52.
8. Zorn KC, Gofrit ON, Orvieto MA, Mikhail AA, Zagaja GP, Shalhav AL. Robotic-assisted laparoscopic prostatectomy: functional and pathologic outcomes with interfascial nerve preservation. *Eur Urol* 2007;51:755-62.
9. Webb DR, Sethi K, Gee K. An analysis of the causes of bladder neck contracture after open and robot-assisted laparoscopic radical prostatectomy. *BJU Int* 2009;103:957-63.
10. Popken G, Sommerkamp H, Schultze-Seemann W, Wettebauer U, Katzenwadel A. Anastomotic stricture after radical prostatectomy: incidence, findings and treatment. *Eur Urol* 1998;33:382-6.
11. Surya BV, Provet J, Johanson KE, Brown J. Anastomotic strictures following radical prostatectomy: risk factors and management. *J Urol* 1990;143:755-8.
12. Borboroglu PG, Sands JP, Roberts JL, Amling CL. Risk factors for vesicourethral anastomotic stricture after radical prostatectomy. *Urology* 2000;56:96-100.
13. Besarani D, Amoroso P, Kirby R. Bladder neck contracture after radical retropubic prostatectomy. *BJU Int* 2004;94:1245-7.
14. Santucci RA, McAninch JW. Urethral reconstruction of strictures resulting from treatment of benign prostatic hypertrophy and prostate cancer. *Urol Clin North Am* 2002;29:417-27.
15. Magera JS Jr, Inman BA, Elliott DS. Outcome analysis of urethral wall stent insertion with artificial urinary sphincter placement for severe recurrent bladder neck contracture following radical prostatectomy. *J Urol* 2009;181:1236-41.

16. Van Velthoven RE, Ahlering TE, Peltier A, Skarecky DW, Clayman RV. Technique for laparoscopic running urethrovesical anastomosis: the single knot method. *Urology* 2003;61:699-702.
17. Park R, Martin S, Goldberg JD, Lepor H. Anastomotic strictures following radical prostatectomy: insights into incidence, effectiveness of intervention, effect on continence, and factors predisposing to occurrence. *Urology* 2001;57:742-6.
18. Garg T, See WA. Bladder neck contracture after radical retro-pubic prostatectomy using an intussuscepted vesicourethral anastomosis: incidence with long-term follow-up. *BJU Int* 2009;104:925-8.
19. Elliott SP, Meng MV, Elkin EP, McAninch JW, Duchane J, Carroll PR, et al. Incidence of urethral stricture after primary treatment for prostate cancer: data From CaPSURE. *J Urol* 2007;178:529-34.
20. Brannan W. Management of urethral strictures. *J Urol* 1985; 133:442.
21. Ghalayini IE, Al-Ghazo MA, Pickard RS. A prospective randomized trial comparing transurethral prostatic resection and clean intermittent self-catheterization in men with chronic urinary retention. *BJU Int* 2005;96:93-7.
22. Patel SG, Cookson MS, Clark PE, Smith JA Jr, Chang SS. Neovesical-urethral anastomotic stricture after orthotopic urinary diversion: presentation and management. *BJU Int* 2008;101:219-22.
23. Tugcu V, Polat H, Ozbay B, Eren GA, Tasci AI. Stone formation from intravesical Hem-o-lok clip migration after laparoscopic radical prostatectomy. *J Endourol* 2009;23:1111-3.
24. Banks EB, Ramani A, Monga M. Intravesical Weck clip migration after laparoscopic radical prostatectomy. *Urology* 2008;71:351.e3-4.
25. Mora ER, Gali OB, Garin JA, Arango O. Intravesical migration and spontaneous expulsion of a Hem-o-lok polymer ligating clip after laparoscopic radical prostatectomy. *Urology* 2010; 75:1317.
26. Wu SD, Rios RR, Meeks JJ, Nadler RB. Rectal Hem-o-Lok clip migration after robot-assisted laparoscopic radical prostatectomy. *Can J Urol* 2009;16:4939-40.
27. Shin YS, Doo AR, Cha JS, Kim MK, Jeong YB, Kim HJ. Floating Hem-o-Lok clips in the bladder without stone formation after robot-assisted laparoscopic radical prostatectomy. *Korean J Urol* 2012;53:60-2.
28. Blumenthal KB, Sutherland DE, Wagner KR, Frazier HA, Engel JD. Bladder neck contractures related to the use of Hem-o-lok clips in robot-assisted laparoscopic radical prostatectomy. *Urology* 2008;72:158-61.
29. Rassweiler J, Sentker L, Seemann O, Hatzinger M, Rumpelt HJ. Laparoscopic radical prostatectomy with the Heilbronn technique: an analysis of the first 180 cases. *J Urol* 2001;166: 2101-8.
30. Gonzalgo ML, Pavlovich CP, Trock BJ, Link RE, Sullivan W, Su LM. Classification and trends of perioperative morbidities following laparoscopic radical prostatectomy. *J Urol* 2005;174: 135-9; discussion 139.