

James P. Orenge, MD,  
PhD  
Melike Pekmezci, MD  
Bruce A.C. Cree, MD,  
PhD, MAS

*Neurol Neuroimmunol  
Neuroinflamm*  
2015;2:e101; doi: 10.1212/  
NXL.000000000000101

## SIMULTANEOUS SERUM AQP4 ANTIBODY AND CSF NMDA RECEPTOR ANTIBODY-POSITIVE ENCEPHALITIS

### OPEN

A 29-year-old Hmong woman presented with 3 months of worsening imbalance and intermittent vertigo followed by right facial numbness, slurred/nonsensical speech, and memory impairment. She reported generalized weakness, fatigue, and anorexia with more than 10 kg weight loss. She denied paresthesia, vision loss, nausea, vomiting, or hiccups. Neurologic examination revealed impaired short-term memory, expressive aphasia, mild right appendicular ataxia, and profound abulia.

Brain MRI showed multiple areas of T2 hyperintensity (figure, A). Extensive extracranial imaging was unrevealing of a primary malignancy. On admission, lumbar puncture found 40 white blood cells (100% lymphocytes), 9 red blood cells, glucose 49 mg/dL, and protein 50 mg/dL. Lumbar punctures performed 10 and 11 days later had similar cell and chemistry profiles. The immunoglobulin G (IgG) index was elevated at 0.9 (normal range 0.2–0.6). Four well-defined IgG bands were unique to the CSF. An extensive evaluation for systemic and infectious etiologies was uninformative (see appendix e-1 at [Neurology.org/nn](http://Neurology.org/nn) for details).

Serum anti-neuromyelitis optica (NMO)/aquaporin-4 (AQP4) antibody was positive and was confirmed by repeat serology (cell-based assay, Mayo Clinic). Serum paraneoplastic panel and anti-NMDA receptor antibody tests were negative. However, CSF tested positive for anti-NMDA receptor antibodies (semi-quantitative indirect fluorescent antibody, ARUP Laboratories). A stereotactic brain biopsy of the right basal ganglia lesion demonstrated prominent perivascular and intraparenchymal lymphocytic infiltrates (figure, B–E). There were numerous reactive astrocytes as well as activated microglia throughout the parenchyma without microglial nodules or neuronophagia. Penetrating axons showed intact myelin, arguing against a demyelinating process. Immunohistochemical and special stains, including Gram, modified Gomori methenamine-silver nitrate, polyoma virus, and herpes simplex virus (HSV) 1/2, were negative for infectious etiologies. The findings were consistent with encephalitis. Because of the limited biopsy sample, special stains for complement deposition,

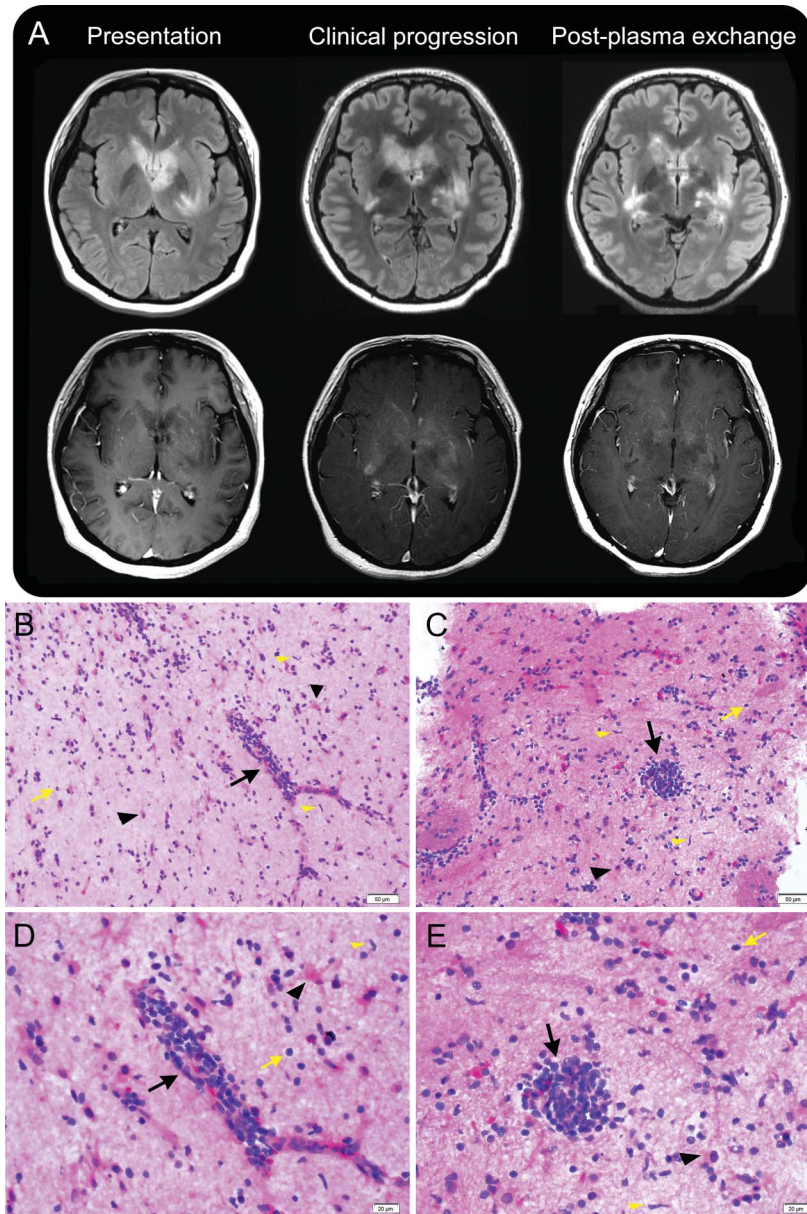
AQP4, or other astroglial markers could not be performed.

The patient deteriorated during the hospitalization, with worsening abulia, aphasia, and akinesia. She was treated with 1 g of methylprednisolone daily for 5 days followed by a prednisone taper without benefit. The patient underwent plasmapheresis for 5 exchanges (1 blood volume per exchange with albumin replacement) and began to clinically improve. Repeat imaging showed reduction in contrast enhancement of the brain lesions (figure, A). She was treated with rituximab for ongoing immune suppression (1,000 mg IV  $\times$  2 infusions with plans for repeat infusions after 6 months).

This case is notable for the simultaneous occurrence of CSF anti-NMDA receptor and serum anti-NMO/AQP4 antibodies. Anti-NMDA receptor antibodies present in the CSF that are not found in the serum in patients with encephalitis are thought to correlate with clinical outcomes.<sup>1</sup> Anti-NMO/AQP4 antibodies typically are associated with transverse myelitis and optic neuritis and sometimes are associated with brainstem or cerebral involvement.<sup>2</sup> The sequential occurrence of NMO/NMO spectrum disorder followed by NMDA receptor encephalitis was recently reported in 5 patients.<sup>3</sup> The simultaneous occurrence of these CNS pathogenic antibodies with pathologic findings has not been previously reported. Although we do not know to what extent the anti-NMO/AQP4 and the anti-NMDA receptor autoantibodies contributed to the presentation, the clinical and radiographic features in this case suggest features of both NMO spectrum disorder and NMDA receptor encephalitis. Clinical and radiographic features that could be consistent with NMO include the brainstem syndrome with anorexia and radiographic involvement of the brainstem, hypothalamus, and optic chiasm. Similarly, cognitive impairment and akinesia along with the radiographic features of encephalitis might be due to NMDA receptor antibodies.

Other autoimmune diseases, including systemic lupus erythematosus, Sjögren syndrome, and myasthenia gravis, occur in patients with NMO. Many patients with NMO test seropositive for other autoantibodies.<sup>4</sup> More recently, anti-myelin oligodendrocyte glycoprotein antibodies were associated with a

Supplemental data at  
[Neurology.org/nn](http://Neurology.org/nn)



(A) Brain MRI at presentation shows multiple areas of T2 hyperintensity in the mesial temporal lobes, basal ganglia, left thalamus, hypothalamus, optic chiasm, right cerebella, and brainstem. As the patient clinically deteriorated, her MRI showed expanding areas of T2 hyperintensity and contrast enhancement. With the completion of plasma exchange there was reduced contrast enhancement. The top row is T2 fluid-attenuated inversion recovery sequence and the bottom row is T1 sequence post gadolinium. (B-E) Moderate (B, C) and high-power (D, E) images of hematoxylin & eosin-stained sections show prominent perivascular lymphocytic infiltrate (black arrows) and scattered intraparenchymal lymphocytes (yellow arrows). There are scattered activated microglia with elongated comma-shaped nuclei (black arrowheads) and numerous reactive astrocytes with abundant star-shaped cytoplasm (yellow arrowheads).

clinical presentation consistent with NMO.<sup>5</sup> We speculate that a mechanism underlying a breach in immune tolerance could be shared by CNS autoantibody-mediated diseases, resulting in the sequential occurrence of NMO and NMDA receptor encephalitis and possibly explaining the co-occurrence of these autoantibodies in our patient. An immunodominant AQP4 peptide recognized by T cells in patients with NMO has a high degree of homology to an ABC

transporter from *Clostridium* species, suggesting that molecular mimicry might be involved in NMO pathogenesis.<sup>6</sup> Colonization of *Clostridium* or other bacterial species in the gut could promote immune responses that cross-react with the AQP4 and NMDA receptor proteins. Alternately, we speculate that NMO-related inflammation could “reveal” CNS antigens to the immune system, resulting in a secondary inflammatory response similar to that proposed for HSV and NMDA

receptor encephalitis.<sup>7</sup> We suggest that patients presenting with encephalitis be systematically screened for the presence of anti-NMO/AQP4 and anti-NMDA receptor antibodies in serum and CSF.

*From the Departments of Neurology (J.P.O., B.A.C.C.) and Pathology (M.P.), University of California, San Francisco.*

*Author contributions: James P. Orengo: acquisition of data, analysis and interpretation, critical revision of the manuscript for important intellectual content. Melike Pekmezci: acquisition of data, analysis and interpretation. Bruce A.C. Cree: study concept and design, analysis and interpretation, critical revision of the manuscript for important intellectual content, study supervision.*

*Study funding: No targeted funding reported.*

*Disclosure: J.P. Orengo reports no disclosures. M. Pekmezci received research support from UCSF and their spouse received research support from Stryker Corp and NuVasive Inc. B.A.C. Cree is an editor for Annals of Neurology; has consulted for Abbvie, Biogen Idec, EMD Serono, Genzyme, MedImmune, Novartis, Sanofi Aventis, and Teva Neurosciences; received research support from Acorda, Avanir, Biogen Idec, EMD Serono, Hoffman La Roche, MedImmune, Novartis, and Teva Neurosciences; and was an expert consultant for Biogen Idec. Go to [Neurology.org/mn](http://Neurology.org/mn) for full disclosure forms. The Article Processing Charge was paid by the authors.*

*This is an open access article distributed under the terms of the Creative Commons Attribution-Noncommercial No Derivative 3.0 License, which permits downloading and sharing the work provided it is properly cited. The work cannot be changed in any way or used commercially.*

*Received April 21, 2014. Accepted in final form March 9, 2015.*

*Correspondence to Dr. Cree: [bruce.cree@ucsf.edu](mailto:bruce.cree@ucsf.edu)*

1. Dalmau J, Gleichman AJ, Hughes EG, et al. Anti-NMDA-receptor encephalitis: case series and analysis of the effects of antibodies. *Lancet Neurol* 2008;7:1091–1098.
2. Pittock SJ, Lennon VA, Krecke K, Wingerchuk DM, Lucchinetti CF, Weinshenker BG. Brain abnormalities in neuromyelitis optica. *Arch Neurol* 2006;63:390–396.
3. Titulaer MJ, Höftberger R, Iizuka T, et al. Overlapping demyelinating syndromes and anti-N-methyl-D-aspartate receptor encephalitis. *Ann Neurol* 2014;75:411–428.
4. Pittock SJ, Lennon VA, de Seze J, et al. Neuromyelitis optica and non organ-specific autoimmunity. *Arch Neurol* 2008;65:78–83.
5. Kitley J, Waters P, Woodhall M, et al. Neuromyelitis optica spectrum disorders with aquaporin-4 and myelin-oligodendrocyte glycoprotein antibodies: a comparative study. *JAMA Neurol* 2014;71:276–283.
6. Varrin-Doyer M, Spencer CM, Schulze-Topphoff U, et al. Aquaporin 4-specific T cells in neuromyelitis optica exhibit a Th17 bias and recognize Clostridium ABC transporter. *Ann Neurol* 2012;72:53–64.
7. Armangue T, Leypoldt F, Málaga I, et al. Herpes simplex virus encephalitis is a trigger of brain autoimmunity. *Ann Neurol* 2014;75:317–323.