

Advanced heart block in acute rheumatic fever



Zakariya Hubail^{a,*}, Ishaq M. Ebrahim^a

^a Department of Pediatrics, Salmaniya Medical Complex

^a Bahrain

First degree heart block is considered a minor criterion for the diagnosis of this condition. The cases presented here demonstrate that higher degrees of heart block do occur in rheumatic fever. Children presenting with acquired heart block should be worked-up for rheumatic fever. Likewise, it is imperative to serially follow the electrocardiogram in patients already diagnosed with acute rheumatic fever, as the conduction abnormalities can change during the course of the disease.

© 2015 The Authors. Production and hosting by Elsevier B.V. on behalf of King Saud University. This is an open access article under the CC BY-NC-ND license (<http://creativecommons.org/licenses/by-nc-nd/4.0/>).

Keywords: Carditis, Heart block, Rheumatic fever

Introduction

Prolonged atrioventricular conduction, i.e., first degree heart block, is a well-recognized feature of acute rheumatic fever, occurring in about one-fifth to three-fifths of patients [1,2] and is considered a minor criterion in the diagnosis of this condition. Higher degrees of heart block, however, are not usual features of acute rheumatic fever. Here we present two cases of acute rheumatic fever who presented with second and third degree heart block.

Case reports

Case 1

A 10-year-old girl presented with fever and knee pain for 3 days. The pain started in the left knee,

and then involved the right knee. She had no skin rash or abnormal movement. There was recent history of history of sore throat.

On examination she was febrile, 38.9 °C, and tachycardiac, 140 beats/min. Her throat was erythematous. A grade 3 apical systolic murmur was audible, radiating to the left axilla. The knees were warm and swollen with evidence of effusion, and painful to move. The first electrocardiogram (ECG) showed a second degree atrioventricular block Mobitz type II, with 2:1 conduction (Figure 1). An echocardiogram showed mild mitral regurgitation. Her erythrocyte sedimentation rate was 86 mm/h, and antistreptolysin-O titer was 1090 IU. She was started on high dose aspirin and penicillin, with good clinical improvement. Two months later her ECG showed a third degree heart block (Figure 2), with a junctional escape rhythm of 65/min. On her last follow-up 3 years

Disclosure: Authors have nothing to disclose with regard to commercial support.

Received 25 June 2015; revised 8 September 2015; accepted 2 November 2015.

Available online 6 November 2015

* Corresponding author at: Department of Pediatrics, SMC, PO Box 12, Manama, Bahrain.

E-mail address: zhubail@hotmail.com (Z. Hubail).



P.O. Box 2925 Riyadh – 11461KSA
Tel: +966 1 2520088 ext 40151
Fax: +966 1 2520718
Email: sha@sha.org.sa
URL: www.sha.org.sa



1016–7315 © 2015 The Authors. Production and hosting by Elsevier B.V. on behalf of King Saud University. This is an open access article under the CC BY-NC-ND license (<http://creativecommons.org/licenses/by-nc-nd/4.0/>).

Peer review under responsibility of King Saud University.

URL: www.ksu.edu.sa

<http://dx.doi.org/10.1016/j.jsha.2015.11.001>



Production and hosting by Elsevier

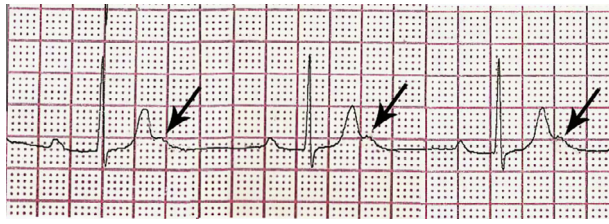


Figure 1. A rhythm strip showing second degree heart block, Mobitz type II, with 2:1 conduction. The arrows point to the nonconducted P-waves.

later, she remained asymptomatic but in complete heart block.

Case 2

A previously healthy 9-year-old boy presented to the emergency department with abdominal and chest pain. On examination he was found to have a slow heart rate of 56/minute. An ECG showed a third degree heart block (Figure 3). He was discharged from the emergency room with a cardiology follow-up appointment. Two days later he presented with fever, persistent abdominal pain, and an inability to walk. Examination showed no joint abnormalities, a slow heart rate, and no heart murmur. Acute rheumatic fever was considered. Erythrocyte sedimentation rate

was 87 mm/h, and antistreptolysin-O titer 953 IU. Rheumatoid factor and antinuclear antibodies were negative. An echocardiogram revealed mild mitral regurgitation. High dose aspirin and prednisolone were started. He made a good recovery and his heart rhythm returned to sinus rhythm 9 days after presentation (Figure 4).

Discussion

Cardiac involvement in acute rheumatic fever is typically described as “pancarditis”, underscoring the fact that the pericardium, myocardium, and endocardium can all be affected. The salient feature, nonetheless, is valvar involvement, given its long term ramifications. It is the hallmark of carditis and is therefore considered a major criterion in the Jones criteria for the diagnosis of rheumatic fever. Atrioventricular conduction abnormalities are also well recognized features of acute rheumatic fever. The advent of ECG has allowed for precise measurement of such abnormalities. Early studies in the 20s and 30s of the last century have found first degree heart block to be a common feature. When Dr Jones introduced his criteria for the diagnosis of rheumatic fever in 1944, he considered first degree heart block as a minor criterion, and that continued in all

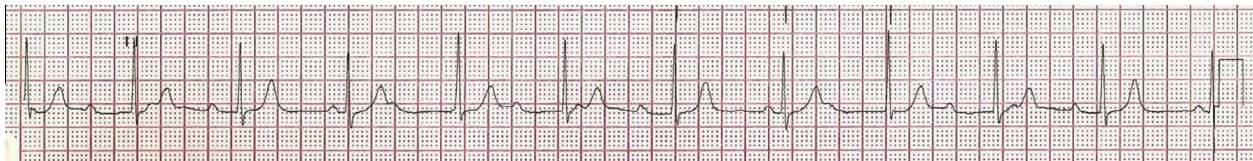

Figure 2. A follow-up electrocardiogram 2 months later, showing third degree heart block; the atrial rate is 115/min, the ventricular rate is 65/min.

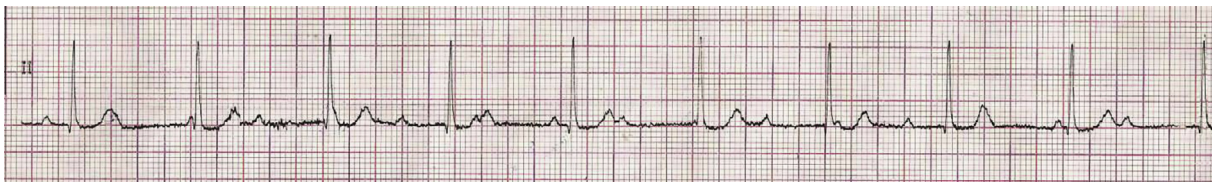

Figure 3. The rhythm strip on presentation showing third degree heart block; the atrial rate is 107/min, the ventricular rate is 63/min.

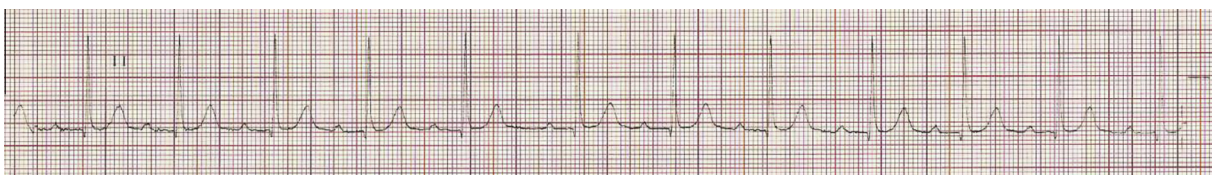

Figure 4. A rhythm strip taken 9 days later showing the return of sinus rhythm, with prolonged PR interval (0.28 seconds).

subsequent revisions of the criteria [3]. Higher degrees of atrioventricular block, however, were not common enough or consistently present to be included in the criteria. Later on, case reports of advanced heart block appeared sporadically in the literature. Presentation varied from incidental findings on examination or in ECG, to syncope [4,5]. The incidence remained low; in a large series only an occasional patient would be found to develop advanced heart block, giving incidence that varied from 0% to 1.6%. A large study of 6000 military recruits with rheumatic fever found only four patients with second degree heart block (0.06%) and one patient with third degree block (0.016%) [6]. In a relatively recent study of 65 patients, a surprisingly high percentage of patients (6.1%) had second and third degree block [7]. Interestingly the conduction abnormalities in rheumatic fever are mostly transient and self-limited [8] returning to sinus rhythm in a matter of a few weeks [9], but rarely can be persistent for a longer time [10].

The two cases presented here illustrate that higher degrees of atrioventricular block do occur in acute rheumatic fever, albeit rarely. They also demonstrate the variability in presentation, the time course, the progression, and the eventual outcome of heart block. The patient in the first case presented with rheumatic fever and second degree heart block that progressed to third degree, which then persisted. The patient in the second case, had complete heart block on presentation, and on further work-up turned out to have acute rheumatic fever. Corticosteroids were added to his treatment regimen, although their role in altering the outcome is controversial. The heart

block resolved, and the patient returned to normal sinus rhythm.

In conclusion, advanced degrees of heart block can occur in acute rheumatic fever. Pediatric patients presenting with acquired heart block deserve a work-up for rheumatic fever. Likewise, it is imperative to repeat the ECG in patients already diagnosed with acute rheumatic fever, as the conduction abnormalities can change during the course of the disease.

References

- [1] Karacan M, Işıkay S, Olgun H, Ceviz N. Asymptomatic rhythm and conduction abnormalities in children with acute rheumatic fever: 24-hour electrocardiography study. *Cardiol Young* 2010;20:620–30.
- [2] Clarke M, Keith JD. Atrioventricular conduction in acute rheumatic fever. *Br Heart J* 1972;34:472–9.
- [3] Jones TD. The diagnosis of rheumatic fever. *JAMA* 1944;126:481–4.
- [4] Lenox CC, Zuberbuhler JR, Park SC, Neches WH, Mathews RA, Zoltun R. Arrhythmias and Stokes-Adams attacks in acute rheumatic fever. *Pediatrics* 1978;61:599–603.
- [5] Carano N, Bo I, Tchana B, Vecchione E, Fantoni S, Agnetti A. Adams-Stokes attack as the first symptom of acute rheumatic fever: report of an adolescent case and review of the literature. *Ital J Pediatr* 2012;38:61.
- [6] Filberbaum MB, Griffith GC, Solley RF, Leake WH. Electrocardiographic abnormalities in 6,000 cases of rheumatic fever. *Cal West Med* 1946;64:340–6.
- [7] Zalstein E, Maor R, Zucker N, Katz A. Advanced atrioventricular conduction block in acute rheumatic fever. *Cardiol Young* 2003;13:506–8.
- [8] Malik JA, Hassan C, Khan GQ. Transient complete heart block complicating acute rheumatic fever. *Indian Heart J* 2002;54:91–2.
- [9] Barold SS, Sischy D, Punzi J, Kaplan EL, Chessin L. Advanced atrioventricular block in a 39-year-old man with acute rheumatic fever. *Pacing Clin Electrophysiol* 1998;21:2025–8.
- [10] Shah CK, Gupta R. Persistent complete heart block following acute rheumatic fever in a 12 year old girl. *J Assoc Physicians India* 1993;41:389–90.