

Anesthetic implications of subxiphoid coronary artery bypass surgery

Murali Chakravarthy, Muralimanohar Veerappa¹, Vivek Jawali¹, Nischal Pandya¹, Jayaprakash Krishnamoorthy, Geetha Muniraju, Antony George, Jitumoni Baishya

Department of Anesthesia, Critical Care and Pain Relief, ¹Department of Cardiac Surgery, Fortis Hospitals, Bengaluru, Karnataka, India

ABSTRACT

Background: Minimal invasive surgeries are carried out to benefit the patient with less pain, blood loss, mechanical ventilation and hospital stay; a smaller scar is not the aim. Minimal invasive cardiac surgeries are carried out via small sternotomy, small thoracotomy and via robotic arms. Subxiphoid route is a novel method and avoids sternotomy. **Aim:** This case series is an attempt to understand the anesthetic modifications required. Secondly, whether it is feasible to carry out subxiphoid coronary artery bypass surgery. **Methods:** Elective patients scheduled to undergo subxiphoid coronary artery bypass surgery were chosen. The surgeries were conducted under general anesthesia with left lung isolation via either endobronchial tube or bronchial blocker. **Results:** We conducted ten (seven males and 3 females) coronary artery bypass graft surgeries via subxiphoid technique. The mean EuroSCORE was 1.7 and the mean ejection fraction was 53.6. Eight patients underwent surgery via endobronchial tube, while, in the remaining two lung isolation was obtained using bronchial blocker. Mean blood loss intraoperatively was 300 ± 42 ml and postoperatively 2000 ± 95 ml. The pain score on the postoperative day '0' was 4.3 ± 0.6 and 2.3 ± 0.7 on the day of discharge. Length of stay in the hospital was 4.8 ± 0.9 days. There were no complications, blood transfusions, conversion to cardiopulmonary bypass. The modifications in the anesthetic and surgical techniques are, use of left lung isolation using either endobronchial tube or bronchial blocker, increased duration for conduit harvesting, grafting, requirement of transesophageal echocardiography monitoring in addition to hemodynamic monitoring. Other minor requirements are transcutaneous pacing and defibrillator pads, a wedge under the chest to 'lift' up the chest, sparing right femoral artery and vein (to serve as vascular access) for an unlikely event of conversion to cardiopulmonary bypass. Any anesthesiologist wishing to start this technique must be aware of these modifications. **Conclusions:** Subxiphoid route is safe to carry out coronary artery bypass graft surgery using the minimal invasive cardiac surgery. It is reproducible and has undeniable benefits. We plan to conduct such surgeries in awake patients under thoracic epidural anesthesia thus making it even less invasive and amenable for fast tracking.

Received: 01-03-16
Accepted: 12-06-16

Key words: Minimal invasive coronary artery bypass surgery; Off-pump coronary artery bypass surgery; Subxiphoid coronary artery bypass graft

INTRODUCTION

Minimal invasive coronary artery surgeries (MICS) are carried out with an intention to reduce morbidity, pain, cost, and length of stay (LOS) in the Intensive Care Unit (ICU) and hospital. Minimal invasive direct coronary artery bypass graft (CABG) via thoracotomy, subxiphoid coronary artery bypass surgery, cardiac surgery via partial sternotomy, and robotic-assisted coronary artery bypass are a few examples of MICS. We have conducted a series of MICS via a subxiphoid route, without sternotomy, to

Address for correspondence: Dr. Murali Chakravarthy, Department of Anesthesia, Critical Care and Pain Relief, Fortis Hospitals, Bannerghatta Road, Bengaluru - 560 076, Karnataka, India.
E-mail: mailchakravarthy@gmail.com

This is an open access article distributed under the terms of the Creative Commons Attribution-NonCommercial-ShareAlike 3.0 License, which allows others to remix, tweak, and build upon the work non-commercially, as long as the author is credited and the new creations are licensed under the identical terms.

For reprints contact: reprints@medknow.com

Cite this article as: Chakravarthy M, Veerappa M, Jawali V, Pandya N, Krishnamoorthy J, Muniraju G, *et al.* Anesthetic implications of subxiphoid coronary artery bypass surgery. *Ann Card Anaesth* 2016;19:433-8.

Access this article online
Website: www.annals.in
DOI: 10.4103/0971-9784.185525
Quick Response Code:


achieve and augment the claimed benefits. There are anesthetic challenges that the anesthesiologists come across due to the modification in the surgical approach. An anesthesiologist without prior exposure to such cases might find it difficult if issues are not anticipated ahead. This is an early report toward improving awareness among anesthesiologists since anesthetic aspects of this surgery have hitherto been not described in the literature.

Levinson described conducting one such surgery in mid-2005.^[1] We are describing our anesthetic technique during the conduct of ten cases from July to December 2015 at our center as it has not been described earlier.

METHODS

Patients selected to undergo subxiphoid coronary artery bypass surgery were studied. The selection criteria for undergoing this type of surgery were patients requiring one or two left-sided grafts less likely to require coronary artery endarterectomy, without valve dysfunction. Respiratory cripples were not contraindicated to undergo this type of surgery.

The following were considered as exclusion criteria:

- Patients with unstable angina or unstable hemodynamic status stabilized by mechanical ventilation or intra-aortic balloon counterpulsation
- Complicated coronary anatomy requiring either multiple coronary artery grafts or coronary artery endarterectomy
- Combined or very complicated cardiothoracic surgeries
- Obese patients
- Patients likely to require cardiopulmonary bypass (CPB) to complete the planned surgery
- Prior upper abdominal surgery.

Anesthetic technique

Preanesthetic check was conducted before surgery, and the patients were briefed about the use of visual analog pain scale (VAPS). They were premedicated with oral alprazolam 0.5 mg at bedtime on the night before surgery. After arrival in the operating room, routine monitoring including electrocardiography, pulse oximetry, and noninvasive blood pressure monitoring commenced. Peripheral vein on the left forearm was secured; left femoral artery (in contrast to the institution's protocol of right side for non-MICS cases), right jugular vein was cannulated under local anesthesia. Central venous catheter or pulmonary artery catheter was

inserted depending on the perioperative monitoring requirement. General anesthesia was induced using intravenous administration of adequate doses of propofol, rocuronium, and ventilation with equal mixtures of oxygen in air and 2% of sevoflurane. Anatomy of the trachea and the main bronchi was assessed by fiber-optic bronchoscope before choosing the type of lung isolation. If the size of the bronchus appeared normal, without anatomical deviations, endobronchial tube was chosen. If the bronchial lumen was smaller than expected, bronchial blocker was used. Since it is technically easier to insert left endobronchial tube, we used the left-sided one if endobronchial tube was required. Depending on the size and shape of the bronchial tree either a left endobronchial tube or a bronchial blocker chosen and inserted into the patient's trachea; its correct position was checked both by auscultation and by fiber-optic bronchoscope. Mechanical ventilation was instituted with tidal volume of 8 ml/kg and a frequency of 12/min. Two-lung ventilation was carried out as long as possible. Transesophageal echo (TEE) probe was passed, to monitor the wall motion abnormality and/or valve regurgitation.

A sandbag was kept under the back, with its upper level at patient's lower end of scapula so as to lift the xiphisternum [Figure 1] to "push up" the chest. Percutaneous defibrillator/pacing pads were placed; one on the right anterior aspect of the chest and the other on the left posterior aspect of the chest (thus allowing for possible midline sternotomy and insertion of intercostal drainage tube on the left). Intraoperative adverse hemodynamic changes were countered using boluses of intravenous fluids and/or by instituting an infusion of a vasopressor such as noradrenaline or an inotrope.

Anesthetic goals

The main anesthetic goals are stable one lung anesthesia, with hemodynamic stability. During the

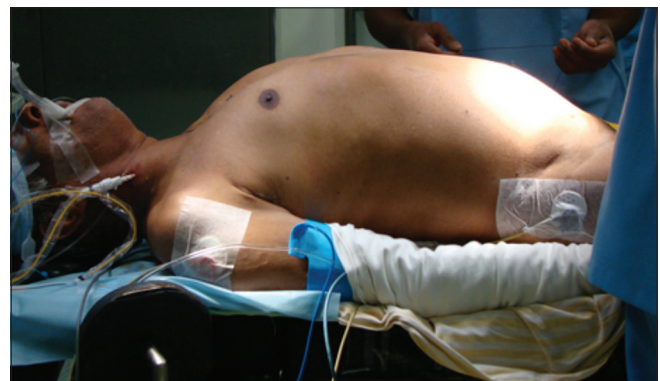

Figure 1: The "push-up" of the lower chest using sandbag

coronary artery bypass, the left lung should be isolated, and ventilation is maintained on right lung only. Arrhythmias, hypotension, and blood gas disturbances may occur and might not allow continuation of the surgery, thereby delaying it. Discontinuation of the anesthetic agents may be timed well to achieve early extubation. A good postoperative pain relief must be provided. Administering serratus anterior plane block is the method used at the author's institute. Postoperative mechanical ventilation is usually not required, and one should aim for early ambulation as well.

Surgical technique

The chest and both groins were prepared and draped. An 8 cm vertical incision taken in midline starting from the tip of xiphoid process and extended below toward umbilicus. Thorexpo retractor system by Fehling (Fehling Instruments, Karlstein, Germany) was used to lift up the sternum to aid harvesting of left internal mammary artery (LIMA). LIMA was harvested from lower end at the level of xiphoid bone up to first intercostal space. One-lung ventilation was commenced at this time; the left lung was isolated. During one-lung ventilation, the tidal volume was adjusted to achieve end-tidal carbon dioxide value of about 30 mmHg. If this was not achievable, both lung ventilation was started, and ventilatory parameters were further refined based on arterial blood gas values. After harvesting LIMA, 5000 units of heparin were administered intravenously.

Pericardium was opened, and the heart was positioned to give adequate exposure of left anterior descending (LAD) artery by placing mops behind the heart. LIMA to LAD anastomosis was performed on beating heart with help of octopus nuvo (Medtronic, 710, Medtronic

Parkway Minneapolis, Minnesota, 55432-5604, USA) which was inserted through the planned site for drains [Figure 2]. The other conduits such as right internal mammary or right gastroepiploic artery were used for appropriate targets as required. Off-pump coronary artery anastomosis was completed in the usual fashion if required for the other coronary arteries. Once satisfactory hemostasis was confirmed, thoracic drains were inserted through the ports that were used to insert Octopus Neo, and the surgical incision was closed.

Provisional plan for conversion to cardiopulmonary bypass

If CPB was required for whatever reasons, percutaneous right femoral artery and femoral vein cannulation would be carried out via the groin vessels which was prepared and draped earlier. If the femoral route was not providing adequate arterial flow during CPB midsternotomy would be carried out, and the ascending aorta would be cannulated with 28 French Medtronic aortic cannula to enhance the arterial return.

After completion of the intrathoracic work by the surgeon, two-lung ventilation was resumed, and lung recruitment maneuver by manual continuous positive airway pressure was carried out. After completion of surgery, the TEE probe was removed, and nasogastric tube was inserted. The nasogastric tube was retained for a day or two in patients who underwent grafting with right gastroepiploic artery. Residual neuromuscular blockade was reversed, and suitability of extubation was assessed; if suitable, the patient's trachea was extubated, if not, elective postoperative ventilation was offered after removing either the double lumen endobronchial tube or the bronchial blocker and inserting a single lumen endotracheal tube. Intraoperative blood loss was calculated by gravimetric method, if necessary, replaced with blood and/or blood products.

Postsurgical management

Patients not suitable for "on table extubation" of trachea were mechanically ventilated till they were deemed fit for extubation. The criteria for extubation were awake pain-free patient without arrhythmias, bleeding, or low cardiac output. After extubation, pain relief was provided using 5–7 mg of morphine administered subcutaneously. If the pain relief was not adequate with this measure, intravenous infusion of fentanyl via patient controlled analgesia would be initiated. The patients were allowed oral fluids after 3 h after surgery. We conducted a postoperative graft angiogram on the first postoperative day for all. Electrocardiogram and

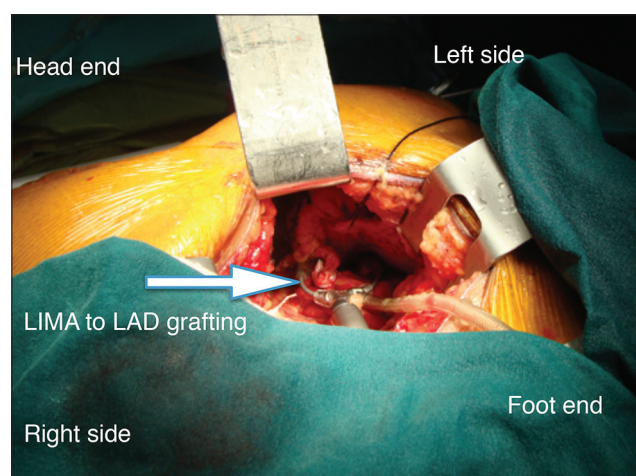


Figure 2: Left internal mammary artery being anastomosed to left anterior descending artery

Table 1: Patient details

Patient number	Age	Weight (kg)	Height (cm)	Sex	Graft/s	EuroSCORE	Ejection fraction %	Comorbidities
#1	46	48.6	146	Female	1	0.88	50	None
#2	76	67.5	169	Male	2	1.7	50	Diabetes mellitus
#3	69	57.2	152	Female	1	2.35	50	Diabetes mellitus and hypertension
#4	57	66.5	163	Male	1	1.33	50	Diabetes mellitus and hypertension
#5	67	92	168	Male	1	1.15	50	Diabetes mellitus and hypertension
#6	60	80	165	Male	2	1.73	50	Diabetes mellitus and hypertension
#7	69	55	154	Female	1	1.6	60	Diabetes mellitus and hypertension interstitial lung disease
#8	52	65	179	Male	1	1.83	62	Diabetes mellitus
#9	58	65	164	Male	1	1.87	61	Diabetes mellitus and hypertension
#10	85	63	164	Male	1	6.7	48	Diabetes mellitus and hypertension, pituitary adenoma excised

cardiac enzyme evidence for postoperative myocardial infarction were looked for. If there were no events, the patients were transferred to the ward on the postoperative day 1 and discharged when deemed fit. VAPS was used to assess the postoperative pain.

RESULTS

Ten patients underwent subxiphoid CABG surgery from July 2015 till date at our institute. Patient details are shown in Table 1. There were three females in our cohort. Nine patients had diabetes and six had hypertension. The EuroSCORE of the cohort ranged from 1.15 to 2.35 and mean was 1.7. The mean ejection fraction was 53.6. All the surgeries were carried out under endotracheal general anesthesia. All the patients received intravenous propofol 1 mg/kg for induction of anesthesia and intubation was carried out using rocuronium 1 mg/kg intravenously. Following intubation of the trachea, 2% end-tidal sevoflurane was administered. Left endobronchial tube was inserted in eight and bronchial blocker in two as based on the information by the preintubation bronchoscopy. In our series, eight patients received LIMA, one received right internal mammary artery, and yet another patient received right gastroepiploic artery. Seven patients received one graft each, whereas three patients received two each. Mean graft harvesting time was 90 ± 27 min. Patient #7 requiring repeat surgery for right coronary artery had functioning LIMA anastomosed to LAD. Patient #10 was receiving steroid replacement therapy following pituitary adenoma excision. In this patient, right internal mammary artery was grafted to the required target, without the need for sternotomy.

None of the cases in our cohort required either sternotomy or CPB or intra-aortic balloon counterpulsation to

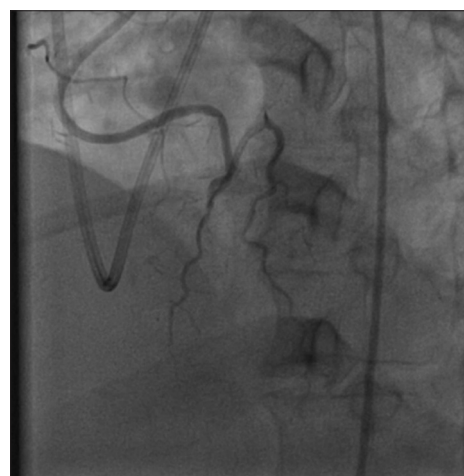


Figure 3: Left internal mammary artery anastomosed to left anterior descending artery

complete the surgery. No patients required transfusion of blood or blood products. Mean intraoperative blood loss was 300 ± 42 , postoperative blood loss 200 ± 95 , and total blood loss was 500 ± 125 . The duration of surgery was 380 ± 90 min. Postoperative graft angiogram was performed in all the patients; all the grafts were patent. A few samples of the angiogram images are shown in Figures 3-5. The pain score was 4.3 ± 0.6 on the operative day and 2.3 ± 0.7 on the day of discharge. LOS in the hospital was 4.8 ± 0.9 days. No patients required either readmission to the ICU or were re-explored.

DISCUSSION

MICS is practiced globally with an intention to reduce morbidities, transfusion requirement, and LOS in the ICU. It appears that carrying out MICS may not be cost- and time-effective; instead one could perform percutaneous coronary interventions. Although

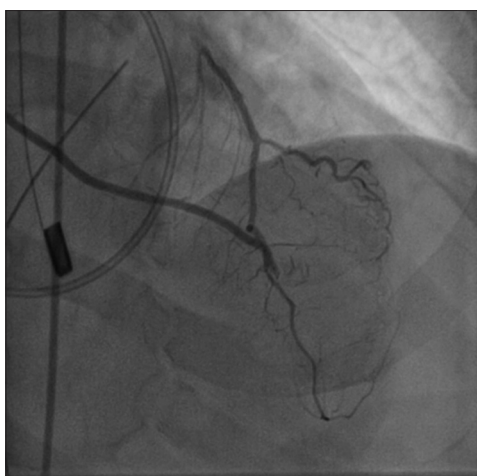


Figure 4: Right internal mammary artery anastomosed to left anterior descending artery

completing MICS take time, it is well worth it because the postoperative outcomes are good. Carrying out MICS poses major challenges to anesthesiologists. Requirement of one lung ventilation (left lung isolation), increase in the time to conduit harvesting, grafting, and surgery in contrast to surgeries via midsternotomy. One might question, if these additional maneuvers are necessary? or could they simply be avoided by carrying out conventional off-pump coronary artery bypass (OPCAB) surgery/conduct percutaneous coronary interventions? The answer, yes, they are necessary. Perhaps MICS is here to stay, as it has been shown to reduce morbidity, postoperative pain, LOS in ICU, and LOS in hospital, without compromising the quality of surgery and revascularization.^[2,3] We know that the outcome of revascularization by CABG surgery is superior to percutaneous coronary intervention. It is meaningful to pursue MICS to improve patient outcome without compromising quality of surgery. With accruing experience, the time to harvest conduits, anastomose, and completing grafting will come down, thus minimal invasive surgeries become relevant. In the endeavor of conducting MICS, newer anesthetic challenges as mentioned above have come up; to pass on the benefits of MICS to the patients, perhaps the anesthesiologists have to gear up to the increasing demands and suitably alter the anesthetic technique to aid MICS.

MICS is not just minimal invasive; at times, it appears to be tailor-made for patients. From our cohort, we had two examples. First, patient #7 (with a functioning LIMA anastomosed to LAD) was scheduled to undergo repeat CABG to right coronary artery; right gastroepiploic artery was anastomosed to the right coronary artery by subxiphoid method. Thus, the potential hazards of

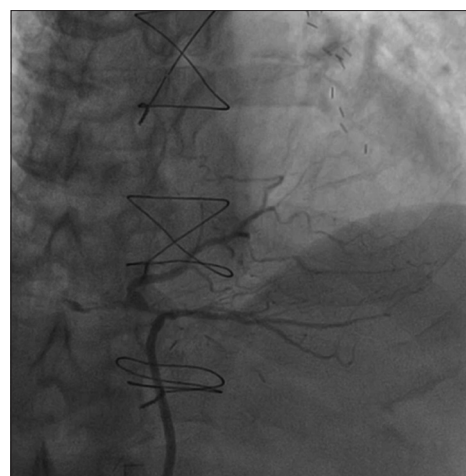


Figure 5: Right gastroepiploic artery anastomosed to posterior descending artery

repeat sternotomy such as potential injury to functional LIMA/other grafts and blood loss were obviated. Second, patient #10, who required grafting to LAD, had undergone excision of pituitary adenoma and was receiving replacement corticosteroid therapy for many years. Such patients may have bone quality, poor wound, and sternal healing.

Carrying out awake subxiphoid approach appears to be a very patient-friendly attractive possibility. Watanabe and coworkers have indeed conducted awake subxiphoid CABG surgery under thoracic epidural anesthesia in three patients and rightly termed them “minimal invasive cardiac surgery.”^[4] At our center, several awake cardiac surgeries via midsternotomy have been conducted earlier under thoracic epidural anesthesia.^[5] It is our belief that awake subxiphoid coronary artery bypass surgery may be beneficial in pulmonary cripples.

Yet, another option in modifying subxiphoid technique is the use of 3 dimension cameras for harvesting LIMA via videoendoscopy and use of robots to harvest LIMA and graft it to the LAD or first diagonal may revolutionize the surgery and postoperative recovery. Considering these, despite the initial difficulties encountered by the team, in the long run, this technique may prove patient friendly.

Role of transesophageal echo during minimally invasive coronary artery surgeries

The role of TEE during MICS but carried out under CPB has been discussed by Jha *et al.*^[6] Unlike the information provided by Jha *et al.*, the applications of TEE are different during MICS via subxiphoid

approach. Most cardiac anesthesiologists are comfortable “seeing” the heart and monitoring it. However, during subxiphoid surgery, one is unable to visualize the heart and in the absence of this luxury, viewing the heart using TEE becomes very important. Monitoring valve function and wall motion abnormalities during grafting is important and is a morbidity saving early information. Since the grafting time is prolonged during MICS, it is vital that anesthesiologists monitor the cardiac function and add inputs to the surgeon about the myocardial function. In patient #3, myocardial function worsened (detected by TEE) during grafting, possibly due to hypoxia caused by one-lung ventilation. Both hypoxia and myocardial dysfunction were reversed by restoring two-lung ventilation briefly. Rest of the surgery was carried out again under one-lung ventilation without events. Hemodynamic monitoring alone may not provide such data early; in our opinion, TEE is invaluable monitoring option during MICS. As mentioned earlier, TEE helps in positioning of arterial or venous cannula (used for CPB) for covering to CPB and intra-aortic balloon counterpulsation catheter.

Lack of requirement of blood or blood product transfusion appears to be a factor which is clearly superior to midsternotomy. While comparing our prevailing midsternotomy data, we observed a mean reduction in the blood loss by about 400–500 ml. With time and experience, the blood loss could further be reduced. Graft patency during minimally invasive surgeries is a matter of debate.^[4] Noting 100% patency of grafts in our cohort is a reassuring fact; this observation suggests that MICS by subxiphoid approach needs further serious attention and analysis, with an intention to popularize the technique. There would always be a limitation that this approach is beneficial

only for patients requiring fewer grafts in contrast to midsternotomy.

CONCLUSIONS

MICS via subxiphoid approach is safe, reproducible, has a good short-term outcome, and undeniable benefits over the conventional MICS via thoracotomy and sternotomy. Applying robotic limbs, three-dimensional endoscopic vision might improve the technique and outcome further. Conducting awake subxiphoid surgery may be possible.

Financial support and sponsorship

Nil.

Conflicts of interest

There are no conflicts of interest.

REFERENCES

1. Levinson MM. Subxiphoid multi-arterial OPCAB: Surgical technique and initial case report. *Heart Surg Forum* 2005;8:E303-10.
2. Modi P, Hassan A, Chitwood WR Jr. Minimally invasive mitral valve surgery: A systematic review and meta-analysis. *Eur J Cardiothorac Surg* 2008;34:943-52.
3. Iribarne A, Easterwood R, Chan EY, Yang J, Soni L, Russo MJ, *et al.* The golden age of minimally invasive cardiothoracic surgery: Current and future perspectives. *Future Cardiol* 2011;7:333-46.
4. Gersbach P, Imsand C, von Segesser LK, Delabays A, Vogt P, Stumpe F. Beating heart coronary artery surgery: Is sternotomy a suitable alternative to minimal invasive technique? *Eur J Cardiothorac Surg* 2001;20:760-4.
5. Chakravarthy M, Jawali V, Manohar MV. *Journal of anesthesiology clinical pharmacology* 2005;21:217-20.
6. Jha AK, Malik V, Hote M. Minimally invasive cardiac surgery and transesophageal echocardiography. *Ann Card Anaesth* 2014;17:125-32.