



Update Article

Hip arthroscopy[☆]

Henrique Antônio Berwanger de Amorim Cabrita^{a,b,*},
 Christiano Augusto de Castro Trindade^b, Henrique Melo de Campos Gurgel^{a,b},
 Rafael Demura Leal^b, Ricardo da Fonseca de Souza Marques^b

^a Instituto de Ortopedia e Traumatologia, Hospital das Clínicas, Faculdade de Medicina, Universidade de São Paulo, São Paulo, SP, Brazil

^b Instituto Vita, São Paulo, SP, Brazil

ARTICLE INFO

Article history:

Received 8 July 2013

Accepted 12 July 2013

Available online 14 May 2014

Keywords:

Hip/pathology

Hip/surgery

Arthroscopy

Palavras-chave:

Quadril/patologia

Quadril/cirurgia

Artroscopia

ABSTRACT

Hip arthroscopy is a safe method for treating a variety of pathological conditions that were unknown until a decade ago. Femoroacetabular impingement is the commonest of these pathological conditions and the one with the best results when treated early on. The instruments and surgical technique for hip arthroscopy continue to evolve. New indications for hip arthroscopy has been studied as the ligamentum teres injuries, capsular repair in instabilities, dissection of the sciatic nerve and repair of gluteal muscles tears (injuries to the hip rotator cuff), although still with debatable reproducibility. The complication rate is low, and ever-better results with fewer complications should be expected with the progression of the learning curve.

© 2014 Sociedade Brasileira de Ortopedia e Traumatologia. Published by Elsevier Editora Ltda. All rights reserved.

Artroscopia de quadril

RESUMO

A artroscopia de quadril é um método seguro para o tratamento de diversas patologias desconhecidas até a última década. O impacto femoroacetabular é a patologia mais comum e com melhores resultados quando tratada precocemente. O instrumental e a técnica cirúrgica da artroscopia de quadril continuam em evolução. Novas indicações de artroscopia de quadril vem sendo estudadas, como o tratamento das lesões do ligamento redondo, capsulorrafia nas instabilidades, dissecação do nervo ciático e reparo de lesões dos músculos glúteos (lesões do manguito rotador do quadril), porém ainda com reprodutibilidade discutível. A taxa de complicações é baixa e resultados cada vez melhores e com menor número de complicações devem ser esperados com a progressão da curva de aprendizado.

© 2014 Sociedade Brasileira de Ortopedia e Traumatologia. Publicado por Elsevier Editora Ltda. Todos os direitos reservados.

[☆] Work performed in the Institute of Orthopedics and Traumatology, Hospital das Clínicas, School of Medicine, Universidade de São Paulo and in the Hip Group, Instituto Vita, São Paulo, SP, Brazil.

* Corresponding author.

E-mail: henriqucabrita@uol.com.br (H.A.B. de Amorim Cabrita).

2255-4971/\$ – see front matter © 2014 Sociedade Brasileira de Ortopedia e Traumatologia. Published by Elsevier Editora Ltda. All rights reserved.
<http://dx.doi.org/10.1016/j.rboe.2014.04.024>

Introduction

Within arthroscopic surgery, approaches toward the hip joint were shunned until recently because of the difficulty in diagnosing intra-articular pathological conditions and the technical difficulty of the surgery.¹

The hip joint capsule is the thickest joint capsule in the human body and is located in deep levels that can only be accessed through voluminous muscles such as the gluteus medius, and the structures neighboring it include the femoral triangle and the sciatic nerve, which limit the access portals. The coxofemoral space is very small and accessible only with joint traction, and instrument manipulation is made difficult by the convex format of the femoral head.²

Over the last two decades, the development of magnetic resonance imaging (MRI) has made it possible to evaluate very many joint and periarticular injuries. New concepts such as femoroacetabular impingement (FAI) and the peritrochanteric space have been introduced.^{2,3}

Specific instruments have also been developed, such as long cannulae, special optics and flexible radiofrequency shavers and probes of smaller diameter.

Indications and contraindications

Hip arthroplasty provides a minimally invasive technique for procedures that will require surgical dislocation of the hip. In addition, it allows orthopedists to access intra-articular alterations that previously were not diagnosed, let alone treated.⁴

The most commonly treated pathological conditions are FAI, labral lesions, teres ligament injuries and external and internal prominences.⁵

The diagnostic indications involve evaluation of the cartilage in osteonecrosis cases or in conjunction with osteotomy and evaluation of painful arthroplasty and collection of tissue for culturing.⁶

Synovial diseases (chondromatosis, pigmented villonodular synovitis and rheumatoid arthritis) present good surgical indications, as also does treatment of deep gluteal pain (formerly piriform syndrome).

New indications for arthroscopy, such as reconstruction of the teres ligament, capsulorrhaphy in cases of instability⁷ and repair of injuries to the gluteal tendons³ are being studied.

The main contraindication for hip arthroscopy is the existence of active infectious processes, except in cases of drainage of pyoarthritis or evaluation of infection in prostheses. Active skin infections and, especially, infections in the region of the portals impede surgery.⁸

Technical difficulties should be expected, but are not an absolute contraindication for surgery in obese patients with advanced osteoarthritis or arthrofibrosis.⁸

Arthroscopic hip examination

The arthroscopic anatomy of the hip is divided into two joint compartments: central and peripheral (Table 1).

The central compartment is the space between the cartilaginous portion of the femoral head and the acetabular

Table 1 – Arthroscopic examination of the hip.

Central compartment – approached under traction
Load surface of the femoral head
Hyaline joint cartilage
Articular portion of the fibrocartilaginous labrum
Acetabular fossa and pulvinar
Teres ligament
Transverse ligament
Peripheral compartment – examined without traction
Surface of the femoral head that is not subjected to loading
Femoral neck
Joint capsule
Capsular portion of the labrum
Zona orbicularis (transverse fibers of the joint capsule)
Medial synovial plica
Medial articular recess
Articular portion of the transverse ligament (in cases of laxity)

cotyledon, with participation from the articular portion of the labrum, the pulvinar and the teres and transverse ligaments. This compartment can only be reached through traction and separation of these joint surfaces.

The peripheral compartment involves the joint capsule (with its medial, anterior and posterior recesses and the transverse thickening of its fibers, named the zona orbicularis), the capsular point of the labrum, the transverse ligament, the medial synovial plica and the anterolateral portion of the femoral head, where cam-like deformities commonly occur.

In addition to these, the periarticular structures, such as the gluteal musculature, iliotibial band, fascia lata, piriform muscles, external rotators, sciatic nerve and greater sciatic foramen, can be explored. This is done in a so-called extra-articular endoscopic procedure.

Some authors have preferred to begin the surgical procedure in the peripheral compartment, using the argument that, in this manner, the labrum is not exposed to inadvertent perforation. However, most authors have started the surgery at the central compartment, under traction, and then have explored the peripheral compartment secondarily.

Pathological conditions dealt with using hip arthroscopy

Acetabular labral tears

Labral tears are an important cause of hip pain. The function of the labrum is better understood today and it is believed that it acts as a sealant and that, under negative pressure, it ensures some stability for the hip and prevents excessive contact between the cartilages of the acetabulum and the femoral head.

Acetabular labral tears were initially characterized as an isolated pathological condition without major repercussions, but they have started to be thought of as a consequence of bone deformity, trauma or supraphysiological movements of the hip, as in the case of ballerinas,⁹ and are directly related to joint degeneration.¹⁰

Labral tears may have traumatic or degenerative origins¹¹ and may have the following etiological factors: traumatic

wrenching, joint degeneration, bone insufficiency (dysplasia), instability or femoroacetabular impingement.¹²

Independent of the etiology, labral tears are more common in the anterosuperior quadrant.¹³ In this location, the mechanical resistance of the labrum is less than in all other regions, either through traction (instability) or through compression (femoroacetabular impingement), as shown in *in vitro* mechanical tests.¹⁴

McCarthy et al.¹⁰ observed that labral tears and hip arthrosis were progressions of the same degenerative disease and opened up the possibility of intervening in the evolution of the arthrosis through arthroscopic surgical treatment of the labral tear and its causes.¹⁵

Arthroscopic surgery has traditionally been used for diagnosing intra-articular lesions and for removing free bodies from the hip. Its use for labral tears has been widely disseminated over the past decade.¹⁵

Arthroscopy with stabilization by means of anchors or partial resection of the labrum, together with correction of the factor that triggered the lesion, is the most recommended treatment. Although the initial studies on arthroscopy reported a relatively high failure rate,¹⁶ the results have become more promising since the development of the concepts of femoroacetabular impingement and labral re-fixation or reconstruction.

Good results from partial resection of the labrum by means of arthroscopy were presented by 82% of 52 patients who were followed up for 10 years, according to Byrd and Jones.¹⁷

Studies on sheep have demonstrated that the labrum has the capacity to heal after re-fixation.¹⁸ Likewise, arthroscopy performed on human cases has shown healing in more than 88% of reoperated cases.¹⁸

In open treatment for femoroacetabular impingement, Espinosa et al.¹⁹ observed that the results were better in patients in whom the labrum had been fixed than in those who underwent resection (80% versus 28%), after two years of follow-up.

In a matched group of 74 patients who underwent arthroscopy to treat mixed or pincer-like femoroacetabular impingement, labral fixation also presented better results than resection. After one year of follow-up, the group with the repairs presented a mean Harris hip score (HHS) of 94.3%, and 87.9% of the results were good. On the other hand, in the group in which the labrum was resected, the mean HHS was 88.9% and 66.7% of the results were good.²⁰

In following up two groups (23 and 25 patients) with labral tears and femoroacetabular impingement that were operated by means of arthroscopy, the group that was treated with labral stabilization and osteochondroplasty presented a better functional score and lower reoperation rate.²¹

In cases in which labral fixation is not possible, reconstruction can be performed. Techniques using grafts coming from the iliotibial band or gracilis tendon have been described, with excellent results.^{22,23}

Evaluation of the results from treating labral tears is very difficult because there is no uniform classification, the non-arthrotic indices for functional evaluation are inconsistent and the treatment protocols are very varied.¹⁶

Mohtadi et al.²⁴ described a ceiling effect in which active young patients presented good scores despite their limitations

due to pathological conditions of the hip. Thus, they created iHOT, which is a specific questionnaire for this active population with hip pains.

All the studies are unanimous in stating that the main factor for a poor prognosis is the presence of arthrosis or cartilage injuries of Outerbridge type IV or Tönnis type III or IV.¹⁶ If the joint space is less than 2 mm, progression to arthroplasty occurs in 80% of such cases on average, after two years of follow-up.²⁵

Femoroacetabular impingement

Femoroacetabular impingement (FAI) is a purely mechanical disorder that occurs when the hip presents incongruence and the extremes of its range of movement. It has the consequences of joint pain and predisposition toward arthrosis.²⁶ Its behavior resembles an abnormality of the rotation mechanism of the femoral head, in contrast with the shearing forces that occur in varus or valgus necks.

The estimated prevalence of asymptomatic FAI in the general population is 10–15%.²⁷

The clinical types described clinically by Ganz et al.²⁶ are the cam and pincer or tong types.

In more than 70% of the cases of dislocation operated surgically or arthroscopically, both acetabular and femoral alterations are found, and these cases are described as presenting “mixed” impingement.^{28,29}

The appropriate surgical treatment involves correction of the deformities on both sides of the joint, by means of osteochondroplasty.

In some cases, the impingement may be due to overload, above the physiological level, of a hip that is normal from an anatomical point of view, as seen in ballerinas, for example.³⁰ In these cases, the cartilage injury may occur in atypical locations.⁹

Ganz et al.²⁶ described a direct association between FAI and secondary arthrosis of the hip and recommended early surgical intervention in cases of femoroacetabular deformities, before irreversible cartilage injuries occur, thus possibly delaying the evolution of the hip arthrosis. In their pioneering evaluation, they reported surgical dislocation, which became the gold standard at that time.

Arthroscopy is clearly an attractive option, since it involves smaller incisions, shorter recovery time and potentially fewer complications than seen in open surgery. In several recent articles, the two procedures were seen to have results similar to those from arthroscopy.

The best indications for arthroscopy are cam-like tears alone and mild acetabular retroversion.¹⁶

Mardones et al.³¹ compared the open and arthroscopic surgical techniques in cadavers and did not find any significant differences in the precision of osteochondroplasty of the femoral head in cases of cam-like impingement.

Ilizaliturri et al.³² demonstrated improvements in the WOMAC (Western Ontario and McMaster Universities) arthritis score in 15 of their 19 patients. There were no severe complications. One patient evolved to arthroplasty two years after the surgery.

Cabrita et al.³³ described 60 hip arthroscopy procedures (35 cases of femoroacetabular impingement), without severe

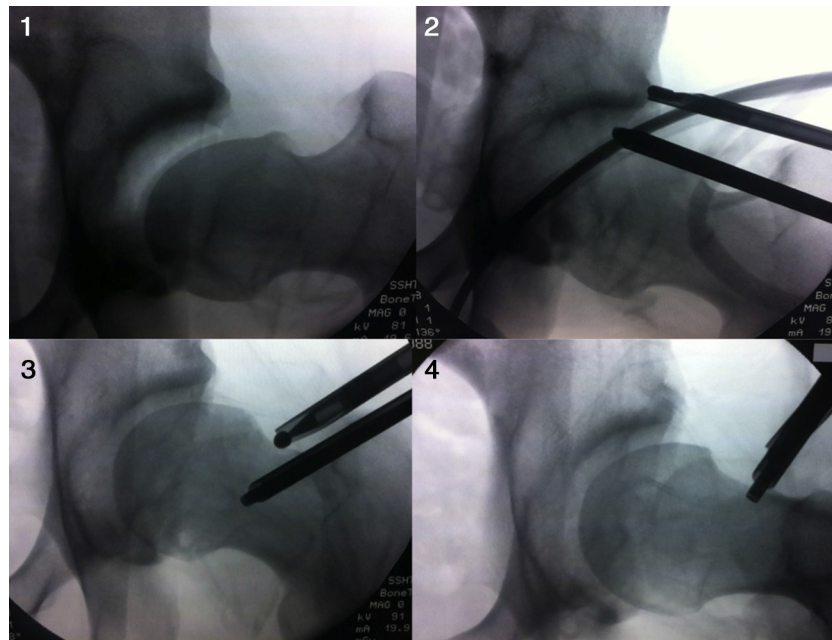


Fig. 1 – Sequence of fluoroscopy images during hip arthroscopy: (1) joint under traction, with the presence of cam and pincer; (2) resection of the pincer; (3) osteochondroplasty of the femoral neck (cam); and (4) final appearance.

complications and with conversion to arthroplasty in 6% (Fig. 1).

Polesello et al.³⁴ operated on 49 athletes (51 hips) and found that 76% of the athletes had fully returned to their sports after a minimum follow-up period of one year (mean of 39 months).

Larson and Giveans³⁵ described their early experience from 100 hips in 96 patients with a mean follow-up of 9.9 months, with significant improvement in the HHS and conversion to arthroplasty in 3% of the cases.

Philippon et al.³⁶ operated on 122 patients with femoroacetabular impingement by means of arthroscopy and followed them up for a mean of 2.3 years (minimum follow-up of two years). The mean HHS went from 58 to 84, and 10 patients (8.2%) underwent total hip arthroplasty. The factors that predicted improvements were preoperative HHS > 80, previous joint space larger than 2 mm and labral repair rather than resection during the arthroscopy procedure.

Diagnostic indications

Painful hip arthroplasty

Evaluation of painful hip arthroplasty by means of arthroscopy is the commonest diagnostic indication. Collection of synovial and joint capsule fluid samples provides a good source for cultures. Other sources of pain can also be observed in prostheses, such as tendinitis of the iliopsoas due to friction,³⁶ interposition of foreign bodies, joint instability, aseptic loosening, impingement between components and adhesions.³⁷

Osteonecrosis

Evaluation of the joint cartilage in osteonecrosis cases is possible using hip arthroscopy, which can be done

together with decompression (forage) of the femoral head, in Ficat stages I or IIa of osteonecrosis, without risk of worsening the circulation of the femoral head. Ellenrieder et al.³⁸ used arthroscopy to determine how to manage these cases. In patients with Steinberg stages II and III, without head collapse or chondral lesions, decompression was performed in association with grafting using autologous graft cylinders. In cases of collapse (Steinberg IV), reduction of the collapsed portion was attempted with the aid of fluoroscopy.³⁸

In addition, indication of arthroscopy has become interesting because damage to the cartilage of the femoral head can be better assessed. In 52 cases of osteonecrosis, Rush et al.³⁹ found damage to the femoral cartilage that had not been detected through magnetic resonance imaging in 36% of the patients.

Hip arthroscopy in trauma cases

Hip arthroscopy is indicated in post-traumatic cases, with good results achieved safely.⁴⁰

Cabrita et al.⁴¹ performed 32 hip arthroscopy procedures in trauma cases, of which twenty were subsequent to traumatic hip dislocation. The state of the joint cartilage, the fractured acetabular border or femoral head, teres ligament injuries and joint instability were viewed. The cases were operated 6 h to 10 days after the dislocation. There was no extra-articular extravasation of physiological serum during the surgery, and the pressure of 30 mmHg that was maintained by means of an infusion pump was sufficient for surgical manipulation. Likewise, in cases of late sequelae of hip dislocation, arthroscopy can be very useful for documenting injuries and removing free bodies from the joint.⁴²

Synovial diseases of the hip

Pigmented villonodular synovitis may present diffusely or focally. Both conditions can be treated using arthroscopy, but the prognosis is very different and poorer in diffuse cases, with early progression to arthritis.⁴³

Boyer and Dorfmann⁴⁴ treated 111 patients with synovial chondromatosis arthroscopically, with a mean follow-up of six years. Half of the patients evolved well and without any need for other treatments. There were indications for new arthroscopy in 20% of the cases, open surgery in 37% and total hip arthroplasty in 19%.

Other authors have reported that arthroplasty is an effective method for removing free chondromatous bodies, but that there might be difficulties in accessing posteromedial and posterolateral areas in the peripheral compartment, which could lead to recurrences.^{45,46}

In a retrospective study, Zhou et al.⁴⁷ inspected 40 hips in 36 patients with autoimmune diseases (17 with ankylosing spondylitis, 11 with rheumatoid arthritis and eight with psoriatic arthritis), by means of irrigation and debridement of the inflammatory tissue. All of the patients presented improved range of motion and diminished synovitis on magnetic resonance imaging, and 75% of the patients were satisfied with the results.

Arthroscopy in cases of sequelae of childhood diseases

Hip dysplasia

There is some controversy regarding indications for arthroscopy in cases of dysplasia, and its use should be considered to be the exception.

Byrd and Jones⁴⁸ reported good results in 38 cases that were dysplastic or on the threshold of dysplasia, with progression of the mean HHS from 57 points to 83, and there were only three unsatisfactory results after a mean follow-up of 27 months.

Parvizi et al.⁴⁹ reported that painful symptoms persisted in 24 cases out of 34 cases that were followed up. Fourteen cases evolved to serve arthrosis and there were 13 cases of lateral migration of the femoral head. These authors contraindicated hip arthroscopy in cases of dysplasia because of the possibility of acceleration of the degenerative process.

Recently, arthroscopy has been performed in such patients together with or after periacetabular osteotomy, with good results. One hypothesis for explaining this is that the acetabular reorientation provides a better environment for the repaired labrum to heal in.⁵⁰

Slipped capital femoral epiphysis and Perthes sequelae

Slipped capital femoral epiphysis and Perthes sequelae are two causes of cam-like femoroacetabular impingement that can be dealt with using arthroscopy.⁵¹

Deformities due to slipped capital femoral epiphysis should be evaluated by means of lateral radiographs or computed tomography. In cases of alteration of the femoral offset, i.e. significant posterior slippage, osteochondroplasty to correct the

femoroacetabular impingement will not work. Rather, there needs to be realignment of the proximal femur by means of intra-articular or subtrochanteric.

Although Freeman et al.⁵² affirmed that arthroscopy would not affect the natural history of Perthes disease, they indicated that this procedure would improve quality of life and scores, over a minimum follow-up of two years.

Teres ligament injuries and capsule repair in cases of instability

The function of the teres ligament has still not been well established, but it seems to place limits on combined extension and external rotation movements. It becomes tensed when this movement is tested in physical examinations, or with the Fabere movement (flexion, abduction and external rotation).

Rao et al.⁵³ classified teres ligament injuries into three groups: I – partial traumatic; II – total traumatic; and III – degenerative.

In an initial series of 271 hip arthroscopy procedures, Byrd and Jones⁵⁴ found 41 cases of teres ligament injuries, of which 23 were traumatic and 18 were degenerative.

Philippon et al.⁵⁵ reported that reconstruction of the teres ligament could be performed in a select group of patients with complaints of instability and supraphysiological movements, after attempting the usual arthroscopic management, as in treatments for femoroacetabular impingement, labral repair and capsule plication.

The capsule-ligament stabilizers of the hip are continuing to be studied and their role has still not been defined. Some authors have developed techniques for capsule repair, but the effects of this surgical procedure over the long term remain unknown and prospective studies are still being conducted.^{7,56}

Hip pyoarthritis

Kim et al.⁵⁷ performed arthroscopy on eight cases of hip pyoarthritis in children and two cases in adults and achieved therapeutic success in all of them.

El-Sayed⁵⁸ compared arthroscopic treatment with open drainage in cases of hip pyoarthritis in 20 children: 70% of the results from the open technique were good and 90% from the arthroscopic technique.

Yamamoto et al.⁵⁹ successfully treated four adults with hip pyoarthritis, and Nusem et al.⁶⁰ six adults, using arthroscopy.

Resection of osteoid osteoma

Resection of osteoid osteoma in the hip has been described in children and adults in isolated cases. The symptoms in these patients may simulate those of femoroacetabular impingement, with good indications only in subchondral or anterior femoral neck cases.⁶⁰

Extra-articular arthroscopy (endoscopic treatment of pathological conditions of the hip)

The commonest indications for extra-articular arthroscopy are trochanteric bursitis, external projection and

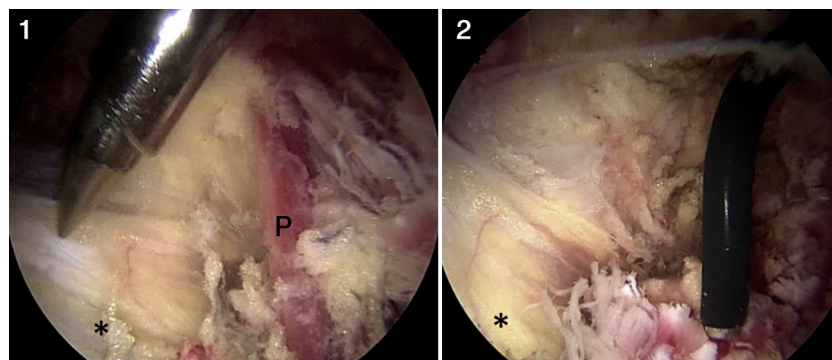


Fig. 2 – Image of endoscopic release of the sciatic nerve: (1) nerve (represented by*) with the piriform muscle, showing adhesences and (2) final appearance of the procedure following tenotomy of the piriform muscle and neurolysis of the sciatic nerve.

tendinopathy of the gluteus minimus and gluteus maximus, which together cover the concept of the painful syndrome of the greater trochanter,⁶¹ internal projection and piriform syndrome (deep gluteal pain).

External projection

External projection is produced by thickening of the posterior portion of the iliotibial band or anterior thickening of the fibers of the gluteus maximus. It is reproduced through friction between these structures and the greater trochanter during flexion or extension, and it may or may not be painful.⁶² Many of the symptomatic cases can be resolved by means of physiotherapy and stretching. Release can be performed as an open or an arthroscopic procedure.⁶³ This can be done with the patient in lateral decubitus.

Polesello et al.⁶³ described a technique that diminished the tension in the iliotibial band by means of half-releasing the gluteal tendon at its femoral insertion, on the linea aspera, with good results.

Trochanteric bursitis and injuries of the gluteal muscles

There are many therapeutic possibilities for trochanteric bursitis. Cases that are refractory to conservative treatment can be treated surgically by means of endoscopy, efficiently and safely.⁶²

Tendon tears of the gluteal muscles have been compared with rotator cuff tears in the shoulder. Incomplete or complete tears are correlated with chronic trochanteric bursitis with a positive Trendelenburg sign. It is very likely that these injuries are underdiagnosed. There is little published data on this topic and new techniques are emerging. However, it remains unclear to what point the muscle injury is reversible, or what its long-term prognosis is.

Internal projection

Internal projection generally occurs when the tendon of the iliopsoas rubs against the iliopectineal eminence or the femoral head.

Ilizariturri et al.⁶⁴ treated 19 patients with internal projection caused by the iliopsoas muscle, with good results and

without any difference regarding whether tenotomy should be performed at the level of the lesser trochanter or in the anterior capsular region of the hip.

In a review article, Khan et al.⁶⁵ reported that arthroscopic release had a lower complication rate and less postoperative pain than shown with the open technique.

Deep gluteal pain

Deep gluteal pain, formerly known as piriform syndrome, is a pathological condition diagnosed by ruling out alternatives and its treatment is eminently conservative. Surgery is indicated in refractory cases.⁶⁶

It manifests as pain in the gluteal region, with or without accompanying sciatic pain. It worsens with local compression and generally continues for years until it is identified.

The classical surgical treatment consists of an open technique, but the esthetic result from this approach and the potential for sciatic nerve injuries often inhibit use of this surgery.

Martin et al.⁶⁷ performed endoscopic release of the sciatic nerve in 35 patients. They dissected it from structures such as the piriform muscle, fibrous bands, vascular malformations and adhesences to the obturator muscles and the quadratus femoris muscle, thereby achieving improvement of the mean HHS from 54.4 before the operation to 78 after the operation, with a follow-up of 1.5 years. The sciatic pain that the patients had complained of when they were seated disappeared in 83% of the cases.

Cabrita et al.⁶⁸ described exploration of the sciatic nerve (Fig. 2) accompanied by tenotomy of the piriform and neurolysis of the sciatic nerve, with intraoperative neural monitoring (evoked potential and electroneuromyography), with good results in their initial ten cases, without recurrences and without neurological injuries.

Complications

In a systematic review of the literature⁶⁹ that included 92 studies and more than 6000 patients, it was concluded that the complication rate was low (0.58%), with a reoperation rate of

6.3%. The commonest cause of complications was conversion to a total hip prosthesis.

The commonest complication is iatrogenic injury to the cartilage or labrum during positioning of the portals.

Neuropraxia of the pudendum nerve and lateral cutaneous nerve of the thigh was the commonest neurovascular complication and was directly related to the traction mechanisms and to skin lesions in the perineal region.

Hip dislocation due to excessive removal of the acetabular rim, intra-abdominal and intrathoracic extravasation, hypothermia, infection, thromboembolic phenomena, avascular necrosis, heterotopic ossification and fracturing of the neck are complications that are reported from time to time.

Cabrita et al.⁴¹ reported that among 450 consecutive cases, the complication rate diminished with the evolution of the learning curve.

However, Souza et al.⁷⁰ stated that among 194 cases that they followed up, the complication rate remained unchanged with the learning curve, although the nature of the complications changed, accompanying indications and surgical techniques that were increasingly complex.

Final remarks

1. Hip arthroscopy is a safe treatment method for a myriad of pathological conditions of the hip that were unknown until a decade ago.
2. Femoroacetabular impingement is the commonest arthroscopic pathological condition and the one that presents the best results from early treatment.
3. The instruments and the surgical techniques for hip arthroplasty are continuing to evolve.
4. New indications for hip arthroplasty are being studied, such as repairs for teres ligament injuries, capsulorrhaphy in cases of traumatic and non-traumatic instability; dissection of the sciatic nerve; and repairs to injuries of the gluteus medius and minimus muscles. Despite the enthusiasm, these indications are technically difficult, with debatable reproducibility, and there is a lack of long-term prospective studies for proving their efficacy.
5. Ever-better results and ever-fewer complications should be expected, in accordance with the learning curve.

Conflicts of interest

The authors declare no conflicts of interest.

REFERENCES

1. Glick JM. Hip arthroscopy by the lateral approach. *Instr Course Lect.* 2006;55:317-23.
2. Byrd JW. Hip arthroscopy utilizing the supine position. *Arthroscopy.* 1994;10(3):275-80.
3. Bedi A, Kelly BT, Khanduja V. Arthroscopic hip preservation surgery: current concepts and perspective. *Bone Joint J.* 2013;95(1):10-9.
4. Cabrita HA, Gurgel HM, Leal RD, Oksman D. Hip arthroscopy in the supine position: follow-up of 400 consecutive cases. *Arthroscopy.* 2011;27(10):e108-9.
5. Lynch TS, Terry MA, Bedi A, Kelly BT. Hip arthroscopic surgery: patient evaluation, current indications, and outcomes. *Am J Sports Med.* 2013;41(5):1174-89.
6. Byrd JW. Hip arthroscopy: patient assessment and indications. *Instr Course Lect.* 2003;52:711-9.
7. Slikker W 3rd, Van Thiel GS, Chahal J, Nho SJ. The use of double-loaded suture anchors for labral repair and capsular repair during hip arthroscopy. *Arthrosc Tech.* 2012;1(2):e213-7.
8. McCarthy JC, Lee JA. Hip arthroscopy: indications, outcomes, and complications. *Instr Course Lect.* 2006;55:301-8.
9. Kolo FC, Charbonnier C, Pfirrmann CW, Duc SR, Lubbeke A, Duthon VB, et al. Extreme hip motion in professional ballet dancers: dynamic and morphological evaluation based on magnetic resonance imaging. *Skeletal Radiol.* 2013;42(5):689-98.
10. McCarthy JC, Noble PC, Schuck MR, Wright J, Lee J, The Otto E. Aufranc Award: the role of labral lesions to development of early degenerative hip disease. *Clin Orthop Relat Res.* 2001;(393):25-37.
11. Leunig M, Sledge JB, Gill TJ, Ganz R. Traumatic labral avulsion from the stable rim: a constant pathology in displaced transverse acetabular fractures. *Arch Orthop Trauma Surg.* 2003;123(8):392-5.
12. Kelly BT, Weiland DE, Schenker ML, Philippon MJ. Arthroscopic labral repair in the hip: surgical technique and review of the literature. *Arthroscopy.* 2005;21(12):1496-504.
13. Leunig M, Podeszwa D, Beck M, Werlen S, Ganz R. Magnetic resonance arthrography of labral disorders in hips with dysplasia and impingement. *Clin Orthop Relat Res.* 2004;(418):74-80.
14. Smith CD, Masouros S, Hill AM, Amis AA, Bull AM. A biomechanical basis for tears of the human acetabular labrum. *Br J Sports Med.* 2009;43(8):574-8.
15. McCarthy JC. Hip arthroscopy: when it is and when it is not indicated. *Instr Course Lect.* 2004;53:615-21.
16. McCarthy JC. The diagnosis and treatment of labral and chondral injuries. *Instr Course Lect.* 2004;53:573-7.
17. Byrd JW, Jones KS. Hip arthroscopy for labral pathology: prospective analysis with 10-year follow-up. *Arthroscopy.* 2009;25(4):365-8.
18. Philippon MJ, Schenker ML, Briggs KK, Kuppertschmidt DA, Maxwell RB, Stubbs AJ. Revision hip arthroscopy. *Am J Sports Med.* 2007;35(11):1918-21.
19. Espinosa N, Rothenfluh DA, Beck M, Ganz R, Leunig M. Treatment of femoro-acetabular impingement: preliminary results of labral refixation. *J Bone Joint Surg Am.* 2006;88(5):925-35.
20. Larson CM, Giveans MR. Arthroscopic debridement versus refixation of the acetabular labrum associated with femoroacetabular impingement. *Arthroscopy.* 2009;25(4):369-76.
21. Nepple JJ, Zebala LP, Clohisy JC. Labral disease associated with femoroacetabular impingement: do we need to correct the structural deformity? *J Arthroplasty.* 2009;24(6 Suppl):114-9.
22. Ejnisman L, Philippon MJ, Lertwanich P. Acetabular labral tears: diagnosis, repair, and a method for labral reconstruction. *Clin Sports Med.* 2011;30(2):317-29.
23. Matsuda DK, Burchette RJ. Arthroscopic hip labral reconstruction with a gracilis autograft versus labral refixation: 2-year minimum outcomes. *Am J Sports Med.* 2013;41(5):980-7.
24. Mohtadi NG, Griffin DR, Pedersen ME, Chan D, Safran MR, Parsons N, et al. The development and validation of a self-administered quality-of-life outcome measure for young, active patients with symptomatic hip disease: the

- International Hip Outcome Tool (iHOT-33). *Arthroscopy*. 2012;28(5):595-605.
25. Philippon MJ, Briggs KK, Carlisle JC, Patterson DC. Joint space predicts THA after hip arthroscopy in patients 50 years and older. *Clin Orthop Relat Res*. 2013;471(8):2492-6.
 26. Ganz R, Parvizi J, Beck M, Leunig M, Nötzli H, Siebenrock KA. Femoroacetabular impingement: a cause for osteoarthritis of the hip. *Clin Orthop Relat Res*. 2003;(417):112-20.
 27. Leunig M, Ganz R. Femoroacetabular impingement. A common cause of hip complaints leading to arthrosis. *Unfallchirurg*. 2005;108(1):9-10.
 28. Beck M, Kalhor M, Leunig M, Ganz R. Hip morphology influences the pattern of damage to the acetabular cartilage: femoroacetabular impingement as a cause of early osteoarthritis of the hip. *J Bone Joint Surg Br*. 2005;87(7):1012-8.
 29. Philippon M, Schenker M, Briggs K, Kuppersmith D. Femoroacetabular impingement in 45 professional athletes: associated pathologies and return to sport following arthroscopic decompression. *Knee Surg Sports Traumatol Arthrosc*. 2007;15(7):908-14.
 30. Duthon VB, Charbonnier C, Kolo FC, Magnenat-Thalmann N, Becker CD, Bouvet C, et al. Correlation of clinical and magnetic resonance imaging findings in hips of elite female ballet dancers. *Arthroscopy*. 2013;29(3):411-9.
 31. Mardones R, Lara J, Donndorff A, Barnes S, Stuart MJ, Glick J, et al. Surgical correction of "cam-type" femoroacetabular impingement: a cadaveric comparison of open versus arthroscopic debridement. *Arthroscopy*. 2009;25(2):175-82.
 32. Ilizaliturri Jr VM, Orozco-Rodriguez L, Acosta-Rodriguez E, Camacho-Galindo J. Arthroscopic treatment of cam-type femoroacetabular impingement: preliminary report at 2 years minimum follow-up. *J Arthroplasty*. 2008;23(2):226-34.
 33. Cabrita HA, Castropil LF. Hip arthroscopy - an evaluation of 60 consecutive cases. *J Bone Joint Surg Br*. 2006;88(Suppl 1):76.
 34. Polesello GC, Ono NK, Bellan DG, Honda EK, Guimarães RP, Junior WR, Sella GD. Artroscopia do quadril em atletas. *Rev Bras Ortop*. 2009;44(1):26-31.
 35. Larson CM, Giveans MR. Arthroscopic management of femoroacetabular impingement: early outcomes measures. *Arthroscopy*. 2008;24(5):540-6.
 36. Philippon MJ, Briggs KK, Yen YM, Kuppersmith DA. Outcomes following hip arthroscopy for femoroacetabular impingement with associated chondrolabral dysfunction: minimum two-year follow-up. *J Bone Joint Surg Br*. 2009;91(1):16-23.
 37. McCarthy JC, Jibodh SR, Lee JA. The role of arthroscopy in evaluation of painful hip arthroplasty. *Clin Orthop Relat Res*. 2009;467(1):174-80.
 38. Ellenrieder M, Tischer T, Kreuz PC, Fröhlich S, Fritsche A, Mittelmeier W. Arthroscopically assisted therapy of avascular necrosis of the femoral head. *Oper Orthop Traumatol*. 2013;25(1):85-94.
 39. Ruch DS, Sekiya J, Dickson Schaefer W, Koman LA, Pope TL, Poehling GG. The role of hip arthroscopy in the evaluation of avascular necrosis. *Orthopedics*. 2001;24(4):339-43.
 40. Yamamoto Y, Ide T, Ono T, Hamada Y. Usefulness of arthroscopic surgery in hip trauma cases. *Arthroscopy*. 2003;19(3):269-73.
 41. Cabrita HBA. Artroscopia de quadril. In: Barros Filho TEP, Camargo OP, Camanho GL, organizadores. *Clínica Ortopédica*. São Paulo: Manole; 2011. p. 966-89.
 42. Ilizaliturri Jr VM, Gonzalez-Gutierrez B, Gonzalez-Ugalde H, Camacho-Galindo J. Hip arthroscopy after traumatic hip dislocation. *Am J Sports Med*. 2011;39(Suppl):50S-7S.
 43. Ward Sr WG, Boles CA, Ball JD, Cline MT. Diffuse pigmented villonodular synovitis: preliminary results with intralesional resection and p32 synoviorthesis. *Clin Orthop Relat Res*. 2007;454:186-91.
 44. Boyer T, Dorfmann H. Arthroscopy in primary synovial chondromatosis of the hip: description and outcome of treatment. *J Bone Joint Surg Br*. 2008;90(3):314-8.
 45. Lee JB, Kang C, Lee CH, Kim PS, Hwang DS. Arthroscopic treatment of synovial chondromatosis of the hip. *Am J Sports Med*. 2012;40(6):1412-8.
 46. Zini R, Longo UG, de Benedetto M, Loppini M, Carraro A, Maffulli N, et al. Arthroscopic management of primary synovial chondromatosis of the hip. *Arthroscopy*. 2013;29(3):420-6.
 47. Zhou M, Li ZL, Wang Y, Liu YJ, Zhang SM, Fu J, et al. Arthroscopic debridement and synovium resection for inflammatory hip arthritis. *Chin Med Sci J*. 2013;28(1):39-43.
 48. Byrd JW, Jones KS. Hip arthroscopy in the presence of dysplasia. *Arthroscopy*. 2003;19(10):1055-60.
 49. Parvizi J, Bican O, Bender B, Mortazavi SM, Purtill JJ, Erickson J, et al. Arthroscopy for labral tears in patients with developmental dysplasia of the hip: a cautionary note. *J Arthroplasty*. 2009;24(Suppl 6):110-3.
 50. Matsuda DK, Safran MR. Arthroscopic internal fixation of osteochondritis dissecans of the femoral head. *Orthopedics*. 2013;36(5):e683-6.
 51. Jayakumar P, Ramachandran M, Youm T, Achan P. Arthroscopy of the hip for paediatric and adolescent disorders: current concepts. *J Bone Joint Surg Br*. 2012;94(3):290-6.
 52. Freeman CR, Jones K, Byrd JW. Hip arthroscopy for Legg-Calvé-Perthes disease: minimum 2-year follow-up. *Arthroscopy*. 2013;29(4):666-74.
 53. Rao J, Zhou YX, Villar RN. Injury to the ligamentum teres. Mechanism, findings, and results of treatment. *Clin Sports Med*. 2001;20(4):791-9.
 54. Byrd JW, Jones KS. Traumatic rupture of the ligamentum teres as a source of hip pain. *Arthroscopy*. 2004;20(4):385-91.
 55. Philippon MJ, Pennock A, Gaskill TR. Arthroscopic reconstruction of the ligamentum teres: technique and early outcomes. *J Bone Joint Surg Br*. 2012;94(11):1494-8.
 56. Domb BG, Philippon MJ, Giordano BD. Arthroscopic capsulotomy, capsular repair, and capsular plication of the hip: relation to atraumatic instability. *Arthroscopy*. 2013;29(1):162-73.
 57. Kim SJ, Choi NH, Ko SH, Linton JA, Park HW. Arthroscopic treatment of septic arthritis of the hip. *Clin Orthop Relat Res*. 2003;(407):211-4.
 58. El-Sayed AM. Treatment of early septic arthritis of the hip in children: comparison of results of open arthrotomy versus arthroscopic drainage. *J Child Orthop*. 2008;2(3):-37.
 59. Yamamoto Y, Ide T, Hachisuka N, Maekawa S, Akamatsu N. Arthroscopic surgery for septic arthritis of the hip joint in 4 adults. *Arthroscopy*. 2001;17(3):290-7.
 60. Nusem I, Jabur MK, Playford EG. Arthroscopic treatment of septic arthritis of the hip. *Arthroscopy*. 2006;22(8):902.e1-3.
 61. Ilizaliturri Jr VM, Camacho-Galindo J. Endoscopic treatment of snapping hips, iliotibial band, and iliopsoas tendon. *Sports Med Arthrosc*. 2010;18(2):120-7.
 62. Cabrita HABA, Gurgel HMC, Leal RD, Emilio L, Oksman D. External snapping hip: a new diagnostic maneuver and arthroscopic treatment of 15 cases. *Arthroscopy*. 2011;27(10):e95-6.
 63. Polesello GC, Queiroz MC, Domb BG, Ono NK, Honda EK. Surgical technique: endoscopic gluteus maximus tendon release for external snapping hip syndrome. *Clin Orthop Relat Res*. 2013;471(8):2471-6.
 64. Ilizaliturri Jr VM, Chaidez C, Villegas P, Briseño A, Camacho-Galindo J. Prospective randomized study of 2 different techniques for endoscopic iliopsoas tendon release in the treatment of internal snapping hip syndrome. *Arthroscopy*. 2009;25(2):159-63.

-
65. Khan M, Adamich J, Simunovic N, Philippon MJ, Bhandari M, Ayeni OR. Surgical management of internal snapping hip syndrome: a systematic review evaluating open and arthroscopic approaches. *Arthroscopy*. 2013;29(5):942-8.
 66. Fishman LM, Dombi GW, Michaelsen C, Ringel S, Rozbruch J, Rosner B, et al. Piriformis syndrome: diagnosis, treatment, and outcome – a 10-year study. *Arch Phys Med Rehabil*. 2002;83(3):295-301.
 67. Martin HD, Shears SA, Johnson JC, Smathers AM, Palmer JJ. The endoscopic treatment of sciatic nerve entrapment/deep gluteal syndrome. *Arthroscopy*. 2011;27(2):172-81.
 68. Cabrita HABA, Gurgel HMC, Leal RD, Oksman D, Ferreira R. Arthroscopic release of the piriformis tendon with intra-operative neuromuscular monitoring. *Arthroscopy*. 2011;27(10):e94-5.
 69. Harris JD, McCormick FM, Abrams GD, Gupta AK, Ellis TJ, Bach Jr BR, et al. Complications and reoperations during and after hip arthroscopy: a systematic review of 92 studies and more than 6,000 patients. *Arthroscopy*. 2013;29(3):589-95.
 70. Souza BG, Dani WS, Honda EK, Ricioli W, Guimaraes RP, Ono NK, et al. Do complications in hip arthroscopy change with experience? *Arthroscopy*. 2010;26(8):1053-7.