

Consider Myocarditis When Patients Treated with Immune Checkpoint Inhibitors Present with Ocular Symptoms

John Y. Rhee^{1,2,*}, Nurhan Torun³, Tomas G. Neilan⁴, Amanda C. Guidon⁵

¹Mass General Brigham, Department of Neurology, Harvard Medical School, Boston, MA, USA

²ATLANTES Research Program, Institute for Culture and Society, University of Navarra, Pamplona, Spain

³Beth Israel Deaconess Medical Center, Department of Ophthalmology, Harvard Medical School, Boston, MA, USA

⁴Massachusetts General Hospital, Division of Cardiology, Harvard Medical School, Boston, MA, USA

⁵Massachusetts General Hospital, Division of Neuromuscular Medicine, Department of Neurology, Harvard Medical School, Boston, MA, USA

*Corresponding author: Amanda C. Guidon, MD, MPH, Mass General Hospital, 165 Cambridge Street, Suite 820, Boston, MA 02114, USA. Tel: +1 617 643 2080; Email: aguidon@partners.org.

Abstract

Immune checkpoint inhibitors (ICIs) have been associated with neurological immune related adverse events (irAE-N) and patients with ICI toxicity may present with neurological or ocular symptoms. Furthermore, patients on ICI may initially present to oncology or neurology. We report a case series of 3 patients treated with ICIs presenting with diplopia or ptosis, found to have concurrent myocarditis in addition to immune-related myopathy (irMyopathy) or myasthenia gravis (irMG). None of the patients described cardiac symptoms, underscoring the importance of screening for myocarditis in patients presenting with diplopia and/or other neuromuscular symptoms which may suggest either irMyopathy or irMG.

Key words: immune checkpoint inhibitor; immune-related adverse events; myocarditis; diplopia; myasthenia gravis.

Background

Immune checkpoint inhibitors (ICIs) are increasingly used for treating various malignancies and may cause serious side effects. Neurological immune-related adverse events (irAE-N) are difficult to diagnose due to non-specific symptoms that can be related to cancer or atypical presentations.¹ One potentially fatal non-neurological irAE is immune-related myocarditis, with high mortality rates.² We describe 3 patients whose presenting symptoms of diplopia or ptosis reflected irMyopathy and/or irMG affecting ocular muscles, and were also found to have myocarditis which was asymptomatic.

Cases

Case 1

A 69-year-old man with metastatic renal cell carcinoma (RCC) on axitinib and 3 months of pembrolizumab presented to the emergency room (ER) with 2 weeks of binocular diplopia and no cardiac symptoms. Work-up is summarized in [Table 1](#). Cardiac biopsy demonstrated myocarditis. He received methylprednisolone 1 g i.v. daily for 3 days. Because TropT-hs rose again after initial improvement, mycophenolate mofetil (MMF) 1000 mg twice a day (BID) was added. TropT-hs decreased, and prednisone and MMF were tapered off over 3 months. His ocular symptoms improved on pyridostigmine 60 mg 3 times a day (TID). His RCC is being followed with active surveillance, off therapy, and he has had no adverse cardiovascular outcomes.

Case 2

A 69-year-old woman with metastatic breast cancer on ipilimumab and nivolumab, presented to the emergency department with acute right ptosis and binocular diplopia, worse at day's end. She denied chest pain, pressure, or palpitations. Work-up is summarized in [Table 1](#). On hospital day 1, she developed new onset atrial fibrillation with heart rates reaching 200 beats per minute. TropT-hs peaked at 132 ng/L. Endomyocardial biopsy showed active myocarditis. Methylprednisolone 1 g i.v. for 3 days followed by prednisone and pyridostigmine 90 mg TID resulted in improved ptosis and diplopia, and down-trending TropT-hs. MMF 750 mg PO BID was initiated when TropT-hs rose again during steroid taper. Though ICI therapy was discontinued, at 1 year follow-up, she had no evidence for cancer progression. She had no ocular symptoms and was at her cardiovascular baseline off prednisone and MMF.

Case 3

A 73-year-old man with a past medical history of melanoma (Stage IIIc), and right bundle branch block was referred to neuro-ophthalmology clinic for 1 week of binocular diplopia without ptosis, generalized weakness, and orthopnea without variability or fatigability. He denied chest pain, shortness of breath, dizziness, or palpitations. Given perineural invasion, he had been started on nivolumab 1 month before presentation. With workup in [Table 1](#), he was admitted for presumed irMyocarditis/irMyopathy and irMG and started on

Table 1. Summary of characteristics and treatment of patients.

	Case 1	Case 2	Case 3
Age (years)	69	69	73
Malignancy	Renal cell carcinoma	Breast cancer	Melanoma
Immune checkpoint inhibitor	Pembrolizumab	Ipilimumab, Nivolumab	Nivolumab
Time of drug initiation to presentation (months)	3	1	1
Presenting cardiovascular symptoms	None	None	Orthopnea without variability or fatigability
Physical exam	Left greater than right, and bilateral restrictions in abduction, adduction, and supra- and infraduction, not overcome by oculocephalics, as well as mild exotropia in primary gaze; no fatigable ptosis or diplopia	Moderate right ptosis (not fatigable), diplopia worse on right gaze, and restricted extraocular movements with bilateral medial rectus weakness worse on the left and impaired supraduction bilaterally; moderate eye closure weakness, mild tongue weakness, and extremity weakness of 4+/5 in the triceps and hip flexors bilaterally	Esodeviation at distance which increased slightly on horizontal gaze with limited abduction in both eyes, left more than right, which seemed variable
Troponin (T-hs ref 0-14 ng/L, T ref <0.11 ng/mL)	699 (T-hs)	132 (T-hs)	0.58 (T)
Creatine kinase (ref 39-308 U/L)	201	117	4986
CSF nucleated cells (ref 0-5 cells/mm ³)	116	Not done	Not done
CSF protein (ref 15-45 mg/dL)	64	Not done	Not done
Serum antibody testing	Striated muscle Ab abnormal (titer 1:245760); negative AChR Ab	AChR-binding and modulating antibodies, striational antibodies, and MUSK antibodies negative	AChR-binding antibodies abnormal (titer 5.5 nmol/L, reference < 0.02 nol/L). Modulating antibodies of 96% (reference < 32%) and blocking antibodies 48% (reference < 15%)
Electrocardiogram (EKG)	Normal sinus rhythm. Unchanged during hospital stay	Left atrial enlargement and left anterior hemiblock, low precordial left ventricular voltage. Normal sinus rhythm at discharge	
Echocardiogram (ejection fraction ref 50%-75%)	No wall motion abnormalities, LVEF 66%	No wall motion abnormalities. LVEF 69%	Inferior and inferolateral wall motion abnormality, LVEF 64%
Cardiac MRI	Preserved biventricular resting systolic function with no regional wall motion deficits. Left ventricular ejection fraction (LVEF) 59%, right ventricular ejection fraction (RVEF) 64%. No definite abnormal late gadolinium enhancement demonstrated to indicate active myocardial inflammation	Normal biventricular size and systolic function with no regional wall motion deficits. LVEF 59%, RVEF 64%. No definite abnormal late gadolinium enhancement demonstrated to indicate active myocardial inflammation	Not done
Treatment	Methylprednisolone with prednisone taper, mycophenolate mofetil; pyridostigmine for myasthenia gravis	Methylprednisolone with prednisone taper, mycophenolate mofetil; pyridostigmine for myasthenia gravis	Methylprednisolone, IV immunoglobulin G); pyridostigmine for myasthenia gravis
MRI brain	No signal abnormality or abnormal enhancement	No signal abnormality or abnormal enhancement	No signal abnormality or abnormal enhancement
Electrodiagnostic studies	Abnormal. Spontaneous activity with positive sharp waves in thoracic paraspinal muscles; nerve conduction studies showed no polyneuropathy; repetitive nerve stimulation was not performed	Normal. Repetitive nerve stimulation and needle EMG of the thoracic paraspinals were not performed	Abnormal. Slow repetitive nerve stimulation of the right facial nerve showed abnormal decrement between 1 and 4 minutes post-exercise with maximal decremental response of 18.7%; mild myopathic motor unit potentials in left deltoid

Table 1. Continued

	Case 1	Case 2	Case 3
Cardiac biopsy	Rare scattered CD3 and CD8 T cells, some forming tiny aggregates with myocyte injury; CD4 did not stain myocytes, suggesting a lack of myocyte necrosis; findings were consistent with borderline myocarditis	Active myocarditis with CD3+CD8+ lymphocytes and lesser numbers of CD68+ macrophages associated with myocyte injury in multiple small foci with a trichrome stain showing mild interstitial/replacement fibrosis. Congo red stain was negative for amyloid as were stains for C4D, FoxP3, Granzyme-B, and CD8/PDL1	None

Abbreviations: Ab, antibodies; AChR, acetylcholine receptor; CSF, cerebrospinal fluid; EMG, electromyography; LVEF, left ventricular ejection fraction; MRI, magnetic resonance imaging.

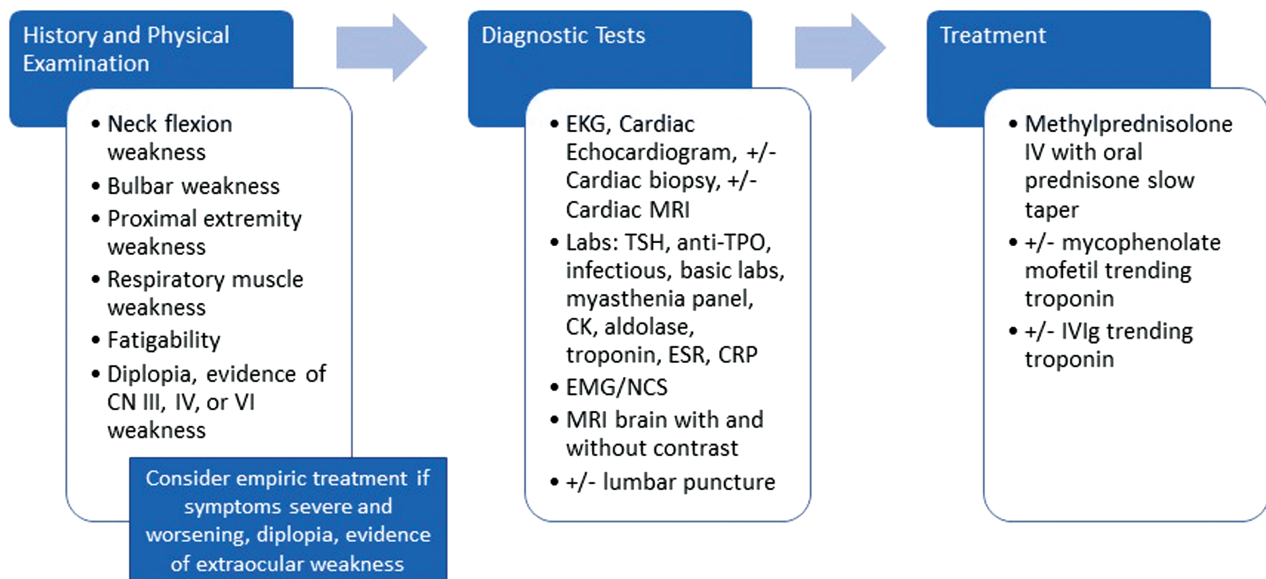


Figure 1. Overlap syndrome of patients on immune checkpoint inhibitors presenting with neurological signs/symptoms and myocarditis. Abbreviations: CK, creatine kinase; CN, cranial nerve; CRP, C-reactive protein; EKG, electrocardiogram; EMG, electromyogram; ESR, erythrocyte sedimentation rate; IV, intravenous; IVIG, intravenous immunoglobulin; MRI, magnetic resonance imaging; NCS, nerve conduction study; TSH, thyroid stimulating hormone; TOP, thyroid peroxidase.

1 g i.v. daily of methylprednisolone for 3 days followed by oral prednisone, plus a heparin drip for 48 hours for non-ST segment elevation myocardial infarction. After 3 days of oral corticosteroids, he had worsening negative inspiratory force (NIFs), diplopia, and required bilevel positive airway pressure (BiPAP) overnight, so was started on i.v. immunoglobulin G (2 g/kg). Prednisone was continued at 60 mg/day. Within 2 days, diplopia and NIFs improved. Pyridostigmine 30 mg PO TID was initiated and prednisone tapered. At the time of his last follow-up in mid-2021, he remained free of ocular symptoms and without cardiovascular symptoms.

Discussion

Clinical Approach to Diplopia and Ptosis in Patients on Immune-Checkpoint Inhibitors

When an irAE-N is considered, workup includes ESR and CRP, CK, and troponin. If CK or troponin is elevated, an EKG is obtained and cardiology consulted. False-positive elevations in troponin-T have been reported in the presence of myositis.³

Therefore, when the source is uncertain, Troponin-I may be considered. irMyocarditis can be difficult to diagnose, typically presents within the first 6 weeks of starting ICI therapy, and may require a cardiac muscle biopsy for definitive diagnosis. An MG antibody panel which includes acetylcholine receptor binding antibody should be checked. Anti-striational Ab is frequently present in these patients (68%), although are not diagnostic for MG⁴ (Fig. 1). Electrodiagnostic studies evaluate for neuromuscular junction disorders or myopathy, although a normal study does not exclude these diagnoses (case 2). Thoracic paraspinous muscles should be included when feasible as they may be the only muscles demonstrating abnormality in irMyopathy.⁵

Brain MRI with contrast excludes a structural cause of symptoms, such as metastatic disease. After brain imaging, lumbar puncture with cytology may be performed to rule out leptomeningeal disease, particularly if these other tests are inconclusive. irAE-N may result in an inflammatory CSF profile with non-specific findings such as a mildly elevated nucleated cell count (typically <20 cells/ μ L) with a lymphocytic predominance, and elevated protein.

The mainstay of irAE-Ns and irMyocarditis treatment is high-dose corticosteroids followed by a taper.⁶ i.v. immunoglobulins and plasma exchange are typically second-line therapy or can be used in combination for severe disease. Mycophenolate mofetil may be added in irMyocarditis which responds incompletely to corticosteroid monotherapy. In unstable patients, escalation of immunosuppression with therapies such as anti-thymocyte globulin, abatacept and alemtuzumab are considered, but mortality is still high, even after treatment.¹

The potential severity of irMyocarditis is high. Nearly 50% of patients experience a major adverse cardiovascular event, resulting in a mortality rate of 25%-50%.² Notably, none of our 3 patients had an adverse cardiac outcome. Monitoring and/or treating subclinical myocarditis may prevent these adverse outcomes and therefore irMyocarditis is a rare but important irAE-N to diagnose and treat.

Pathophysiology of irMyopathy and irMyasthenia Gravis

There are a few proposed mechanisms for irMyopathy and irMyasthenia gravis. A case series autopsies of 2 patients showed that immune infiltration could be limited to cardiac and skeletal muscles and not affect other tissues including adjacent smooth muscle.² Both patients' biopsies had common high-frequency T-cell receptor sequences in infiltrates from cardiac and skeletal muscle, and tumors, with expanded T-cell receptors in the tumor after treatment. High levels of muscle-specific antigens (desmin and troponin) were observed in tumors of both patients, raising hypothesis that targeting of skeletal and cardiac muscle may be from specific antigens present in the myocardium, skeletal muscle, and tumors that are recognized by identical T-cell clones. Therefore, myositis of ocular muscles of a patient on an ICI should prompt evaluation for other muscle involvement, including cardiac muscle. One review of patients who developed a neuromuscular irAE-N showed that 27% were diagnosed with MG, 23% with neuropathy, 34% with myopathy, and 16%, an overlap of one or more of these. Most importantly, 30% of patients diagnosed with MG or myositis had cardiac complications.¹ This may account at least partially for the high irMG-related mortality.¹

Conclusion

Though neurological symptoms may be mild or isolated in patients on ICIs, expedited workup is paramount, due to high mortality from potential rapid worsening of weakness and myocarditis. Because oncologists or neurologists may be the first points of contact for patients presenting with diplopia or ptosis, implementation of multidisciplinary care and

consideration of myocarditis is critical, even when presenting symptoms are only ptosis and/or diplopia.

Acknowledgments

We would like to thank and acknowledge Dr. Xin Gao (Mass General Hospital), Dr. Michael Hassett (Mass General Hospital), Dr. David McDermott (Beth Israel Deaconess), and Dr. Elizabeth Raynor (Beth Israel Deaconess) also provided clinical care for patients included in this manuscript.

Conflict of Interest

The authors indicated no financial relationships.

Author Contributions

Conception/design: J.Y.R., A.C.G. Provision of study material/patients: A.C.G., N.T. Data analysis and interpretation: all authors. Manuscript writing: All authors. Final approval of manuscript: All authors.

Data Availability

The data underlying this article will be shared on reasonable request to the corresponding author.

References

- Johansen A, Christensen SJ, Scheie D, et al. Neuromuscular adverse events associated with anti-PD-1 monoclonal antibodies: Systematic review. *Neurology* 2019;92(14):663-674. <https://doi.org/10.1212/WNL.0000000000007235>
- Johnson DB, Balko JM, Compton ML, et al. Fulminant Myocarditis with Combination Immune Checkpoint Blockade. *N Engl J Med*. 2016;375(18):1749-1755. doi:10.1056/NEJMoa1609214.
- Aggarwal R, Lebiez-Odrobina D, Sinha A, et al. Serum cardiac troponin T, but not troponin I, is elevated in idiopathic inflammatory myopathies. *J Rheumatol*. 2009;36(12):2711-2714. doi:10.3899/jrheum.090562.
- Seki M, Uruha A, Ohnuki Y, et al. Inflammatory myopathy associated with PD-1 inhibitors. *J Autoimmun*. 2019;100:105-113. doi:10.1016/j.jaut.2019.03.005.
- Guidon AC, Burton LB, Chwalisz BK, et al. Consensus disease definitions for neurologic immune-related adverse events of immune checkpoint inhibitors. *J ImmunoTher Cancer*. 2021;9(7). doi:10.1136/jitc-2021-002890.
- Brahmer JR, Lacchetti C, Schneider BJ et al. Management of immune-related adverse events in patients treated with immune checkpoint inhibitor therapy: American Society of Clinical Oncology Clinical Practice Guideline. *J Clin Oncol*. 2018;17:1714-1768.