

Aortic Root Translocation with Arterial Switch for Transposition of the Great Arteries or Double Outlet Right Ventricle with Ventricular Septal Defect and Pulmonary Stenosis

Han Pil Lee, M.D.¹, Ji Hyun Bang, M.D.¹, Jae-Suk Baek, M.D.², Hyun Woo Goo, M.D.³,
Jeong-Jun Park, M.D.¹, Young Hwee Kim, M.D.²

Double outlet right ventricle (DORV) and transposition of the great arteries (TGA) with ventricular septal defect (VSD) and pulmonary stenosis (PS) are complex heart diseases, the treatment of which remains a surgical challenge. The Rastelli procedure is still the most commonly performed treatment. Aortic root translocation including an arterial switch operation is advantageous anatomically since it has a lower possibility of conduit blockage and the left ventricle outflow tract remains straight. This study reports successful aortic root transpositions in two patients, one with DORV with VSD and PS and one with TGA with VSD and PS. Both patients were discharged without postoperative complications.

Key words: 1. Congenital heart disease (CHD)
2. CHD-great vessel anomalies
3. CHD-arterial switch
4. Nikaidoh operation
5. Aortic root translocation

CASE REPORT

1) Case 1

A six-month-old cyanotic child diagnosed with double outlet right ventricle (DORV) with ventricular septal defect (VSD) and pulmonary stenosis (PS) was admitted to the emergency room. The patient's birth weight was 3.3 kg and the patient weighed 7.1 kg at arrival. Previously, the patient had undergone balloon atrial septostomy. Echocardiography revealed DORV, a large subaortic committed VSD, and combined PS (the pulmonary valve annulus was 5 mm, and the Z-score was -4.16), and computed tomography (CT) con-

firmed the echocardiographic diagnosis (Fig. 1A). The size of the aortic valve annulus was 12 mm (Z-score=3.8) on echocardiography.

The operation was performed successfully. Cardiopulmonary bypass (CPB) weaning was smooth with low-dose inotropic support. The CPB and aortic cross-clamp times were 235 minutes and 136 minutes, respectively.

The patient was extubated three days after the operation and the postoperative course was uneventful. The patient was discharged from the hospital nine days after the operation. Postoperative echocardiography showed normal left ventricle (LV) function (LV ejection fraction, 58%). No LV outflow

¹Department of Thoracic and Cardiovascular Surgery, ²Division of Pediatric Cardiology, and ³Department of Radiology, Asan Medical Center, University of Ulsan College of Medicine

Received: July 22, 2015, Revised: October 26, 2015, Accepted: October 27, 2015, Published online: June 5, 2016

Corresponding author: Jeong-Jun Park, Department of Thoracic and Cardiovascular Surgery, University of Ulsan College of Medicine, 88 Olympic-ro 43-gil, Songpa-gu, Seoul 05505, Korea
(Tel) 82-2-3010-3587 (Fax) 82-2-3010-6811 (E-mail) pkjj@amc.seoul.kr

© The Korean Society for Thoracic and Cardiovascular Surgery. 2016. All right reserved.

© This is an open access article distributed under the terms of the Creative Commons Attribution Non-Commercial License (<http://creativecommons.org/licenses/by-nc/4.0>) which permits unrestricted non-commercial use, distribution, and reproduction in any medium, provided the original work is properly cited.

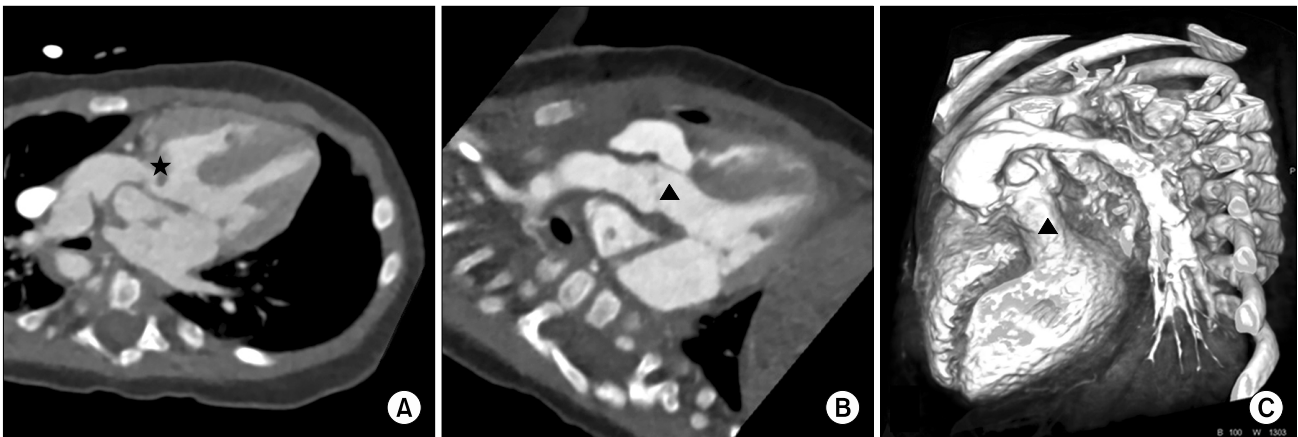


Fig. 1. Case 1: double outlet right ventricle with ventricular septal defect and pulmonary stenosis. (A) Preoperative CT indicating a severely posterior deviated conal septum (★). (B, C) Postoperative CT indicating a widened left ventricle outflow tract (▲). CT, computed tomography.

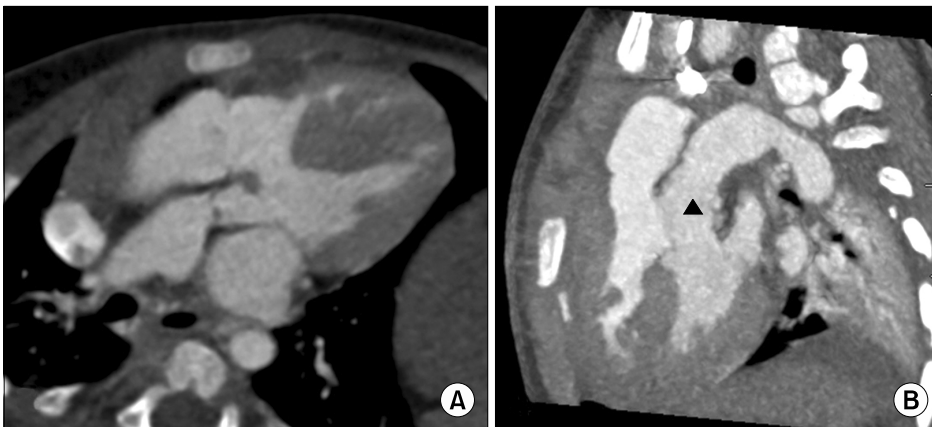


Fig. 2. Case 2: transposition of the great arteries with ventricular septal defect and pulmonary stenosis. (A) Preoperative CT. (B) Postoperative CT showing a widened and straightened left ventricle outflow tract (▲). CT, computed tomography.

tract obstruction (LVOTO) (velocity, 1.1 m/sec), right ventricle outflow tract obstruction (RVOTO) (velocity, 1.0 m/sec), or aortic regurgitation was noted, and free pulmonary regurgitation was observed. Postoperative CT confirmed the successful correction of the condition and a straighter course of the left ventricle outflow tract (LVOT) with intact perfusion of the coronary arteries (Fig. 1B, C). Thirty months after the operation, the patient was still doing very well.

2) Case 2

Case 2 involved a child who was admitted to the emergency room due to cardiac murmur at six days of age. Transposition of the great arteries (TGA) with perimembranous VSD and PS was diagnosed via echocardiography. The patient then underwent balloon atrial septostomy nine

days after birth. Twenty-two days after birth, the patient underwent a modified Blalock-Taussig shunt. Preoperative echocardiography at the age of 20 months revealed TGA with a very large perimembranous VSD and severe PS (the pulmonary valve annulus was 7.4 mm, with a Z-score of -3.34). CT confirmed complete TGA with perimembranous VSD, PS, and the usual TGA patterns of the coronary arteries (Fig. 2A).

At the age of 20 months, the patient was successfully operated on. CPB weaning was smooth. The CPB and aortic cross-clamp times were 409 minutes and 196 minutes, respectively.

Delayed sternal closure was performed on the fifth day after the operation. On the next day, the patient was extubated. After a smooth postoperative course, the patient was discharged from the hospital on postoperative day 14. Postoper-

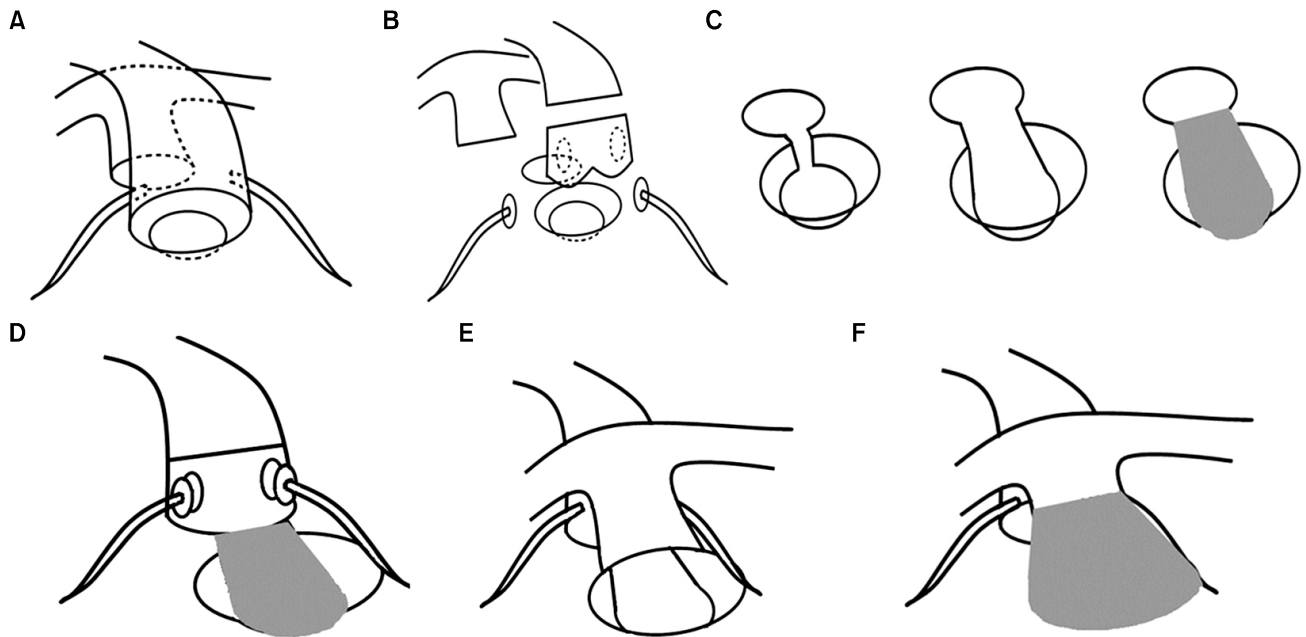


Fig. 3. Operative scheme. (A) Preoperative findings. (B) Aortic root harvest, coronary buttoning, and pulmonary trunk transection. (C) Conal septum resection and widening, and ventricular septal defect closure with a Dacron patch. (D) Aortic root anastomosis and coronary reimplantation after the Lecompte maneuver. (E) Pulmonary trunk anastomosis. (F) Neo-main pulmonary artery pericardial hood creation.

ative echocardiography revealed normal LV function (LV ejection fraction, 75%). No residual stenosis was found at either ventricular outflow tract, as well as no residual shunt in the ventricular septum, trace aortic regurgitation, and free pulmonary regurgitation. CT confirmed an appropriate correction of both great arteries and the outflow tract with no significant abnormalities in the coronary arteries (Fig. 2B). As of 6.5 years after the operation, the patient was still doing very well.

3) Operative techniques

The operation was performed through median sternotomy under CPB at moderate hypothermia. The pericardium was harvested for neopulmonary artery reconstruction. Aortic and bicaval cannulation was performed. After aortic cross-clamping, St. Thomas cardioplegic solution was infused into the aortic root and cold saline was administered for topical cooling to protect the myocardium. Immediately after the aortotomy at the level of the root purse string site, the coronary artery buttons were detached from the aorta. Subsequently, the main pulmonary artery (MPA) was dissected just above the pulmonary valve and the pulmonary valve was excised (Fig.

3B). The conal septum was resected and the Lecompte maneuver was performed (Fig. 3B, C). The aortic root was turned 180 degrees and was anastomosed to the neo-LVOT with 5-0 prolene. A Dacron patch was used to close the VSD. After the aortic root anastomosis, the coronary artery buttons were reimplanted to the aortic root (Fig. 3D). The posterior part of the MPA was anastomosed directly to the RVOT with 6-0 prolene (Fig. 3E). After the release of aortic cross-clamping, a glutaraldehyde-fixed pericardial patch was used to create a hood for the MPA anterior wall (Fig. 3F).

DISCUSSION

Due to anatomical variability and the poor results associated with existing procedures, the surgical management of TGA or DORV with VSD and PS remains a challenge. Therefore, several surgical techniques have been proposed.

The Rastelli procedure, introduced in 1969, includes closure of the VSD and creates an extra-anatomical pathway from the RV to the pulmonary artery by using a conduit. This procedure has been considered the gold standard to cor-

rect this type of anomaly. However, despite good early results, the Rastelli procedure has been reported to have disappointing results regarding late morbidity and mortality. In 2000, Kreutzer et al. [1] reported that the main causes of morbidity and mortality were conduit obstruction, LVOTO, and arrhythmia. Out of 94 survivors, 11 patients underwent surgical revision of LVOTO [1]. According to a recent study by Brown et al. [2], mortality associated with the Rastelli procedure has improved, with a Kaplan-Meier survival rate of 93% at five, 10, and 20 years. However, 18 patients (45%) underwent reoperation: 16 patients (40%) required a conduit change for RVOTO and two patients (5%) required reoperation for LVOTO [2].

The Réparation à l'Étage Ventriculaire (REV) procedure was introduced by Lecompte in 1980 [3]. Unlike the Rastelli procedure, the REV procedure attempts to reconstruct anatomic structures through resection of the conal septum and direct reimplantation of the pulmonary trunk. Although the early results were satisfactory, no reports were initially reported on the long-term results of the procedure. However, according to a recent study that reported long-term results of the procedure, 13 late deaths occurred in a sample of 171 patients whose long-term postoperative courses were monitored. Of this group of patients, 45% survived without reoperation. Thirty-six patients (33%) required reoperation due to RVOTO, and three (5%) needed reoperation due to LVOTO within the 25-year follow-up interval [3].

The Nikaidoh procedure, introduced in 1984, translocates the aortic root and main pulmonary artery, combining conal septum resection and the Lecompte maneuver, which were used to augment the REV procedure and obtain anatomically favorable results. This procedure has received attention as an alternative method of reducing the risk of LVOTO, which was the major problem posed by the previously existing procedure [4-6].

Subsequently, a modified procedure was introduced to avoid coronary artery kinking associated with the Nikaidoh procedure. This modified procedure incorporated coronary artery reimplantation. The mid- and long-term results of the modified procedure were reported to be better than those of other existing procedures [7,8].

The operative methods developed after the Rastelli proce-

cedure attempted to reconstruct a more stable structure between both ventricles and the great arteries. Most of these operation methods showed a lower rate of LVOTO than was associated with the Rastelli procedure, and these methods made it possible to create an anatomically favorable LVOT. However, the choice of the reconstruction method used to treat RVOT is still controversial. In order to prevent pulmonary insufficiency, which could occur after RVOT widening or valve resection, valved conduits and homografts have been used. According to a recent study on the Rastelli procedure, the percentages of patients who did not require reoperation for conduit change at five, 10, 15, and 20 years were 86%, 74%, 63%, and 59%, respectively [2].

Transannular RVOT reconstruction has the drawback of increasing the risk of RV failure by causing free pulmonary regurgitation. In an intermediate-term study of 32 patients who were operated on using the Nikaidoh procedure, 14 patients (44%) required reintervention for the RVOT. Thirteen of these 14 patients had a valved conduit and only one patient underwent transannular RVOT reconstruction [9]. Although the study period was relatively short, with a median follow-up period of 20.8 months, transannular patch RVOT reconstruction appeared to yield better results than valved conduits. However, transannular RVOT reconstruction has the risk of RV volume overload caused by free pulmonary insufficiency, as in transannularly repaired tetralogy of Fallot. Transannular patch reconstruction presents the possibility of pulmonary valve replacement to address free pulmonary regurgitation. However, reconstruction with a conduit may require a change of conduit relatively soon after the operation and require several operations for conduit stenosis.

Therefore, we performed the modified Nikaidoh procedure, including aortic root translocation, coronary reimplantation, and transannular RVOT reconstruction. We obtained a more anatomically normal LVOT from this modified procedure than would have been possible using previously developed procedures. No complications occurred, with the exception of free pulmonary regurgitation related to the modified procedure.

In conclusion, for patients diagnosed with DORV or TGA with VSD and PS, the Nikaidoh procedure is a good alternative to the Rastelli procedure. The transannular RVOT reconstruction method for reconstructing the RVOT requires a

long-term follow-up study to address pulmonary regurgitation and pulmonary valve replacement.

CONFLICT OF INTEREST

No potential conflict of interest relevant to this article was reported.

REFERENCES

1. Kreuzer C, De Vive J, Oppido G, et al. *Twenty-five-year experience with rastelli repair for transposition of the great arteries*. J Thorac Cardiovasc Surg 2000;120:211-23.
2. Brown JW, Ruzmetov M, Huynh D, Rodefeld MD, Turrentine MW, Fiore AC. *Rastelli operation for transposition of the great arteries with ventricular septal defect and pulmonary stenosis*. Ann Thorac Surg 2011;91:188-93.
3. Di Carlo D, Tomasco B, Cohen L, Vouhe P, Lecompte Y. *Long-term results of the REV (reparation a letage ventriculaire) operation*. J Thorac Cardiovasc Surg 2011;142:336-43.
4. Nikaidoh H. *Aortic translocation and biventricular outflow tract reconstruction: a new surgical repair for transposition of the great arteries associated with ventricular septal defect and pulmonary stenosis*. J Thorac Cardiovasc Surg 1984;88:365-72.
5. Jeong IS, Lee CH, Lee C, Lim HG, Kim IS, Youn HC. *Aortic translocation for complete transposition of the great arteries with a ventricular septal defect and pulmonic stenosis*. Korean J Thorac Cardiovasc Surg 2008;41:476-9.
6. Jeon JH, Seong YW, Kim WH, Chang HW, Chung ES, Kwak JG. *Modified Nikaidoh procedure for patient with TGA, restrictive VSD, and PS*. Korean J Thorac Cardiovasc Surg 2009;42:87-91.
7. Bautista-Hernandez V, Marx GR, Bacha EA, del Nido PJ. *Aortic root translocation plus arterial switch for transposition of the great arteries with left ventricular outflow tract obstruction: intermediate-term results*. J Am Coll Cardiol 2007;49:485-90.
8. Yeh T Jr, Ramaciotti C, Leonard SR, Roy L, Nikaidoh H. *The aortic translocation (Nikaidoh) procedure: midterm results superior to the Rastelli procedure*. J Thorac Cardiovasc Surg 2007;133:461-9.
9. Raju V, Myers PO, Quinonez LG, et al. *Aortic root translocation (Nikaidoh procedure): Intermediate follow-up and impact of conduit type*. J Thorac Cardiovasc Surg 2015;149:1349-55.