

Amiodarone-induced thyrotoxicosis in a pediatric patient: A rare and demanding clinical case

Sofia Oliveira,¹⁻⁴ Bernardo Marques,^{1,5} Sérgio Laranjo,⁶ Lurdes Lopes¹

¹Unit of Pediatric Endocrinology, Centro Hospitalar de Lisboa Central, Lisbon;

²Department of Endocrinology, Diabetes and Metabolism, Centro Hospitalar Universitário de São João, Porto;

³Faculty of Medicine, Universidade do Porto; ⁴Instituto de Investigação e Inovação em Saúde, Universidade do Porto;

⁵Department of Endocrinology, Instituto Português de Oncologia de Coimbra Francisco Gentil, Coimbra;

⁶Department of Pediatric Cardiology, Centro Hospitalar de Lisboa Central, Lisbon, Portugal

Abstract

Thyroid dysfunction is one of the most common adverse effects of amiodarone therapy, ranging from subclinical changes to overt clinical thyrotoxicosis (AIT) and/or hypothyroidism. Due to its heterogeneity, AIT lasts as a defiant entity, leading to a thorny treatment course, particularly in pediatrics. AIT can be classified as either type 1, type 2 or mixed form based on its pathophysiology. Differentiating between the main AIT subtypes is quite relevant, since there is specific treatment for both, however, this distinction may be difficult in clinical practice. We describe a rare case of AIT in a pediatric patient, with an uncommon congenital cardiac malformation, that started amiodarone therapy due to paroxysmal supraventricular tachycardia. AIT was reported 26 months after drug onset, with a sudden and explosive emerging. This case highlights the current AIT management challenges on the high-demanding pediatric field pursuing, ultimately, an enhanced patient's care.

Introduction

Amiodarone has emerged as the leading antiarrhythmic therapy for the management of ventricular and supraventricular tachyarrhythmias, being widely used in different clinical settings due to its proven efficacy and safety.¹⁻⁴ As a class III

antiarrhythmic agent according to the Vaughan-Williams classification, amiodarone blocks myocardial potassium channels though it also has some β -blocking properties.^{5,6} Moreover, it has a structurally significant resemblance to thyroid hormones owning two iodine atoms, which represents 37% of its weight.^{5,6} Thereby, standard maintenance therapy with 200 mg/daily can afford for more than 100-fold the daily iodine requirement.² Total body iodine stores remain increased for up to 9 months after drug discontinuation, in face of a highly variable half-life, from 50 to 100 days.² Thus, amiodarone toxicity can persist or even occur after drug withdrawal.¹⁻⁵

Actually, thyroid dysfunction is one of the most common side effects of amiodarone therapy (iodine-induced or drug-intrinsic), reported to affect about 15-20% of this users, ranging from subclinical changes to overt clinical thyrotoxicosis (AIT) and/or hypothyroidism (AIH).¹ Studies in adults point toward a prevalence of AIH that may reach 26% and 5%, in its subclinical and overt forms, respectively, whereas AIT varies from 3-5% or 10-12% in iodine sufficient or deficient regions, respectively.^{1,7} However, epidemiological evidence in pediatric patients is far more restricted. Actually, few studies estimate an overall AIH prevalence of about 2-20% in children.^{8,9} In respect to AIT, one single study has been reported to date in which just 2.1% of the cohort developed this condition, while 33% were found to have thyroid dysfunction.⁸

Despite the relatively easy AIH management, the development of AIT heads to a difficult approach for most cases, being recognized as an arduous diagnostic and management challenge, at times leading to life-threatening complications.¹⁰

AIT can be classified as type 1, type 2 or mixed-form based on its pathophysiology.¹⁻⁴ Type 1 AIT is a form of iodine-induced hyperthyroidism, more common in iodine-deficient areas and usually appears in patients with latent or preexisting thyroid abnormalities, due to increased thyroid hormone synthesis.¹⁻⁴ On the other hand, type 2 AIT is a drug-induced form secondary to a destructive thyroiditis, leading to uncontrolled release of pre-formed thyroid hormones, that occurs in individuals with no underlying thyroid disease, being more frequent in iodine sufficient areas.¹⁻⁴ In the mixed form, both mechanisms may be present, as it encompasses several features of both type 1 and 2.¹⁻⁴ Noteworthy, type 1 AIT tends to arise early after amiodarone treatment is started (median 3.5 months), whereas type 2 AIT occurs much later

Correspondence: Sofia Castro Oliveira, Serviço de Endocrinologia, Diabetes e Metabolismo, Centro Hospitalar Universitário de São João (CHSJ), Alameda Prof. Hernâni Monteiro, 4200-319 Porto, Portugal.
Tel.: +351912310633.
E-mail: sofiaastro.oliveira@gmail.com

Key words: thyrotoxicosis, amiodarone, adolescence.

Contributions: the authors contributed equally.

Conflict of interest: the authors declare no potential conflict of interest.

Funding: none.

Acknowledgments: thanks are due to Associação dos Amigos do Serviço de Endocrinologia do Hospital de São João, Porto, Portugal.

Received for publication: 3 May 2019.

Revision received: 30 July 2019.

Accepted for publication: 31 July 2019.

This work is licensed under a Creative Commons Attribution NonCommercial 4.0 License (CC BY-NC 4.0).

©Copyright: the Author(s), 2019
Licensee PAGEPress, Italy
Pediatric Reports 2019; 11:8166
doi:10.4081/pr.2019.8166

(median 30 months).⁷ Recent reports have pointed out that type 2 AIT is more prevalent than type 1 AIT, for most countries.⁷

Clinically, it is crucial to differentiate between these subtypes in order to guide therapy. First-line treatment for type 1 AIT consists in antithyroid drugs (methimazole or propylthiouracil), often along with potassium perchlorate.¹⁻⁴ Otherwise, type 2 AIT is best treated with glucocorticoids (prednisone).¹⁻⁴ In cases of mixed AIT, combination therapy may be required. Radioactive iodine (RAI) is usually not feasible in AIT due to the low RAI uptake values. Thyroidectomy represents a valid option in cases of resistance to medical therapy.¹⁻⁴

Distinguishing between AIT subtypes can be arduous, leading to a thorny treatment course, particularly in children and adolescents, where an early identification and treatment of thyroid dysfunction is critical to optimize growth and neurocognitive development, as well as in cardiac disease.¹¹ Hereby, we describe a rare case of AIT in a pediatric patient which highlights these challenges.

Case Report

A 16-year-old boy with past medical history of type 1 *truncus arteriosus*, a very rare congenital cardiac malformation, and moderate-to-severe tricuspid insufficiency, who underwent several corrective surgical interventions (the last one in 2014), started amiodarone (200 mg/day) therapy in August 2015 due to paroxysmal supraventricular tachycardia. He was referred to Pediatric Endocrinology in October 2017 for thyroid dysfunction compatible with thyrotoxicosis; he had no personal or family history of thyroid disease and prior thyroid tests proved to be normal.

He complained of a more intense feeling of palpitations, fatigue and had a weight loss of 4kg in the previous 3 months (baseline height and weight: 167cm and 59.8kg, respectively) yet he denied heat intolerance, diarrhea or other symptoms; physical examination showed no relevant changes other than the known holosystolic murmur, loudest at the base. Laboratory assessment revealed: serum thyroid-stimulating hormone (TSH) <0.01 uUI/mL [reference values (RV): 0.47-3.41 uUI/mL]; serum free thyroxine (FT4) 2.83 ng/dL (RV: 0.89-1.37 ng/dL); serum free triiodothyronine (FT3) 7.92 pg/mL (RV: 2.25-3.85 pg/mL); negative antithyroid antibodies [thyroid peroxidase antibodies (TPOAb) <1.0 UI/mL (RV: <5.61 UI/mL), thyroglobulin antibodies (TgAb) <1.0 UI/mL (RV: <4.11 UI/mL) and negative TSH receptor antibodies (TRAb) (<1.0 UI/L)]. Thyroid function was reassessed at the moment of our evaluation (4 days later), which was found to be deteriorated as serum FT3 notably reached 19.76 pg/mL and serum FT4 3.61 ng/dL; serum TSH levels remained undetectable and thyroid autoimmunity negative. The thyroid ultrasound was normal: thyroid with globally hypoechoic texture, with no solid nodules, no increase in vascularization and no latero-cervical adenopathies (Figure 1).

The distinction between the two main AIT types could not be made clinically. Considering the potential iatrogenic effect of corticosteroid therapy on this adolescent heart disease, treatment has been promptly started with thiamazole 15 mg/day (0.25 mg/kg/day). In face of no significant improvement in thyroid function and slight changes in hepatic enzymes during the first couple of weeks, with alanine transaminase (ALT) elevation even attaining > 3-fold upper limit of normal (ULN), it was decided to replace amiodarone by sotalol 160 mg/day (in-hospital replacement on Pediatric Cardiology Department), maintaining a strict monitoring of thiamazole hepatotoxicity,

without prompt dose increase. The patient kept fair control of both heart rhythm and rate. Thyroid hormone levels had then gradually improved (TSH 0.02 UI/mL, FT4 0.78 ng/dL, FT3 2.83 pg/mL) (Table 1), as well as liver enzymes. After 4 months of starting thiamazole the patient had gained 5kg, presenting sustained clinical and analytical enhance. Thiamazole dose was gradually decreased afterwards and treatment was completely discontinued 1.5 months later. The patient remained asymptomatic thereafter.

Discussion

AIT represents a harmful and critical condition for patients with underlying cardiac abnormalities, heading to an increased mortality.¹⁻⁵ Further, is of paramount importance an early diagnosis and treatment of thyroid dysfunction in youth in order to promote proper growth and neurocognitive development.¹¹ Thus,

physicians must be aware of this entity at pediatric-ages and how to manage a case where there is ambiguity between the different AIT forms.

We describe a rare case of AIT in a pediatric patient, with an uncommon congenital cardiac malformation, that had started amiodarone therapy due to paroxysmal supraventricular tachycardia.

The accurate underlying mechanism of amiodarone effects on thyroid function is complex and multifactorial yet still remains to be fully unveiled.¹⁻⁵ Given the small number of pediatric patients and the lack of controlled studies, only scarce data can be found in the literature regarding the pathophysiology particularities and outcome of amiodarone-associated thyroid disorders in childhood and adolescence.

Amiodarone has pharmacological properties enabling thyrotoxicosis, with structural resemblance to thyroxine and a high iodine content.² Due to its lipophilic character, is concentrated in adipose tissue, cardiac and skeletal muscle, and the thyroid. In effect, its elimination from the body

Table 1. Biochemical follow-up.

Parameter	27/02/2018	18/04/2018*	02/05/2018
TSH (0.47-3.41 uUI/mL)	0.02	22.10	6.34
FT4 (0.89-1.37 ng/dL)	0.78	0.51	0.90
FT3 (2.25-3.85 pg/mL)	2.83	2.62	3.54

*Suspension of thiamazole. TSH: thyroid-stimulating hormone; FT3: free triiodothyronine; FT4: free thyroxine.

Table 2. Differences between type 1 and 2 amiodarone-induced thyrotoxicosis.

	Type 1	Type 2
Underlying thyroid disease	Yes (Multinodular goiter, Grave's)	No
Time after amiodarone onset	Short (median 3.5 months)	Long (median 30 months)
T4/T3 ratio	Decreased	Increased
TgAb/TPOAb/TRAb	May be present	Usually absent
Serum IL-6	Normal or slightly elevated	Frequently markedly elevated
Vascularity on echo-color Doppler ultrasound	Increased	Absent
24-hour iodine uptake	Normal or Increased	Low or Absent

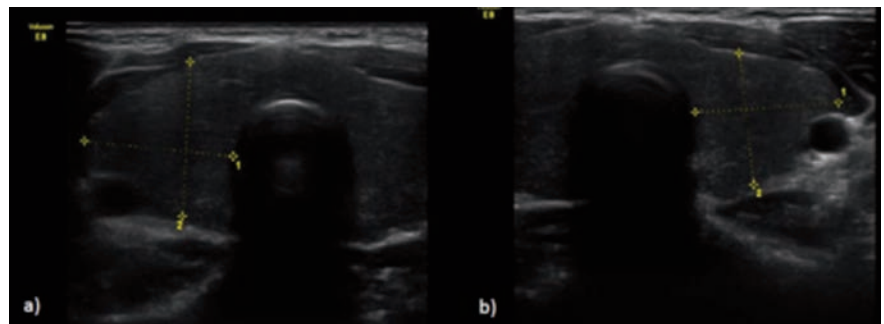


Figure 1. Thyroid ultrasound (24/10/2017): thyroid with globally hypoechoic texture, with no solid nodules; no increase in vascularization; no latero-cervical adenopathies. a) Thyroid right lobe; b) Thyroid left lobe.

occurs with a half-life from 50 to 100 days.² This drug inhibits type 1 5 α -deiodinase enzyme activity, thus decreasing the peripheral conversion of T4 to T3 and reducing the clearance of both T4 and reverse T3.² Furthermore, amiodarone and its metabolites may also have a direct cytotoxic effect on the thyroid follicular cells, which results in a destructive thyroiditis.²

Differentiating between the main AIT subtypes is quite relevant, since there is specific treatment for both, however, this distinction may be difficult in clinical practice.¹² Indeed, due to its heterogeneity, AIT poses a difficult diagnosis and therapeutic challenge. In many patients neither the clinical findings nor the response to treatment clearly indicates which AIT type we are dealing with, and some cases may in fact represent mixed-forms, with features of both.¹² The distinction between the two main types is based on several factors, described in Table 2. Notably, none of the proposed methods is able to distinguish these two types by itself, requiring the combination of different techniques.¹²

In our case, AIT was reported 26 months after amiodarone onset, with a sudden and explosive emerging, in a patient with no underlying thyroid disease. The absence of thyroid antibodies and normal ultrasound, with no solid nodules or increase in vascularization, suggested type 2 AIT. However, considering that in AIT serum FT3 levels may not be as elevated as expected, since amiodarone inhibits FT4 to FT3 conversion, it's quite striking that, for this patient, the increase in serum FT3 levels were significantly higher than FT4 levels, pointing towards type 1 AIT. Serum Interleukin-6 (IL-6) was not available, as well as 24h-RAI uptake, not performed also considering the patient's pediatric-age and we were unable to accomplish an accurate distinction between the two types of AIT clinically. Recently, thyroid (^{99m}Tc)²-methoxyisobutyl-isonitrile (MIBI) scintigraphy has been assessed as a useful diagnostic tool in a small study, albeit it doesn't offers a uniform consistency.⁷ As a result, the true effectiveness of this expensive procedure needs to be confirmed by larger studies.⁷

In face of the potential iatrogenic effect of corticosteroid therapy on this pediatric patient, with a severe and rare baseline heart disease, it was decided to promptly start treatment with thiamazole 15mg/day (0.25mg/kg/day), monitoring clinical evolution and response to therapy. In fact, corticosteroid therapy shouldn't be separated from its metabolic and cardiovascular effects, particularly in childhood and adolescence and, thus, the risk-benefit ratio had to be weighed in this particular case. Actually, pediatric patients are more vulnerable to the adverse effects of these

potent drugs, namely effects on growth, immunity, adrenal suppression.¹³ Noteworthy, it is also known that fluid and electrolyte problems may be more dangerous in patients with associated cardiac illness and arrhythmias, which was the case of our patient and, thereby, glucocorticoids were avoided due to their potential toxic effects.¹³

Since an iodine-replete thyroid gland is less responsive to the inhibitory action of thionamides, one must bear in mind that higher drug doses and longer periods of therapy may be required before euthyroidism is restored.⁷ In fact, no significant improvement was observed during the first couple of weeks and, moreover, a slight increase of liver enzymes was noted, with ALT elevation even attaining > 3-fold ULN. The documented thiamazole hepatotoxicity represented a rare adverse effect, confining the dose titration and the patient was, therefore, kept in a strict monitoring. Together with Pediatric Cardiology, we opted to replace amiodarone by sotalol 160mg/day under in-hospital regimen, preserving good control of both heart rhythm and rate. Actually, the decision to stop, or not, amiodarone is one of the most controversial treatment options, being widely non-consensual.^{1,5} If feasible from the cardiologist standpoint, it's probably safer to withdraw amiodarone and use a different anti-arrhythmic drug, though no controlled trials have been published regarding this issue.⁷

A sustained clinical and analytical improvement was observed afterwards, nevertheless, therapy with thiamazole had to be continued due to the long amiodarone half-life. After several months it was possible to initiate drug weaning and subsequent withdrawal, remaining the patient asymptomatic thereafter. It's also noteworthy to take into account the long-term effects of thionamides and steroids. Therefore, once the patient's symptoms are stable, the decision regarding tapering down or stopping these drugs may rest a priority, in order to avoid possible sequelae, mainly in pediatric-ages.

Conclusions

Amiodarone-associated thyroid dysfunction is usually a mild clinical condition, however, AIT can be severe, life-threatening and even lethal. Thus, its prognosis emphasizes the need for careful monitoring of patients receiving amiodarone treatment, with an accurate evaluation prior and during the pharmacological therapy. In Pediatrics, AIT still remains a huge diagnostic and therapeutic challenge for the physician. A proper identification of the different subtypes may be

difficult and often imprecise, hampering a directed therapeutic approach. Hence, AIT should be ideally managed in cooperation by a cardiologist and an endocrinologist pursuing, ultimately, an enhanced patient's care.

References

1. Bartalena L, Bogazzi F, Chiovato L, et al. European Thyroid Association (ETA) Guidelines for the Management of Amiodarone-Associated Thyroid Dysfunction. *Eur Thyroid J* 2018;7:55-66.
2. Gopalan M, Burks J. Thyroid Dysfunction Induced by Amiodarone Therapy: Background, Pathophysiology, Epidemiology. *Medscape* 2018 (Updated: Oct 08, 2018).
3. Bogazzi F, Bartalena L, Martino E. Approach to the patient with amiodarone-induced thyrotoxicosis. *J Clin Endocrinol Metab* 2010;95:2529-35.
4. Eskes SA, Wiersinga WM. Amiodarone and thyroid. *Best Pract Res Clin Endocrinol Metab* 2009;23:735-51.
5. Cohen-Lehman J, Dahl P, Danzi S, Klein I. Effects of amiodarone therapy on thyroid function. *Nat Rev Endocrinol* 2010;6:34-41.
6. Narayana SK, Woods DR, Boos CJ. Management of amiodarone-related thyroid problems. *Ther Adv Endocrinol Metab* 2011;2:115-26.
7. Macchia PE, Feingold KR. Amiodarone Induced Thyrotoxicosis. *Endotext* 2018
8. Barrett B, Hawkes CP, Isaza A, Bauer AJ. The effects of amiodarone on thyroid function in pediatric and young adult patients. *JCEM* 2019 [Ahead of print].
9. Creo A, Anderson H, Cannon B, et al. Patterns of amiodarone-induced thyroid dysfunction in infants and children. *Heart Rhythm* 2019 [Ahead of print].
10. Kotwal A, Clark J, Lyden M, et al. Thyroidectomy for Amiodarone-Induced Thyrotoxicosis: Mayo Clinic Experience. *J Endocr Soc* 2018;2:1226-35.
11. Hanley P, Lord K, Bauer AJ. Thyroid Disorders in Children and Adolescents. *JAMA Pediatr* 2016;170:1008-19.
12. Tomisti L, Rossi G, Bartalena L, et al. The onset time of amiodarone-induced thyrotoxicosis (AIT) depends on AIT type. *Eur J Endocrinol* 2014;171:363-8.
13. Deshmukh CT. Minimizing side effects of systemic corticosteroids in children. *Indian J Dermatol Venereol Leprol* 2007;73:218-21.