

Acute nephrotic-range glomerular proteinuria following ibuprofen intoxication in two cats

Yaiza Herrero¹, Claudia Iannucci¹, Nora Schreiber², Bernard D Hansen³ and Alessio Vigani¹

Journal of Feline Medicine and Surgery Open Reports
1–5

© The Author(s) 2022

Article reuse guidelines:

sagepub.com/journals-permissions

DOI: 10.1177/20551169221104551

journals.sagepub.com/home/jfmsopenreports

This paper was handled and processed by the European Editorial Office (ISFM) for publication in *JFMS Open Reports*



Abstract

Case series summary In this report we describe the origin of protein loss and development of acute kidney injury after ibuprofen intoxication in two cats. Two 13-month-old neutered male domestic shorthair siblings were presented with acute kidney injury (AKI) and severe glomerular proteinuria following witnessed ibuprofen intoxication 3 days prior. Both cats presented with severe azotaemia (creatinine >900 µmol/l [>10 mg/dl]) and severe proteinuria (urine protein:creatinine [UPC] >20, normal <0.5). Urine protein electrophoresis upon presentation revealed mainly albumin and primary glomerular protein losses. The proteinuria and azotaemia resolved completely within 5 days of hospital treatment (8 days after ingestion). Urine protein electrophoresis, once the azotaemia and proteinuria resolved (UPC 0.11; normal <0.5), had a similar pattern to the one from admission. Both cats made a full recovery with supportive care.

Relevance and novel information This is the first clinical report of AKI with nephrotic-range protein losses following ibuprofen intoxication in cats. We propose that this finding is due to idiosyncratic glomerular injury, as described in humans.

Keywords: ibuprofen; proteinuria; toxicity; nephrotic

Accepted: 15 May 2022

Introduction

Accidental ingestion of non-steroidal anti-inflammatory drugs (NSAIDs) is common and accounts for more than 3% of all reports of intoxications in small animals reported to the American Society for the Prevention of Cruelty to Animals Animal Poison Control Center.¹ Moreover, NSAIDs are among the most common intoxications associated with acute kidney injury (AKI) in small animals.²

Compared with other NSAIDs there is limited information on the pharmacokinetic and toxicological profile of ibuprofen in cats, but it has been suggested that they are supposedly more sensitive to toxicity than dogs owing to their limited hepatic metabolic capacity.^{3,4} Doses as low as 50 mg/kg (110 mg/lbs) have been reported to cause severe clinical signs, including AKI and death.⁵

In human medicine, two forms of AKI secondary to NSAID toxicity have been described. The first form develops in conditions of haemodynamic instability and typically presents with acute tubular necrosis and

interstitial nephritis. The second form is associated with acute glomerular injury and nephrotic-range proteinuria.^{6–8}

Clinical reports in the small animal literature describe NSAID-induced AKI as a form of acute nephritis with findings suggestive of acute tubular necrosis.⁹ No cases of NSAID toxicity with acute glomerular injury and

¹Division of Emergency and Critical Care, Department of Small Animals, University of Zurich, Zurich, Switzerland

²Division of Cardiology, Clinic for Small Animal Medicine, University of Zurich, Zurich, Switzerland

³Department of Clinical Sciences, North Carolina State University College of Veterinary Medicine, Raleigh, NC, USA

Corresponding author:

Alessio Vigani DVM, PhD, DACVAA, DACVECC, DECVECC, Division of Emergency and Critical Care, Department of Small Animals, Vetsuisse Faculty, University of Zurich, Winterthurerstrasse 260, Zurich CH-8057, Switzerland
Email: alessio.vigani@uzh.ch



Creative Commons Non Commercial CC BY-NC: This article is distributed under the terms of the Creative Commons

Attribution-NonCommercial 4.0 License (<https://creativecommons.org/licenses/by-nc/4.0/>) which permits non-commercial use, reproduction and distribution of the work without further permission provided the original work is attributed as specified on the SAGE and Open Access pages (<https://us.sagepub.com/en-us/nam/open-access-at-sage>).

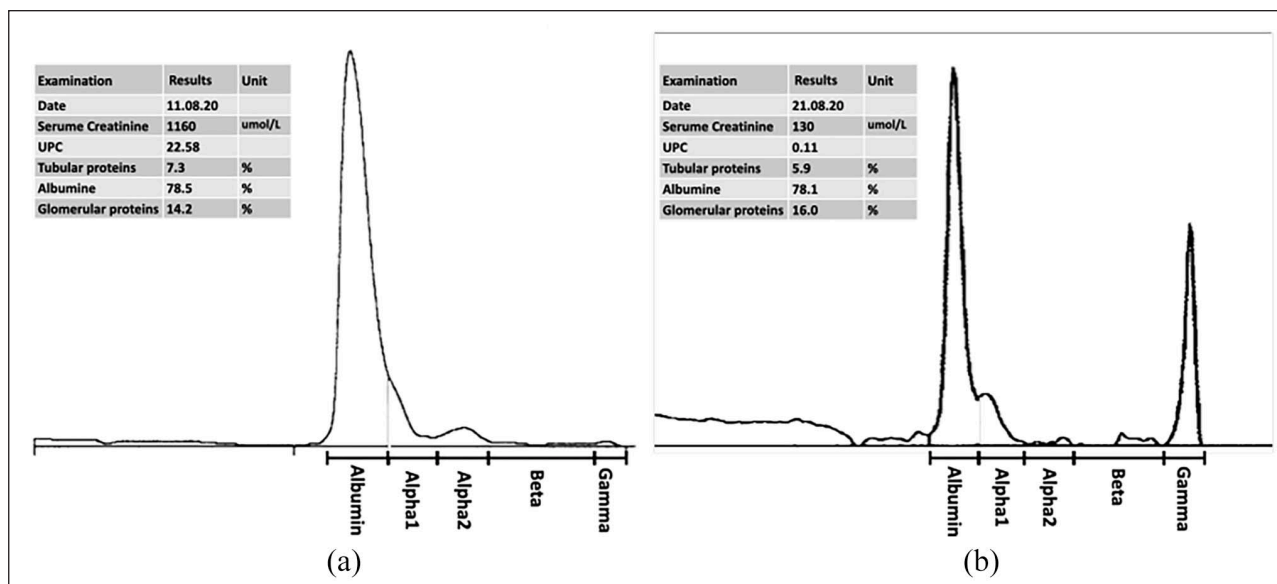


Figure 1 Urine protein electrophoresis plots in cat 1 performed (a) 3 days and (b) 13 days after ibuprofen ingestion. The respective legends report serum creatinine, urine protein:creatinine (UPC) and the fractional percentage of proteins in the urine (albumin; tubular proteins; glomerular proteins). The electrophoresis plots show the albumin band, glomerular proteins (alpha1 band), tubular proteins (alpha2 and beta bands) and gamma globulins. Notably, although both plots display a similarly large fraction of albumin and glomerular proteins (alpha 1 band) present in the urine, the UPC in (a) is 22.58, suggesting significant protein loss, whereas the UPC in (b) is only 0.11, which indicates physiological protein loss. The gamma band present in (b) is also considered a physiological trace gamma-globulin loss when associated with a normal UPC.

glomerular proteinuria have been described in small animals. This case series documents the occurrence and time course of nephrotic-range glomerular proteinuria associated with severe AKI secondary to ibuprofen intoxication in two cats.

Case series description

Two 13-month-old neutered male domestic shorthair littermates weighing 5.4 kg (cat 1; 11 lbs) and 5.9 kg (cat 2; 13 lbs) were referred to the Small Animal Hospital of the Vetsuisse Faculty of Zurich for evaluation of acute vomiting and anorexia. The owner confirmed accidental ingestion of an unknown amount of 400 mg ibuprofen tablets 3 days prior. The day after ingestion, the cats had been treated for vomiting with maropitant by the primary veterinarian. No other therapy was prescribed, and the gastrointestinal signs persisted for 2 more days before being presented to the Small Animal Hospital of the Vetsuisse Faculty of Zurich. Neither cat had previous significant medical history.

Upon presentation, cat 1 was lethargic, with pale and dry mucous membranes. The remainder of the physical examination, including oscillometric blood pressure measurements, was normal. Cat 2 was bright, alert and responsive, with a normal physical examination and normal non-invasive blood pressure measurement.

The results of the serum biochemical analyses in cat 1 revealed severe azotaemia, with a blood urea

nitrogen (BUN) of 80.3 mmol/l (225 mg/dl), creatinine of 1084 µmol/l (12 mg/dl) and hyperphosphataemia of 5.6 mmol/l (17 mg/dl) (Figure 1). Additionally, cat 1 had increased serum liver enzyme concentrations (alanine aminotransferase 167 U/l, gamma-glutamyl transferase 5.4 U/l, aspartate aminotransferase 117 U/l, glutamate dehydrogenase activity 38.6 U/l).

Cat 2 presented with azotaemia, with a BUN of 45.1 mmol/l (126 mg/dl), creatinine of 853 µmol/l (10 mg/dl), and hyperphosphatemia of 5.0 mmol/l (16 mg/dl) (Figure 2).

Urinalysis revealed cytologically inactive urine sediment in both cats, decreased urine specific gravity (USG; 1.020) in both cats, and severe proteinuria with a urine:protein creatinine ratio (UPC) of 22.58 in cat 1 (Figure 1a), and 24.92 in cat 2 (Figure 2a). Urine output was normal in both cats.

Protein electrophoresis of the urine samples revealed severe glomerular protein loss (cat 1: albumin 78.5%, glomerular protein 14.2%, tubular protein 7.3% [Figure 1a]; cat 2: albumin 60.1%, glomerular protein 33.8%, tubular protein 6.1% [Figure 2a]).

Abdominal ultrasound findings were consistent with an acute bilateral nephropathy with renomegaly, perirenal inflammation and loss of corticomedullary distinction. Urethral obstruction was excluded in both cats.

Both cats were treated with antiemetics (maropitant 1 mg/kg [2.2 mg/lb] q24h IV; ondansetron (0.5 mg/kg

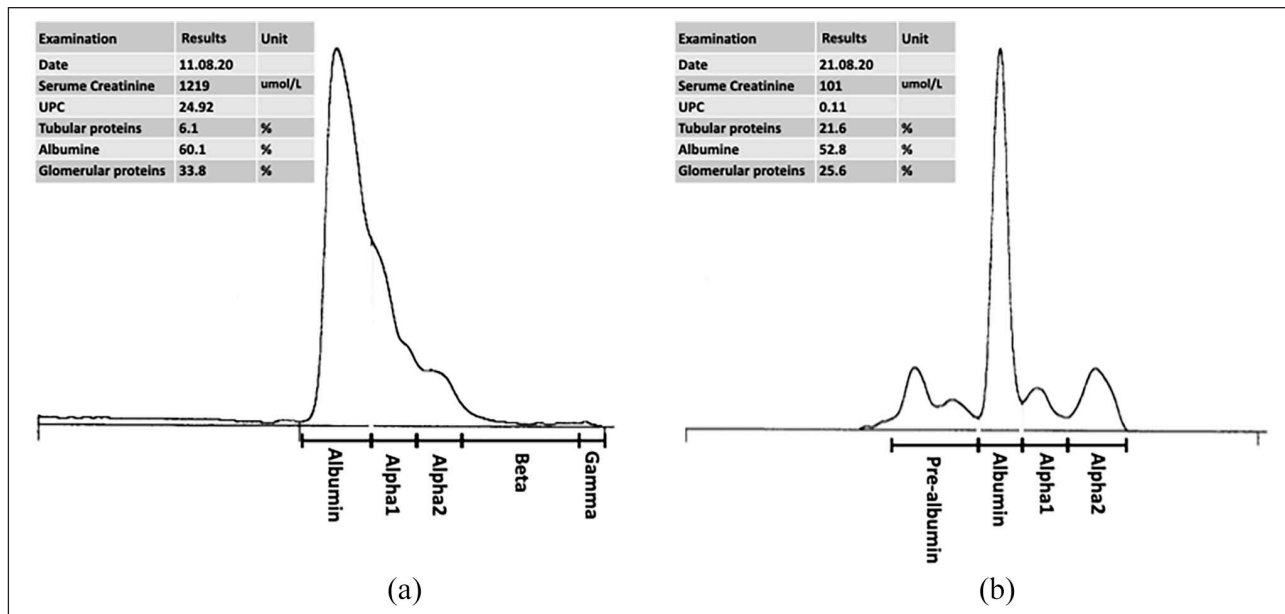


Figure 2 Urine protein electrophoresis plots in cat 2 performed (a) 3 days and (b) 13 days after ibuprofen ingestion. The respective legends report serum creatinine, urine protein:creatinine (UPC) and the fractional percentage of proteins in the urine (albumin; tubular proteins; glomerular proteins). The electrophoresis plots show the albumin peak, glomerular proteins (alpha1 band), tubular proteins (alpha2 and beta bands) and gamma globulins. While both plots display a similarly large fraction of albumin and glomerular proteins (alpha 1 band) present in the urine, the UPC in (a) is 24.92, suggesting a significant urinary protein loss, whereas the UPC in (b) is 0.11, which indicates a physiological protein loss. Plot (b) shows a pre-albumin band that is considered physiological when associated with a normal UPC

[1.1 mg/lb] q8h IV), omeprazole (1 mg/kg [2.2 mg/lb] q12h IV), buprenorphine (10 µg/kg [22 µg/lb] q6h IV) and intravenous fluids (Ringer's acetate, 3 ml/kg/h [6.6 ml/lb/h]). During hospitalisation, urine output, fluid gain/deficit and vital parameters were closely monitored.

On the following day (hospital day 2, 5 days after ingestion) the azotaemia worsened despite fluid therapy and normal cardiovascular function in both cats (cat 1: creatinine 1160 µmol/l [13 mg/dl]; cat 2: creatinine 1219 µmol/l [14 mg/dl]).

Clinically, cat 1 continued to be quiet and anorectic. Cat 2 remained stable, active and responsive. On hospital day 3 (6 days after ingestion) serum creatinine improved in both cats (cat 1: 716 µmol/l [8 mg/dl]; cat 2: 652 µmol/l [7 mg/dl]) and the clinical condition of cat 1 also improved. On day 5 (8 days after ingestion) serum creatinine was only mildly elevated in cat 1 (214 µmol/l [2 mg/dl]) and was within normal limits in cat 2 (147 µmol/l [2 mg/dl]) (Figure 3).

Bacteriology results from urine samples collected at presentation were negative in both cats.

The azotaemia persisted until day 7 (10 days after ingestion) in cat 1, when the serum creatinine returned within normal limits (145 µmol/l [2 mg/dl]). Both cats were then discharged in normal clinical condition with

normal appetite and serum creatinine concentration (Figure 3).

On recheck, 11 days after the initial presentation (14 days after ingestion), both cats were still clinically normal and the serum creatinine concentration was within normal limits for both cats. Urinalysis revealed a cytologically inactive urine sediment, persistent low USG (cat 1: 1.020; cat 2: 1.029) and completely resolved proteinuria (UPC cat 1: 0.11; UPC cat 2: 0.11) in both cats. Protein electrophoresis of the urine samples revealed a normal protein excretion pattern (cat 1: albumin 78.1%, glomerular protein 16%, tubular protein 5.9% [Figure 1b]; cat 2: albumin 52.8%, glomerular protein 25.6%, tubular protein 21.6% [Figure 2b]). Both cats remained clinically normal at a follow-up evaluation 12 months after intoxication.

Discussion

This is the first report of nephrotic-range proteinuria with severe AKI due to NSAID toxicity in cats, with features and a time course similar to the form of glomerular injury caused by NSAIDs in humans.

Two main forms of renal injury with an acute reduction in glomerular filtration rate and development of azotaemia secondary to NSAID toxicity have been described in human medicine.⁶

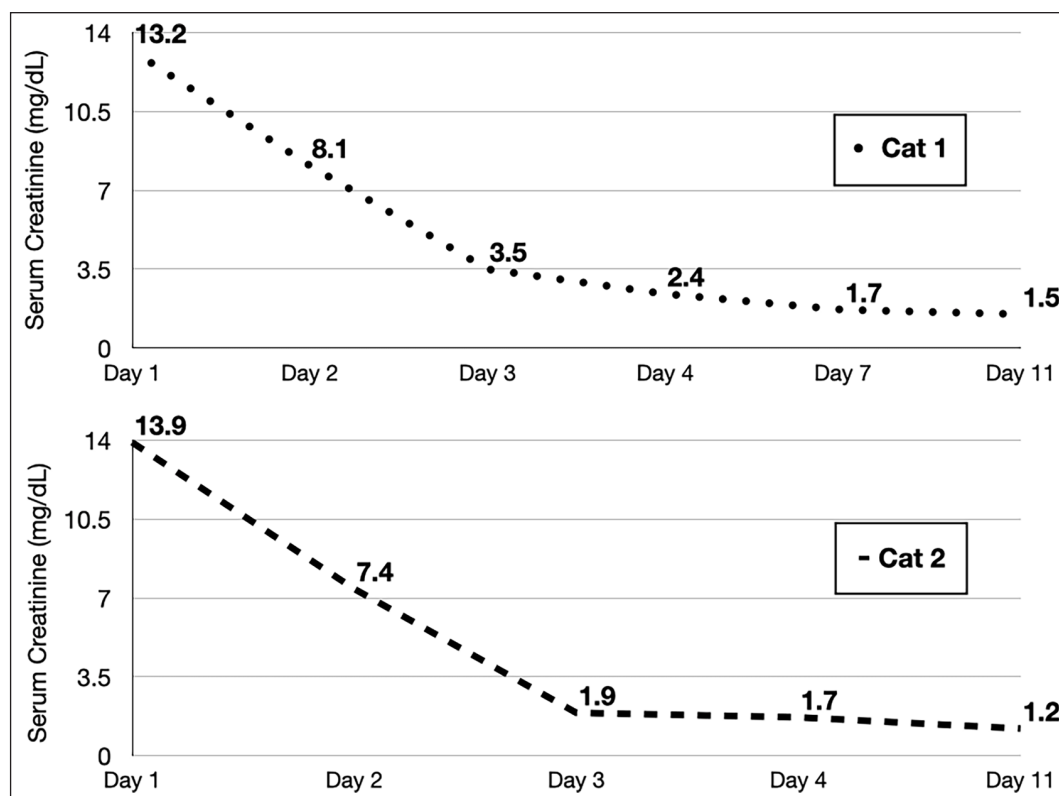


Figure 3 Progression of serum creatinine values in cat 1 and cat 2 following ibuprofen ingestion. Day 1 indicates the day of presentation to the hospital, which was 3 days after the ingestion of ibuprofen

The most common form develops under conditions of haemodynamic instability or volume depletion concurrent to the administration of an NSAID. Under these circumstances, the dose-dependent inhibition of renal prostaglandin synthesis by NSAIDs limits autoregulation of blood flow and GFR. In severe circumstances, this induces renal hypoperfusion and ischaemia, with associated acute tubular necrosis. Urinalysis routinely reveals shed tubular cells and the presence of casts, indicating tubular injury. This form of AKI is not associated with glomerular damage or increased glomerular protein loss.⁶ In small animals, this is the form of AKI caused by NSAIDs commonly described following overdose or prolonged administration.¹⁰

The alternative form, described in humans, is NSAID-induced nephropathy, with glomerular injury in the form of membranous nephropathy or minimal change glomerulonephritis. In 80% of these cases nephrotic syndrome with significant glomerular proteinuria is found concurrently with AKI.¹¹ The exact pathophysiological mechanisms have not yet been proven but have been attributed to a dose-independent idiosyncratic hypersensitivity reaction to NSAIDs. The typical time course of full recovery occurs within 1 week to 6 months.^{6,8} The nephrotic-range glomerular proteinuria found in this form in humans has been attributed to direct damage to the slit diaphragm with fusion of epithelial

foot processes through an acute immune-mediated reaction.^{12,13} This form of NSAID toxicity has never been described in small animals.

The cats described in this report developed severe, fluid-unresponsive AKI 3 days after confirmed ingestion of ibuprofen. The actual dose ingested was not determined and only parts of 400 mg tablets were missing, making it unlikely that either cat was exposed to a massive overdose. Severe nephrotic-range proteinuria, in the absence of active urine sediment, was found in both patients, raising suspicion for the presence of direct glomerular damage. The urine protein electrophoretic analysis confirmed the glomerular origin of the protein loss, with increased albumin and glomerular protein percentages in both cats (Figures 1 and 2). The AKI and proteinuria resolved concurrently, without specific treatment, within 11 days in both cats (Figure 3). The short time course to resolution of the glomerular proteinuria and AKI seen in these cats is compatible with that described in human patients developing NSAID-associated glomerular injury. Interestingly, this type of renal injury in humans often occurs at therapeutic doses of NSAIDs, further highlighting its dose-independent nature.^{7,8,14}

Notably, there is often no clear-cut demarcation in humans between the two forms of NSAID renal toxicity and evidence of tubular necrosis and glomerular

injury may be found in the same patient.¹² Given the short time course of AKI and complete resolution of proteinuria in both cats, no histopathology was performed to confirm glomerular damage. Moreover, the quantification of plasma ibuprofen concentration was not possible owing to the delayed presentation 3 days after ingesting the drug.

Conclusions

Our case series suggests that direct glomerular injury secondary to NSAID toxicity is possible in cats, and that the possibility of NSAID intoxication as a differential diagnosis in cats presenting with AKI and nephrotic-range proteinuria with an inactive urine sediment might be considered. This type of renal injury may occur in a dose-independent fashion, possibly at much lower doses than those previously reported as nephrotoxic in cats.

Conflict of interest The authors declared no potential conflicts of interest with respect to the research, authorship, and/or publication of this article.

Funding The authors received no financial support for the research, authorship, and/or publication of this article.

Ethical approval The work described in this manuscript involved the use of non-experimental (owned or unowned) animals. Established internationally recognised high standards ('best practice') of veterinary clinical care for the individual patient were always followed and/or this work involved the use of cadavers. Ethical approval from a committee was therefore not specifically required for publication in *JFMS Open Reports*. Although not required, where ethical approval was still obtained it is stated in the manuscript.

Informed consent Informed consent (verbal or written) was obtained from the owner or legal custodian of all animal(s) described in this work experimental or non-experimental animals, including cadavers) for all procedure(s) undertaken (prospective or retrospective studies). For any animals individually identifiable within this publication, informed consent (verbal or written) for their use in the publication was obtained from the people involved

ORCID iD Alessio Vigani  <https://orcid.org/0000-0002-8415-6576>

References

- 1 Khan SA and McLean MK. **Toxicology of frequently encountered nonsteroidal anti-inflammatory drugs in dogs and cats.** *Vet Clin North Am Small Anim Pract* 2012; 42: 289–306.
- 2 Mugford A, Li R and Humm K. **Acute kidney injury in dogs and cats 1. Pathogenesis and diagnosis.** *In Pract* 2013; 35: 253–264.
- 3 Villar D, Buck WB and Gonzalez JM. **Ibuprofen, aspirin and acetaminophen toxicosis and treatment in dogs and cats.** *Vet Hum Toxicol* 1998; 40: 156–162.
- 4 Owens-Clark J and Dorman DC. **Toxicity from newer over the counter drugs.** In: Bonagura JD (ed). *Kirk's current veterinary therapy XIII: small animal practice*. Philadelphia, PA: W.B. Saunders; 2000, pp 227–231.
- 5 Kore AM. **Toxicology of nonsteroidal antiinflammatory drugs.** *Vet Clin North Am Small Anim Pract* 1990; 20: 419–429.
- 6 Lucas GNC, Leitão ACC, Alencar RL, et al. **Pathophysiological aspects of nephropathy caused by non-steroidal anti-inflammatory drugs.** *J Bras Nefrol* 2019; 41: 124–130.
- 7 Martínez López AB, Álvarez Blanco O, Luque de Pablos A, et al. **Ibuprofen-induced acute interstitial nephritis in the paediatric population.** *Nefrologia* 2016; 36: 69–71.
- 8 Alper AB, Meleg-Smith S and Krane NK. **Nephrotic syndrome and interstitial nephritis associated with celecoxib.** *Am J Kidney Dis* 2002; 40: 1086–1090.
- 9 Sellers RS, Senese PB and Khan KNM. **Interspecies differences in the nephrotoxic response to cyclooxygenase inhibition.** *Drug Chem Toxicol* 2005; 27: 111–122.
- 10 Bird L and Walker D. **Pathophysiology of acute kidney injury.** *Comp Anim* 2015; 20: 142–147.
- 11 Brezin JH, Katz SM, Schwartz AB, et al. **Reversible renal failure and nephrotic syndrome associated with nonsteroidal anti-inflammatory drugs.** *N Engl J Med* 1979; 301: 1271–1273.
- 12 Ravnskov U. **Glomerular, tubular and interstitial nephritis associated with non-steroidal antiinflammatory drugs. Evidence of a common mechanism.** *Br J Clin Pharmacol* 1999; 47: 203–210.
- 13 Liu AC, Chang Y, Zuckerman JE, et al. **Ibuprofen-associated minimal change disease and acute interstitial nephritis with possibly linked membranous glomerulonephritis.** *SAGE Open Med Case Rep* 2021; 9. DOI: 10.1177/2050313X211025145.
- 14 Shah S, Elder MA and Hata J. **Case report: a rare presentation of NSAID-induced secondary membranous nephropathy in a pediatric patient.** *Front Pediatr* 2021; 9: 670575. DOI: 10.3389/fped.2021.670575.