

## Case Report

# A case of CMV infection and encapsulating peritoneal sclerosis in a renal transplant recipient

Hyunchul Kim<sup>1</sup>, Eunah Hwang<sup>1</sup>, Sungbae Park<sup>1</sup>, Hyungtae Kim<sup>2</sup> and Seungyeup Han<sup>1</sup>

<sup>1</sup>Department of Internal Medicine and <sup>2</sup>Department of General Surgery, Keimyung University School of Medicine, 216 Dalsungro, Junggu, Daegu, Korea

Correspondence and offprint requests to: Eunah Hwang; E-mail: eahwang@gmail.com

### Abstract

Encapsulating peritoneal sclerosis (EPS) is a rare but severe complication of peritoneal dialysis. It has been reported that the condition of patients with EPS may improve after renal transplantation. However, there are also several reports of EPS occurring after renal transplantation. In this report, we present a patient who developed EPS combined with gastrointestinal cytomegalovirus infection 21 months after successful renal transplantation, despite the use of tacrolimus and low-dose steroid as maintenance immunosuppression.

**Keywords:** cytomegalovirus; encapsulating peritoneal sclerosis; immunosuppressive; renal transplantation

### Background

Encapsulating peritoneal sclerosis (EPS) is a rare but devastating complication of peritoneal dialysis (PD). A variety of associated factors has been identified including long duration of PD therapy, number of peritonitis episodes, use of beta-adrenergic blocking agents and chronic irritation due to acetate-containing dialysate [1]. It has been reported that patients with EPS may improve after renal transplantation or with immunosuppressive therapy alone, although the authors of a recent anecdotal case report have questioned the role of immunosuppressive therapy in EPS after transplantation [2].

In this report, we present a case of EPS diagnosed 21 months after renal transplantation, while the patient was on maintenance immunosuppressive therapy with tacrolimus and low-dose corticosteroids.

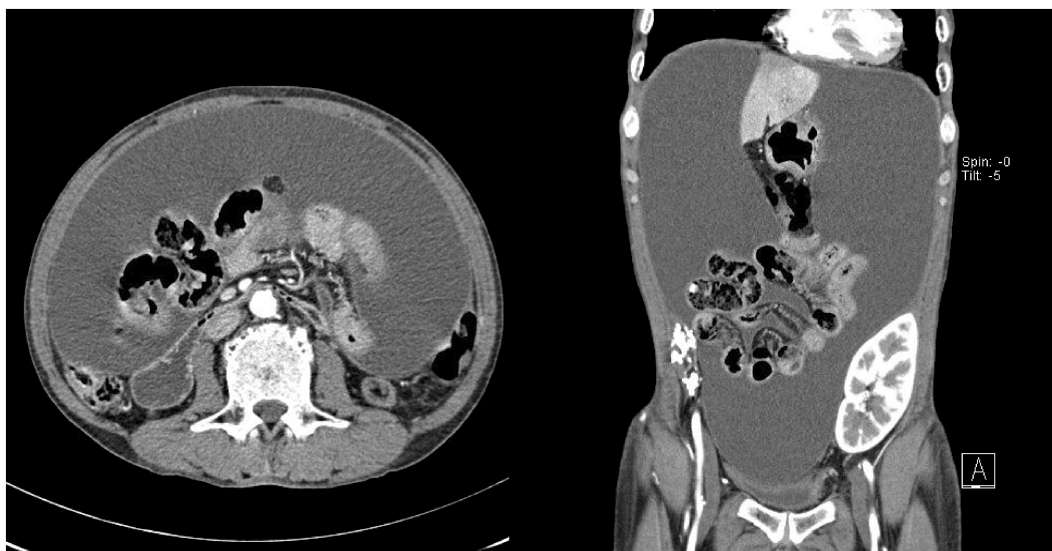
### Case report

A 51-year-old male renal transplant recipient presented with a recent onset of abdominal distension, weight loss and malaise occurring 21 months after transplantation. He was first diagnosed with renal disease manifesting

as chronic glomerulonephritis in 1990 and was initially managed with haemodialysis for 33 months. In 1993, he received his first living unrelated renal transplant, but the graft failed 12 months after transplantation as a result of acute rejection. He was haemodialysed again for 2 years and then switched to PD in 1996. Over the following 6 years, the patient did well, although he had a total of four episodes of bacterial peritonitis (two *Staphylococcus epidermidis*, one *Serratia marcescens* and one culture-negative). All of the peritonitis episodes were successfully treated with intraperitoneal antibiotics. In November 2002, he had problems with fluid balance and hypertension, and required hypertonic exchanges. He was prescribed icodextrin for ultrafiltration inadequacy without peritoneal equilibrium test. The patient was treated with PD for a total of 95 months.

In January 2005, he underwent a cadaveric donor renal transplant and was commenced on tacrolimus, prednisolone and mycophenolate mofetil (MMF). The PD catheter was removed 2 weeks after successful transplantation. At the time of transplantation, the abdominal ultrasound scan did not show any features suggestive of EPS. Seven months after transplantation, the patient developed a gastrointestinal cytomegalovirus (CMV) infection. At this time, his symptoms were intermittent abdominal discomfort without ascites, weight loss or hypoalbuminaemia. The gastrointestinal CMV disease responded well to intravenous ganciclovir therapy and discontinuation of MMF. After 21 days of intravenous ganciclovir therapy, follow-up endoscopic mucosal biopsy showed that the CMV inclusion bodies had disappeared, and immunohistochemistry staining was negative for CMV. The patient became asymptomatic; he had normal serum albumin levels in the range of 4.3–4.7 g/dL, and his body weight remained stable.

In November 2006, the patient was admitted with abdominal discomfort and distension over several days, having experienced vague, unexplained abdominal discomfort for the previous 6 weeks. The laboratory data were: haemoglobin, 11.8 g/dL; WBC, 7060/μL; platelet, 289 000/μL; serum creatinine, 1.1 mg/dL; serum albumin, 3.8 g/dL;



**Fig. 1.** Abdominal computed tomography images show adherent bowel loops, with tethering and luminal narrowing, parietal peritoneal thickening, and loculated fluid collections.

and C-reactive protein, 1.3 mg/dL. Diagnostic paracentesis showed haemorrhagic fluid with a few leucocytes. Cytological studies were repeatedly negative for malignant cells, and cultures of ascitic fluid were repeatedly negative for bacteria, fungi and tubercle bacilli. Computed tomography of the abdomen revealed massive ascites and adherent bowel loops, with tethering, luminal narrowing and partial peritoneal thickening (Figure 1). A diagnosis of EPS was made. The patient complained of epigastric discomfort, and upper gastroendoscopy revealed an active gastric ulcer. Therapeutic paracentesis was performed twice to alleviate symptoms, and he was discharged 8 days later.

However, 4 months after this, he was readmitted with worsening of the abdominal discomfort and distension. A nasogastric tube was placed for drainage, and he was commenced on total parental nutritional support. On Day 8 of his hospital stay, he complained of severe epigastric pain. Upper gastrointestinal endoscopy with mucosal biopsies revealed CMV infection in the oesophagus, stomach and duodenum. Intravenous ganciclovir therapy was started on Day 12, and he underwent exploratory laparotomy on Day 25. At operation, the entire bowel was distended with inflammatory thickening; the bowel loops were coated with exudate and had adhered to each other, forming a large ball. After the operation, the patient was febrile, and blood cultures grew *Candida albicans*. The patient was treated with intravenous fluconazole for 14 days, but he developed bacteraemia caused by methicillin-resistant *Staphylococcus aureus* and *Stenotrophomonas maltophilia*, which led to septic shock. He failed to respond to further therapy and died 52 days after admission.

## Discussion

EPS is one of the most serious complications seen in patients on peritoneal dialysis and is associated with a high mortality rate. It has been reported that EPS may improve

after immunosuppression with or without transplantation. Junor and McMillan [3] reported that five patients with EPS treated with immunosuppression survived, whereas 12 patients not given immunosuppression died. In contrast, de Freitas *et al.* [2] recently reported a case of EPS following renal transplantation despite treatment with tamoxifen and immunosuppression. Also, Bowers *et al.* [4] reported three patients who developed EPS within a year of renal transplantation. Fieren *et al.* [5] reported a cluster of 13 EPS cases occurring shortly after renal transplantation; the patients developed EPS with severe symptoms of intestinal obstruction 1–7 months post-transplant.

The pathogenesis of EPS after renal transplantation remains unclear. Honda and Oda [6] have proposed a 'two-hit' hypothesis for EPS in which disruption of normal peritoneal/mesothelial physiology as a consequence of exposure to PD (generally over a period of years) renders the individual susceptible to a second hit that triggers the process. This second hit may be an inflammatory stimulus such as peritonitis, discontinuation of PD or an acute intra-abdominal event, which is then superimposed on the chronic injury to the peritoneum. According to various reports, EPS has frequently been diagnosed after withdrawal from PD, suggesting that cessation in itself may be a risk factor [5,7,8]. Nakayama *et al.* [7] recommended peritoneal lavage after PD withdrawal to prevent EPS by eliminating possible factors in EPS development. Moriishi *et al.* [8] also suggested that abdominal irrigation through the peritoneal catheter after PD withdrawal enhances recovery from peritoneal damage. The clinical benefit and optimum duration of post-PD lavage have not yet been established; however, the manoeuvre could be included in the management of patients at high risk of developing EPS.

Many inflammatory factors such as interleukin-1 $\beta$ , transforming growth factor- $\beta$  (TGF- $\beta$ ) and vascular endothelial growth factor (VEGF) may play important roles in peritoneal fibroblast activation and fibrosis [5]. In this respect, transplantation itself and the use of immunosuppres-

sive agents after transplantation may be implicated in the development or acceleration of EPS. Fieren *et al.* [5] postulated that the new immunosuppressive treatment regimens may possibly play a role in the pathogenesis of EPS. Calcineurin inhibitors such as cyclosporine and tacrolimus have pro-fibrotic effects and may enhance the pre-existing inflammatory–fibrotic process in the visceral peritoneum of patients on long-term PD, whereas corticosteroids may be the most efficacious immunosuppressive drug in the treatment of post-transplant EPS [5]. In addition, previous CMV infection could be a second hit event in the development of EPS after renal transplantation; CMV enhances expression of TGF- $\beta$  and connective tissue growth factor (CTGF), which are known to be pro-fibrogenic molecules [9]. Dejagere *et al.* [10] have reported a case, similar to ours, of a patient who developed EPS 9 months after transplantation. Their patient had had a gastrointestinal CMV infection 6 months before the onset of EPS.

In our patient, immunosuppressive treatment consisted of tacrolimus and low-dose steroid. Thus, potential triggers for the development of EPS in our patient include the cessation of MMF, which has anti-proliferative properties, the use of very-low-dose steroids, and previous CMV infection.

In conclusion, EPS may develop long after successful renal transplantation, particularly in patients who have been on long-term PD treatment with a high transport state. In addition, specific factors such as particular immunosuppressive agents and CMV could be implicated in the development of EPS.

*Conflict of interest statement.* None declared.

## References

1. Chin AI, Yeun JY. Encapsulating peritoneal sclerosis: an unpredictable and devastating complication of peritoneal dialysis. *Am J Kidney Dis* 2006; 47: 697–712
2. de Freitas D, Augustine T, Hurst H *et al.* Encapsulating peritoneal sclerosis following renal transplantation despite tamoxifen and immunosuppressive therapy. *NDT Plus* 2008; 5: 333–335
3. Junor BJR, MacMillan MA. Immunosuppression in sclerosing peritonitis. *Adv Perit Dial* 1993; 9: 187–189
4. Bowers VD, Ackermann JR, Richardson W *et al.* Sclerosing peritonitis. *Clin Transplant* 1994; 8: 369–372
5. Fieren M, Betjes M, Korte M *et al.* Posttransplant encapsulating peritoneal sclerosis: a worrying new trend? *Perit Dial Int* 2007; 27: 619–624
6. Honda K, Oda H. Pathology of encapsulating peritoneal sclerosis. *Perit Dial Int* 2005; 25: S19–S29
7. Nakayama M, Yamamoto H, Ikeda M *et al.* Risk factors and preventive measures for encapsulating peritoneal sclerosis—Jikei experience 2002. *Adv Perit Dial* 2002; 18: 144–148
8. Moriishi M, Kawanishi H, Kawai T *et al.* Preservation of peritoneal catheter for prevention of encapsulating peritoneal sclerosis. *Adv Perit Dial* 2002; 18: 149–153
9. Helanterä I, Teppo AM, Koskinen P *et al.* Increased urinary excretion of transforming growth factor-beta(1) in renal transplant recipients during cytomegalovirus infection. *Transpl Immunol* 2006; 15: 217–221
10. Dejagere T, Evenepoel P, Claes K *et al.* Acute-onset, steroid-sensitive, encapsulating peritoneal sclerosis in a renal transplant recipient. *Am J Kidney Dis* 2005; 45: e33–e37

*Received for publication: 3.7.09; Accepted in revised form: 19.4.10*