



Management of the distal ureter and bladder cuff at the time of nephroureterectomy: an overview of open, laparoscopic, and robotic approaches

Ram A. Pathak¹, Ashok K. Hemal²

¹Department of Urology, Mayo Clinic Florida, Jacksonville, FL, USA; ²Department of Urology, Wake Forest University, Winston-Salem, NC, USA
Contributions: (I) Conception and design: Both authors; (II) Administrative support: Both authors; (III) Provision of study materials or patients: Both authors; (IV) Collection and assembly of data: Both authors; (V) Data analysis and interpretation: Both authors; (VI) Manuscript writing: Both authors; (VII) Final approval of manuscript: Both authors.

Correspondence to: Ram A. Pathak, MD. Department of Urology, Mayo Clinic Florida, 4500 San Pablo Road, Jacksonville, FL 32224, USA. Email: Pathak.Ram@mayo.edu.

Abstract: Radical nephroureterectomy remains the gold standard treatment for high-risk upper tract urothelial carcinoma. The procedure is subdivided into six main steps: nephrectomy, ureterectomy, bladder cuff excision, cystorrhaphy, template-based lymph node dissection, and perioperative instillation of chemotherapy. Crucial in performing radical nephroureterectomy is successful management of the distal ureter and bladder cuff. Improper, inadequate, or incomplete bladder cuff excision can lead to worse oncologic outcomes and inferior cancer-specific survival. Throughout the years, open, laparoscopic, endoscopic, and robotic approaches have all been reported in performing bladder cuff excision during radical nephroureterectomy. The procedure can be accomplished via an extravesical, intravesical or transvesical manner. Each approach has distinct advantages and disadvantages. The robotic approach offers inherent advantages including improved dexterity, range of motion, and visualization. Critical to choosing an approach, however, is surgeon experience and comfort level. To date, no data suggests superiority of one approach over another. Sound oncologic principles must be adhered to when performing radical nephroureterectomy and include (I) adequate bladder cuff excision, (II) lymphadenectomy, (III) no complications and (IV) negative surgical margins, and (V) perioperative instillation of chemotherapeutic agent. Herein, we describe the various approaches in performing a bladder cuff excision and provide technical commentary supporting the advantages and disadvantages of each technique.

Keywords: Nephroureterectomy; bladder cuff; upper tract urothelial carcinoma (UTUC); ureter; robotic

Submitted Mar 29, 2023. Accepted for publication Dec 21, 2023. Published online Jan 23, 2024.

doi: 10.21037/tau-23-197

View this article at: <https://dx.doi.org/10.21037/tau-23-197>

Introduction

The biology of upper tract urothelial carcinoma (UTUC) is highly dependent on stage and grade of the pathology. The European Association of Urology (EAU) and American Urological Association (AUA) have written comprehensive guidelines that propose a risk-stratified approach when managing UTUC (1,2). Specifically, for high-risk UTUC, the gold standard treatment is *en bloc* radical nephroureterectomy and bladder cuff excision

with lymphadenectomy. The procedure is subdivided into six main steps: nephrectomy, ureterectomy, bladder cuff excision, cystorrhaphy, template-based lymph node dissection, and perioperative instillation of chemotherapy. The most critical portion of the procedure is dissection of the distal ureter along with its intravesical component (bladder cuff) as sub-optimal management can lead to higher rates of cancer-specific mortality (3).

Five-year overall survival rates for UTUC can range

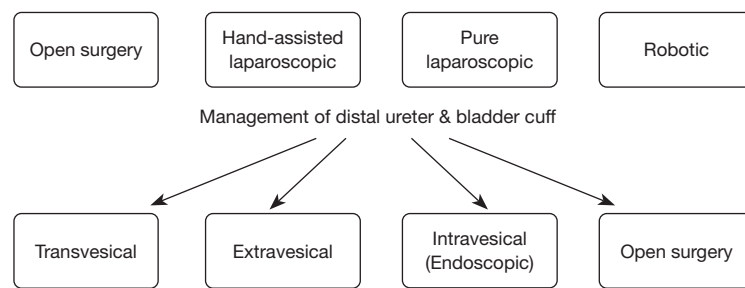


Figure 1 Various approaches in performing radical nephroureterectomy accompanied by the varied techniques in performing the distal ureter and bladder cuff.

from less than 20–75% according to Surveillance, Epidemiology, and End-Results (SEER) data (4). Inadequate management of the distal ureter and bladder cuff can directly result in a 1.25–1.45 times greater disease-specific mortality in patients with advanced or nodal disease (5). The recurrence rate of UTUC can be quite high and sub-optimal dissection of the distal ureter may yield a ureteral remnant with recurrence rates of 33–75% (6). Approach to radical nephroureterectomy is diverse and includes open, hand-assisted laparoscopic, pure laparoscopic, and robotic (Figure 1) (7). Furthermore, the management of the distal ureter and bladder cuff is equally as varied, if not more, and includes extravesical *vs.* transvesical *vs.* intravesical (endoscopic) with each potentially being performed via open, laparoscopic, robotic, or endoscopic approaches (8). The laparoscopic and robotic approaches have resulted in improved perioperative factors compared to open surgery (9,10); though, oncologic outcomes are a bit more inconclusive (11,12). Currently, there is no consensus on approach for managing the distal ureter or bladder cuff and is, therefore, dependent on the expertise and preference of the surgeon.

Morbidity of a procedure is a quantifiable event and the rise of minimally invasive alternatives to traditional open surgery is a testament to the importance of this factor. After initial publications of the laparoscopic approach (13), the robotic approach has gained significant traction (10). A recent systematic review sought to compare oncologic outcomes between open and laparoscopic surgery and found inferior outcomes associated with laparoscopy, especially in patients with pure laparoscopic management of the bladder cuff (3). On the other hand, robotic nephroureterectomy has become increasingly utilized, doubling from 2010 to 2013, with a corresponding decrease in the open approach (14). Increased utilization, however, may not necessarily translate to superior oncologic outcomes. Herein, we

describe the various approaches to managing the distal ureter and bladder cuff at the time of nephroureterectomy and comment on perioperative, functional, and oncologic outcomes of each approach. Regardless of approach, sound oncologic principles must be adhered to and include the following: (I) R0 resection, (II) avoidance of tumor or urine spillage in the operative field, (III) water-tight cystorrhaphy, (IV) instillation of perioperative chemotherapeutic agent, and (V) *en bloc* removal of the kidney, ureter, and bladder cuff.

Open

Open radical nephroureterectomy can be performed via a singular midline or thoraco-abdominal incision *vs.* a two-incision approach (subcostal/flank + lower midline/Gibson/Pfannenstiel). The preference and experience of the surgeon plays a critical role in selecting incision type. However, in older series, a single incision (compared to dual incision) was associated with a 50% likelihood of retaining a ureteral stump (15). In an extravesical bladder cuff excision, tension is applied to the ureter away from the bladder until an oncologically appropriate cuff is included. Typically, a 2–3 cm bladder cuff is sufficient but can be tailored based on pathology. Distal ureteral or fungating tumors emanating from the ureteral orifice may necessitate a larger bladder cuff. The cuff is excised *en bloc* with the kidney and ureter. Cystorrhaphy using 3-0 and 2-0 vicryl is performed, closing the bladder in multiple layers. A leak test is recommended, and the bladder is filled to about 120 cc of sterile saline ensuring no dissipation of fluid into the abdomen. Once confirmed, instillation of a chemotherapeutic agent is performed.

In a transvesical approach, a separate incision is made on the anterior bladder and the ureteral orifice is cored from inside of the bladder. With simultaneous continued

dissection from within the bladder and tension applied on the distal ureter away from the bladder, the intramural cuff is dissected and freed. Closure of the defect can be achieved transvesically and extravesically. The transvesical approach is favored in patients who may be more obese or have history of pelvic radiation or significant prior pelvic surgery. When comparing the open transvesical *vs.* extravesical approaches, one study found that the transvesical approach had improved recurrence free survival and intravesical recurrence free survival (6). The authors postulate this may be technique-dependent and that direct visualization of the ureteral orifice can limit retained ureteric segments.

When comparing the open approach to the pure laparoscopic approach, level I randomized evidence suggests that excising the bladder laparoscopically can result in inferior cancer-specific survival and metastasis-free survival in patients with pT3 and high-grade tumors (3). Results of this trial underscore the importance of adhering to sound oncologic principles when dissecting the distal ureter and bladder cuff.

Endoscopic

Endoscopic approaches such as ureteral unroofing (16), “pluck” technique (17), and “stripping” technique (18) have all been published with varying degrees of oncologic efficacy. The ureteral unroofing technique is initiated with placement of a ureteral catheter. Next, a resectoscope is used to ‘unroof’ the intramural ureter by resecting on the ureteral catheter. The catheter is then withdrawn exposing the ‘gutter’ which is then resected as well (16). The “pluck” technique involves endoscopic incision/resection of the ureteral orifice and surrounding tissue. Typically using the Collins knife, endoscopic dissection is carried out until perivesical fat is visualized. With traction applied to the distal ureteral segment, the intramural ureter is ‘plucked’ and removed *en bloc* (17). “Stripping” is yet another endoscopic manipulation technique where a ureteral catheter is secured to the ureter and the distal ureter is ligated. Endoscopic resection of the proximal portion of the intramural ureter is performed while applying traction to the ureteral catheter, thereby intussuscepting it (18).

Unfortunately, these endoscopic techniques permitted potential spillage of tumor or urine within the abdomen leading to increased retroperitoneal or bladder recurrence (19). In fact, in cases with bulky distal ureteral tumors or high-grade pathology, avoidance of the endoscopic method is recommended (20). One study found the mean rate of

intravesical recurrence at 19.3% for ‘stripping’ and 24% for ‘plucking’ (21). Given these compromises to oncologic safety, several modifications evolved including the use of fibrin glue (22) to help prevent tumor or urine spillage. One center incorporated the use of a preformed 0 PDS II Endoloop which secured around the ureteral orifice prior to ureteral detachment (23). Although several publications indicate the endoscopic approach is non-inferior with respect to oncologic outcomes (24,25), lack of long-term data, level I evidence, or meta-analyses make comparing approaches problematic.

Laparoscopic

Laparoscopic nephroureterectomy with bladder cuff excision is superior compared to the open approach with respect to several functional parameters including length of stay, blood loss, complication profile and postoperative pain (26). In one systematic review and meta-analysis, both laparoscopic and hand-assisted nephroureterectomy were found to have improved peri- and post-operative outcomes with similar oncologic outcomes (27). The bladder cuff can be excised with the help of any of the endoscopic techniques. A LigaSure™ (28), bulldog clamp (29), stapler (30), or formal excision with suture reconstruction (31) are additional methods in performing bladder cuff excision. Laparoscopic extravesical excision of the bladder cuff afforded the same benefits of minimally invasive surgery and allowed avoidance of entry into the urinary tract. The distal ureter is dissected, and traction placed cranially away from the bladder. The dissection is then carried down until the cuff is realized. Eventually the orifice becomes retracted so far cranially that it is inverted. Using a LigaSure™ or stapler to the bladder cuff, the specimen is removed. In comparison to the extravesical technique, the transvesical technique requires two additional ports to be placed transvesically. This allows for early occlusion of the distal ureter. Transurethral detachment would then occur (32).

Though the functional parameters were improved with the laparoscopic approach, it forced surgeons to work in small spaces, decreased exposure and limited range of motion. In some instances, oncologic parameters suffered. When examining laparoscopic extravesical stapling of the bladder cuff, an increased incidence of positive surgical and inferior local recurrence-free survival was noted (33). Moreover, stones could potentially form at the staple line (34). In a meta-analysis examining over 250 patients in nine distinct studies, patients undergoing laparoscopic bladder

cuff excision had a higher rate of distant metastases while the open approach was associated with a higher incidence of intravesical recurrence (35). For bulky distal ureteral tumors, high grade and pT3/T4 tumors, pure laparoscopic excision resulted in inferior oncologic outcomes (9). The decreased working environment and limited range of motion of instruments can be overcome with highly advanced laparoscopic skills, possibly underscoring the etiology of these inferior oncologic outcomes.

Robotic

The robotic approach could theoretically overcome the limitations of the laparoscopic approach by improving dexterity, range of motion, and visualization. Being a multi-quadrant procedure, the first critical step in performing robotic nephroureterectomy is correct and precise port placement. We previously described our templated port-placement for nephroureterectomy (36) and involves a linear placement of 8 mm trocar on the lateral boarder of the rectus sheath superiorly with more lateral displacement inferiorly. In contrast to the endoscopy, no repositioning is required when adopting the robotic approach (37,38). When transitioning to the da Vinci Xi[®], performance of the surgery has become more facile by utilizing additional features such as targeting/re-targeting, camera hopping, and integrated table motion resulting in fewer arm collisions and instrument constraints. In fact, this has directly translated to decreases in operative time and total hospital costs (39).

After port placement, we perform nephrectomy followed by ureterectomy and distal ureteral dissection. The ureter is ligated with a Heme-o-lok clip distal to location of the primary tumor as soon as the renal artery is controlled to prevent theoretical downward migration of tumor cells from manipulation or traction of the kidney. Lymph node dissection can then be performed in a template fashion (40). Robotic assistance has facilitated performance of lymph node dissection. In fact, patients undergoing robotic nephroureterectomy are more likely to undergo lymph node dissection compared to patients undergoing a laparoscopic or open approach (14).

However, the real superiority of the robotic approach lies in the unhampered and unmitigated access to the distal ureter and bladder cuff. Adequate exposure to the bladder cuff can also lead to a water-tight cystorrhaphy curtailing fears of drug spillage from bladder closure and perhaps increasing adherence to guideline-based practice (41). If needed in more complex cases, we feel the following tips

and tricks can ameliorate dissection of the bladder cuff: (I) utilization of simultaneous pneumocystoscopy (CO₂ gas, in particular, to prevent spillage of bladder contents) which allows direct visualization of the ureteral orifice in order to excise an adequate cuff of bladder, especially in cases with narrow pelvis or increased intra-abdominal adiposity and (II) adoption of fluorescence-guidance using indocyanine green which can enhance the viewing of surgical planes when indocyanine green (ICG) is instilled intravesically (42). In summary, the degrees of freedom and 3D vision afforded by robotic assistance possesses inherent advantages over the open/laparoscopic approach.

Despite this progress, there is a paucity of data comparing robotic *vs.* laparoscopic *vs.* open radical nephroureterectomy with no level I evidence confirming the superiority of one approach over another. The data comparing these approaches is largely retrospective and comprise of inhomogenous populations and varied surgical techniques thereby making direct comparisons between open *vs.* laparoscopic *vs.* robotic is difficult. It is important to note that no data has suggested or implied any inferiority with the robotic approach. We previously published on outcomes after robotic radical nephroureterectomy which demonstrated excellent perioperative outcomes (10). Average operative time and length of stay was 229.7 minutes and 3.56 days, respectively, with minimal complications profile. Robotic radical nephroureterectomy is, therefore, deemed safe and efficacious as a valid alternative to traditional open or laparoscopic surgery.

The advantages afforded by the robotic technique should not compromise oncologic outcomes. In fact, positive surgical margins are found to be less frequent when adopting the robotic approach (14). Overall and cancer-specific survival are comparable if not slightly improved compared to the open/laparoscopic approach in certain series (10,43). Critical to this success lies in the complete and more accurate dissection of the distal ureter and bladder cuff. Incomplete distal ureteral dissection can lead to a residual ureteral stump, which translates to inferior rates of overall survival, cancer-specific survival, distant recurrence-free survival, and bladder recurrence-free survival (8). In a multi-center study, data from 17 centers with 276 matched patients (185 robotic/91 laparoscopic) demonstrated that patients undergoing robotic radical nephroureterectomy were more likely to undergo bladder cuff excision (81% *vs.* 63.7%, $P=0.003$) (44). The authors postulate that to achieve “tetrafecta” outcomes, the surgeon must adequately perform the following: (I) adequate bladder cuff excision,

(II) lymphadenectomy (45,46), (III) no complications and (IV) negative surgical margins. However, in order to achieve “pentafecta” outcomes, incorporating instillation of chemotherapeutic agent can increase bladder recurrence-free survival (47).

Thus, when determining efficiency of a procedure, we must investigate the feasibility of performing the procedure, the safety/complication profile, the impact to patient morbidity and define the long-term oncologic outcomes. Robotic radical nephroureterectomy compares favorably with respect to the above factors and represents an efficient, safe and feasible alternative for patients with high-risk UTUC. However, regardless of approach chosen, sound oncologic principles must be adhered to and surgeon confidence and experience should reflect this decision.

Conclusions

No level I evidence exists to support one approach over another. Sound oncologic principles must be adhered to. Performance and successful completion of distal ureterectomy and bladder cuff excision is arguably the most important aspect of radical nephroureterectomy and should not be compromised.

Acknowledgments

Funding: None.

Footnote

Provenance and Peer Review: This article was commissioned by the editorial office, *Translational Andrology and Urology* for the series “Upper Tract Urothelial Cancer”. The article has undergone external peer review.

Peer Review File: Available at <https://tau.amegroups.com/article/view/10.21037/tau-23-197/prf>

Conflicts of Interest: Both authors have completed the ICMJE uniform disclosure form (available at <https://tau.amegroups.com/article/view/10.21037/tau-23-197/coif>). The series “Upper Tract Urothelial Cancer” was commissioned by the editorial office without any funding or sponsorship. A.K.H. and R.A.P. served as the unpaid Guest Editors of the series. A.K.H. also serves as an unpaid editorial board member of *Translational Andrology and Urology*. The authors have no other conflicts of interest to declare.

Ethical Statement: The authors are accountable for all aspects of the work in ensuring that questions related to the accuracy or integrity of any part of the work are appropriately investigated and resolved.

Open Access Statement: This is an Open Access article distributed in accordance with the Creative Commons Attribution-NonCommercial-NoDerivs 4.0 International License (CC BY-NC-ND 4.0), which permits the non-commercial replication and distribution of the article with the strict proviso that no changes or edits are made and the original work is properly cited (including links to both the formal publication through the relevant DOI and the license). See: <https://creativecommons.org/licenses/by-nc-nd/4.0/>.

References

1. Rouprêt M, Seisen T, Birtle AJ, et al. European Association of Urology Guidelines on Upper Urinary Tract Urothelial Carcinoma: 2023 Update. *Eur Urol* 2023;84:49-64.
2. Coleman JA, Clark PE, Bixler BR, et al. Diagnosis and Management of Non-Metastatic Upper Tract Urothelial Carcinoma: AUA/SUO Guideline. *J Urol* 2023;209:1071-81.
3. Peyronnet B, Seisen T, Dominguez-Escrig JL, et al. Oncological Outcomes of Laparoscopic Nephroureterectomy Versus Open Radical Nephroureterectomy for Upper Tract Urothelial Carcinoma: An European Association of Urology Guidelines Systematic Review. *Eur Urol Focus* 2019;5:205-23.
4. Raman JD, Messer J, Sielatycki JA, et al. Incidence and survival of patients with carcinoma of the ureter and renal pelvis in the USA, 1973-2005. *BJU Int* 2011;107:1059-64.
5. Lughezzani G, Sun M, Perrotte P, et al. Should bladder cuff excision remain the standard of care at nephroureterectomy in patients with urothelial carcinoma of the renal pelvis? A population-based study. *Eur Urol* 2010;57:956-62.
6. Kapoor A, Dason S, Allard CB, et al. The impact of method of distal ureter management during radical nephroureterectomy on tumour recurrence. *Can Urol Assoc J* 2014;8:E845-52.
7. Veccia A, Antonelli A, Francavilla S, et al. Robotic versus other nephroureterectomy techniques: a systematic review and meta-analysis of over 87,000 cases. *World J Urol* 2020;38:845-52.
8. Pathak RA, Hemal AK. Fate of residual ureteral stump in patients undergoing robot-assisted radical

- nephroureterectomy for high-risk upper tract urothelial carcinoma. *Transl Androl Urol* 2020;9:856-62.
9. Simone G, Papalia R, Guaglianone S, et al. Laparoscopic versus open nephroureterectomy: perioperative and oncologic outcomes from a randomised prospective study. *Eur Urol* 2009;56:520-6.
 10. Pathak RA, Hemal AK. Techniques and Outcomes of Robot-assisted Nephro-ureterectomy for Upper Tract Urothelial Carcinoma. *Eur Urol Focus* 2018;4:657-61.
 11. Stewart GD, Humphries KJ, Cutress ML, et al. Long-term comparative outcomes of open versus laparoscopic nephroureterectomy for upper urinary tract urothelial-cell carcinoma after a median follow-up of 13 years*. *J Endourol* 2011;25:1329-35.
 12. Ni S, Tao W, Chen Q, et al. Laparoscopic versus open nephroureterectomy for the treatment of upper urinary tract urothelial carcinoma: a systematic review and cumulative analysis of comparative studies. *Eur Urol* 2012;61:1142-53.
 13. Schatteman P, Chatzopoulos C, Assenmacher C, et al. Laparoscopic nephroureterectomy for upper urinary tract transitional cell carcinoma: results of a Belgian retrospective multicentre survey. *Eur Urol* 2007;51:1633-8; discussion 1638.
 14. Rodriguez JF, Packiam VT, Boysen WR, et al. Utilization and Outcomes of Nephroureterectomy for Upper Tract Urothelial Carcinoma by Surgical Approach. *J Endourol* 2017;31:661-5.
 15. Strong DW, Pearse HD, Tank ES Jr, et al. The ureteral stump after nephroureterectomy. *J Urol* 1976;115:654-5.
 16. Abercrombie GF. Nephro-ureterectomy. *Proc R Soc Med* 1972;65:1021-2.
 17. McDONALD HP, UPCHURCH WE, STURDEVANT CE. Nephro-ureterectomy: a new technique. *J Urol* 1952;67:804-9.
 18. McDONALD DF. Intussusception ureterectomy: a method of removal of the ureteral stump at time of nephrectomy without an additional incision. *Surg Gynecol Obstet* 1953;97:565-8.
 19. Walton TJ, Sherwood BT, Parkinson RJ, et al. Comparative outcomes following endoscopic ureteral detachment and formal bladder cuff excision in open nephroureterectomy for upper urinary tract transitional cell carcinoma. *J Urol* 2009;181:532-9.
 20. Jones DR, Moisey CU. A cautionary tale of the modified "pluck" nephroureterectomy. *Br J Urol* 1993;71:486.
 21. Laguna MP, de la Rosette JJ. The endoscopic approach to the distal ureter in nephroureterectomy for upper urinary tract tumor. *J Urol* 2001;166:2017-22.
 22. Mueller TJ, DaJusta DG, Cha DY, et al. Ureteral fibrin sealant injection of the distal ureter during laparoscopic nephroureterectomy--a novel and simple modification of the pluck technique. *Urology* 2010;75:187-92.
 23. Agarwal DK, Khaira HS, Clarke D, et al. Modified transurethral technique for the management of distal ureter during laparoscopic assisted nephroureterectomy. *Urology* 2008;71:740-3.
 24. Luo HL, Kang CH, Chen YT, et al. Oncological impact of endoscopic bladder cuff management during nephroureterectomy varies according to upper urinary tract tumor location. *Int J Urol* 2014;21:366-9.
 25. Fragkoulis C, Pappas A, Papadopoulos GI, et al. Transurethral resection versus open bladder cuff excision in patients undergoing nephroureterectomy for upper urinary tract carcinoma: Operative and oncological results. *Arab J Urol* 2017;15:64-7.
 26. Hemal AK, Kumar A, Gupta NP, et al. Retroperitoneal nephroureterectomy with excision of cuff of the bladder for upper urinary tract transitional cell carcinoma: comparison of laparoscopic and open surgery with long-term follow-up. *World J Urol* 2008;26:381-6.
 27. Nouralizadeh A, Tabatabaei S, Basiri A, et al. Comparison of Open Versus Laparoscopic Versus Hand-Assisted Laparoscopic Nephroureterectomy: A Systematic Review and Meta-Analysis. *J Laparoendosc Adv Surg Tech A* 2018;28:656-81.
 28. Lambert EH, Schachter LR, Altamar HO, et al. A sealed bladder cuff technique during laparoscopic nephroureterectomy utilizing the LigaSure electrosurgical device: laboratory and clinical experience. *J Endourol* 2010;24:327-32.
 29. Liu P, Fang D, Xiong G, et al. A Novel and Simple Modification for Management of Distal Ureter During Laparoscopic Nephroureterectomy Without Patient Repositioning: A Bulldog Clamp Technique and Description of Modified Port Placement. *J Endourol* 2016;30:195-200.
 30. Ritch CR, Kearns JT, Mues AC, et al. Comparison of distal ureteral management strategies during laparoscopic nephroureterectomy. *J Endourol* 2011;25:1149-54.
 31. Gillan A, Alexander E, Townell N, et al. Laparoscopic en bloc resection of ureter with a cuff of bladder during radical nephroureterectomy for lower ureteric tumors: a matched-paired analysis. *J Laparoendosc Adv Surg Tech A* 2013;23:626-31.
 32. Gill IS, Soble JJ, Miller SD, et al. A novel technique

- for management of the en bloc bladder cuff and distal ureter during laparoscopic nephroureterectomy. *J Urol* 1999;161:430-4.
33. Xylinas E, Colin P, Audenet F, et al. Intravesical recurrence after radical nephroureterectomy for upper tract urothelial carcinomas: predictors and impact on subsequent oncological outcomes from a national multicenter study. *World J Urol* 2013;31:61-8.
 34. Yoshino Y, Ono Y, Hattori R, et al. Retroperitoneoscopic nephroureterectomy for transitional cell carcinoma of the renal pelvis and ureter: Nagoya experience. *Urology* 2003;61:533-8.
 35. Whiting D, Sriprasad S. Management of the Distal Ureter in Radical Laparoscopic Nephroureterectomy for Upper Tract Urothelial Carcinoma. *J Laparoendosc Adv Surg Tech A* 2021;31:610-20.
 36. Pathak RA, Patel M, Hemal AK. Comprehensive Approach to Port Placement Templates for Robot-Assisted Laparoscopic Urologic Surgeries. *J Endourol* 2017;31:1269-76.
 37. Hemal AK, Stansel I, Babbar P, et al. Robotic-assisted nephroureterectomy and bladder cuff excision without intraoperative repositioning. *Urology* 2011;78:357-64.
 38. Veccia A, Carbonara U, Derweesh I, et al. Single-stage Xi® robotic radical nephroureterectomy for upper tract urothelial carcinoma: surgical technique and outcomes. *Minerva Urol Nephrol* 2022;74:233-41.
 39. Patel MN, Hemal AK. Does Advancing Technology Improve Outcomes? Comparison of the Da Vinci Standard/S/Si to the Xi Robotic Platforms During Robotic Nephroureterectomy. *J Endourol* 2018;32:133-8.
 40. Saini S, Pathak RA, Hemal AK. Robotic nephroureterectomy in the management of upper tract urothelial cancer: inching toward standard of care? *Int Urol Nephrol* 2022;54:1777-85.
 41. Dobé TR, Califano G, von Rundstedt FC, et al. Postoperative Chemotherapy Bladder Instillation After Radical Nephroureterectomy: Results of a European Survey from the Young Academic Urologist Urothelial Cancer Group. *Eur Urol Open Sci* 2020;22:45-50.
 42. Pathak RA, Hemal AK. Intraoperative ICG-fluorescence imaging for robotic-assisted urologic surgery: current status and review of literature. *Int Urol Nephrol* 2019;51:765-71.
 43. Aboumohamed AA, Krane LS, Hemal AK. Oncologic Outcomes Following Robot-Assisted Laparoscopic Nephroureterectomy with Bladder Cuff Excision for Upper Tract Urothelial Carcinoma. *J Urol* 2015;194:1561-6.
 44. Veccia A, Carbonara U, Djaladat H, et al. Robotic vs Laparoscopic Nephroureterectomy for Upper Tract Urothelial Carcinoma: A Multicenter Propensity-Score Matched Pair "tetrafecta" Analysis (ROBUUST Collaborative Group). *J Endourol* 2022;36:752-9.
 45. Soria F, Pradere B, Hurle R, et al. Radical Nephroureterectomy Tetrafecta: A Proposal Reporting Surgical Strategy Quality at Surgery. *Eur Urol Open Sci* 2022;42:1-8.
 46. Roscigno M, Shariat SF, Margulis V, et al. Impact of lymph node dissection on cancer specific survival in patients with upper tract urothelial carcinoma treated with radical nephroureterectomy. *J Urol* 2009;181:2482-9.
 47. Pathak RA, Hemal AK. Editorial Comment on: "Robotic vs Laparoscopic Nephroureterectomy for Upper Tract Urothelial Carcinoma: A Multicenter Propensity-Score Matched Pair "tetrafecta" Analysis (ROBUUST Collaborative Group)" by Veccia et al. *J Endourol* 2022;36:760-1.

Cite this article as: Pathak RA, Hemal AK. Management of the distal ureter and bladder cuff at the time of nephroureterectomy: an overview of open, laparoscopic, and robotic approaches. *Transl Androl Urol* 2024;13(1):109-115. doi: 10.21037/tau-23-197