

OCULAR DISEASE PATTERN INDUCED BY HERPES  
SIMPLEX VIRUS IS GENETICALLY DETERMINED BY  
A SPECIFIC REGION OF VIRAL DNA\*

BY YSOLINA M. CENTIFANTO-FITZGERALD,‡ TATSUO YAMAGUCHI,  
HERBERT E. KAUFMAN, MAURO TOGNON,§ AND BERNARD ROIZMAN

*From the Lions Eye Research Laboratories, LSU Eye Center, LSU Medical Center School of Medicine,  
New Orleans, Louisiana 70112; and the Marjorie B. Kovler Viral Oncology Laboratories, University of  
Chicago School of Medicine, Chicago, Illinois 60027*

Ocular disease caused by herpes simplex virus (HSV)<sup>1</sup> ranges in severity from a self-limiting blepharitis, conjunctivitis, or dendritic keratitis to a disciform stromal edema and necrotizing stromal keratitis that can cause blindness. Herpes keratitis and stromal disease are distinct, readily differentiable clinical entities that can be studied in animal models. In pure dendritic herpes keratitis, the virus grows in the epithelial layer of the cornea and causes dendritic ulcers of a clearly defined and characteristic shape. These ulcers may enlarge and coalesce to form "geographic" lesions of an ameboid shape. The disease subsides without scarring. Clinically, patients who have HSV infections demonstrate many varieties of corneal clinical findings. In this disease process, the tissue destruction is largely a result of virus growth.

In the stromal disease model, the rabbit cornea infected with an appropriate strain first develops epithelial lesions that usually attain maximum severity 5–7 d postinfection. Shortly thereafter, disciform edema occurs and persists for several weeks. Subsequently, the stromal layer becomes opaque, with infiltration by lymphocytes, macrophages, and polymorphonuclear leukocytes. Ultimately, vascularization of the cornea and tissue necrosis ensues. In this disease process, tissue destruction appears to be a result of the immune response of the host to the antigen present in the stroma because the infectious virus has generally disappeared from the cornea by this time.

The factors that determine the outcome of HSV infection of the eye are not well understood. Whereas host factors certainly play a significant part (1–4), a considerable body of evidence indicates that at least part of the disease pattern may be a reflection of the genetic properties of the infecting strain. Specifically, (a) Wander et al. (5) have shown that the type of ocular disease produced in the rabbit eye is an inherent property of the infecting strain and is independent of the titer of the infecting virus. Strains that produce epithelial disease fail to produce stromal disease regardless of

\* Supported in part by U. S. Public Health Service grants EY02389 (to Dr. Centifanto-Fitzgerald), EY02672 (to Dr. Kaufman), and EY02377 (to Dr. Kaufman) from the National Eye Institute, and U. S. Public Health Service grants CA08494 (to Dr. Roizman), and CA192264 (to Dr. Roizman) from the National Cancer Institute.

‡ To whom all correspondence should be addressed at: LSU Eye Center, 136 South Roman Street, New Orleans, LA. 70112.

§ Present address is the Instituto Microbiologia, Ferrara, Italy.

<sup>1</sup> Abbreviations used in this paper: HSV, herpes simplex virus; PFU, plaque-forming units.

inoculum size. (b) Only a small number of human herpetic keratitis cases develop into stromal disease, even if the disease is untreated and of long duration. In addition, clinical isolates from human epithelial HSV disease, when tested in animals, have failed to produce stromal disease (6), whereas known stromal disease-producing strains regularly reproduce this characteristic disease pattern even after serial propagation in cell culture (7, 8).

In this paper, we report that the pattern of disease characteristic of stromal infection can be transferred from a stromal disease-producing strain [HSV-1(MP)] to an epithelial disease-producing strain [HSV-1(F)] by transfer of a defined fragment of HSV-1(MP) DNA. The derivation and relevant properties of these strains are as follows. HSV-1(MP) is a spontaneously derived mutant of HSV-1(mP) strain and causes fusion of a wide variety of infected cells (9). Preliminary studies have shown that HSV-1(MP) causes a stromal disease in the rabbit eye but that the disease pattern is somewhat simpler and consists mainly of interstitial edema with no opacity or significant cell infiltration. This stromal disease is not prevented by active immunosuppression of the host (10). In this respect, the disease is similar to that produced by the HSV-1(RE) strain in athymic mice, in which edema is present but tissue necrosis and opacity are not seen (11). HSV-1(MP) strain, however, differs from the HSV-1(mP) parent strain in that it fails to specify a major viral glycoprotein (12, 13) and causes rapid encephalitis and death in rabbits when inoculated into the cornea. HSV-1(F) was isolated from a recurrent infection of the lip and has been passaged only a limited number of times outside the human host (14). It causes an epithelial disease pattern upon inoculation into rabbit cornea.

Earlier studies (15) involving the transfer of specific fragments of HSV-1(MP) DNA into the HSV-1(F) DNA by homologous recombination showed that the HSV-1(MP) genome contained two loci responsible for cell fusion (*syn* phenotype) and a locus controlling the synthesis of glycoprotein C ( $Cr^-$  phenotype). The recombinants selected for study caused cell fusion (*syn* phenotype) in infected cells. Recipients of the *syn* 1 locus caused the fusion of Vero cells but not of HEp-2-infected cells. Recipients of a second, closely linked locus (*syn* 2) caused fusion of infected Vero and HEp-2 cells. Finally, recipients of the *Cr* locus failed to synthesize glycoprotein C; this locus appears to be closely linked to the *syn* 2 locus and can be segregated from the *syn* 1 locus. All three loci are contained in the BglII F fragment of HSV-1(MP) DNA, which maps between 0.70 and 0.83 map units of HSV-1 DNA. Because the recombinants resulted from replacement of homologous regions of HSV-1 DNA, the precise region of the specific HSV-1(MP) DNA fragment that replaced the homologous sequence in HSV-1(F) DNA could not be determined; however, the fragment had to include the mutations in the HSV-1(MP) that caused cell fusion. We focused on the recombinants isolated in that study because of the differences in mortality in rabbits inoculated by the corneal route with HSV-1(MP) and its parent HSV-1(mP). These results suggested that viral functions affecting the pattern of eye disease may be encoded in the BglII F fragment.

In this report, we show that the recombinants produced by the DNA transfer cause a variety of disease patterns, including the stromal disease characteristic of HSV-1(MP) virus as well as the morphology and extent of the virus-induced epithelial ulceration.

## Materials and Methods

*Virus and Cells.* The virus strains used in this study were HSV-1(F) (4), HSV-1(MP) (9), and recombinant strains F(MP)A, F(MP)B, F(MP)C, F(MP)D, F(MP)E, and F(MP)F (15). The recombinants were obtained in marker transfer experiments involving transfection of rabbit skin cells with HSV-1(F) DNA and the BglII F fragment of HSV-1(MP) DNA. Recombinants were selected for production of polykarocytes in Vero cells. The procedure and properties of the recombinants have been described elsewhere (15). Viral stocks were made in HEP-2 cells overlaid with mixture 199 supplemented with 1% fetal calf serum.

*Animal Model.* We determined and described the pattern and severity of the ocular disease caused by each of the virus strains in the eyes of New Zealand white rabbits weighing 3–5 kg. Three interlocking 10-mm trephine incisions were made in the superficial epithelium of each cornea. The lid was pulled tightly, creating a cul-de-sac into which 100  $\mu$ l of virus suspension ( $10^6$  plaque-forming units [PFU]) was dropped. The liquid was moved back and forth over the cornea three times. The lid was closed, and the eye was rubbed twice. Both eyes of six animals were infected with each virus strain, for a total of twelve eyes per strain. The eyes were examined with the slit lamp biomicroscope on a masked (blind) basis every 2–3 d for 30 d. Epithelial lesions were evaluated with cobalt-filtered blue light after instillation of fluorescein.

Epithelial disease was classified as follows: 0, if normal;  $\frac{1}{4}$ , if one dendrite was present; 1+, if  $\frac{1}{4}$  of the corneal epithelium was involved; 2+, if  $\frac{1}{2}$  of the epithelium was involved; 3+, if  $\frac{3}{4}$  of the epithelium was involved; and 4+, if the entire epithelium was involved. Geographic defects were described. For this study, an average of  $<1$  was characterized as mild epithelial disease, and an average of 1 to 2 was characterized as moderate epithelial disease.

Stromal disease was classified as follows:  $\frac{1}{2}$ , if minimal stromal edema, infiltration, or scarring was detected; 1+, if mild edema, infiltration, or scarring was present and iris detail was still visible; 2+, if edema, infiltrate, and/or scarring was sufficient to obscure all iris detail; and 4+, if the cornea was totally opaque. Corneal vascularization and stromal edema were described.

Another group of rabbits was used for the characterization of ocular disease by light and electron microscopy. Both corneas of four animals were infected with each strain, as above. The eyes were examined by slit lamp biomicroscope every 2 d. When the infected corneas appeared to show maximum clinical findings, two of the animals infected with each virus strain were sacrificed and the eyes enucleated. One-half of each cornea was processed for transmission electron microscopy and the other one-half for scanning electron microscopy. A portion of the transmission electron microscopy specimen was prepared for light microscope examination by dehydration through a series of graded alcohols and embedding in paraffin. Sections were stained with haematoxylin and eosin.

For transmission electron microscopy, the tissue was fixed in 3% glutaraldehyde with phosphate buffer (pH 7.2) for 90 min, postfixed in 1% osmium tetroxide with the same buffer for 90 min, dehydrated in graded alcohols, and embedded in Epon. Embedded tissues were cut with a Porter-Blum MT-2 microtome (Porter Instrument Co., Hatfield, Pa.) and stained with uranyl acetate and lead citrate. Photographs were taken with an EM-109 (Carl Zeiss, Inc., West Germany) microscope.

For scanning electron microscopy, the tissue was fixed in 3% glutaraldehyde with phosphate buffer (pH 7.2) for 90 min, dehydrated in alcohol, dried in a critical point dryer, placed on aluminum stubs, and coated with gold. Photographs were taken with a Hitachi S-405A (Hitachi, Tokyo, Japan) microscope.

## Results

*Characterization of the Parental and Recombinant Viruses Used in This Study.* Recombinants of HSV-1 [F(MP)A, F(MP)B, F(MP)C, F(MP)D, F(MP)E, and F(MP)F] were produced by transfection of rabbit skin cells with a mixture of intact HSV-1(F) DNA and the BglII F fragment of HSV-1(MP) DNA (15) (Fig. 1). All of the recombinants were selected on the basis of their plaque phenotype in Vero and HEP-2 cells. Thus, recombinants F(MP)A, F(MP)B, F(MP)C, and F(MP)D produced plaques containing polykaryocytes (*syn* plaques) in both Vero and HEP-2 monolayer

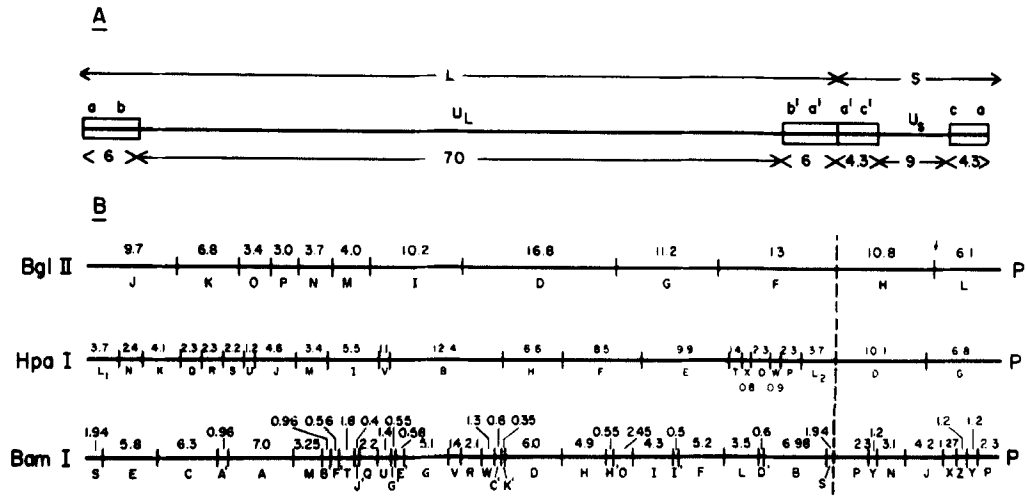


FIG. 1. Sequence arrangement and *BglII*, *HpaI*, and *BamHI* restriction endonuclease maps of the prototype arrangements of HSV-1 DNA. The vertical dashed line separates the large (L) and small (S) components of HSV-1 DNA. A, sequence arrangement. The number refers to percent of total DNA determined to be  $96 \times 10^6$  (17). The letters *ab*, *b'a'*, *a'c'*, and *ca* refer to the reiterated sequences flanking the largely unique sequences *U<sub>L</sub>* in the L component (*ab* and *b'a'*) and the *U<sub>s</sub>* in the S component (*a'c'* and *ca*). B, restriction endonuclease maps. The numbers above the fragment designations are in millions molecular weight.

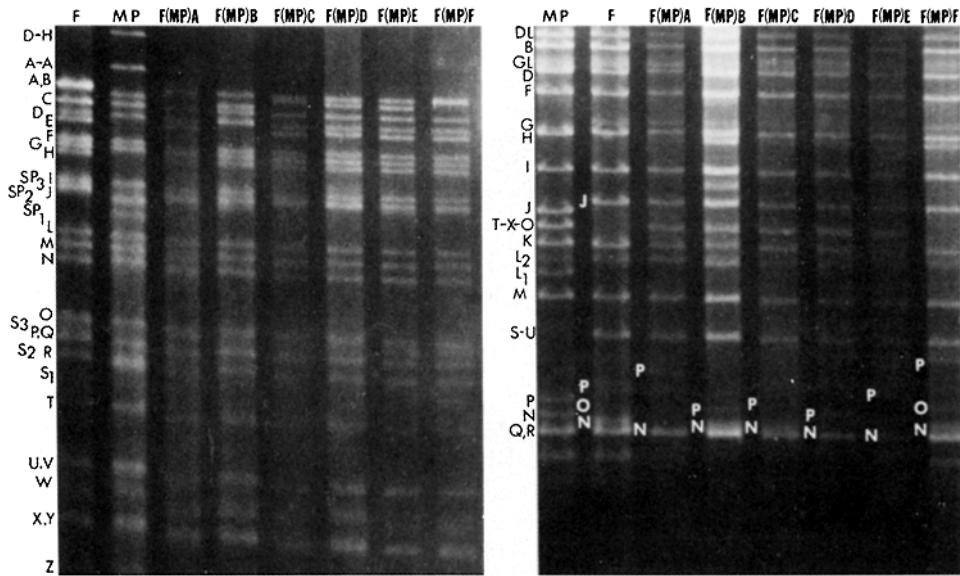


FIG. 2. Electrophoretic profiles of HSV-1 DNA cleaved with *BamHI* (left panel) and *HpaI* (right panel) restriction endonucleases. The DNA digests were subjected to electrophoresis in agarose gels and stained with ethidium bromide as described elsewhere (15, 16, 18). The fragments were designated according to the nomenclature described elsewhere (8). The L component terminal fragments and the junction fragments appear in several bands because of heterogeneity in the terminal sequence (6), and these bands have been designated numerically as *HpaI* L<sub>1</sub>, L<sub>2</sub>, *BamHI* S<sub>1</sub>, S<sub>2</sub>, S<sub>3</sub>, and SP<sub>1</sub>, SP<sub>2</sub>, SP<sub>3</sub>.

cultures characteristic of the HSV-1(MP) parent, whereas F(MP)E and F(MP)F produced *syn* plaques only in Vero cell cultures. F(MP)A, F(MP)B, F(MP)C, and F(MP)D resembled the HSV-1(MP) parent in that cells infected with these recombinants failed to accumulate the viral glycoprotein gC. In contrast, cells infected with F(MP)E and F(MP)F accumulated this glycoprotein (15).

Central to this report is the extent of replacement of HSV-1(F) DNA by the DNA sequences derived from the HSV-1(MP) virus. In an attempt to define the approximate domains of HSV-1(MP) DNA sequences in the recombinants, the parental and recombinant virus DNA were cleaved with several restriction endonucleases and electrophoretically separated in agarose gels. As shown in Fig. 2, HSV-1(MP) DNA lacks the BamHI cleavage sites between fragments A and A', D and H, and the HpaI cleavage sites between fragments T, X, and O, but contains an HpaI site between fragments S and U that is absent in HSV-1(F) DNA. In addition, the HSV-1(MP) fragment HpaI J migrates faster than the corresponding HSV-1(F) fragment. The recombinant F(MP)A, F(MP)B, F(MP)C, F(MP)D, and F(MP)E DNA exhibit the structural features of HSV-1(F) except for the fusion of T, X, and O fragments characteristic of HSV-1(MP) DNA. The DNA of recombinant F(MP)F does not exhibit this fusion. The data indicate, therefore, that the HSV-1(MP) sequences that replaced the HSV-1(F) DNA are either to the left of the HpaI T-X cleavage site or to the right of the HpaI X-O cleavage site. The HSV-1(MP) sequences replacing the HSV-1(F) DNA in all other recombinants encompass the HpaI, T, X, and O cleavage sites. Although the electrophoretic profiles indicate the source of these sequences in recombinant DNA, Locker and Frenkel (16) have shown that the BamHI B fragment is heterogeneous, and Tognon and Roizman (manuscript in preparation) have shown that the electrophoretic mobility of BamHI B and BamHI E fragments of HSV-1 clones derived from plaque-purified stocks may vary considerably, possibly because of loss or amplification of sequences contained in HpaI, N, and P fragments contained in the BamHI B and BamHI E fragments.

The characterization of the pattern of the ocular disease produced in the rabbit eye by a virus strain is apparent from clinical examination. The severity of the particular kind of disease is characterized by the size of the lesions on the cornea as well as by the duration of the disease process and the depth of tissue damage.

*Epithelial Disease.* The epithelial lesion of herpes simplex virus appears to be caused by direct cytotoxicity and cell destruction by the virus. The first result was that with the parent strains there was a marked difference in the morphology of the epithelial lesion. The MP strain produced relatively short but thick epithelial defects that were consistent and reliable in virtually every animal infected. The F strain produced elongate, filamentous, dendritic lesions. These strains could be separated reliably on the basis of their epithelial lesions, which were typical and specific for each parent strain (Fig. 3). The recombinant strains also produced lesions morphologically typical of each recombinant. The F(MP)A and F(MP)B recombinants produced elongate dendritic ulcers, and the F(MP)C produced tiny ulcers; F(MP)D produced thick ulcers, and F(MP)E strain produced both tiny and thick epithelial lesions. The F(MP)F recombinant produced no discernible typical pattern (Fig. 4). It is clear, then, that the epithelial lesions were determined by the viral genetics and were typical of each strain or recombinant studied and that the pattern was easily identifiable when examined on a masked (blind) basis (Table I). The clinical findings

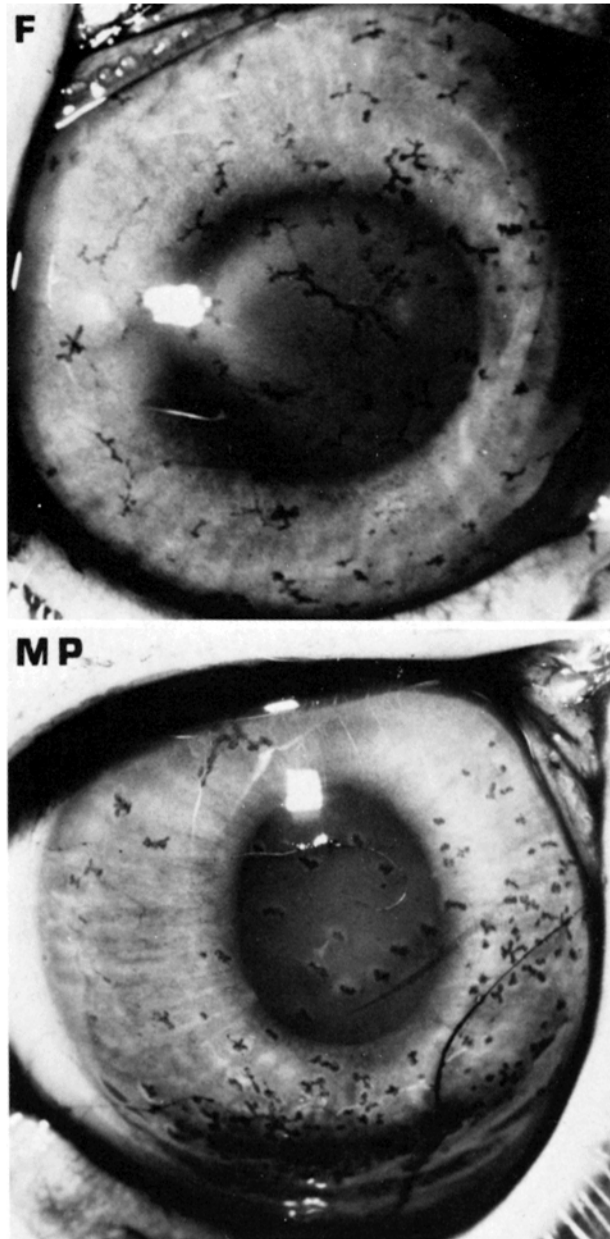


FIG. 3. Photomicrographs of rabbit eyes infected with HSV-1(MP) and HSV-1(F) at 5 d postinfection. The dendritic pattern of the HSV-1(F) strain consists of elongate filamentous lesions, whereas the HSV-1(MP) strain produced short, thick lesions.

characteristic of each strain were recognized more easily in the early stages after infection (2-7 d).

Further characterization of the dendritic pattern resulting from infection by the various strains was obtained with the scanning electron microscope. Figs. 5, 6, and 7

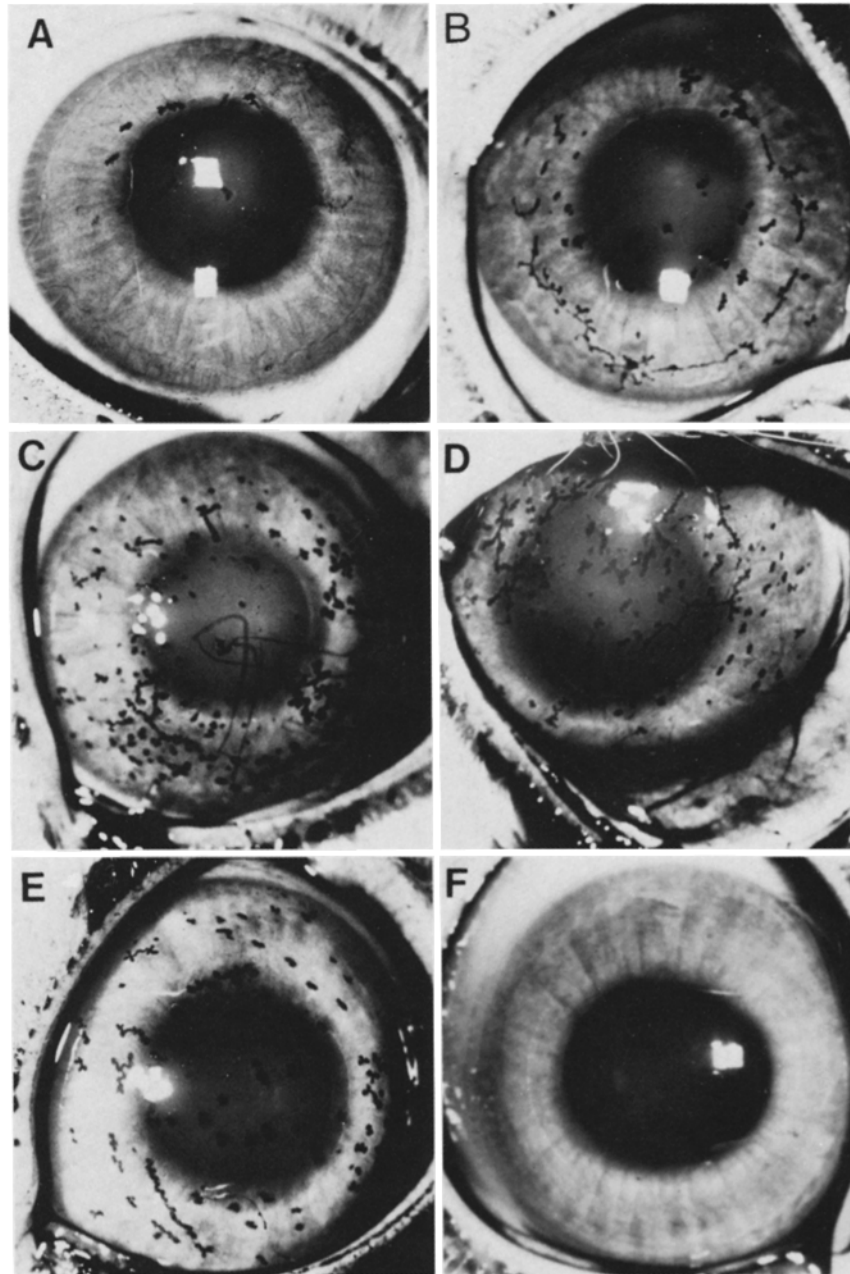


FIG. 4. Photomicrographs of rabbit eyes infected with HSV-1 recombinants. A and B, typically elongate dendrites produced by the F(MP)A and F(MP)B strains. C, tiny lesions caused by F(MP)C strain. D, thick dendrites caused by F(MP)D strain. E, mixture of tiny and thick dendrites caused by F(MP)E strain. F, the F(MP)F shows no disease. All photographs were taken at 5 d postinfection.

TABLE I  
*HSV Ocular Infection: Form of Epithelial Ulcer*

Strain	Dendritic pattern
Parent strain	HSV-1(MP) Short & thick
	HSV-1(F) Typically elongate
Recombinant strains	F(MP)A Typically elongate
	F(MP)B Typically elongate
	F(MP)C Tiny
	F(MP)D Thick
	F(MP)E Tiny, thick
	F(MP)F No pattern

illustrate the epithelial ulcer and dendritic pattern of each strain. Again, an observer who was ignorant of the identity of the infecting strain could characterize the dendritic lesion in a regular and reproducible fashion, indicating that the form and morphology of the lesions were determined by the genetics of the infecting strain.

Just as epithelial morphology varied, the severity of the disease also varied. The HSV-1(F) strain produced moderate to severe epithelial disease that cleared rapidly and was healed after eight days. The HSV-1(MP) strain produced mild epithelial disease, the exact duration of which could not be determined because of the high mortality. Mild epithelial disease was produced by the F(MP)A, F(MP)B, F(MP)C, and F(MP)D recombinants, whereas the F(MP)E strain produced moderately severe disease, and the F(MP)F recombinant produced virtually no observable disease (Table II). The epithelial disease produced by these recombinants lasted from 8 to 10 d, and was free of the mortality associated with infection by the MP strain.

*Stromal Disease.* Stromal disease seems to require colonization of the stromal keratocytes and probably the production of antigenic immunoreactive substances by the virus strain.

Classification of a strain as a stromal disease-producing virus is a function of both the number of infected eyes that develop edema and the persistence of that condition (Fig. 8; Table III). The HSV-1(MP) strain produced severe edema that persisted in all the infected eyes, whereas the HSV-1(F) strain produced sporadic episodes of minimal disease; only one animal showed disease for more than three observations (16%). The stromal disease produced by the recombinants was mild and did not progress to tissue necrosis or corneal vascularization. The disease produced by the F(MP)C and F(MP)E recombinants lasted a week, a persistence level intermediate between the parent HSV-1(F) and HSV-1(MP) strains. The F(MP)D recombinant produced rare, sporadic cases of stromal disease and was therefore similar to the HSV-1(F) parent. The disease produced by the F(MP)A and F(MP)B recombinants was transient, and the F(MP)F strain produced no stromal disease at all. Histologic examination indicated that the observed stromal disease included edema plus infiltration by inflammatory cells in the basal epithelial layer as well as direct damage and degeneration of the keratocytes in the anterior stroma. The severity of the histologic changes generally correlated with the clinical observations of stromal disease, whereas congestion indicating deep infection by the virus generally paralleled the incidence and severity of stromal disease. The presence of tiny or thick dendritic lesions was



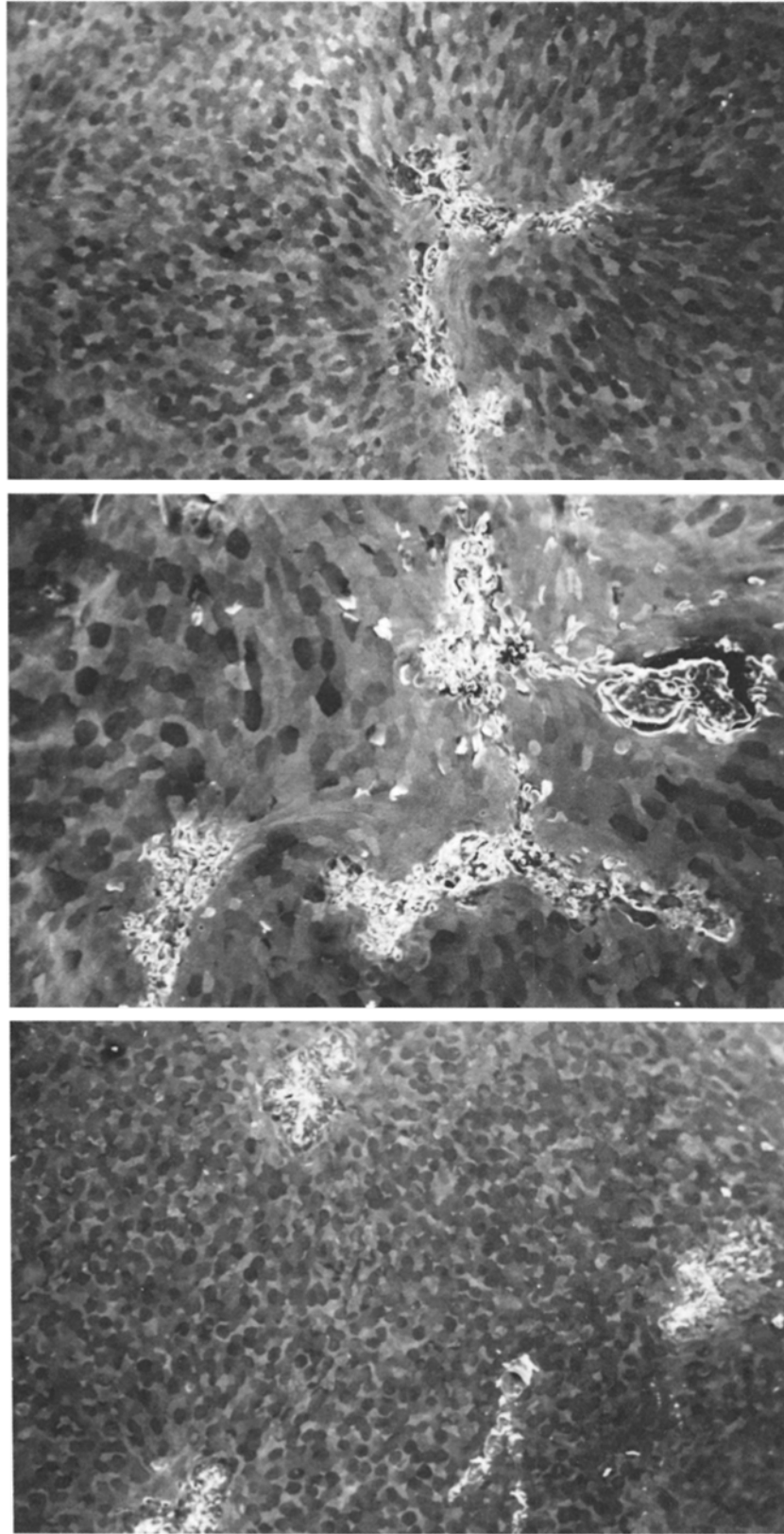


FIG. 5. Top, 7 d after infection with F(MP)A. Scanning electron micrograph. Typical dendritic ulcer is elongated and thin ( $\times 50$ ). Middle, 9 d after infection with F(MP)B, showing thin and relatively long dendritic ulcer. ( $\times 75$ ). Bottom, 7 d after infection with F(MP)C, showing short and tiny dendritic ulcer ( $\times 50$ ).

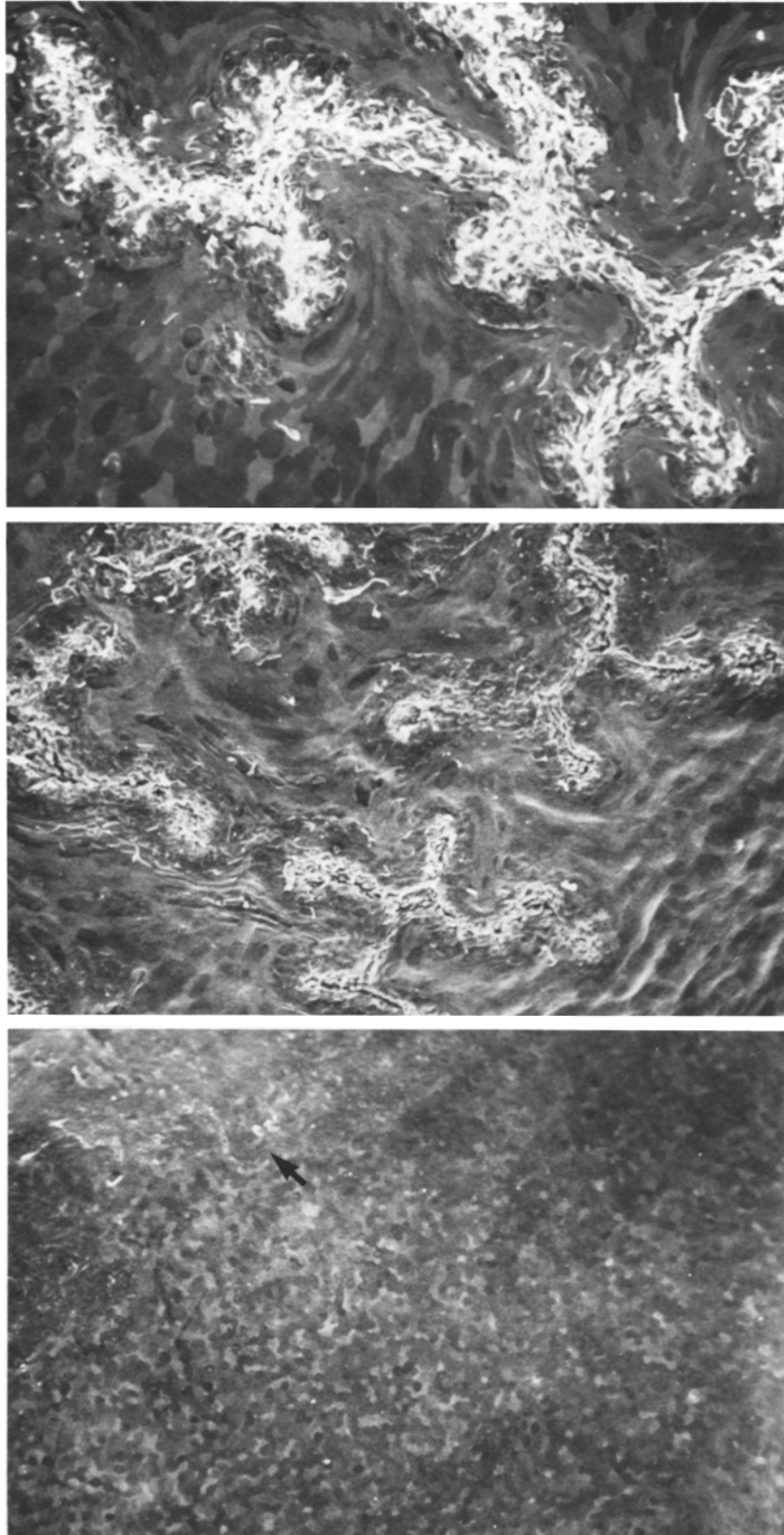


FIG. 6. Top, 5 d after infection with F(MP)D, showing thicker dendritic ulcer ( $\times 75$ ). Middle, 5 d after infection with F(MP)E, showing a short and thick dendritic ulcer ( $\times 75$ ). Bottom, 7 d after infection with F(MP)F, F(MP)F virus produces no discernible typical dendritic ulcer pattern. Some superficial damage (arrow) on the epithelial surface can be seen at the upper left ( $\times 50$ ).

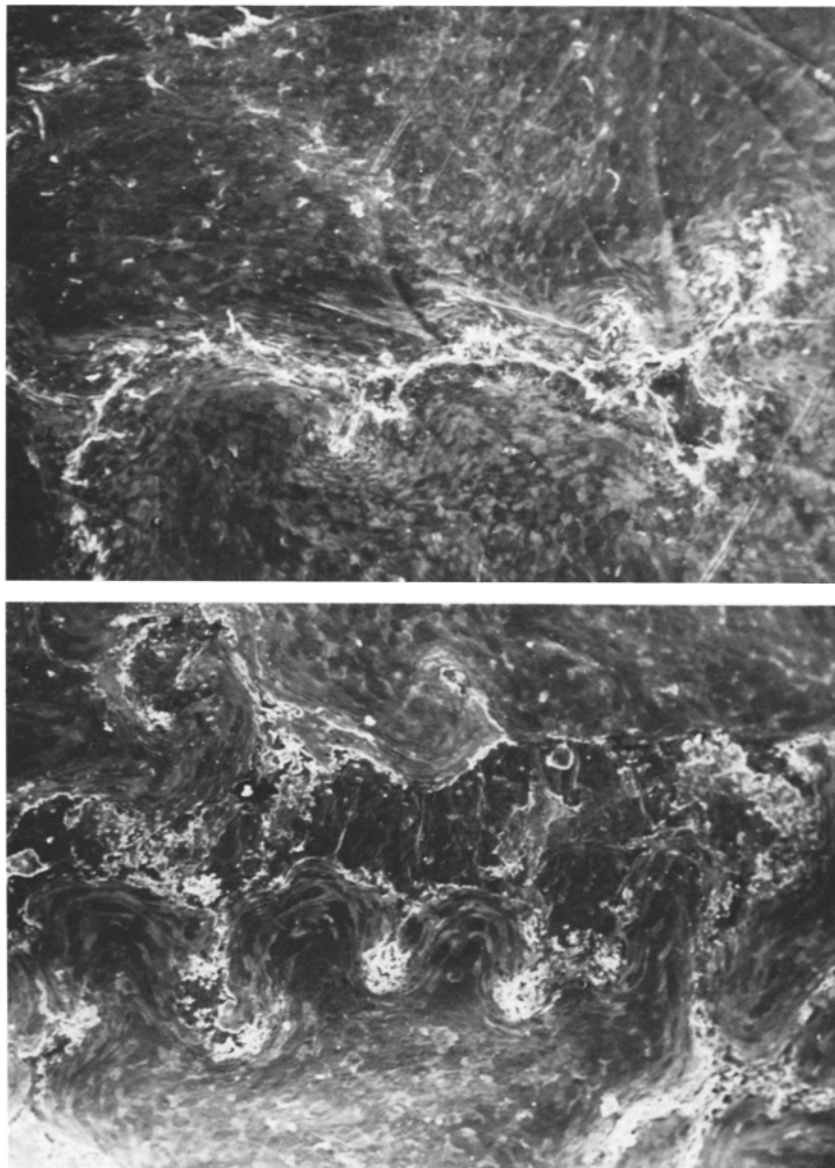


FIG. 7. Top, F strain virus, 9 d after infection. Dendritic ulcer is thin and long ( $\times 50$ ). Bottom, MP strain virus 7 d after infection. The MP virus produces thick dendritic ulcers that are shorter in the early stages of the disease ( $\times 50$ ).

associated with the presence and persistence of stromal disease, but stromal disease was not specifically correlated with the severity of the epithelial disease.

#### Discussion

In the investigations reported in this paper, we focused on the characteristics of ocular herpetic disease, i.e., (a) the characteristic morphology of the dendritic lesions, (b) the severity of epithelial disease, and (c) the incidence and duration of stromal

TABLE II  
*HSV Ocular Infection: Severity of Epithelial Disease*

Strain	Number of days postinfection				
	5	8	12	14	
Parent strains	MP	0.07*	0.79	0.33‡	—§
	F	1.83	0	0	0
Recombinant strains	F(MP)A	0.92	0.19	0.06	0
	F(MP)B	0.60	0.15	0	0
	F(MP)C	0.42	0.10	0.04	0
	F(MP)D	0.38	0.25	0.06	0
	F(MP)E	1.54	0.85	0	0
	F(MP)F	0.06	0.04	0	0

\* Day 3 for the MP strain.

‡ Day 10 for the MP strain,

§ 100% mortality.

Mean corneal epithelial disease scores of rabbits infected with several strains of HSV-1. 12 eyes were used per virus strain. The disease was graded as 0, if normal; 0.25, if one dendrite was present; 1, if ¼ of the epithelium was involved; 2, if ½ of the epithelium was involved.

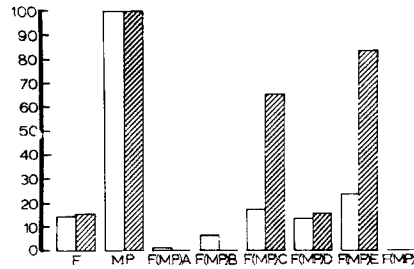


FIG. 8. Incidence of stromal disease in rabbits infected with various HSV-1 strains. □ represents the percentage of observations showing disease; ▨ represents the percentage of animals with disease present for more than two observations.

TABLE III  
*HSV Ocular Infection: Severity of Stromal Disease*

Strain	Number of days postinfection										
	5	8	12	14	16	19	21	23	26	29	
Parent strains	MP	0	0.39	1.67*	—†	—†	—†	—†	—†	—†	
	F	0.08	0.82	0.20	0.4	0.2	0	0.20	0.20	0	0
Recombinant strains	F(MP)A	0	0	0.08	0	0.17	0	0	0	0	0
	F(MP)B	0	0	0.33	0.17	0.17	0.2	0	0	0	0.10
	F(MP)C	0	0	0.08	0.25	0.50	0.42	0.42	0.58	0.50	0.25
	F(MP)D	0	0	0	0	0.38	0.25	0.50	0.50	0.75	0.13
	F(MP)E	0	0	0.33	1.0	0.92	0.75	0.58	0.33	0.25	0.25
	F(MP)F	0	0	0	0	0	0	0	0	0	0

\* Day 10 for the MP strain.

† 100% mortality.

Mean corneal stromal disease scores of rabbits infected with several strains of HSV-1. The numbers represent the mean of 12 eyes. The disease was graded as 0.50, minimal stromal edema; 1, mild edema with iris detail still visible; 2, edema, infiltrate or scarring sufficient to obscure iris detail; and 4, totally opaque cornea.

disease. Our studies show that transfer of genetic information from a defined region of the genome of a (donor) virus that causes stromal involvement to the genome of a (recipient) virus that causes an epithelial pattern of disease yielded recombinant viruses that display one or more characteristics of the ocular disease pattern of the donor virus.

Specifically, our results show that recombinant F(MP)D produced a pattern of dendritic lesions characteristic of the donor HSV-1(MP) virus, and only recombinants F(MP)A and F(MP)B produced the typical elongated dendritic lesions characteristic of the recipient HSV-1(F). Recombinants F(MP)C and F(MP)E produced a stromal disease approaching in severity that produced by the donor HSV-1(MP) strain, although all recombinant strains except F(MP)F produced some episodes of stromal disease.

These results suggest that in the experimental model we have used, (a) the characteristic morphology of the dendritic lesions and the severity and incidence of stromal disease are genetically determined by the virus; (b) the viral functions affecting the ocular disease pattern map between 0.70 and 0.83 map units in HSV-DNA within the BgIII F DNA fragment; (c) the functions affecting these aspects of ocular disease segregate, although they may be closely linked; and (d) the patterns of ocular disease investigated in this study are independent of the production of glycoprotein C or of the ability of recombinants to fuse Vero cells or both Vero and HEp-2 cells. This conclusion is readily apparent from the observation that F(MP)C and F(MP)E produce stromal disease but differ with respect to the production of glycoprotein C and fusion of infected HEp-2 cells. The glycoprotein C-deficient recombinants [F(MP)A and F(MP)B] produced type F, elongate epithelial ulcers but the others, [F(MP)C and F(MP)D], produced short, thick, or tiny ulcers. Our results are consistent with, and experimentally verify, the observations that the ocular disease patterns produced by wild virus isolates may vary and are characteristic of each isolate (5).

The specific functions encoded in the BgIII F fragment that could account for the ocular disease patterns described in this study have not been identified. Furthermore, we cannot exclude the possibility that viral functions encoded elsewhere in the genome also affect ocular disease. We should note, however, that the production of epithelial lesions probably reflects the ability of the virus to replicate and spread through the epithelial layer, whereas the development of stromal disease is probably related to the penetration of the virus or its gene products into the stroma. The determinants of the growth and spread of the virus in epithelial cells and stroma may be a function of both the surface structural proteins of the virus and nonstructural proteins affecting viral replication. To date, no surface structural proteins have been definitively mapped to within the BgIII F fragment. We cannot exclude the possibility that subsurface viral proteins such as envelope matrix proteins are encoded in that region of viral DNA and that these products may affect the virulence of the virus.

This study represents the first attempt to define the viral functions responsible for the disease patterns caused by herpes simplex virus. The results indicate that genetic manipulation of the viral genome might help define the specific functions responsible for ocular disease and possibly for other disease manifestations caused by these viruses.

### Summary

The pattern of ocular disease produced in the rabbit eye by HSV-1(F) and HSV-1(MP) strains and recombinants F(MP)A, F(MP)B, F(MP)C, F(MP)D, F(MP)E, and

F(MP)F was studied. The characteristics of ocular herpetic disease such as morphology of dendritic ulcers, severity of epithelial disease and incidence and duration of stromal disease produced in the rabbit eye are genetically determined by the virus strain. Our studies show that transfer of a defined part of the genome of the stromal disease-producing virus, HSV-1(MP), to the genome of an epithelial disease-producing virus, HSV-1(F), yielded recombinants with one or more of the disease characteristics of the donor strain. Specifically, recombinant F(MP)D produced lesions characteristic of the donor HSV-1(MP) strain; recombinants F(MP)C and F(MP)E produced stromal disease approaching the severity of the disease produced by the donor HSV-1(MP) strain, and only recombinants F(MP)A and F(MP)B retained the typically elongate lesions of the recipient HSV-1(F), whereas the recombinant strain F(MP)F produced no disease. The viral functions pertaining to the ocular disease pattern map between 0.70 and 0.83 map units in HSV-1 DNA within the BglII F DNA fragment. The pattern of stromal disease is independent of the production of glycoprotein C and fusion of HEp2-infected cells. The functions relating to these aspects of ocular disease segregate but are closely linked.

*Received for publication 31 August 1981.*

### References

1. Dawson, C. R., and B. Togni. 1976. Herpes simplex eye infections: clinical manifestations, pathogenesis and management. *Surv. Ophthalmol.* **21**:121.
2. McNeill, J. I. 1979. Host defenses in ocular herpesvirus infections. *In* Current Concepts in Ophthalmology. H. E. Kaufman and T. J. Zimmerman, editors. The C. V. Mosby Company, St. Louis, Mo. **6**:200.
3. Centifanto, Y. M. 1979. Host resistance in recurrent herpes simplex infections: cell mediated immunity. *In* Current Concepts in Ophthalmology. H. E. Kaufman and T. J. Zimmerman, editors. The C. V. Mosby Company, St. Louis, Mo. **6**:28.
4. Metcalf, J. F., and H. E. Kaufman. 1976. Herpetic stromal keratitis—evidence for cell-mediated immunopathogenesis. *Am. J. Ophthalmol.* **82**:827.
5. Wander, A. H., Y. M. Centifanto, and H. E. Kaufman. 1980. Strain specificity of clinical isolates of herpes simplex virus. *Arch. Ophthalmol.* **98**:1458.
6. Sery, T. W., R. M. Nagy, and R. Nazario. 1972/1973. Experimental disciform keratitis. II. Local cornea hypersensitivity to a highly virulent strain of herpes simplex. *Ophthalmic Res.* **4**:99.
7. Irvine, A. R., and S. J. Kimura. 1967. Experimental stromal herpes simplex keratitis in rabbits. *Arch. Ophthalmol.* **78**:654.
8. Metcalf, J. F., J. I. McNeill, and H. E. Kaufman. 1976. Experimental disciform edema and necrotizing keratitis in the rabbit. *Invest. Ophthalmol.* **15**:979.
9. Hoggan, M. D., and B. Roizman. 1959. The isolation and properties of a variant of herpes simplex producing multinucleated giant cells in monolayer cultures in the presence of antibody. *Am. J. Hyg.* **70**:208.
10. Taktikos, A., and L. Aurelian. 1966. Experimental study of the disease of the corneal stroma caused by herpes simplex virus. *Am. J. Ophthalmol.* **62**:1136.
11. Metcalf, J. F., D. S. Hamilton, and R. W. Reichert. 1979. Herpetic keratitis in athymic mice (nude mice). *Infect. Immun.* **26**:1164.
12. Keller, J. M., P. G. Spear, and B. Roizman. 1970. The proteins specified by herpes simplex virus. III. Viruses differing in their effects on the social behavior of infected cells specify different membrane glycoproteins. *Proc. Natl. Acad. Sci. U. S. A.* **65**:865.

13. Heine, H. W., R. W. Honess, E. Cassai, and B. Roizman. 1974. Proteins specified by herpes simplex virus. XII. The virion polypeptides of type 1 strains. *J. Virol.* **14**:640.
14. Ejercito, P. M., E. D. Kieff, and B. Roizman. 1968. Characterization of herpes simplex virus strains differing in their effect on social behavior of infected cells. *J. Gen. Virol.* **3**:357.
15. Ruyechan, W. T., L. S. Morse, D. M. Knipe, and B. Roizman. 1979. Molecular genetics of herpes simplex virus. II. Mapping of the major viral glycoproteins and of the genetic loci specifying the social behavior of infected cells. *J. Virol.* **29**:677.
16. Locker, H., and N. Frenkel. 1979. BamI, KpnI, and SaII restriction enzyme maps of the DNAs of herpes simplex virus strains Justin and F.: occurrence of the heterogeneities in defined regions of the viral DNA. *J. Virol.* **32**:429.
17. Wadsworth, S. C., R. J. Jacob, and B. Roizman. 1975. Anatomy of herpes simplex virus DNA. II. Size, composition and arrangement of inverted terminal repetitions. *J. Virol.* **15**:1487.
18. Jones, P. C., G. S. Hayward, and B. Roizman. 1977. Anatomy of herpes simplex virus DNA. VI. Alpha RNA is homologous to non-contiguous sites in both L and S components of viral DNA. *J. Virol.* **21**:268.