

Metastatic Brachial Plexopathy with Brain and Spinal Metastasis in a Case of Recurrent Breast Carcinoma Demonstrated on ¹⁸F-FDG PET/CT

Abstract

We report a case of a 56-year-old woman diagnosed with infiltrating ductal carcinoma of the left breast, who had undergone left modified radical mastectomy followed by radiotherapy and adjuvant chemotherapy. FDG PET-CT showed metastatic brachial plexopathy with intra-spinal and extra-axial brain metastasis. Metastatic brachial plexopathy along with brain and spinal metastasis is a rare condition with very less incidence. The scan also showed left para-sternal anterior chest wall recurrence with antero-superior mediastinal metastasis. ¹⁸F-FDG-PET scanning is a useful tool in evaluation of patients with suspected metastatic plexopathy. It may also be useful in distinguishing between radiation-induced and metastatic plexopathy. Typical pattern of FDG uptake and dual time point imaging may increase specificity and require further evaluation.

Key words: *Metastatic brachial plexopathy, spinal metastasis, FDG-PET, carcinoma breast*

**Sunny J. Gandhi,
Bhavdeep Rabadiya¹**

*Nuclear Medicine Physician,
¹Radiologist, Infocus Diagnostics,
Ahmedabad, Gujarat, India*

Introduction

Common sites of breast cancer metastases include regional lymph nodes, bones, liver, lungs and brain. Brachial plexopathy is a rare condition with an incidence of less than 0.5%. Metastatic breast and lung cancers are the most common non-traumatic causes of brachial plexopathy, after radiation induced fibrosis.^[1] Because one of the major lymphatic drainage of the breast is through the apex of the axilla, it is not uncommon for metastatic breast cancer to invade the brachial plexus.^[2] Metastatic lymphadenopathy may encase the neurovascular bundle, resulting in vascular or neural symptoms.

Case Report

A 56-year-old woman diagnosed with infiltrating ductal carcinoma of the left breast had undergone left modified radical mastectomy followed by radiotherapy and adjuvant chemotherapy. She presented to her oncologist with left para sternal chest wall recurrence with restriction of movement of the left upper limb. The patient was referred for ¹⁸F-FDG PET/CT to evaluate the extent of recurrent/metastatic disease. Whole-body contrast enhanced PET/CT was acquired 1 hour

following the intravenous injection of 296 MBq of ¹⁸F-FDG on PET CT Discovery 600, with 16 slice CT scanner. The scan showed ill-defined heterogeneously enhancing hypermetabolic soft tissue along left brachial plexus [Figure 1] with intra-spinal extension through neural foramina at C5-C6 & C6-C7 levels on the left side [Figure 2] along with few ill -defined intra-spinal enhancing lesions at D4-D5, D7-D8 & D8-D9 levels [Figure 3] and heterogeneously enhancing extra-axial lesion in left C-P angle region [Figure 4]. The scan also showed heterogeneously enhancing ill-defined soft tissue lesion in subcutaneous plane in left para-sternal region in anterior chest wall at 1st intercostal space [Figure 5] along with soft

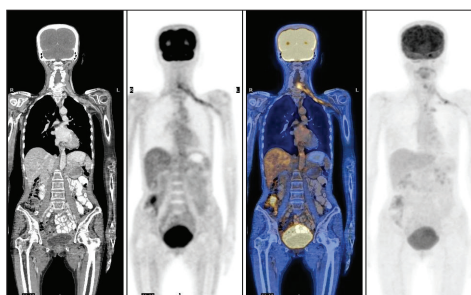


Figure 1: Maximum intensity projection (MIP) and coronal ¹⁸F-FDG PET-CT images show linear extension of tracer activity from superomedial aspect (supra/infraclavicular) to lateral aspect of the left axilla.

This is an open access article distributed under the terms of the Creative Commons Attribution-Non Commercial-Share Alike 3.0 License, which allows others to remix, tweak, and build upon the work non-commercially, as long as the author is credited and the new creations are licensed under the identical terms.

For reprints contact: reprints@medknow.com

How to cite this article: Gandhi SJ, Rabadiya B. Metastatic brachial plexopathy with brain and spinal metastasis in a case of recurrent breast carcinoma demonstrated on ¹⁸F-FDG PET/CT. Indian J Nucl Med 2017;32:118-21.

Address for correspondence:

*Dr. Sunny J. Gandhi,
Infocus Diagnostics, Swastik
Society, Opp. Vipul Dudhiya,
Navrangpura, Ahmedabad, India.
E-mail: gndsunny@gmail.com*

Access this article online

Website: www.indjso.org

DOI: 10.4103/0972-3919.202252

Quick Response Code:



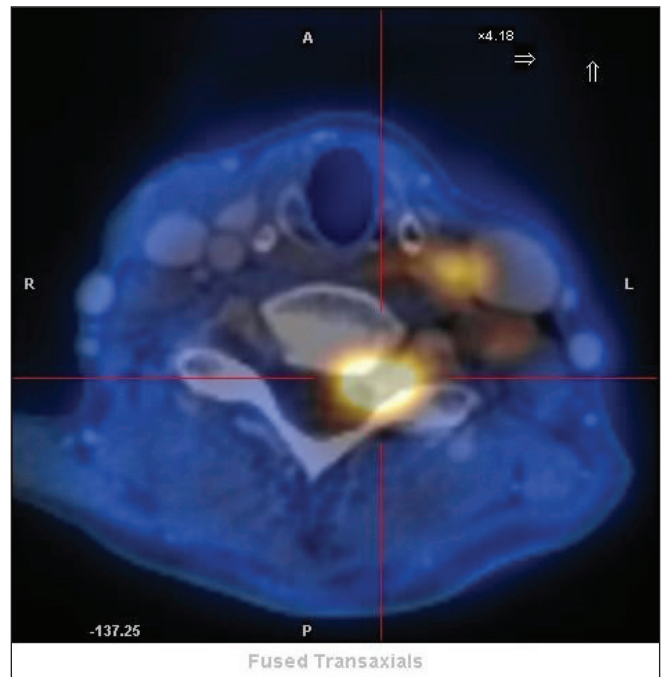
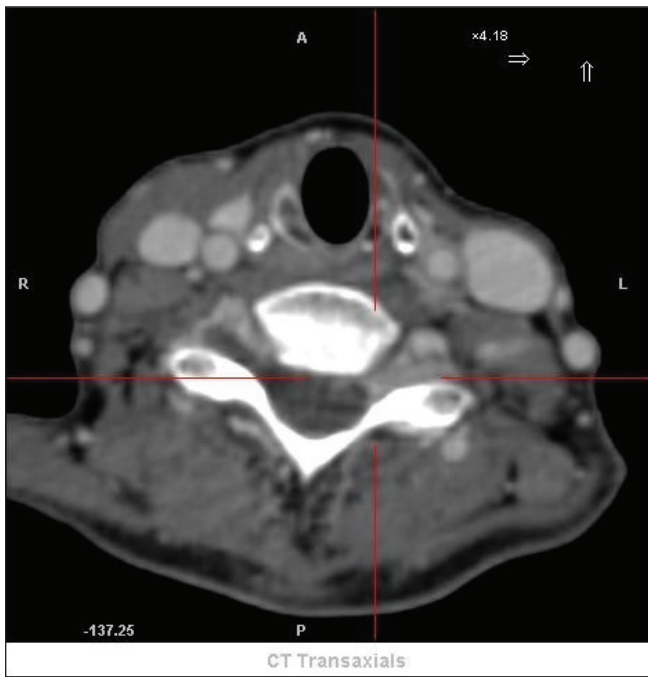


Figure 2: Ill-defined heterogeneously enhancing hypermetabolic soft tissue along left brachial plexus with intra-spinal extension through neural foramina at C5-C6 and C6-C7 levels on left side.

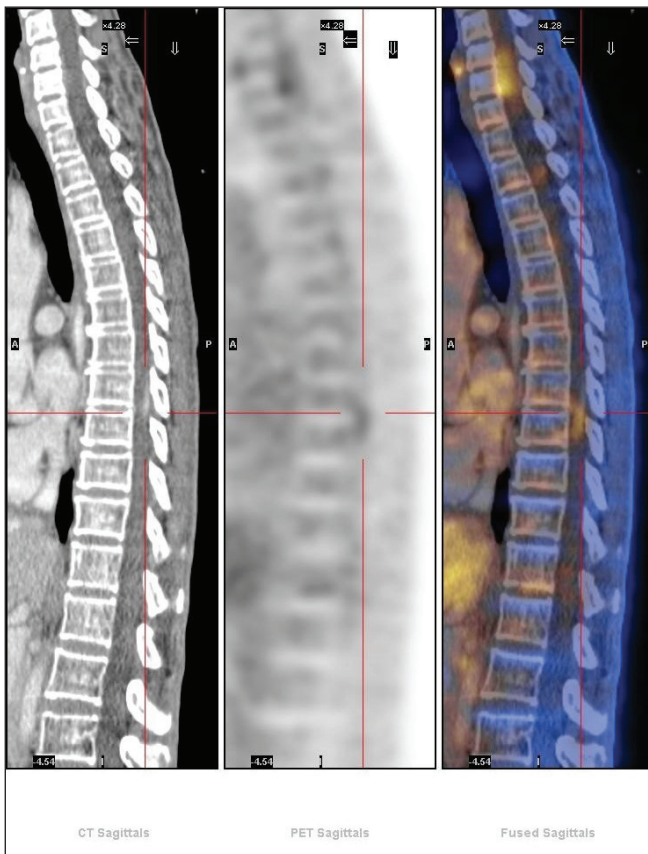


Figure 3: FDG avid ill-defined intra-spinal enhancing lesions at D8-D9 level.

tissue in antero-superior mediastinum extending along left proximal common carotid artery [Figure 6].

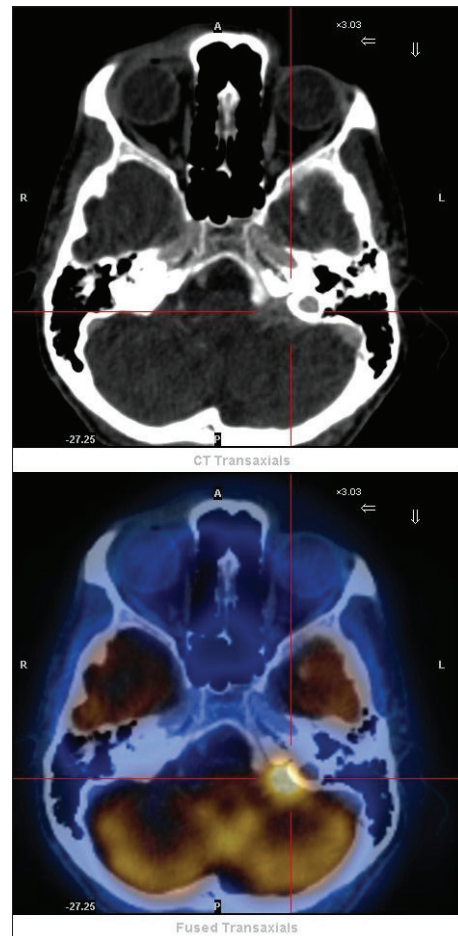
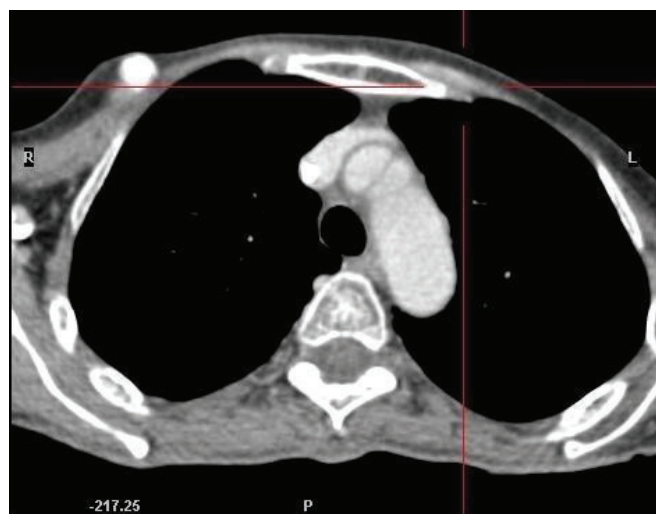
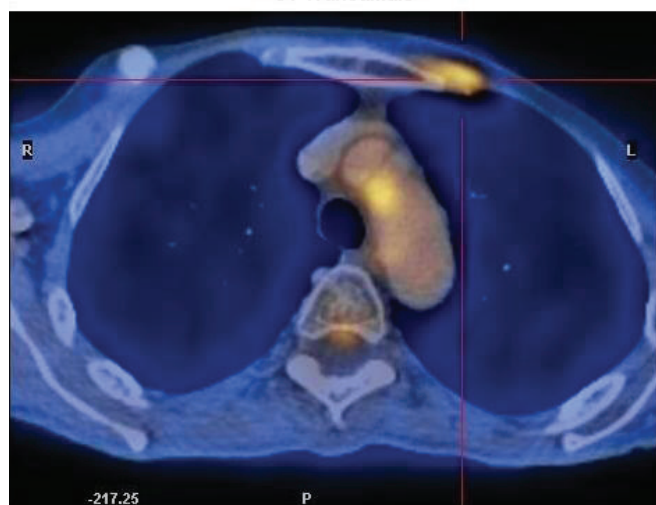


Figure 4: FDG avid heterogeneously enhancing extra-axial lesion in left C-P angle region.



CT Transaxials



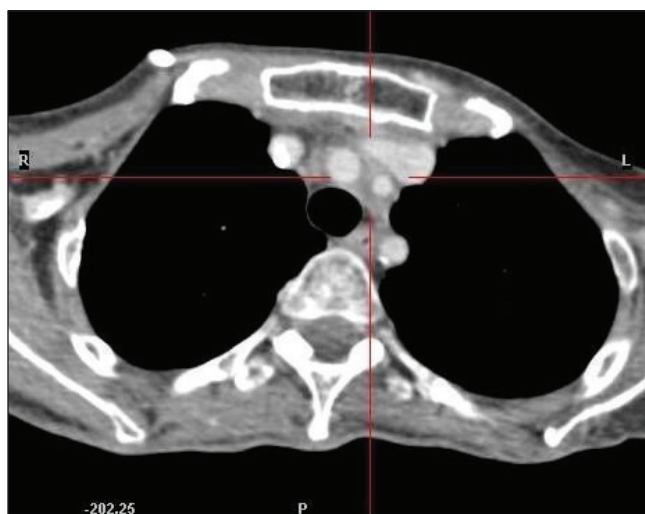
Fused Transaxials

Figure 5: FDG avid heterogeneously enhancing ill-defined soft tissue lesion in subcutaneous plane in left para-sternal region in anterior chest wall at 1st intercostal space.

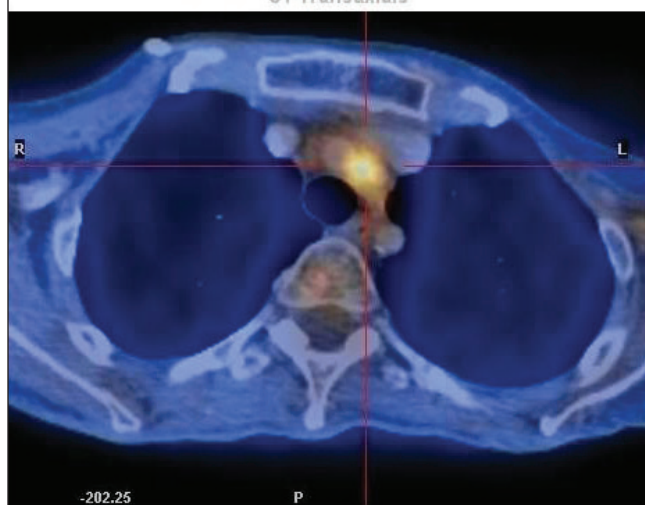
Discussion

The two major causes of brachial plexopathy in breast cancer patients are metastatic invasion of and radiation damage to the plexus.^[3,4] Differentiation between the two pathologies is important to plan treatment optimally. It is difficult to image because of complicated anatomy of the plexus and its immediate anatomical relationship to blood and lymphatic vessels.

Computerized tomography scanning has been used to assess the brachial plexus^[5,6] but it has several limitations. The neurovascular bundle of the axillary artery and brachial plexus may appear as a single structure when the administration of contrast medium is poorly timed.^[7] In a series of 46 patients with proven metastatic plexopathy, 11% of patients had normal CT scans.^[4] A Ahmad *et al* also had either normal CT or the appearance of minimal thickening of the brachial plexus in 6 cases out of the



CT Transaxials



Fused Transaxials

Figure 6: FDG avid soft tissue in antero-superior mediastinum extending along left proximal common carotid artery.

total 11 cases in their study.^[8] Minimal thickening can be related to previous surgery or radiotherapy. All these cases were positive on FDG PET. Furthermore, CT is not able to differentiate tumor infiltration from radiation fibrosis.^[4]

MRI has been claimed to be the test of choice in evaluating brachial plexopathy. Its superiority to CT scanning relates to its ability to differentiate more accurately nerves from surrounding vessels and soft tissues. Review of the literature suggests that there is no doubt that MRI can delineate both the normal and abnormal anatomy of the brachial plexus in more detail than CT scan. There are conflicting data on distinction between radiation and neoplastic plexopathy using MRI. Some studies have shown that tumor recurrence has a higher signal intensity than radiation fibrosis on T2-weighted images,^[7,9] although other authors have reported increased T2 signal in both metastatic and radiation plexopathy patients.^[10]

FDG-PET is a useful imaging technique to study the brachial plexus in breast cancer

patients and that it may be useful to monitor treatment efficacy as well. The current data is insufficient to suggest unequivocally that FDG-PET may be useful in distinguishing neoplastic from radiation plexopathy. Typical pattern has been advocated for detecting metastatic brachial plexopathy.^[11] Maximum intensity projection (MIP) and coronal 18F-FDG PET/CT images show linear extension of tracer activity from superomedial aspect (supra/infraclavicular) to lateral aspect of the axilla closely related to the subclavian/axillary vessels. Dual time point imaging may have some role in this scenario and further work in this area may be proved useful.

Financial support and sponsorship

Nil

Conflicts of interest

There are no conflicts of interest

References:

1. Wood JJ, Gawler J, Whittle RJ, Staunton MD. Brachial plexopathy in breast carcinoma - An unsolved problem. *Eur J Surg Oncol* 1991;17:265-9.
2. Wittenberg KH, Adkins MC. MR imaging of nontraumatic brachial plexopathies: Frequency and spectrum of findings. *Radiographics* 2000;20:1023-32.
3. Bagley FH, Walsh JW, Cady B, Salzman FA, Oberfield RA, Pazianos AG. Carcinomatous versus radiation-induced brachial plexus neuropathy in breast cancer. *Cancer* 1978;41:2154-157.
4. Cascino TL, Kori S, Krol G, Foley KM. CT of the brachial plexus in patients with cancer. *Neurology* 1983;33:1553-557.
5. Cooke J, Cooke D, Parsons C. The anatomy and pathology of the brachial plexus as demonstrated by computed tomography. *Clin Radiol* 1988; 39:595-601.
6. Moskovic E, Curtis S, A'Hern RP, Harmer CL. The role of diagnostic CT scanning of the brachial plexus and axilla in the follow-up of patients with breast cancer. *Clin Oncol (R Coll Radiol)* 1992;4:74-77.
7. Rapaport S, Blair DN, McCarthy SM, Desser TS. Brachial plexus: Correlation of MR imaging with CT and pathological findings. *Radiology* 1988;167:161-5.
8. Ahmad A, Barrington S, Maisey M, Rubens RD. Use of positron emission tomography in evaluation of brachial plexopathy in breast cancer patients. *Br J Cancer* 1999;79:478-82.
9. Glazer HS, Lee JK, Levitt RG, Heiken JP, Ling D, Totty WG, *et al.* Radiation fibrosis: Differentiation from recurrent tumor by MR imaging. *Radiology* 1985; 156:721-26.
10. Thyagarajan D, Cascino T, Harms G. Magnetic resonance imaging in brachial plexopathy of cancer. *Neurology* 1995;45:421-27.
11. Tripathi Madhavi, Das Chandan J. Srivastava Anurag, Bal ChandraSekhar, Malhotra Arun, Metastatic Brachial Plexopathy in a case of Recurrent Breast Carcinoma demonstrated on 18F-FDG PET/CT Nucl Med Mol Imaging. 2014;48:85-86.