

# Glomus Tumors and Neurofibromatosis: A Newly Recognized Association

Bridget Harrison, MD  
Douglas Sammer, MD

**Background:** Glomus tumors are painful benign tumors arising from the neuromyoarterial elements of the glomus body, typically in a subungual location. Historically, glomus tumors have been considered isolated or sporadic, not typically associated with other disease processes. Over the last few years, however, multiple case reports, a molecular genetics study, and an epidemiologic study have confirmed an association between type I neurofibromatosis and glomus tumors. The purpose of this review is to summarize the existing information about the association between neurofibromatosis and glomus tumors and to determine whether glomus tumors that are associated with neurofibromatosis differ from isolated glomus tumors in terms of tumor number, location, and sex distribution.

**Methods:** A PubMed, Ovid Medline, and Cochrane Database search was performed using the terms “glomus tumor,” “glomus tumour,” and “glomangioma” each combined with the search term “neurofibromatosis.” Fifteen English language articles were included. Information about the molecular genetics, patient sex, number of tumors per patient, and tumor location were recorded.

**Results:** A total of 36 patients with glomus tumors and neurofibromatosis have been reported in the literature. Seventy-nine percent were female. Tumors were multifocal in 32% of patients, with an average of 1.4 glomus tumors per patient. Glomus tumors arose in a nonsubungual location in 38% of patients.

**Conclusions:** A strong association between type I neurofibromatosis and glomus tumors has been identified. In neurofibromatosis patients with glomus tumors, the sex distribution, tumor location, and tumor burden appear similar to those in patients with isolated glomus tumors. Treating providers should be aware of this association to facilitate prompt diagnosis and treatment. (*Plast Reconstr Surg Glob Open* 2014;2:e214; doi: 10.1097/GOX.0000000000000144; Published online 15 September 2014.)

**G**lomus tumors are exquisitely painful benign tumors of the glomus body, a neuromyoarterial structure that exists in high concentrations

in the fingertips, and is involved in thermoregulation. Glomus tumors are usually solitary and often arise in a subungual location, although multifocal disease and nonsubungual presentation are not uncommon. They occur more commonly in women and usually occur in the fourth decade of life. Historically, they have been considered isolated sporadic tumors, not associated with other disease processes.

Recently, however, multiple case reports, a molecular genetics study, and an epidemiologic study have confirmed that type I neurofibromatosis is associated with glomus tumors. Type I neurofibroma-

*From the Department of Plastic Surgery, University of Texas Southwestern Medical Center, Dallas, Tex.*

*Received for publication November 3, 2013; accepted June 3, 2014.*

*Copyright © 2014 The Authors. Published by Lippincott Williams & Wilkins on behalf of The American Society of Plastic Surgeons. PRS Global Open is a publication of the American Society of Plastic Surgeons. This is an open-access article distributed under the terms of the Creative Commons Attribution-NonCommercial-NoDerivatives 3.0 License, where it is permissible to download and share the work provided it is properly cited. The work cannot be changed in any way or used commercially.*

DOI: 10.1097/GOX.0000000000000144

**Disclosure:** *The authors have no financial interest to declare in relation to the content of this article. The Article Processing Charge was paid for by the authors.*

tosis (formerly von Recklinghausen’s disease) is a rare genetic condition with an incidence of approximately 1 in 3000 (Table 1). Although the presentation can vary, it often results in multiple cutaneous neurofibromas or large plexiform neurofibromas. Although several benign and malignant tumors have been associated with type I neurofibromatosis, until recently, glomus tumors have not been believed to be part of the tumor spectrum in patients with neurofibromatosis.

Despite the fact that plastic surgeons treat both glomus tumors and neurofibromatosis patients, this association has not been well described in the plastic surgery literature. The purpose of this review is to summarize the existing literature on the association between glomus tumors and type I neurofibromatosis and to characterize glomus tumors that present in patients with neurofibromatosis in terms of sex distribution, tumor location, and tumor burden.

### METHODS

PubMed, Ovid (MEDLINE), and Cochrane database searches limited to English language publications using the terms “glomus tumor,” “glomus tumour,” “glomangioma,” and “neurofibromatosis” were performed. Additional articles were also identified by a manual reference search of relevant articles generated by the database searches. Articles that were nonrelevant or duplicative were excluded, and a single article that was not accessible was also excluded.<sup>1</sup> Figure 1 provides details of the systematic database search. A total of 15 articles were included in the review (Table 2). Information about the strength and the genetics of the association was recorded. Data on patient sex, tumor location, and number of tumors were recorded.

### RESULTS

A total of 36 patients with neurofibromatosis and glomus tumors were identified. Among the reports that included data on patient sex, 79% were female. Among the reports that included data on the number of tumors per patient, there was an average of

1.4 glomus tumors per patient, with 32% of patients having multifocal tumors. Among the reports that described tumor location, 62% of patients had tumors that arose in a subungual location and 38% of patients had nonsubungual tumors. Table 3 summarizes the data obtained from the case reports.

### DISCUSSION

In 1938, Klaber<sup>2</sup> provided the first report of a glomus tumor arising in a patient with neurofibromatosis. In this report, a “blue nodule” was excised from the right calf of a 13-year-old girl with type I neurofibromatosis. She was also noted to have similar soft blue nodules on the neck and left heel that were tender to deep pressure. The literature contains no further reports of glomus tumors in patients with neurofibromatosis until 1995, when Sawada et al<sup>3</sup> reported 3 patients with type I neurofibromatosis and subungual glomus tumors. Between 1995 and 2013, 13 more case reports described glomus tumors arising in the setting of type I neurofibromatosis. Although many of the authors speculated about the possibility of an association, it was not confirmed until 2009.

In 2009, Brems et al<sup>4</sup> defined the genetics of the association between glomus tumors and type I neurofibromatosis. Type I neurofibromatosis is an autosomal dominant condition caused by loss or inactivation of 1 allele of the tumor suppressor gene *NFI*. The authors demonstrated that glomus tumors that arise in patients with type I neurofibromatosis are due to biallelic inactivation of the *NFI* gene, or a “second hit” that occurs specifically within the  $\alpha$ -smooth muscle actin–positive cells of the glomus body. Interestingly, even though these glomus tumors are histologically identical to isolated, sporadic glomus tumors, isolated glomus tumors do not exhibit the same *NFI* mutations.

In 2013, Harrison et al<sup>5</sup> performed a case–control epidemiologic study in which a cohort of patients who had undergone glomus tumor excision were compared with a similar cohort of patients who had undergone excision of other benign hand lesions. Twenty-nine percent of patients who had undergone glomus tumor excision were found to carry the diagnosis of neurofibromatosis, whereas none of the patients in the control cohort had neurofibromatosis, resulting in a calculated odds ratio of 168:1. Although the number of patients in this study was low, it does support a strong epidemiologic association between neurofibromatosis and glomus tumors. It should be noted, however, that even though the association between glomus tumors and type I neurofibromatosis is strong, it would probably be more

**Table 1. Neurofibromatosis Type I Diagnostic Criteria: 2 of the following Criteria Needed for Diagnosis**

Two or more neurofibromas, or 1 plexiform neurofibroma
Axillary or groin freckling
Six or more café au lait spots (>5 mm in prepubertal or >15 mm in postpubertal)
Sphenoid dysplasia or thinning of cortex of long bones
Lisch nodules
Optic nerve tumors
First-degree relative with <i>NFI</i>

**Table 2. Data from the 15 Articles Included in the Systematic Review**

Article	Author	Year	No. Patients	Male	Female	Mean Age	No. Tumors	Subungual
Morbus Recklinghausen with glomoid tumors	Klaber <sup>2</sup>	1938	1		X	13	1	No
Three cases of subungual glomus tumors with von Recklinghausen neurofibromatosis	Sawada et al <sup>3</sup>	1995	3	X	X	45	5	Yes
					X	31	1	Yes
					X	39	1	Yes
A case of multiple subungual glomus tumors associated with NF type 1	Okada	1999	1		X	22	6	Yes
Glomus tumors	De Maerteleire	2000	1*					
An additional case of solitary subungual glomus tumor associated with NF 1	Kim	2000	1		X	34	1	Yes
Multifocal glomus tumours of the fingers in two patients with NF type 1	De Smet L	2002	2	X	X	53	2	No
						35	2	Yes
Glomus tumors in neurofibromatosis type 1: genetic, functional and clinical evidence of a novel association	Brems et al <sup>4</sup>	2009	11†	X	X	42	2	NR
				X	X	57	1	
					X	41	1	
					X	36	1	
					X	11	1	
					X	35	4	
					X	50	4	
						26	1	
						29	1	
Glomus tumour of the thumb in a child with neurofibromatosis: a case report	Leonard M	2010	1	X		11	1	No
Diagnosis, management, and complications of glomus tumors of the digits in NF type 1	Stewart D	2010	15‡		X	28	1	NR
					X	49	1	
					X	35	1	
					X	34	1	
					X	25	1	
					X	57	1	
Multiple glomus tumors and segmental neurofibromatosis: there are no coincidences	Cabral R	2011	1	X		62	1	No
Oral ketamine in the palliative care setting: a review of the literature and case report of a patient with NF type 1 and glomus tumor-associated complex regional pain syndrome	Soto E	2012	1§					
The association between glomus tumors and neurofibromatosis	Harrison et al <sup>5</sup>	2013	6	NR				NR
Multiple subungual glomus tumours associated with NF1	Morohashi	2013	1		X	45	3	Yes
Glomus tumours in the long finger and in the thumb of a young patient with neurofibromatosis-1	Dahlin L	2013	1		X	17	2	No
Subungual glomus tumors of the finger in a patient with type 1 neurofibromatosis	Kuwabara H	2013	1		X	35	1	Yes

\*Patient reported in De Smet 2002.

†2 patients previously reported by De Smet 2002.

‡2 patients previously reported in De Smet 2002; 7 patients previously reported by Brems et al<sup>4</sup>.

§Patient reported in Brems et al.<sup>4</sup>

NR indicates not recorded.

common for a plastic surgeon or hand surgeon to encounter isolated, sporadic glomus tumors in clinical practice, due to the fact that type I neurofibromatosis is rare.

Some authors have speculated that glomus tumors arising in the setting of type I neurofibromatosis are more likely to be multifocal, rather than solitary.<sup>4</sup> In the literature, the incidence of multifocality for sporadic glomus tumors varies widely,

ranging from 2.3% to 25%.<sup>6-8</sup> Multifocality has been associated with children, familial inheritance, and pregnancy.<sup>9-11</sup> Multiple hereditary glomus tumors is a distinct, well-described entity and represents a subset of patients in whom multiple glomus tumors develop at a young age. Multiple hereditary glomus tumors are inherited in an autosomal dominant fashion through a *glomulin* gene mutation.<sup>12,13</sup> In this review of patients with neurofibromatosis, the average

**Table 3. Summary Data**

Characteristic	Percent	No.
Total no. patients		36
Mean no. tumors per patient		1.4
Male*	21%	6/28
Female	79%	22/28
Multifocal	32%	9/28
Solitary	68%	19/28
Subungual†	62%	8/13
Nonsubungual	38%	5/13

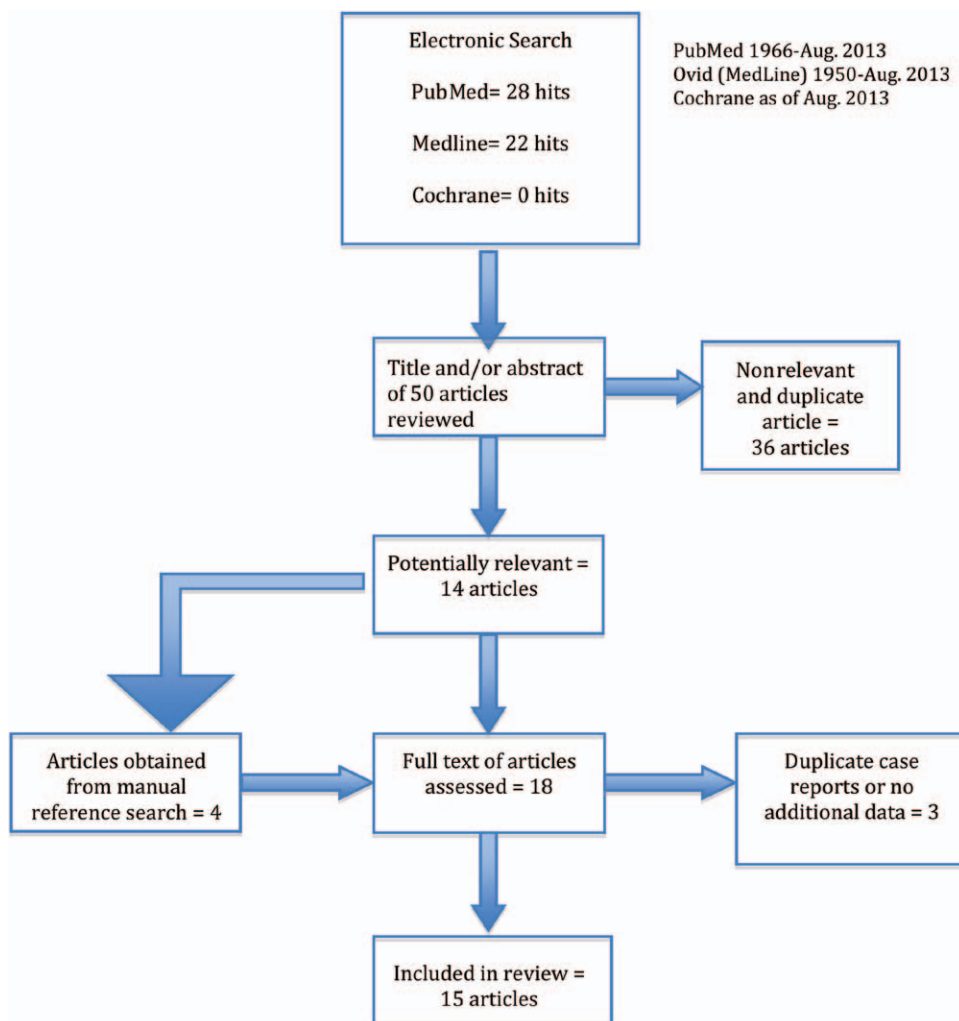
\*Of 36 patients, data on sex and number of tumors (solitary versus multifocal) were available for 28 patients.

†Data on location of tumor (subungual versus nonsubungual) were available for 13 patients.

number of tumors per patient was 1.4, with 32% of patients having multiple glomus tumors. Although this value is slightly greater than is typically reported for isolated sporadic glomus tumors, a statistical comparison is not possible. Regardless of whether multifocality is more common in neurofibromatosis-

associated glomus tumors than in sporadic glomus tumors, it is important to note that multifocality is not uncommon.

Glomus tumors associated with type I neurofibromatosis do not appear to differ from isolated glomus tumors in terms of sex distribution. In this review, 79% of patients were female. Sporadic glomus tumors are also known to be much more common in women (although there is no sex predilection for multiple familial glomus tumors).<sup>12</sup> In a large study of isolated glomus tumors, which included 51 patients with glomus tumors of the hand, 86% of patients were female.<sup>14</sup> Type I neurofibromatosis, an autosomal dominant disease, has an equal sex distribution, suggesting that the female predominance that is seen in both sporadic and neurofibromatosis-associated glomus tumors is unrelated to the association with neurofibromatosis. Why this female predilection is not present in multiple familial glomus tumors is unknown.



**Fig. 1.** Algorithm demonstrating the details of the database search.

Glomus tumors have been found almost everywhere in the body, including the head and face, back, foot, ankle, vagina, penis, lung, various visceral organs, cervix, and bone.<sup>15–19</sup> However, for isolated sporadic glomus tumors, the subungual location is by far the most common (60%–80%).<sup>20–22</sup> Sex also plays a role in tumor location, with a subungual location being more common in women, but with no sex preference noted at other locations.<sup>12</sup> In this review, 62% of tumors were subungual, which is consistent with reports of isolated sporadic glomus tumors.

An understanding of the association between type I neurofibromatosis and glomus tumors is important for plastic surgeons and hand surgeons. Because type I neurofibromatosis is usually diagnosed at a young age<sup>23</sup> and glomus tumors typically occur in adults, it is unlikely that the surgeon will see a patient with a glomus tumor who has undiagnosed neurofibromatosis. However, this clinical scenario can occur, and glomus tumors in patients with type I neurofibromatosis in the pediatric population have been described.<sup>4</sup> Therefore, the surgeon should always keep the diagnosis of type I neurofibromatosis in mind when a glomus tumor is identified. A more likely scenario would be a patient with known neurofibromatosis presenting with an undiagnosed painful lesion in the fingertip or elsewhere. If the presentation of the glomus tumor is classic, with a single painful subungual tumor, the diagnosis and treatment may be straightforward. However, in this study, an atypical presentation was common, with 38% of patients having nonsubungual tumors and 32% of patients having multifocal tumors. Even with classically presenting glomus tumors, the diagnosis is often delayed, and patients may see multiple physicians before receiving a diagnosis and treatment.<sup>14</sup> Therefore, in patients with known type I neurofibromatosis, the presence of focal subcutaneous pain should lead to the consideration of the possibility of a glomus tumor. If the diagnosis is in question, magnetic resonance imaging can be diagnostic. A glomus tumor will have low signal intensity on T1-weighted images and very high signal intensity on T2-weighted images, with a “nidus” appearance. If gadolinium contrast is administered, post-gadolinium T1-weighted images will show marked enhancement.

## CONCLUSIONS

Multiple case reports, a molecular genetics study, and a recent epidemiologic study all confirm that type I neurofibromatosis is associated with glomus tumors and that glomus tumors should be considered part of the tumor spectrum of type I neurofibromatosis. It is important for plastic surgeons and

hand surgeons to be aware of this association. In the patient with type I neurofibromatosis who presents with a painful subcutaneous lesion, the diagnosis of glomus tumor must be considered. Like isolated glomus tumors, they are more common in women, usually solitary, and most commonly found in a subungual location. However, atypical presentations with multifocal or nonsubungual tumors are not unusual. It is hoped that as this association becomes more widely recognized, earlier referral, diagnosis, and tumor excision will provide pain relief and prevent delays in treatment.

**Douglas M. Sammer, MD**

University of Texas Southwestern Medical Center  
1801 Inwood Rd  
Dallas, TX 75390  
E-mail: douglas.sammer@utsouthwestern.edu

## REFERENCES

1. Park YH, Choi SW, Cho BK, et al. Solitary type of glomus tumor developed in multiple sites. *Ann Dermatol.* 1994;6:225–229.
2. Klaber R. Morbus Recklinghausen with glomoid tumours. *Proc R Soc Med.* 1938;31:347.
3. Sawada S, Honda M, Kamide R, et al. Three cases of subungual glomus tumors with von Recklinghausen neurofibromatosis. *J Am Acad Dermatol.* 1995;32(2 Pt 1):277–278.
4. Brems H, Park C, Maertens O, et al. Glomus tumors in neurofibromatosis type 1: genetic, functional, and clinical evidence of a novel association. *Cancer Res.* 2009;69:7393–7401.
5. Harrison B, Moore AM, Calfee R, et al. The association between glomus tumors and neurofibromatosis. *J Hand Surg Am.* 2013;38:1571–1574.
6. Hollingsworth JF, Ochsner JL. A multifocal diffuse glomus tumor: case report and review of the literature. *Am Surg.* 1972;38:161–167.
7. Maxwell GP, Curtis RM, Wilgis EF. Multiple digital glomus tumors. *J Hand Surg Am.* 1979;4:363–367.
8. Plewes B. Multiple glomus tumours: four in one fingertip. *Can Med Assoc J.* 1941;44:364–365.
9. Reed WB. Multiple glomus tumors with a family history. *Arch Dermatol.* 1969;100:496–497.
10. Laymon CW, Peterson WC Jr. Glomangioma (glomus tumor). A clinicopathologic study with special reference to multiple lesions appearing during pregnancy. *Arch Dermatol.* 1965;92:509–514.
11. Kohout E, Stout AP. The glomus tumor in children. *Cancer.* 1961;14:555–566.
12. Gombos Z, Zhang PJ. Glomus tumor. *Arch Pathol Lab Med.* 2008;132:1448–1452.
13. Kale SS, Rao VK, Bentz ML. Glomus tumor of the index finger. *J Craniofac Surg.* 2006;17:801–804.
14. Van Geertruyden J, Lorea P, Goldschmidt D, et al. Glomus tumours of the hand. A retrospective study of 51 cases. *J Hand Surg Br.* 1996;21:257–260.
15. Spector GJ, Druck NS, Gado M. Neurologic manifestations of glomus tumors in the head and neck. *Arch Neurol.* 1976;33:270–274.
16. Charles NC. Multiple glomus tumors of the face and eyelid. *Arch Ophthalmol.* 1976;94:1283–1285.
17. Weiss SWG Jr. *Enzinger and Weiss's Soft Tissue Tumours.* 5th ed. Elsevier: Philadelphia, PA. 2008.

18. Fletcher CDM; World Health Organization; International Agency for Research on Cancer. *WHO Classification of Tumours of Soft Tissue and Bone*. 4th ed. Lyon, France: IARC Press; 2013.
19. Harvey WF, Dawson E, Innes JRM. *Debatable Tumours in Human and Animal Pathology*. Edinburgh, United Kingdom: Oliver and Boyd; 1940.
20. Carroll RE, Berman AT. Glomus tumors of the hand: review of the literature and report on twenty-eight cases. *J Bone Joint Surg Am*. 1972;54:691–703.
21. Tomak Y, Akcay I, Dabak N, et al. Subungual glomus tumours of the hand: diagnosis and treatment of 14 cases. *Scand J Plast Reconstr Surg Hand Surg*. 2003;37:121–124.
22. Pater TJ, Marks RM. Glomus tumor of the hallux: case presentation and review of the literature. *Foot Ankle Int*. 2004;25:434–437.
23. Abecassis S, Bastuji-Garin S, Khosrotehrani K, et al. Age at diagnosis of neurofibromatosis 1: an audit of practice. *Dermatology*. 2008;216:347–348.