

## Ultrasound-guided central venous cannulation—Missing climacteric step?

Sir,

A 12-year male, diagnosed as a case of extrahepatic portal venous obstruction, was on regular endoscopic therapy at our institute for the past 5 years for recurrent haematemesis during the last 3 years. The child had recurrent haematemesis along with moderate splenomegaly, hypersplenism, and growth retardation, which warranted a surgical intervention for portal

hypertension. The child was posted for splenectomy with a central end-to-side splenorenal shunt.

The anaesthetic induction was uneventful and post-induction of anaesthesia, 7 Fr triple lumen central venous catheter (CVC) was inserted in right internal jugular vein (IJV) under ultrasound guidance under all aseptic precautions. All ports were checked and properly flushed. The surgical procedure was uneventful with a duration of 6 hours and post-surgery, the child was extubated. Post-extubation it was found that there was reduced air entry on the right side of the chest and it was thought to be atelectasis due to prolonged surgery. The child was encouraged to do incentive spirometry as trained in the preoperative stage. On post-operative

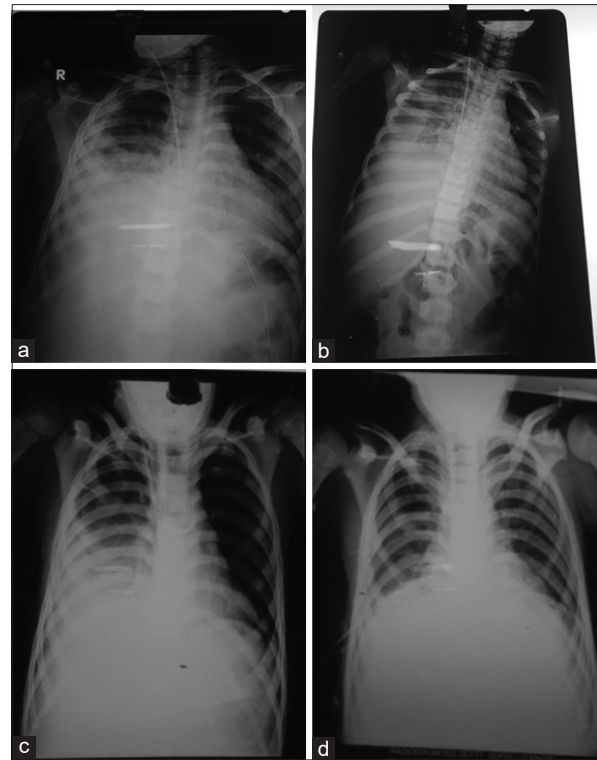
day (POD)-1, the child developed slight respiratory distress and his oxygen saturation fell to 90%. Oxygen was administered through nasal cannula along with chest physiotherapy and incentive spirometry.

On examination of the chest, it was found that there was decreased air entry in the right lung field, which persisted in the mid and lower zone. Further, a chest skiagram was done, which revealed opacity in the middle and lower zone of the right lung [Figure 1a]. Initially, this was managed conservatively with aggressive chest physiotherapy and incentive spirometry. The blood and sputum cultures were sent and the patient remained afebrile with a normal leukocyte count. However, the opacity persisted on follow-up chest skiagram imaging despite aggressive chest physiotherapy and incentive spirometry [Figure 1b] and therefore, an ultrasonography (USG) chest was done, which revealed a fluid collection in the right side of the chest. Following the USG chest, a USG guided needle aspiration was done and around 200 ml thick haemorrhagic fluid was drained. Repeat chest ultrasound done on the very next day again revealed persistent opacity in the right side of the chest [Figure 1c]. So, a right intercostal drain (ICD) was finally placed to drain out the residual collection and it drained out approximately 300 ml haemorrhagic fluid (a total of approximately 500 ml drained). This ICD placement was followed by an expansion of the right lung field [Figure 1d]. The ICD was further removed after 2 days.

Even in most experienced hands, complications during CVC insertion can occur, viz. pneumothorax, haemothorax, carotid artery puncture, haematoma etc.<sup>[1-3]</sup>

In our case, we operated upon a child with significant haemothorax for major surgery and this could have been a major event but, somehow, we were fortunate. Such iatrogenic haemothorax may lead to serious events intraoperatively and postoperatively. The cause of such haemothorax could be due to vascular injury during guidewire insertion or dilatation phase. Sometimes, even the azygous vein rupture during right-sided cannulation of IJV can be the cause.<sup>[3]</sup>

Real-time USG guided IJV cannulation significantly reduces, but does not wholly eliminate, the incidence of complications associated with central venous cannulations.<sup>[4]</sup>



**Figure 1:** Chest X ray during the entire perioperative period. (a) CXR showing opacity in the middle and lower zone of the right lung, (b) CXR showing persistent opacity on the right side of lung, (c) CXR showing opacity on right side of chest despite ultrasound drainage, (d) CXR following Intercostal drain insertion

Nath *et al.*<sup>[5]</sup> also recommended from their experience that free venous outflow must be carefully checked in all the ports of the CVC, and following placement of such a catheter, a chest radiograph should be done to confirm the position of the catheter.

We emphasise upon careful auscultation followed by a brief ultrasound of the chest after placement of CVC as chest x rays are not done immediately post-insertion of CVC in the operative rooms.

#### Declaration of patient consent

The authors certify that they have obtained all appropriate patient consent forms. In the form, the legal guardian has given his consent for images and other clinical information to be reported in the journal. The guardian understands that names and initials will not be published and due efforts will be made to conceal identity, but anonymity cannot be guaranteed.

#### Financial Support and Sponsorship

Nil.

#### Conflicts of Interest

There are no conflicts of interest.

**Amit Rastogi, Ankur Mandelia<sup>1</sup>, Vansh Priya**  
 Departments of Anaesthesiology and <sup>1</sup>Paediatric Surgical Super  
 Speciality, SGPGI, Lucknow, Uttar Pradesh, India

**Address for correspondence:**

Dr. Amit Rastogi,  
 Department of Anaesthesiology, SGPGI, Lucknow,  
 Uttar Pradesh, India.  
 E-mail: amit.rastogi.sgpgi@gmail.com

**Submitted:** 02-Mar-2021

**Revised:** 23-Mar-2021

**Accepted:** 27-Sep-2021

**Published:** 29-Oct-2021

**REFERENCES**

1. Naik VM, Mantha SS, Rayani BK. Vascular access in children. *Indian J Anaesth* 2019;63:737-45.
2. Govil N, Dhar M, Masaipeta K, Ahmed I. Displaced paediatric central venous catheter causing extravasation of intravenous fluid due to relatively longer gap between the distal and proximal lumens. *Indian J Anaesth* 2019;63:157-9.
3. Bharati SJ, Chowdhury T, Sapra H. Azygous vein rupture after right internal jugular vein cannulation: A rare complication. *Indian J Anaesth* 2013;57:215-7.
4. Srinivasan S, Govil D, Gupta S, Patel S, Jagadeesh KN,

- Tomar DS. Incidence of posterior wall penetration during internal jugular vein cannulation: A comparison of two techniques using real-time ultrasound. *Indian J Anaesth* 2017;61:240-4.
5. Nath MP, Gupta S, Chakrabarty A. Extravasation of catheter tip following central venous catheterisation: A near fatal complication. *Indian J Anaesth* 2010;54:572-3.

This is an open access journal, and articles are distributed under the terms of the Creative Commons Attribution-NonCommercial-ShareAlike 4.0 License, which allows others to remix, tweak, and build upon the work non-commercially, as long as appropriate credit is given and the new creations are licensed under the identical terms.

Access this article online	
Quick response code	Website: www.ijaweb.org
	DOI: 10.4103/ija.ija_124_21

**How to cite this article:** Rastogi A, Mandelia A, Priya V. Ultrasound guided central venous cannulation- Missing climacteric step? *Indian J Anaesth* 2021;65:770-2.

© 2021 Indian Journal of Anaesthesia | Published by Wolters Kluwer - Medknow