

# Cervical Laminectomy with Lateral Mass Screw Fixation in Cervical Spondylotic Myelopathy

## Neurological and Sagittal Alignment Outcome: Do We Need Lateral Mass Screws at each Segment?

### Abstract

**Background:** Anterior cervical decompression and fusion is the standard procedure used for treating patients with cervical myelopathy. However, these procedures are associated with complications such as pseudarthrosis, construct failure, and neurological complications. Posterior cervical laminectomy and instrumentation is an alternative procedure to treat multilevel cervical myelopathy. In this study, we raised questions whether instrumentation is required at all levels and whether stabilizing the spine in neutral or lordotic contour with indirect decompression leads to neurological improvement with radiological evidence of anterior decompression. The results of posterior cervical laminectomy and instrumentation with lateral mass screw in terms of radiological and functional outcome in patients with multilevel cervical myelopathy are prospectively evaluated. **Materials and Methods:** In this prospective study conducted between June 2006 and December 2015, we have evaluated 112 patients with multilevel cervical myelopathy who underwent multilevel cervical laminectomy and instrumentation with lateral mass screw. All patients were evaluated preoperatively and postoperatively with Nurick's grading and Modified Japanese Orthopaedic Association (mJOA) scale for neurological function. Cooper scale and British Medical Research Council grading system for motor function. Curvature index was used to measure the alignment of cervical spine preoperatively and postoperatively. Alignment of the cervical spine was done preoperatively and postoperatively by calculating the curvature index. Axial MRI was used to calculate the severity of compression preoperatively which was calculated as per Singh's criteria and postoperatively to assess the adequacy of decompression at the operated level. **Results:** In our study, there were 112 patients including 99 males and 13 females, with mean age of 59.53 years. The mean duration of followup of patients was 33.24 months. In total, cervical laminectomy was performed at 342 levels in 112 patients with an average of 3.05 laminectomies, and in total, 112 lateral mass screws were inserted. On postoperative followup, the mJOA and Nurick's grading showed improvement in all cases as compared to preoperative findings. The mean mJOA improved significantly from 8.56 preoperatively to 13.57 postoperatively ( $P < 0.001$ ). The mean Nurick's grading also improved significantly from 2.59 preoperatively to 0.66 postoperatively ( $P < 0.001$ ). The mean Cooper scale also showed significant improvement in both upper and lower limbs postoperatively ( $P < 0.001$ ). The mean preoperative Cooper scale was 1.75 and postoperative was 0.31 for upper limbs, and the mean Cooper scale was 2.14 preoperatively and 0.56 postoperatively for lower limbs. X-rays done on routine followups showed good alignment of the cervical spine with maintenance of curvature index in all patients. The mean grade of compression as seen on preoperative MRI was 2.46 which reduced significantly postoperatively to 0.16 ( $P < 0.001$ ). **Conclusion:** The multilevel cervical laminectomy and instrumentation with lateral mass screw for multilevel cervical myelopathy is a safe technique that provides decompression of the spinal cord, prevents the development of kyphotic spinal deformity and posterior tension band of the spinal cord as associated with laminoplasty or uninstrumented laminectomy.

**Keywords:** Cervical laminectomy, cervical myelopathy, indirect decompression, lateral mass screw

**MeSH terms:** Bone screws, myelopathy, spinal cord compression, laminectomy

### Introduction

Cervical spondylosis secondary to degeneration of intervertebral disc, facet joints, posterior longitudinal ligament, ligamentum flavum, and ossification of

posterior longitudinal ligament (OPLL) are the most common causes of cervical myelopathy which can lead to irreversible neurological impairment.<sup>1-3</sup> The standard surgical treatment for cervical myelopathy

This is an open access article distributed under the terms of the Creative Commons Attribution-NonCommercial-ShareAlike 3.0 License, which allows others to remix, tweak, and build upon the work non-commercially, as long as the author is credited and the new creations are licensed under the identical terms.

For reprints contact: reprints@medknow.com

**How to cite this article:** Singrakhia MD, Malewar NR, Singrakhia SM, Deshmukh SS. Cervical laminectomy with lateral mass screw fixation in cervical spondylotic myelopathy: Neurological and sagittal alignment outcome: Do we need lateral mass screws at each segment?. Indian J Orthop 2017;51:658-65.

**Manoj Dayalal Singrakhia,**  
**Nikhil Ramdas Malewar,**  
**Sonal Manoj Singrakhia<sup>1</sup>,**  
**Shivaji Subhash Deshmukh<sup>1</sup>**

Departments of Spine Surgery and <sup>1</sup>Anaesthesia, Shanta Spine Institute, Nagpur, Maharashtra, India

**Address for correspondence:**  
Dr. Manoj Dayalal Singrakhia,  
Department of Spine Surgery,  
Shanta Spine Institute, 1<sup>st</sup> Floor,  
Ashirvad Complex, Ramdaspath,  
Nagpur - 440 010,  
Maharashtra, India.  
E-mail: singrakhia@hotmail.com

### Access this article online

**Website:** www.ijoonline.com

**DOI:**  
10.4103/ortho.IJOrtho\_266\_16

### Quick Response Code:



consists of either anterior decompressive procedure or posterior decompressive procedure. Anterior decompressive procedure consists of anterior discectomy and fusion or corpectomy and fusion.<sup>4,5</sup> Posterior decompressive procedure consists of either laminoplasty or laminectomy with or without instrumentation.<sup>6-8</sup>

The pathophysiology behind cervical myelopathy is direct compression of the cord and ischemic insult to the cord as a result of reduced blood flow. Anterior cervical decompression surgery helps to remove the direct compression on the cord as well as helps to increase the blood flow to the spinal cord. Anterior cervical discectomy and fusion is gold standard for single-level cervical myelopathy and has shown to produce good clinical results.<sup>9</sup> However, in patients with multiple segment involvement with myelopathy, the approach toward the treatment is unclear.<sup>8-11</sup>

Multilevel anterior surgery is associated with complications such as increased surgical trauma and increased incidence of pseudarthrosis, graft dislodgement, and implant failure as the number of level increases. It is also associated with increased incidence of adjacent segment degeneration and neurological deterioration.<sup>12-15</sup> Multilevel posterior surgeries such as laminoplasty or laminectomy without instrumentation are associated with complications such as instability, kyphosis, axial pain, perineural adhesion, neurological deterioration, and C5 nerve root palsy.<sup>16-20</sup> However, multilevel cervical laminectomy with lateral mass screw fixation provides immediate stability, hence prevents the development of kyphotic deformity and adjacent segment degeneration by the prevention of osteophyte formation.<sup>21-23</sup> The goal in treating multilevel cervical myelopathy is to achieve adequate decompression without compromising the stability of the cervical spine.

This study evaluates the outcome of multilevel cervical laminectomy and stabilization with lateral mass screw fixation in patients with multilevel cervical spine myelopathy and its outcome in terms of spinal cord decompression, neurological function, and spinal alignment.

## Materials and Methods

112 patients with multilevel cervical myelopathy who underwent cervical laminectomy and stabilization with lateral mass screw between June 2006 to and December 2015 were included in this prospective study. The mean duration of symptoms was 9.76 months. Inclusion criteria included patients below the age of 65 years with cervical myelopathy secondary to either cervical spondylosis at two or more levels or posterior longitudinal ligament ossification at two or more levels causing spinal cord compression and patients having lordotic or a straight cervical spine. The exclusion criteria comprised of patients above the age of 65 years, patients with neurological weakness secondary to

stroke, trauma, or chronic neurological conditions, kyphotic cervical spine, and patients who underwent both anterior and posterior surgeries.

## Preoperative evaluation

The common presenting symptoms in our study were gait disturbance, hand use difficulty, upper and lower extremity sensory abnormality, neck pain, upper extremity pain, and sphincter dysfunction [Table 1].

All patients underwent functional evaluation preoperatively and postoperatively with Nurick's grading [Table 2] and Japanese Orthopaedic Association Scale [Table 3].<sup>24</sup> Patients also underwent evaluation with Cooper scale [Table 4] which has the advantage of providing separate assessment of upper and lower limbs.<sup>23</sup> Muscle strength in each patient of all muscle groups was evaluated with the Medical Research Council, British grading system. Weakness of one or more muscle was detected in 81 patients (72.3%). Other signs of myelopathy were hyperreflexia (69%), Hoffmann's reflex (42%), Romberg's sign (38%), Babinski sign (29%), and ankle clonus (19%). Preoperative muscle weakness was seen most commonly in hand intrinsic muscles (71%), triceps (59%), iliopsoas (31%), biceps (22%), deltoid (16%), quadriceps (11%), plantar flexion (6%), and dorsiflexion (6%).

## Preoperative imaging

Preoperatively, X-rays of the cervical spine in anteroposterior view and lateral dynamic views (flexion and extension) were done. Alignment of cervical spine was calculated

**Table 1: Number of patients with particular symptoms on preoperative assessment**

Symptoms	Number of patients	Percentage of patients
Upper limb sensory abnormality	96	85.71
Gait abnormality	81	72.3
Difficulty using upper extremity	83	74.1
Lower limb sensory abnormality	36	32.14
Neck pain	29	25.89
Upper limb pain	24	21.4
Sphincter dysfunction	21	18.75

**Table 2: Nurick's grading system for cervical myelopathy**

Nurick's grading	
Grade	Function
0	Signs and symptoms of nerve root involvement, but no evidence of spinal cord disease
1	Signs of spinal cord disease, but no difficulty in walking
2	Slight difficulty in walking but do not affect full-time employment
3	Severe difficulty in walking which requires assistance and affects full-time employment
4	Walk with the help of support
5	Bedridden or wheelchair bound

**Table 3: Grading system for cervical myelopathy as per the Modified Japanese Orthopaedic Association****mJOA Scale**

## Motor dysfunction in upper extremity

0. Unable to feed oneself
1. Unable to use knife and fork, but able to use spoon
2. Able to use fork and knife with much difficulty
3. Able to use fork and knife with slight difficulty
4. None

## Motor dysfunction in lower extremity

0. Unable to walk
1. Can walk on plain surface with support
2. Can walk upstairs and downstairs with support
3. Smooth gait but lack of stability
4. None

## Sensory deficit

0. Upper limb severe sensory loss or pain
1. Upper limb mild sensory loss or pain
2. Upper limb, no sensory deficit
- 0-2. Lower limb
- 0-2. Trunk

## Sphincter dysfunction

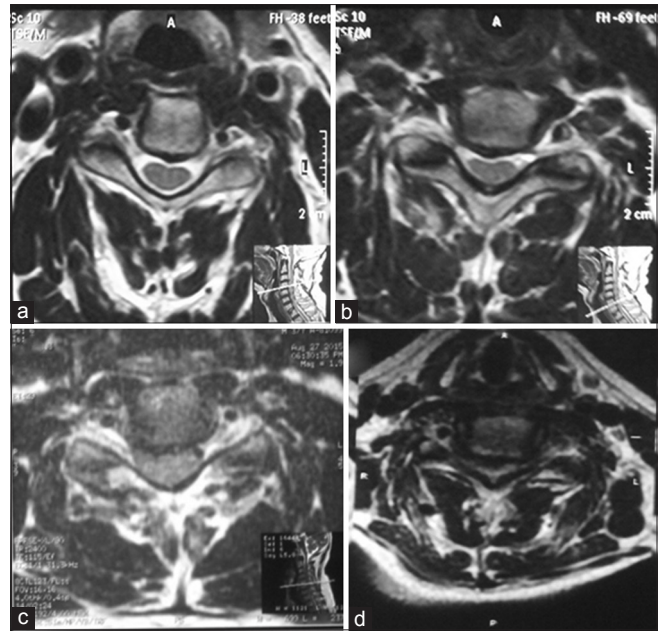
0. Unable to void
1. Severe difficulty in micturition, urinary retention
2. Difficulty in micturition

mJOA=Modified Japanese Orthopaedic Association

**Table 4: Grading for cervical myelopathy as per Cooper grading system**

Cooper scale	
Grade	Function
Lower limb	
0	Intact
1	Independent walker, but gait is not normal
2	Walk with support
3	Can stand, unable to walk
4	Unable to stand and walk, slight movement present
5	Paralysis
Upper limb	
0	Intact
1	Only sensory symptoms
2	Mild motor deficit with mild functional impairment
3	Major functional impairment in at least one of the upper limbs, but can perform simple tasks
4	No movement or flicker of movement, but no useful function
5	Paralysis

by measuring curvature index as described by Ishiara.<sup>23</sup> Preoperatively, the mean curvature index was 4.62. Magnetic resonance imaging (MRI) was also done in all the patients to assess the degree of cervical cord compression. Modified Singh *et al.* grading system was used to assess the severity of the spinal cord compression on axial T2-weighted MRI [Figure 1].<sup>23</sup> It is calculated from the midbody of one vertebra to midbody of the adjacent one at



**Figure 1: T2W MRI axial cut showing (a) Grade 0-360° cushion of cerebrospinal fluid around the spinal cord. (b) Grade 1 - loss of cerebrospinal fluid cushion without indentation of spinal cord. (c) Grade 2 - mild spinal cord compression. (d) Grade 3 - severe spinal cord compression**

the level of cervical spinal cord compression. The axial cut showing maximum compression of the spinal cord is used to assign the grading as per Singh *et al.* grading system. The mean preoperative compression was 2.41 [Figure 1].

**Operative procedure**

Under general anesthesia in prone position, the head was placed in horseshoe-shaped positioner. Gardner well tongs were applied to provide traction. The movements of cervical spine was done gently to avoid injury to already compromised cord and prevent quadriplegia. The upper limbs were strapped to the side of the body and gentle traction applied to the cervical spine for adequate visualization the cervical spine on lateral radiograph. The parts were cleaned properly, painted, and draped. The level was confirmed with the help of lateral cervical C-arm imaging. At the level of fusion, the lateral masses were exposed. Adequate size screws were inserted in the lateral mass at the most proximal and distal level of fusion. In cases of long segment fixation, screws were inserted in the intermediate level also. If laminectomy was done at 3 or 4 levels, a 4-screw construct was used. In laminectomy done at more than 4 levels, additional screws were inserted in the middle, that is, a 6-screw construct was used. Laminectomy with undercutting of proximal and distal lamina is performed at the level of cord compression to achieve indirect decompression of the cervical spinal cord. T2 sagittal and axial MRI were used to assess the number of level to be decompressed. Flow of cerebrospinal fluid anterior and posterior to spinal cord in sagittal section and in axial cuts modified Singh's index were used to determine the number of levels to be decompressed. All

levels showing compression Grade 1 or more according to the modified Singh's index were decompressed by doing laminectomies. Undercutting of the proximal and distal lamina was done to avoid secondary stenosis. Rods of adequate size were inserted. During surgery, care was taken to burr out the facet joint capsule, and small bone pieces from local lamina were inserted to induce fusion. We did not use iliac crest bone graft for fusion. Wound was closed in layers over negative suction drain. Postoperatively, cervical collar was used for immobilization for 6 weeks as an additional protection by the time fusion is induced.

### Statistical analysis

The data were tabulated in Microsoft Excel sheet. The statistical analysis of data was done by "paired *t*-test" for comparing the outcome between pre- and postoperative results.  $P < 0.05$  was considered statistically significant.

### Results

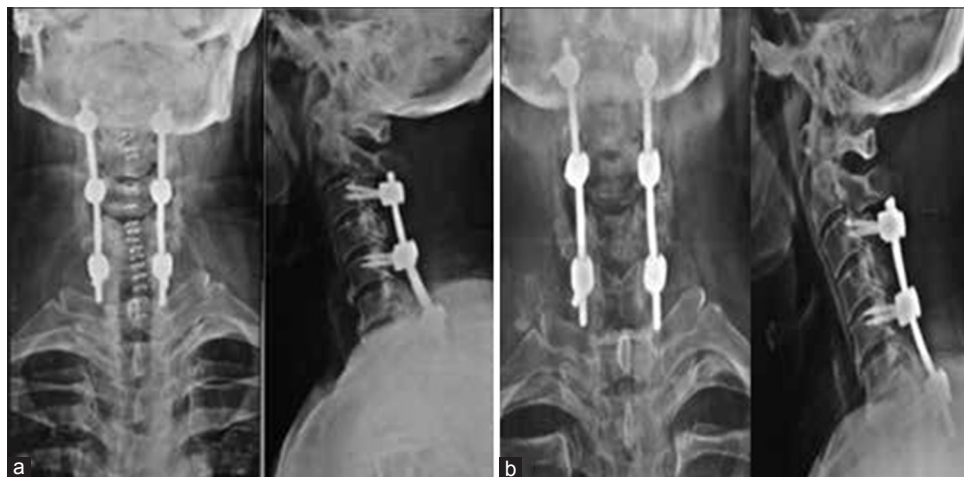In our study of 112 patients of cervical myelopathy, there were 99 males and 13 females. The mean age of presentation was 59.53 years. Eighty nine patients had myelopathy secondary to cervical spondylosis, 17 patients had myelopathy due to OPLL, and 6 patients had both as a cause for myelopathy. In total, cervical laminectomy was performed at 342 levels in 112 patients with a mean of 3.05. All patients were followed up after 1 month, 3 months, 6 months, 12 months, and then yearly after the surgery. The mean duration of followup was 33.24 months. At every followup, the patients were evaluated clinically by the modified Japanese Orthopaedic Association (mJOA), Cooper scale, and Nurick's grading. X-rays were done to calculate Ishihara index, evaluate screw position, any loosening or breakage of screw or rod, and kyphosis of cervical spine.

On postoperative evaluation as on the final followup, the mJOA, Nurick's grading, and Cooper score were

improved in all patients. The mean mJOA score was 8.56 preoperatively and 13.57 postoperatively. There was significant improvement in mean mJOA ( $P < 0.001$ ). The Cooper scale for both upper extremity and lower extremity showed significant improvement postoperatively. The Cooper scale for upper extremity was improved from 1.75 preoperatively to 0.31 postoperatively ( $P < 0.001$ ); similarly for lower extremity, the Cooper scale showed significant improvement from 2.14 preoperatively to 0.56 postoperatively ( $P < 0.001$ ). The Nurick's grading also showed significant improvement from 2.59 preoperatively to 0.66 postoperatively ( $P < 0.001$ ). There was significant improvement in muscle power also postoperatively in patients who had muscular weakness preoperatively. The muscle power was less than Grade 5 in 185 muscle groups and improvement to Grade 5 was seen in 160 muscle groups postoperatively. None of the patients had worsening of neurology.

### Postoperative imaging

All patients were evaluated postoperatively at every followup with cervical spine X-ray for bony alignment, curvature index, and implant position. None of the patients showed implant backout, rod, or screw breakage. The mean postoperative curvature index as calculated at final followup was 4.63. There was no significant change in curvature index on postoperative X-rays at the final followup as compared to preoperative X-rays ( $P > 0.05$ ). Postoperative MRI was done in 35 patients. All patients had adequate decompression as seen on postoperative MRI. There was significant reduction ( $P < 0.001$ ) in compression grading on postoperative MRI as compared to preoperative MRI. The mean preoperative compression was 2.41 which reduced significantly to 0.42 postoperatively [Figures 2-5].



**Figure 2:** (a) Immediate postoperative X-ray of cervical spine anteroposterior and lateral views following C3–C7 laminectomy and instrumentation done with lateral mass screw at C3, C5, and C7. (b) 2-year followup X-ray of the same patient showing well-maintained alignment of the cervical spine. Screws and rods are in good position

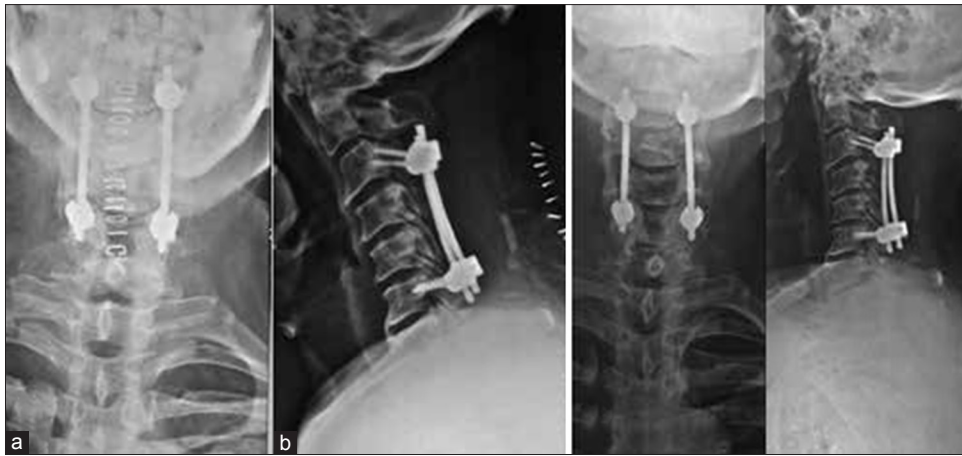

Figure 3: (a) Immediate postoperative X-ray of cervical spine anteroposterior and lateral views following C3–C6 laminectomy and instrumentation done with lateral mass screw at C3 and C6. (b) 3-year followup X-ray of the same patient showing well-maintained alignment of the cervical spine. Screws and rods are in good position

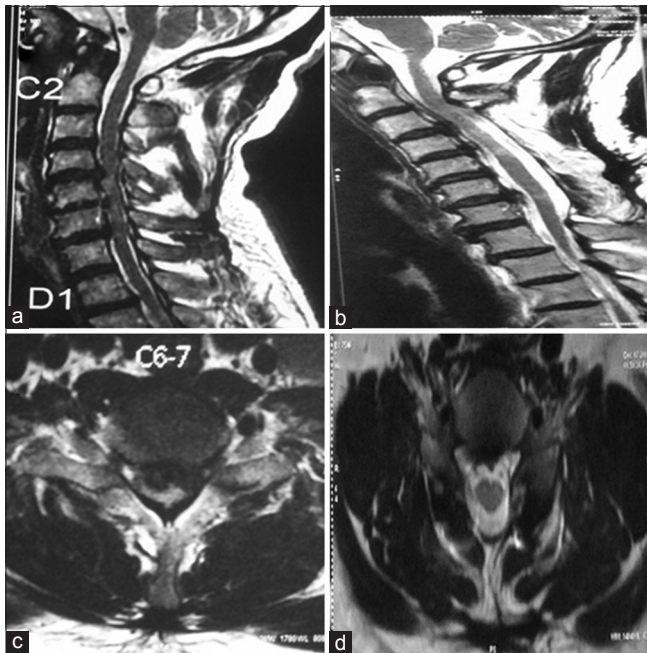


Figure 4: Sagittal MRI T2WI of cervical spine showing (a) multilevel spinal cord compression secondary to ossification of posterior longitudinal ligament. (b) Well decompressed spinal cord which has moved substantially away from anterior pathology. (c) Preoperative axial scan showing severe compression of the spinal cord. (d) Postoperative axial scan showing well-decompressed cord with 360° cushioning of cerebrospinal fluid

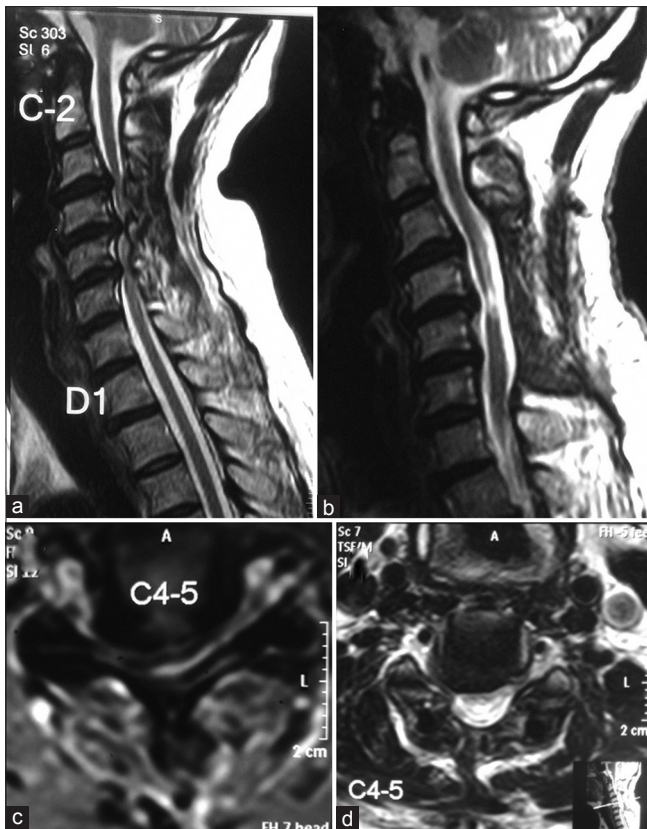
### Complications

In our study, one patient had superficial wound infection which healed on regular dressing. Two patients had postoperative epidural hematoma after the removal of drain. Both the patients developed transient quadriplegia without any respiratory discomfort. The patients were taken inside the operation theater immediately, the clots were removed completely, and hemostasis was achieved under general anesthesia. Both the patients recovered completely without any residual neurological deficit.

### Discussion

Multilevel cervical myelopathy can be treated with either anterior or posterior decompressive procedure; the choice of surgery depends on the location of pathology, alignment of the cervical spine, and also surgeon's preference.<sup>25,26</sup> In this study, we have evaluated the outcome of multilevel posterior cervical laminectomy with instrumented fusion with lateral mass screw. The results of our study show that patients with multilevel cervical myelopathy operated with this technique have favorable neurological and functional outcome as measured by mJOA score, Cooper scale, and Nurick's grading. The reason for favorable result is good surgical exposure, excellent cord decompression, accurate placement of the screw in lateral mass, good bone graft for fusion, and avoidance of screw penetration in the spinal canal or disc space. This factor helps in the maintenance of cervical spine alignment and prevents the development of cervical kyphosis as the loss of alignment of cervical spine and development of cervical kyphosis may affect the outcome after surgery. Maintenance of alignment and adequate decompression are the most important factors in achieving good clinical outcome as micromotion in degenerated cervical spine can lead to continuous irritation of the already compromised cord and can prevent the progress of neurological recovery.<sup>23,27</sup>

Laminoplasty or laminectomy without instrumentation for multilevel pathology is associated with complications such as neurological deterioration and progressive kyphotic deformity. As the posterior neck muscles provide tension band, it keeps the cervical spine maintained in lordosis, as these muscles are detached and facet joints are removed during laminoplasty and laminectomy which undergoes significant atrophy causing loss of cervical lordosis and leading to progressive kyphotic deformity.<sup>28</sup> Facetectomy done while doing laminectomy is also one of the important causes of postoperative kyphosis after laminectomy.<sup>29</sup> Excluding patients with kyphotic cervical spine helps to



**Figure 5:** Sagittal MRI T2WI of cervical spine showing (a) multilevel spinal cord compression secondary to cervical spondylosis. (b) Well decompressed spinal cord which has moved substantially away from anterior pathology in postoperative image. (c) Preoperative axial scan showing severe compression of the spinal cord. (d) Postoperative axial scan showing well-decompressed cord with 360° cushioning of cerebrospinal fluid

prevent the bowstringing of the decompressed cervical spinal cord over the anterior osteophytes or vertebra body.<sup>9,21,23</sup> Postoperative MRI done in our study showed that the cervical cord moved backward away from the anterior osteophytes after posterior decompression, providing indirect decompression of the cervical spinal cord and helps in good postoperative outcome.

The results of our study can be compared with similar studies done in the past. In a similar study conducted by Kumar *et al.*,<sup>30</sup> they concluded that, after cervical laminectomy and fusion for cervical myelopathy, 80% of patients had good clinical outcome and 76% of patients showed improvement in myelopathy scores. In their study, none of the patients had worsening of neurological symptoms, instability, or progression of kyphosis. They also stated that patients with better preoperative neurological status were likely to improve more as compared to patients with poor neurological status.

In a study conducted by Chang *et al.*<sup>8</sup> on 58 patients with multilevel cervical myelopathy who underwent cervical laminectomy and fusion with lateral mass screw, mJOA scores improved significantly in 85.5%, while 14.5% of

patients showed no improvement. None of the patients had deterioration of mJOA score in their study. All patients showed radiographic fusion in dynamic X-ray done at an average followup duration of 11.9 months. Four patients had C5 nerve root palsy and one patient had superficial wound infection which settled without any sequelae.

Huang *et al.*<sup>31</sup> retrospectively studied 32 patients who were treated with cervical laminectomy and fusion with lateral mass screw for cervical myelopathy. The patients were evaluated by Nurick's grading for clinical evaluation, and X-ray and MRI were done for radiological assessment both preoperatively and postoperatively in their study. Nurick's grading showed significant improvement in 22 patients, 9 patients showed no improvement. However, none of the patients had worsening of Nurick's grading. Postoperative MRI showed compression in one patient and myelomalacic change in 15 patients which was same in preoperative MRI. However, these patients had significant neurological recovery similar to patients who did not show compression or myelomalacic changes. One patient had pseudarthrosis, three patients had wound infection which required reoperation, and two patients had C5 nerve root palsy which settled gradually without any intervention.

Houten and Cooper<sup>23</sup> studied 38 patients with cervical myelopathy who underwent laminectomy and instrumentation with lateral mass fixation. The patients were evaluated clinically with mJOA score, Cooper scale, and 5-point muscle grading. X-ray and MRI were done both preoperatively and postoperatively for the assessment of cervical spine alignment and adequacy of decompression. Clinically significant improvement was seen in 97% of patients with mJOA scale improved to 15.8 from 12.9. Cooper scale also showed significant improvement from 1.8 to 0.7 for upper extremities and 1.0–0.4 for lower extremities. X-rays done at mean followup of 5.9 months showed no change in the alignment of cervical spine. Postoperative MRI showed significant improvement in compression grading from 2.46 to 0.16. They concluded that multilevel cervical laminectomy with instrumentation is an effective procedure with minimum morbidity, adequate cord decompression, and provides immediate stability. The authors also concluded that neurological outcome was similar to anterior procedures and avoided the complications associated with anterior procedures and multilevel laminectomy without instrumentation.

Multilevel cervical laminectomy is associated with C5 nerve root palsy with incidence of 4.6% in spondylotic myelopathy and 8.3% in OPLL.<sup>21</sup> Posterior shift of the spinal cord following laminectomy leads to the tethering effect on the nerve root resulting in C5 palsy.<sup>31</sup> Incomplete removal of osteophytes and soft tissue from the neural foramina during decompression can also reduce the mobility of the nerve root and increase the risk of

nerve root palsy. Reconstruction of the cervical spine following decompression in excessive lordosis can cause impingement of the C5 nerve root leading to palsy.<sup>32</sup> In our study, none of the patients developed C5 nerve root palsy as the decompression was adequate with removal of osteophytes from the neural foramen and also undermining of the facet joint was done which provided enough space for dorsal shift of the nerve root.

Postoperative epidural hematoma can occur as a result of bleeding from the edges of the bone from the facet joint while decompressing the neural foramen.<sup>21</sup> Hemostasis must be achieved carefully with bipolar electrocautery and gelatin sponge. Postoperative epidural hematoma can lead to progressive neurological deficit. The neurological deficit is temporary if drained within time. The neurological deficit can be permanent, irreversible, and can also lead to death if the hematoma is not drained in time.<sup>33-35</sup> In our study, two patients had postoperative epidural hematoma with transient paralysis. The hematoma was drained immediately and meticulous hemostasis was achieved. None of the patients had residual paralysis.

Posterior cervical spine instrumentation with lateral mass screw is the most commonly used technique for subaxial stabilization of the cervical spine. The common complications associated with lateral mass screw are due to breach in the lateral mass leading to screw penetration in the ventral soft tissue which can cause injury to the vertebral artery, nerve roots, and the cervical cord.<sup>7</sup> The accurate placement of the lateral mass screw is dependent on the surgeon's experience. Adequate bony fusion is necessary to prevent the screw back out and rod breakage. In our study, none of the patients had complications related to lateral mass screw.

The incidence of complication was low in our study because of appropriate case selection, adequate decompression of the spinal cord, meticulous hemostasis, accurate trajectory of the lateral mass screw, and restoration of the cervical spine in lordosis. In our study, age, sex, previous medical illness, duration of symptoms, degree of compression, and signal intensity changes on MRI were not found to affect the final outcome of surgical intervention.

There are certain limitations of our study. This study did not have any control group, hence whether this study leads to better neurological outcome as compared to anterior surgery could not be studied. In addition, there was no comparison group to study the cervical alignment postoperatively, in which lateral mass screws were put at all the levels being decompressed. Since there was no deterioration in the alignment of the followup X-rays, we conclude that instrumentation at all levels is not mandatory in multilevel cervical myelopathy.

## Conclusion

The multilevel cervical laminectomy and instrumentation with lateral mass screw for multilevel cervical myelopathy

is a safe technique that provides decompression of the spinal cord, prevents the development of kyphotic spinal deformity and posterior tension band of the spinal cord as associated with laminoplasty or uninstrumented laminectomy.

## Financial support and sponsorship

Nil.

## Conflicts of interest

There are no conflicts of interest.

## References

- Miyazaki M, Kodera R, Yoshiwa T, Kawano M, Kaku N, Tsumura H. Prevalence and distribution of thoracic and lumbar compressive lesions in cervical spondylotic myelopathy. *Asian Spine J* 2015;9:218-24.
- Edwards CC 2<sup>nd</sup>, Riew KD, Anderson PA, Hilibrand AS, Vaccaro AF. Cervical myelopathy. Current diagnostic and treatment strategies. *Spine J* 2003;3:68-81.
- Ellingson BM, Salamon N, Hardy AJ, Holly LT. Prediction of neurological impairment in cervical spondylotic myelopathy using a combination of diffusion MRI and proton MR spectroscopy. *PLoS One* 2015;10:e0139451.
- Fei Q, Li J, Su N, Wang B, Li D, Meng H, *et al.* Comparison between anterior cervical discectomy with fusion and anterior cervical corpectomy with fusion for the treatment of cervical spondylotic myelopathy: A meta-analysis. *Ther Clin Risk Manag* 2015;11:1707-18.
- Liu T, Xu W, Cheng T, Yang HL. Anterior versus posterior surgery for multilevel cervical myelopathy, which one is better? A systematic review. *Eur Spine J* 2011;20:224-35.
- Lao L, Zhong G, Li X, Qian L, Liu Z. Laminoplasty versus laminectomy for multi-level cervical spondylotic myelopathy: A systematic review of the literature. *J Orthop Surg Res* 2013;8:45.
- Song M, Zhang Z, Lu M, Zong J, Dong C, Ma K, *et al.* Four lateral mass screw fixation techniques in lower cervical spine following laminectomy: A finite element analysis study of stress distribution. *Biomed Eng Online* 2014;13:115.
- Chang V, Lu DC, Hoffman H, Buchanan C, Holly LT. Clinical results of cervical laminectomy and fusion for the treatment of cervical spondylotic myelopathy in 58 consecutive patients. *Surg Neurol Int* 2014;5 Suppl 3:S133-7.
- Zhu B, Xu Y, Liu X, Liu Z, Dang G. Anterior approach versus posterior approach for the treatment of multilevel cervical spondylotic myelopathy: A systemic review and meta-analysis. *Eur Spine J* 2013;22:1583-93.
- Komotar RJ, Mocco J, Kaiser MG. Surgical management of cervical myelopathy: Indications and techniques for laminectomy and fusion. *Spine J* 2006;6 6 Suppl:252S-67S.
- Fehlings MG, Barry S, Kopjar B, Yoon ST, Arnold P, Massicotte EM, *et al.* Anterior versus posterior surgical approaches to treat cervical spondylotic myelopathy: Outcomes of the prospective multicenter AOSpine North America CSM study in 264 patients. *Spine (Phila Pa 1976)* 2013;38:2247-52.
- Tian P, Fu X, Li ZJ, Sun XL, Ma XL. Hybrid surgery versus anterior cervical discectomy and fusion for multilevel cervical degenerative disc diseases: A meta-analysis. *Sci Rep* 2015;5:13454.
- Shriver MF, Lewis DJ, Kshetry VR, Rosenbaum BP, Benzel EC, Mroz TE. Pseudarthrosis rates in anterior cervical discectomy and fusion: A meta-analysis. *Spine J* 2015;15:2016-27.
- McAnany SJ, Baird EO, Overley SC, Kim JS, Qureshi SA,

- Anderson PA. A meta-analysis of the clinical and fusion results following treatment of symptomatic cervical pseudarthrosis. *Global Spine J* 2015;5:148-55.
15. Feng NL, Zhong HL, Xuan H, Zhi C, Fang Z, Hong XS, *et al.* Comparison of two reconstructive techniques in the surgical management of four level cervical spondylotic myelopathy. *Biomed Res Int* 2015;2015:513906.
  16. Du W, Wang L, Shen Y, Zhang Y, Ding W, Ren L. Long term impacts of different posterior operations on curvature, neurological recovery and axial symptoms for multilevel cervical degenerative myelopathy. *Eur Spine J* 2013;22:1594-602.
  17. McAllister BD, Rebholz BJ, Wang JC. Is posterior fusion necessary with laminectomy in the cervical spine? *Surg Neurol Int* 2012;3 Suppl 3:S225-31.
  18. Kaptain GJ, Simmons NE, Replogle RE, Pobereskin L. Incidence and outcome of kyphotic deformity following laminectomy for cervical spondylotic myelopathy. *J Neurosurg* 2000;93 2 Suppl: 199-204.
  19. Liu X, Min S, Zhang H, Zhou Z, Wang H, Jin A. Anterior corpectomy versus posterior laminoplasty for multilevel cervical myelopathy: A systematic review and meta-analysis. *Eur Spine J* 2014;23:362-72.
  20. Epstein NE, Hollingsworth R. C5 nerve root palsies following cervical spine surgery: A review. *Surg Neurol Int* 2015;6 Suppl 4:S154-63.
  21. Du W, Zhang P, Shen Y, Zhang YZ, Ding WY, Ren LX. Enlarged laminectomy and lateral mass screw fixation for multilevel cervical degenerative myelopathy associated with kyphosis. *Spine J* 2014;14:57-64.
  22. Anderson PA, Matz PG, Groff MW, Heary RF, Holly LT, Kaiser MG, *et al.* Laminectomy and fusion for the treatment of cervical degenerative myelopathy. *J Neurosurg Spine* 2009;11:150-6.
  23. Houten JK, Cooper PR. Laminectomy and posterior cervical plating for multilevel cervical spondylotic myelopathy and ossification of the posterior longitudinal ligament: Effects on cervical alignment, spinal cord compression, and neurological outcome. *Neurosurgery* 2003;52:1081-7.
  24. Revanappa KK, Rajshekhar V. Comparison of nurick grading system and modified Japanese Orthopaedic Association scoring system in evaluation of patients with cervical spondylotic myelopathy. *Eur Spine J* 2011;20:1545-51.
  25. Liu K, Shi J, Jia L, Yuan W. Surgical technique: Hemilaminectomy and unilateral lateral mass fixation for cervical ossification of the posterior longitudinal ligament. *Clin Orthop Relat Res* 2013;471:2219-24.
  26. Chen Y, Chen D, Wang X, Lu X, Guo Y, He Z, *et al.* Anterior corpectomy and fusion for severe ossification of posterior longitudinal ligament in the cervical spine. *Int Orthop* 2009;33:477-82.
  27. Uchida K, Nakajima H, Sato R, Yayama T, Mwaka ES, Kobayashi S, *et al.* Cervical spondylotic myelopathy associated with kyphosis or sagittal sigmoid alignment: Outcome after anterior or posterior decompression. *J Neurosurg Spine* 2009;11:521-8.
  28. Ito M, Nagahama K. Laminoplasty for cervical myelopathy. *Global Spine J* 2012;2:187-94.
  29. Cho WS, Chung CK, Jahng TA, Kim HJ. Post-laminectomy kyphosis in patients with cervical ossification of the posterior longitudinal ligament: Does it cause neurological deterioration? *J Korean Neurosurg Soc* 2008;43:259-64.
  30. Kumar VG, Rea GL, Mervis LJ, McGregor JM. Cervical spondylotic myelopathy: Functional and radiographic long term outcome after laminectomy and posterior fusion. *Neurosurgery* 1999;44:771-7.
  31. Huang RC, Girardi FP, Poynton AR, Cammisa FP Jr. Treatment of multilevel cervical spondylotic myelodysplasia with posterior decompression and fusion with lateral mass plate fixation and local bone graft. *J Spinal Disord Tech* 2003;16:123-9.
  32. Geck MJ, Eismont FJ. Surgical options for the treatment of cervical spondylotic myelopathy. *Orthop Clin North Am* 2002;33:329-48.
  33. Blizzard DJ, Gallizzi MA, Sheets C, Klement MR, Kleeman LT, Caputo AM, *et al.* The role of iatrogenic foraminal stenosis from lordotic correction in the development of C5 palsy after posterior laminectomy and fusion. *J Orthop Surg Res* 2015;10:160.
  34. Yi S, Yoon DH, Kim KN, Kim SH, Shin HC. Postoperative spinal epidural hematoma: Risk factor and clinical outcome. *Yonsei Med J* 2006;47:326-32.
  35. Takahashi Y, Sato T, Hyodo H, Kawamata T, Takahashi E. Symptomatic epidural haematoma after cervical laminoplasty: A report of three cases. *J Orthop Surg (Hong Kong)* 2016;24:121-4.