

Case report

Ceftazidime-resistance in pediatric melioidosis: A case report and literature review

Tonnii Loong-Loong Sia^{a,b,*}, Charles Dekun Lai^{c,d}, Kamilah Manan^e, Fu-Lung Khiu^d, Siti Zakiyyah Bakhtiar^f, Yek-Kee Chor^d, Su-Lin Chien^g, Lee-See Tan^g, Mong-How Ooi^{d,h}, Anand Mohan^{h,i,**}

^a Imperial College, London, United Kingdom

^b Department of Medicine, Miri Hospital, Miri, Sarawak, Malaysia

^c Faculty of Medicine and Health Sciences, Universiti Malaysia Sarawak, Sarawak, Malaysia

^d Department of Pediatrics, Sarawak General Hospital, Kuching, Sarawak, Malaysia

^e Department of Radiology, Bintulu Hospital, Bintulu, Sarawak, Malaysia

^f Department of Pharmacy, Sarawak General Hospital, Kuching, Sarawak, Malaysia

^g Department of Pathology, Bintulu Hospital, Bintulu, Sarawak, Malaysia

^h Institute of Health and Community Medicine, Universiti Malaysia Sarawak, Sarawak, Malaysia

ⁱ Department of Pediatrics, Bintulu Hospital, Bintulu, Sarawak, Malaysia

ARTICLE INFO

Keywords:

Melioidosis

Burkholderia pseudomallei

Ceftazidime

Antimicrobial resistance

ABSTRACT

We report a first case of ceftazidime-resistant pediatric melioidosis involving a previously healthy seven-year-old boy who presented with right lobar pneumonia complicated with a 5-cm lung abscess. Ceftazidime was initiated on Day-6 of admission when *Burkholderia pseudomallei* (ceftazidime-susceptible, minimum inhibitory concentration [MIC] 1.0 mcg/mL) was isolated from blood. Despite ceftazidime therapy at the recommended dosage, he developed fulminant septic shock and respiratory failure on Day-18 of hospitalization, requiring invasive ventilation, hemodynamic support, and continuous renal replacement therapy. His antibiotic was empirically escalated to meropenem; ceftazidime-resistant *B. pseudomallei* (MIC 32 mcg/mL) was subsequently isolated from blood and endotracheal secretions. He improved after two weeks of intensive care and was discharged well after two months of hospitalization. Our literature review on ceftazidime-resistant *B. pseudomallei* infection indicates that acquired resistance is a rare but potentially lethal treatment-related complication. All melioidosis patients should be carefully monitored during treatment with ceftazidime (or other β -lactams) for the development of antimicrobial resistance.

Introduction

Melioidosis, a community-acquired infection with protean clinical manifestations caused by the environmental saprophyte *Burkholderia pseudomallei* (*Bp*), is an important cause of mortality and morbidity among residents of and travellers to the tropics [1]. Fatality rates up to 40 % are still reported and are associated with deficiencies in clinical recognition, diagnostic capacity, antimicrobial therapy, and intensive care management [2]. A key factor relating to these high fatality rates is that patients often do not receive *Bp*-active empiric antibiotics, as this soil-borne pathogen is intrinsically resistant to most antibiotics used for

treatment of community-acquired infections [3].

Ceftazidime is highly active against *Bp*. Compared with other third generation cephalosporins, ceftazidime has a more complex moiety that confers extra stability against beta-lactamases [3,4]. Importantly, ceftazidime was shown to halve melioidosis mortality in a landmark trial [5]. Effective antibiotic treatment of melioidosis consists of an initial intravenous intensive phase followed by an oral eradication phase. According to international guidelines, 2–8 weeks of ceftazidime or a carbapenem is recommended during the intensive phase [6]. While carbapenems have the lowest minimum inhibitory concentrations (MIC) against *Bp* and in-vitro time-kill studies as well as observational data

* Corresponding author at: Imperial College, London, United Kingdom.

** Corresponding author at: Institute of Health and Community Medicine, Universiti Malaysia Sarawak, Sarawak, Malaysia.

E-mail addresses: tls22@ic.ac.uk (T.L.-L. Sia), anand_bintulu@yahoo.com (A. Mohan).

suggest carbapenems perform better than ceftazidime [2], the latter remains the first line treatment in most regions due to its availability, cost, and antimicrobial stewardship concerns.

While the global surge in the frequency of antimicrobial resistance among community-acquired pathogens has become a major public health concern, ceftazidime-resistance in melioidosis has only infrequently been reported. Little is known about the epidemiology, risks, disease course, treatment, and outcome of ceftazidime-resistant melioidosis. In this report, we present a child with melioidosis who deteriorated following development of acquired ceftazidime-resistance and review the literature on ceftazidime-resistance in melioidosis.

Case report

A previously healthy seven-year-old boy (height 117 cm; weight 15 kg) presented to a district hospital with a week of fever and cough. On admission, he was febrile, had normal blood pressure, and had mild respiratory distress. Respiratory system examination suggested right lung consolidation. Chest radiography showed a round cavitation containing an air-fluid level in the right lower zone (Fig. 1).

He was diagnosed with community-acquired pneumonia and started on intravenous ampicillin and oral erythromycin. This was escalated to intravenous cefuroxime the next day and to piperacillin-tazobactam at Day-5 of hospitalization when Gram-negative bacilli were detected in the blood culture obtained the day before (no bacterial cultures were performed prior to this). His antibiotic was switched to ceftazidime 750 mg (50 mg/kg/dose) infused over three hours four times a day the following day when the Gram-negative bacillus was identified as *Bp* (ceftazidime-susceptible, MIC 1.0 mcg/mL). A bacterial blood culture obtained on Day-8 was negative.

Computed tomography (CT) of the thorax confirmed a 5-cm lung abscess at the right posterobasal segment with small bilateral pleural effusions (Fig. 2). Following discussions with the pediatric surgical unit, a decision for non-operative management of the abscess was made, and no drainage/resection was performed. Serial clinical and laboratory investigation results are shown in Table 1.

Despite intravenous ceftazidime, he continued to have high fever. On Day-18 of hospitalization, he abruptly deteriorated with respiratory failure and septic shock. Chest radiography showed extensive right lung consolidation (Fig. 1). He was promptly intubated for mechanical ventilatory support, and the antibiotic was empirically escalated to meropenem 600 mg (40 mg/kg/dose) infused over four hours three times a day. He required resuscitation with fluid boluses, multiple inotropes and vasopressors, and continuous renal replacement therapy (CRRT). *Bp* was again isolated from the blood culture obtained prior to

administration of meropenem; however, antibiotic susceptibility testing was not performed. He was then transferred to a tertiary pediatric intensive care unit at Day-20. Here, blood and endotracheal secretion cultures grew ceftazidime-resistant *Bp* (MIC 32 mcg/mL). These isolates were susceptible to meropenem (MIC 0.75 mcg/mL), amoxycillin/clavulanic acid (MIC 2.0 mcg/mL), and cotrimoxazole (MIC 2.0 mcg/mL). In both hospitals, *Bp* was identified using the API®20NE (BioMérieux, France) biochemical test and antibiotic susceptibility testing were performed using E-tests (BioMérieux, France).

His clinical condition gradually improved thereafter. Despite persistent fever and positive endotracheal secretion cultures (ceftazidime-resistant *Bp*, MIC 32 mcg/mL) obtained on Day-29–33 of hospitalization, serial serum procalcitonin measurement showed a significant and steady decline indicative of satisfactory antibiotic treatment response (Table 1). He received seven days of CRRT and fourteen days of mechanical ventilatory support. A repeated CT thorax at Day-33 showed necrotising pneumonia at the right upper and middle lobes and resolution of the lung abscess. The fever finally abated at Day-34 of hospitalization.

He received six weeks of meropenem and was discharged after two months of hospitalization. At his 4-month post-discharge follow-up, he was asymptomatic and had good weight gain. He completed four months of eradication therapy with oral cotrimoxazole 400 mg/80 mg (~25/5 mg/kg) twice a day.

As there are no published clinical guidance on ceftazidime-resistant melioidosis in childhood, we reviewed the available literature to better understand this treatment-related clinical challenge.

Literature review

We searched the PubMed/MEDLINE database using the MeSH keywords ((*burkholderia pseudomallei*) OR (*pseudomonas pseudomallei*) OR (melioidosis)) AND (ceftazidime) from inception until December 2023 to identify studies reporting epidemiological and clinical characteristics of ceftazidime-resistance in human melioidosis. Initial screening recovered 386 studies. After including additional records identified from references within articles and other sources, 29 relevant studies, including seven case reports, were identified. All of the studies reported ceftazidime-resistant melioidosis among adult patients; no cases of ceftazidime-resistance in pediatric melioidosis were reported. The main findings of these studies are summarised in Table 2.

In the largest studies published, ceftazidime-resistance was reported in 0.5–2.0 % of cases [13,33,35]. Higher resistance rates were, however, documented in a few smaller studies from Indonesia (41 %), Malaysia (9 %), and China (7–13 %) [18,21,25,26]. Although geographical

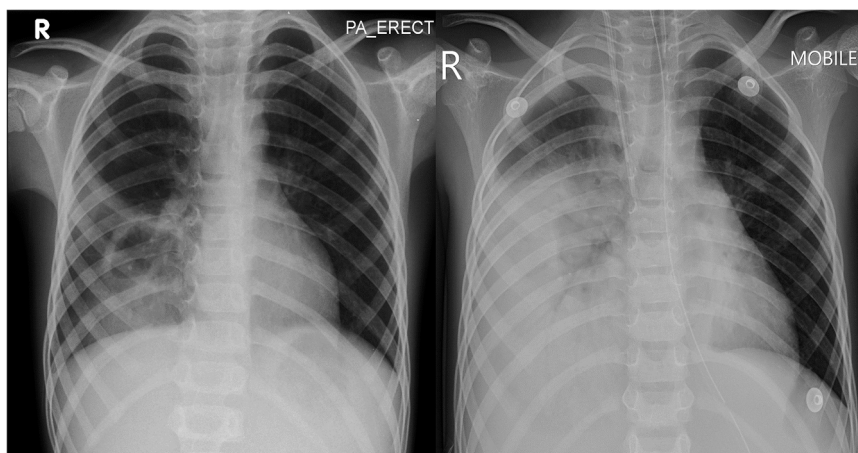


Fig. 1. Serial chest radiograph images showing a thick-walled cavity with air-fluid level in the right lower zone at admission (left) which progressed into a fairly homogenous consolidation involving the same region on day-18 of hospitalization (right).

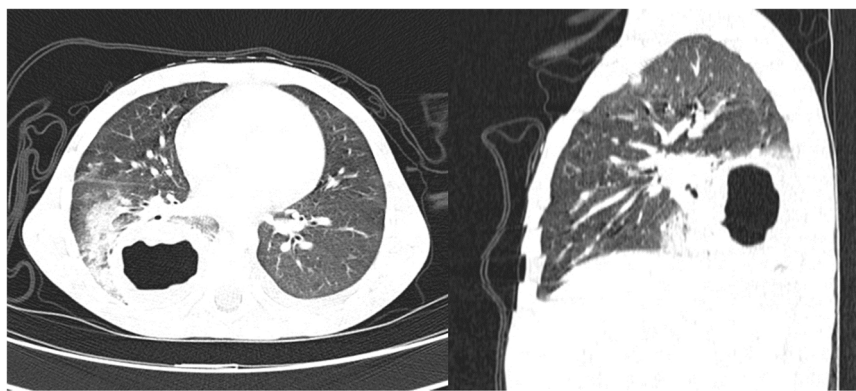


Fig. 2. Axial (left) and sagittal (right) computed tomography images in lung window performed on day-8 of hospitalization depicting a thick-walled cavity in the right lower lobe with consolidation of the surrounding lung parenchyma.

variations in drug susceptibility may be a plausible explanation [36], variations in laboratory methods could also have contributed to these aberrant findings. As *Bp* MICs are close to 'breakpoint' values for many antibiotics, minor variations in the medium and inoculum used could result in a change to the susceptibility category [12].

Nearly all ceftazidime-resistance in melioidosis was acquired; primary resistance was exceedingly rare. For example, only 2 (0.05 %) of 4021 melioidosis cases in Thailand were associated with primary ceftazidime-resistance [35]. Similarly, only sporadic cases of primary resistance have been documented elsewhere [8,27].

Acquired ceftazidime-resistance was detected a median of 15 days (range 6–31 days) after admission [35], typically during treatment with the antimicrobial. Additionally, acquired ceftazidime-resistance can occur following exposure to antimicrobials other than ceftazidime, viz., without exposure to ceftazidime. For example, two of seven acquired ceftazidime-resistant cases developed resistance to both ceftazidime and co-amoxiclav although both patients had not received either of these drugs; they had, however, received other β -lactam antibiotics [13].

Apart from the frequent presence of suppurative collections (involving soft tissue, spleen, kidney, and mediastinum) [11,12,22,29], no other distinguishing characteristics were evident in patients who developed ceftazidime-resistant disease. In the few case reports that detailed clinical progression, non-resolving presenting manifestations, as was observed in our case, or an initial improvement followed by deterioration were noteworthy disease courses [22,29]. Ceftazidime-resistant strains were also detected in cases of recrudescence and relapse after initial treatment of ceftazidime-susceptible disease [28]. Non-blood specimens were the predominant source of resistant isolates (72 % of resistant cases were detected from non-blood samples) [35].

In most cases, a carbapenem was used after the detection of ceftazidime-resistant *Bp*, as nearly all the isolates remained susceptible to this antibiotic class [35]. To what extent the development of acquired ceftazidime-resistance affected patients' outcomes were unclear, as mortality rates in melioidosis are high even in ceftazidime-susceptible disease [1]. One study reported that mortality in 3 (43 %) of 7 ceftazidime-resistant cases were directly attributable to the antibiotic resistance [13].

Acquired ceftazidime-resistance in *Bp* was shown to arise through several mechanisms. Increased ceftazidime hydrolysis mediated by altered substrate specificity due to single-nucleotide polymorphisms in the *penA* gene (that encodes the class A β -lactamase, penA) was most frequently cited [17,27,28]. Alternatively, loss of the drug target, penicillin-binding protein (PBP) 3, through deletion of the PBP 3 encoding gene was determined to be the cause of ceftazidime-resistance in six patients who had treatment failure [11]. In this study, the resistant strains were not initially detected, as they had failed to grow in routine culture media, a phenomenon attributed to the wider genomic loss

associated with the PBP 3 gene deletion. These findings suggest that therapeutic failure due to acquired ceftazidime-resistance (due to PBP 3 gene deletion) may be more prevalent than reported. Indeed, treatment failure occurs in as many as 11–17 % of melioidosis patients while acquired ceftazidime-resistance is confirmed in only 0.5–2.0 % of patients [37].

Discussion

To the best of our knowledge, this is the first report of ceftazidime-resistance in paediatric patients. There are several plausible reasons for the development of acquired ceftazidime-resistance in our patient, including the presence of a large unresected lung abscess. Although many patients who developed acquired ceftazidime-resistance were reported to have melioidosis abscesses or sequestered foci of infection, it is unclear if this represents a true risk factor for acquired ceftazidime-resistance, as suppurative collections are detectable in over 50 % of all *Bp* infection [36,38]. Nevertheless, it would be reasonable to assume that the presence of high bacterial loads in niches not easily penetrated by antimicrobials could facilitate the genetic mutations that result in resistance. Another possible risk for the development of acquired resistance in our patient was the initial use of antibiotics that were ineffective against *Bp*. Prolonged exposure to antimicrobials without eradication promotes development of antimicrobial resistance [39]. Indeed, ceftazidime-resistance has been reported even with exposure to non-ceftazidime β -lactam antibiotics [13].

Despite the lack of supportive evidence from our literature search, rapid clearance of *Bp* from the blood and other sites should be sought in every case of melioidosis, as this presumably could hinder development of resistance. Foremost to this will be avoiding delays in diagnosis and initiation of melioidosis-appropriate antibiotics. Additionally, as it is not uncommon to isolate ceftazidime-susceptible *Bp* from blood for several days despite ceftazidime treatment - delayed bacterial clearance lasting ≥ 7 days was reported in 3–9 % of bacteremic patients [37] - dosing regimens of ceftazidime should be optimized to improve bacterial killing. Ceftazidime pharmacologic and pharmacodynamic studies have shown that continuous infusion provides longer time above MIC and therefore improved bactericidal activity [40,41]. Augmented renal clearance in critically ill or septic patients could lead to subtherapeutic levels of β -lactam antibiotics and hence dose adjustments may be required [42]. Similar to guidelines that recommend addition of oral cotrimoxazole to intensive phase treatment when certain organ-sites are involved [43], the role of non-antagonistic combinations of ceftazidime with unrelated antimicrobials should also be explored. Undoubtedly, source control - either drainage or removal of suppurative foci - should be attempted whenever possible.

Several patterns of disease progression were identified in patients with acquired ceftazidime-resistance. These included unrelenting

Table 1

Clinical and laboratory investigation results for a child with melioidosis complicated by acquired ceftazidime-resistance, Sarawak, Malaysia.

Investigation	Day-1	Day-4	Day-5	Day-8	Day-18	Day-20	Day-21	Day-26	Day-29	Day-31	Day-42–58
Highest body temperature recorded (°C)*	40.8	40.7	41.3	39.8	39.8	38.1	37.0	37.0	38.5	38.0	37.0
Hemoglobin, g/dL	10.0	-	8.7	7.8	7.7	7.9	6.3	7.9	11.1	9.0	11.9
Total white cell count, $\times 10^9$ cells/L	10.2	-	8.1	7.0	1.8	-	6.6	9.8	14.8	17.0	14.6
Neutrophil count, $\times 10^9$ cells/L	8.4	-	6.7	5.2	1.5	-	4.8	6.4	9.9	13.0	-
Lymphocyte count, $\times 10^9$ cells/L	1.3	-	0.9	1.2	0.2	-	0.5	1.5	1.9	1.8	-
Platelet count, $\times 10^9$ cells/L	371	-	211	164	207	88	29	52	148	334	626
C-reactive protein, mg/L	186	-	249	193	223	-	-	-	-	-	3
Procalcitonin, ng/mL	-	-	-	-	-	65.5	25.3	2.3	0.89	0.41	-
Blood C&S	-	<i>Bp</i>	<i>Bp</i>	NG	<i>Bp</i>	<i>Bp</i>	NG	-	NG	NG	NG
Endotracheal tube aspirate C&S	NA	NA	NA	NA	-	-	-	-	<i>Bp</i>	<i>Bp</i>	NG
<i>Bp</i> ceftazidime MIC, mcg/mL (susceptibility category)	NA	1.0 (S)	NT	NA	NT	32 (R)	NA	NA	32 (R)	32 (R)	NA
Estimated creatinine clearance (mL/min/1.73m ²)*§	-	-	271	230	-	93	237	> 379	334	> 379	184
Antibiotics received	ampicillin 750 mg (50 mg/kg/dose) 6 H IV; erythromycin ethylsuccinate 300 mg (20 mg/kg/dose) 12 H orally	cefuroxime 750 mg (50 mg/kg/dose) 8 H IV	piperacillin-tazobactam 1.5 g (100 mg/kg/dose) 6 H	ceftazidime 750 mg(50 mg/kg/dose) 6 H, infused over 3 hours	meropenem 600 mg (40 mg/kg/dose) 8 H, infused over 4 hours	meropenem 2250 mg/day (150 mg/kg/day) continuous infusion	As previous	meropenem 2700 mg/day (180 mg/kg/day) continuous infusion from Day–24	As previous	As previous	meropenem 2250 mg/day (150 mg/kg/day) continuous infusion from Day–44; meropenem 860 mg (50 mg/kg/dose) 8 H, infused over 3 hours from Day–53

Abbreviations: C&S, culture and sensitivity; *Bp*, *Burkholderia pseudomallei*; NG, no growth; NA, not applicable; MIC, minimum inhibitory concentration; S, susceptible; NT, not tested; R, resistant; H, hourly; IV, intravenous.

*Values affected by continuous renal replacement therapy performed from Day-20 until Day-27.

§The Schwartz formula was used for calculation of estimated creatinine clearance.

Table 2

Characteristics and salient findings of studies reporting ceftazidime-resistant melioidosis in the English language literature up to December 2023.

Reference	Region, country; study period; study type	Method of AST	Number (%) of cases or isolates	Type of resistance*	Age (y), gender	Risk factors; presenting illness	Clinical manifestations or affected organs/sites	Antibiotic treatment	Outcome	Key scientific findings and further remarks
Agrawal et al. [7]	Mumbai, India; 2023; CR	Disk diffusion	1 patient	Primary	Middle-aged, male	DM; fever and headache for 8 weeks	Brain abscess	MEM, SXT	Survived	As the patient had received prior antimicrobial treatment (ceftriaxone, metronidazole, first line anti-TB), the CAZ resistance may in fact be acquired.
Ahmad et al. [8]	11/14 states in Malaysia; 2001–2009; DR	E-test	1 (<1 %) of 170 cases	Primary	NR	NR	Bacteremia	NR	Died	The CAZ-resistant strain was isolated from blood culture of a case who had no history of melioidosis and succumbed a day after admission. The isolates showed a heterogenous <i>Bp</i> population. No information about prior antibiotic treatment was available.
Behera et al. [9]	Andhra Pradesh, India; 2011; CR	NR	1 patient	Primary	39, male	DM; fever for 8 M, left elbow swelling for 1 M	Bacteremia, septic arthritis, lung/liver/ spleen abscesses	IPM	Survived	As the patient had received prior antimicrobial treatment (antimalarials and multiple courses of oral antimicrobials), the CAZ resistance may in fact be acquired.
Behera et al. [10]	Odisha, India; 2015–2017; DR	Disk diffusion and E-test	2 (4 %) of 47 cases	NR	NR	NR	Both cases had bacteremia	NR	NR	-
Chantratita et al. [11]	Northeast Thailand, Thailand; 2006–2007; DR	E-test	6 patients	Acquired	NR	Multiple splenic abscesses, other typical presentations	Unresolved fever despite CAZ and splenectomy	SXT and DXT	2/6 died	All the isolates had complete deletion of a PBP 3 gene and marked growth defect (failure to grow in culture media) due to an associated loss of 49 genes.
Dance et al. [12]	Northeast Thailand, Thailand; 1986–1988; PO	Agar dilution	1 (0.5 %) of 221 isolates	Acquired	NR	CKD, urolithiasis; Renal abscess	Septicaemia	Drainage and oral AMC	Survived	The resistant strain was isolated after 19 days of CAZ treatment.
Dance et al. [13]	Ubon Ratchathani, Thailand; 1986–1989; PO	Disk diffusion and agar dilution	7 (2 %) of 400 cases	Acquired	NR	NR	NR	NR	3 died	In 5 patients, resistance to CAZ developed after ≥ 7 days of CAZ; In 2 others, resistance to CAZ developed without exposure to CAZ; both had received ≥ 2 days of other β -lactams.
Hadano [14]	Japan; 1990–2017; DR	NR	1 (7 %) of 14 patients	NR	65, male	DM; fever and dysuria	Pneumonia, OM, septic arthritis, abdominal abscess	MEM, Minomycin	Survived	All the 14 cases were travel-related (imported) melioidosis.
Hassan et al. [15]	Alor Setar, Malaysia; 2005–2010; DR	Disk diffusion	5 (2.2 %) of 228 cases	NR	NR	NR	NR	NR	NR	No significant differences in clinical features and outcome with susceptible versus non-susceptible strains were identified.
Heng et al. [16]	Singapore; 1992–1996; PO	NR	3 (0.9 %) of 319 isolates	NR	NR	NR	NR	NR	NR	-
Hii et al. [17]	Northeast Thailand; 2015–2018; PO	Broth microdilution	2 (0.2 %) of 1304 isolates, 1 (8 %) of 13 relapse cases	Acquired	NR	2 patients had DM, 1 had TB, COPD, CKD; NR	NR	MEM, SXT	2/3 died	All cases had received prolonged courses of CAZ prior to detection of the resistant isolate.

(continued on next page)

Table 2 (continued)

Reference	Region, country; study period; study type	Method of AST	Number (%) of cases or isolates	Type of resistance*	Age (y), gender	Risk factors; presenting illness	Clinical manifestations or affected organs/sites	Antibiotic treatment	Outcome	Key scientific findings and further remarks
Hui et al. [18]	Hainan, China; 2015–2020; DR	VITEK 2 automated	3 (7 %) of 45 cases	NR	NR	NR	NR	NR	NR	All isolates were susceptible to carbapenems.
Jenney et al. [19]	Northern Territory, Australia; 1989–1999; PO	Agar dilution and E-test	1 (0.6 %) of 170 isolates	Acquired	NR	NR	NR	NR	NR	The isolate was obtained from a case of relapsed melioidosis.
Karuna et al. [20]	West Bengal, India; 2015; CR	NR	1 patient	Primary	48, male	Fever and cough for 1 M, peritonitis	Pneumonia, ileal perforation	IPM, DXT	Survived	As the patient had received prior antimicrobial treatment (anti-TB and possibly other antimicrobials), the CAZ resistance may in fact be acquired.
Khosravi et al. [21]	Malaysia; NR; DR	Broth dilution and E-test	6 (9 %) of 70 isolates	NR	NR	NR	NR	NR	NR	-
Kung et al. [22]	Kaohsiung Hsien, Taiwan; 2010; CR	Vitek GNS–131 cards (BiomérieuxVitek Inc, USA) and E-test	1 patient	Acquired	48, male	Alcohol; fever and constitutional symptoms for 3 weeks	Mediastinal lymphadenitis, tissue culture at Day 29 grew CAZ-resistant <i>Bp</i>	IPM after Day 29	Survived	The patient was initially treated with ceftriaxone for 5 days. There was no molecular confirmation of clonality.
Lo et al. [23]	Singapore, 1998–2007; PO	NR	5 (0.9 %) of 575 isolates	NR	NR	NR	NR	NR	NR	-
Paveenkittiporn et al. [24]	Thailand; 2000–2004; PO	Disk diffusion	1.5 % of isolates	NR	NR	NR	NR	NR	NR	-
Rahayu et al. [25]	Malang, Indonesia; 2011–2013; DR	Disk diffusion	21 (41 %) of 51 cases	NR	NR	NR	NR	NR	NR	Ten (20 %) cases had resistance to both CAZ and MEM
Rao et al. [26]	Hainan, China; 2004–2016; DR	BD Phoenix–100 (Becton, Dickinson and Company, USA)	21 (13 %) of 164 cases	NR	NR	NR	NR	NR	NR	Some PFGE types were associated with more resistance. Significant increase in resistance over the study period was noted.
Sam et al. [27]	Kuala Lumpur, Malaysia; 2009; CR	E-test	1 patient	primary	57, male	DM; severe pneumonia	NR	CAZ	NR	The patient had received initial treatment with ampicillin-sulbactam. Findings suggest clonal population containing subpopulations with differing susceptibility.
Sarovich et al. [28]	Darwin, Australia; 1991, 2001; DR	E-test	2 patients	Acquired	Patient 1: 63, male; Patient 2: 61, male	Patient 1: DM, CKD, alcohol; recrudescence disease; Patient 2: DM, CA; relapsing disease	-	Patient 1: CAZ and AMC; Patient 2: CAZ, DXT, CMC	Patient 1: died; Patient 2: CA	As the patient had received prior antimicrobial treatment (ampicillin-sulbactam), the CAZ resistance may in fact be acquired
Sarovich et al. [29]	Thailand; 2012; CR	E-test	1 patient	Acquired	51, male	Fever with soft tissue (leg) abscess	Improvement followed by deterioration after 2 weeks	CAZ	Died	<i>Bp</i> isolates obtained from these cases were found to have <i>penA</i> single-nucleotide polymorphisms that directly increased CAZ hydrolysis.
Sood et al. [30]	Rajasthan, India; 2010; CR	Microscan autoScan–4 (Siemens, USA)	1 patient	Primary	49, male	Fever and SOB for 1 week	Needed intensive care	IPM	Died	The case had been treated with ceftriaxone and clindamycin for 1 day before initiation of CAZ.
										Isolates had MIC > 16 µg/mL. No documentation about prior antibiotic use before hospital admission.

(continued on next page)

Table 2 (continued)

Reference	Region, country; study period; study type	Method of AST	Number (%) of cases or isolates	Type of resistance*	Age (y), gender	Risk factors; presenting illness	Clinical manifestations or affected organs/sites	Antibiotic treatment	Outcome	Key scientific findings and further remarks
Sookpranee et al. [31]	Khon Kaen, Thailand; NR, DR	Disk diffusion and agar dilution	< 0.5 % of 199 isolates	NR	NR	NR	NR	NR	NR	-
Stoesser et al. [32]	Siem Reap, Cambodia; 2007–2011; DR	Disk diffusion	1 (4 %) of 23 patients	NR	< 15 year, NR	pediatric suppurative parotitis	NR	NR	Survived	Antibiotic treatment prior to admission was common.
Tan et al. [33]	Singapore; 1987–1989; 1996–2007; DR	Disk diffusion	0.5 % of 1278 isolates	NR	NR	NR	NR	NR	NR	No increase in CAZ resistance over study period.
Thibault et al. [34]	Vietnam, Thailand, Hong Kong, Malaya, Singapore, Australia, Chad, England; 1923–2001; DR	Agar dilution	1 (2 %) of 50 isolates	NR	NR	NR	NR	NR	NR	The isolate remained susceptible to IPM.
Wuthiekanun et al. [35]	Ubon Ratchathani, Thailand; 1987–2007; PO	Disk diffusion and E-test	20 (0.6 %) of 4021 cases	Acquired; primary CAZ resistance in 2 (0.05 %) of 4021 cases	NR	NR	NR	NR	NR	Median duration of CAZ treatment before detection of resistance was 15 days

Abbreviations: AST, antimicrobial susceptibility testing; y, year; CR, case report; DM, diabetes mellitus; MEM, meropenem; SXT, cotrimoxazole; TB, tuberculosis; CAZ, ceftazidime; DR, descriptive retrospective; NR, not reported; *Bp*, *Burkholderia pseudomallei*; M, months; IPM, imipenem; DXT, doxycycline; PBP, penicillin binding protein; PO, prospective observational; CKD, chronic kidney disease; AMC, co-amoxiclav; OM, osteomyelitis; COPD, chronic obstructive pulmonary disease; PFGE, pulsed-field gel electrophoresis; CMC, chloramphenicol; CA, carcinoma; SOB, shortness of breath; MIC, minimum inhibitory concentration.

*Ceftazidime resistance was categorized as primary if the first positive clinical isolate of *Burkholderia pseudomallei* was resistant to ceftazidime and the patient had not received prior ceftazidime treatment. Ceftazidime resistance was categorized as acquired if an initial *Burkholderia pseudomallei* isolate was shown to be susceptible to ceftazidime and a subsequent isolate obtained during or after treatment with ceftazidime (or other B-lactams) was resistant.

§Intermediate ceftazidime susceptibility was characterized by a minimum inhibitory concentration of 16 mcg/mL.

presenting manifestations, an initial improvement followed by deterioration, and relapse of infection after initial treatment success. Each scenario presents challenges to early recognition of acquired resistance. Firstly, fever clearance in melioidosis takes longer than most other bacterial infections, with a median of up to nine days [44]. This may cause difficulties in differentiating a typical course of disease resolution from the development of drug resistance. In the second scenario, common clinical problems encountered in hospital and intensive care settings, such as nosocomial sepsis, ventilator-associated pneumonia, and pulmonary thromboembolism, are more plausible reasons for an initial improvement followed by deterioration compared to acquired ceftazidime-resistance. Finally, relapses are more commonly caused by a *Bp* strain that remains susceptible rather than a strain that has acquired resistance. Due to these difficulties, we believe that clinical vigilance and close clinical and laboratory monitoring are vital in early detection of ceftazidime-resistance. Slow clinical resolution or persistently elevated sepsis markers (e.g., procalcitonin), deterioration after seven days of treatment, or recurrent melioidosis should prompt suspicion of acquired ceftazidime-resistance.

The empirical switch to a carbapenem following the clinical deterioration in our patient was likely a key factor of the favourable outcome. The role of antimicrobials other than carbapenems in treating ceftazidime-resistant *Bp* is unclear. For example, clinical studies on the use of newer agents such as ceftazidime/avibactam have not been performed although they do have excellent in vitro activity against *Bp* [45]. For now, the use of carbapenems seems prudent if ceftazidime-resistance is confirmed or when it is suspected in the presence of life-threatening disease.

Conclusions

Ceftazidime-resistance in melioidosis is a rare yet potentially lethal treatment-related complication. Although it is uncommon, all melioidosis patients should be carefully monitored during treatment with ceftazidime (or other β -lactams) for development of acquired antimicrobial resistance. Ceftazidime should remain the initial antibiotic of choice in the intensive treatment phase, and routine use of carbapenems in patients not requiring intensive care should be discouraged. Little is known of the risks for acquired ceftazidime-resistance and whether or how these risks could be overcome, and this underscores a need for more comprehensive research.

CRediT authorship contribution statement

Charles Dekun Lai: Writing – review & editing, Writing – original draft, Project administration. **Tonni Sia:** Writing – review & editing, Writing – original draft, Validation, Project administration. **Yek-Kee Chor:** Writing – review & editing, Supervision, Project administration. **Siti Zakiyyah Bakhtiar:** Writing – review & editing, Investigation. **Fu-Lung Khiu:** Writing – review & editing, Project administration, Investigation. **Kamilah Manan:** Writing – review & editing, Project administration, Investigation. **Anand Mohan:** Writing – review & editing, Writing – original draft, Methodology, Formal analysis, Conceptualization. **Mong-How Ooi:** Writing – review & editing, Supervision, Formal analysis, Data curation, Conceptualization. **Lee-See Tan:** Writing – review & editing, Investigation. **Su-Lin Chien:** Writing – review & editing, Investigation.

Ethical approval

The study was approved by the Malaysian Medical Research Ethics Committee under National Medical Research Registry (NMRR-16-1029-31390). All data analyzed were anonymized.

Consent

Written informed consent was obtained from the patient's parents for publication of this case report and accompanying images. A copy of the written consent is available for review by the Editor-in-Chief of this journal on request.

Funding

There is no funding received in this study.

Declaration of Competing Interest

The authors declare the following financial interests/personal relationships which may be considered as potential competing interests: Reports a relationship with that includes: Has patent pending to. If there are other authors, they declare that they have no known competing financial interests or personal relationships that could have appeared to influence the work reported in this paper.

Acknowledgements

The authors would like to thank the Director General of Health Malaysia for the permission to publish this paper. We also thank all the doctors and nurses in the Pediatric and Intensive Care wards as well as our colleagues in the Departments of Microbiology and Radiology in both Sarawak General Hospital and Bintulu Hospital for their expertise in the diagnosis and management of the patient.

References

- [1] Gassiep I, Armstrong M, Norton R. Human Melioidosis. *Clin Microbiol Rev* 2020;33(2).
- [2] Currie BJ. Melioidosis: evolving concepts in epidemiology, pathogenesis, and treatment. *Semin Respir Crit Care Med* 2015;36(1):111–25.
- [3] McEniry DW, Gillespie SH, Felmingham D. Susceptibility of *Pseudomonas pseudomallei* to new beta-lactam and aminoglycoside antibiotics. *J Antimicrob Chemother* 1988;21(2):171–5.
- [4] Richards DM, Brogden RN. Ceftazidime. A review of its antibacterial activity, pharmacokinetic properties and therapeutic use. *Drugs* 1985;29(2):105–61.
- [5] White NJ, Dance DA, Chaowagul W, Wattanagoon Y, Wuthiekanun V, Pitakwatchara N. Halving of mortality of severe melioidosis by ceftazidime. *Lancet* 1989;2(8665):697–701.
- [6] Sullivan RP, Marshall CS, Anstey NM, Ward L, Currie BJ. 2020 Review and revision of the 2015 Darwin melioidosis treatment guideline: paradigm drift not shift. *PLoS Negl Trop Dis* 2020;14(9):e0008659.
- [7] Agrawal U, Sunavala A, Vaidya V, Roy R, Basu S, Drego L, et al. Ceftazidime-resistant *Burkholderia pseudomallei* masquerading as isolated atypical neuromelioidosis. *Indian J Med Microbiol* 2023;41:111–3.
- [8] Ahmad N, Hashim R, Mohd Noor A. The in vitro antibiotic susceptibility of Malaysian isolates of *Burkholderia pseudomallei*. *Int J Microbiol* 2013;2013:121845.
- [9] Behera B, Prasad Babu TL, Kamalesh A, Reddy G. Ceftazidime resistance in *Burkholderia pseudomallei*: first report from India. *Asian Pac J Trop Med* 2012;5(4):329–30.
- [10] Behera B, Mohanty S, Mahapatra A, Hallur VK, Mishra B, Dey A, et al. Melioidosis in Odisha: a clinico-microbiological and epidemiological description of culture-confirmed cases over a 2-year period. *Indian J Med Microbiol* 2019;37(3):430–2.
- [11] Chantaratita N, Rholl DA, Sim B, Wuthiekanun V, Limmathurotsakul D, Amornchai P, et al. Antimicrobial resistance to ceftazidime involving loss of penicillin-binding protein 3 in *Burkholderia pseudomallei*. *Proc Natl Acad Sci USA* 2011;108(41):17165–70.
- [12] Dance DA, Wuthiekanun V, Chaowagul W, White NJ. The antimicrobial susceptibility of *Pseudomonas pseudomallei*. Emergence of resistance in vitro and during treatment. *J Antimicrob Chemother* 1989;24(3):295–309.
- [13] Dance DA, Wuthiekanun V, Chaowagul W, Suputtamongkol Y, White NJ. Development of resistance to ceftazidime and co-amoxiclav in *Pseudomonas pseudomallei*. *J Antimicrob Chemother* 1991;28(2):321–4.
- [14] Hadano Y. Imported melioidosis in Japan: a review of cases. *Infect Drug Resist* 2018;11:163–8.
- [15] Hassan MR, Vijayalakshmi N, Pani SP, Peng NP, Mehenderkar R, Voralu K, et al. Antimicrobial susceptibility patterns of *Burkholderia pseudomallei* among melioidosis cases in Kedah, Malaysia. *Southeast Asian J Trop Med Public Health* 2014;45(3):680.
- [16] Heng BH, Goh KT, Yap EH, Loh H, Yeo M. Epidemiological surveillance of melioidosis in Singapore. *Ann Acad Med Singap* 1998;27(4):478–84.

- [17] Fen SHY, Tandhavanant S, Phunpang R, Ekcharyawat P, Saiprom N, Chewapreecha C, et al. Antibiotic susceptibility of clinical *Burkholderia pseudomallei* isolates in northeast Thailand during 2015–2018 and the genomic characterization of beta-lactam-resistant isolates. *Antimicrob Agents Chemother* 2023;95(5).
- [18] Hui H, Sheng Y, Han X, Wang S, Zhang G, Wei X. A clinical study on clinical features, manifestations and drug resistance of melioidosis. *Pak J Med Sci* 2022;38(8):2301–6.
- [19] Jenney AW, Lum G, Fisher DA, Currie BJ. Antibiotic susceptibility of *Burkholderia pseudomallei* from tropical northern Australia and implications for therapy of melioidosis. *Int J Antimicrob Agents* 2001;17(2):109–13.
- [20] Karuna T, Khadanga S, Dugar D, Sau B, Bhoi P. Melioidosis as a cause of acute abdomen in immuno-competent male from eastern India. *J Lab Physicians* 2015;7(1):58–60.
- [21] Khosravi Y, Vellasamy KM, Mariappan V, Ng SL, Vadivelu J. Antimicrobial susceptibility and genetic characterisation of *Burkholderia pseudomallei* isolated from Malaysian patients. *ScientificWorldJournal* 2014;2014:132971.
- [22] Kung CT, Lee CH, Li CJ, Lu HI, Ko SF, Liu JW. Development of ceftazidime resistance in *Burkholderia pseudomallei* in a patient experiencing melioidosis with mediastinal lymphadenitis. *Ann Acad Med Singap* 2010;39(12):945–3.
- [23] Lo TJ, Ang LW, James L, Goh KT. Melioidosis in a tropical city state, Singapore. *Emerg Infect Dis* 2009;15(10):1645–7.
- [24] Paveenkittiporn W, Apisarnthanarak A, Dejsirilert S, Trakulsomboon S, Thongmali O, Sawanpanyalert P, et al. Five-year surveillance for *Burkholderia pseudomallei* in Thailand from 2000 to 2004: prevalence and antimicrobial susceptibility. *J Med Assoc Thai* 2009;92(4):S46–52.
- [25] Rahayu SI, Noorhamdani A, Santoso S. Resistance pattern of *Burkholderia pseudomallei* from clinical isolates at Dr. Saiful Anwar general hospital, Malang-Indonesia. *J Clin Microbiol Infect Dis* 2014;1(1).
- [26] Rao C, Hu Z, Chen J, Tang M, Chen H, Lu X, et al. Molecular epidemiology and antibiotic resistance of *Burkholderia pseudomallei* isolates from Hainan, China: a STROBE compliant observational study. *Med (Baltim)* 2019;98(9):e14461.
- [27] Sam IC, See KH, Puthucherry SD. Variations in ceftazidime and amoxicillin-clavulanate susceptibilities within a clonal infection of *Burkholderia pseudomallei*. *J Clin Microbiol* 2009;47(5):1556–8.
- [28] Sarovich DS, Price EP, Von Schulze AT, Cook JM, Mayo M, Watson LM, et al. Characterization of ceftazidime resistance mechanisms in clinical isolates of *Burkholderia pseudomallei* from Australia. *PLoS One* 2012;7(2):e30789.
- [29] Sarovich DS, Price EP, Limmathurotsakul D, Cook JM, Von Schulze AT, Wolken SR, et al. Development of ceftazidime resistance in an acute *Burkholderia pseudomallei* infection. *Infect Drug Resist* 2012;5:129–32.
- [30] Sood S, Khedar RS, Joad SH, Gupta R. Septicaemic melioidosis: case report from a non-endemic area. *J Clin Diagn Res* 2014;8(12):DD01–2.
- [31] Sookpranee T, Sookpranee M, Mellencamp MA, Preheim LC. *Pseudomonas pseudomallei*, a common pathogen in Thailand that is resistant to the bactericidal effects of many antibiotics. *Antimicrob Agents Chemother* 1991;35(3):484–9.
- [32] Stoesser N, Pocock J, Moore CE, Soeng S, Chhat HP, Sar P, et al. Pediatric suppurative parotitis in Cambodia between 2007 and 2011. *Pediatr Infect Dis J* 2012;31(8):865–8.
- [33] Tan AL, Tan ML. Melioidosis: antibiogram of cases in Singapore 1987–2007. *Trans R Soc Trop Med Hyg* 2008;102(1):S101–2.
- [34] Thibault FM, Hernandez E, Vidal DR, Girardet M, Cavallo JD. Antibiotic susceptibility of 65 isolates of *Burkholderia pseudomallei* and *Burkholderia mallei* to 35 antimicrobial agents. *J Antimicrob Chemother* 2004;54(6):1134–8.
- [35] Wuthiekanun V, Amornchai P, Saiprom N, Chantratita N, Chierakul W, Koh GC, et al. Survey of antimicrobial resistance in clinical *Burkholderia pseudomallei* isolates over two decades in Northeast Thailand. *Antimicrob Agents Chemother* 2011;55(11):5388–91.
- [36] Sia TLL, Mohan A, Ooi MH, Chien SL, Tan LS, Goh C, et al. Epidemiological and clinical characteristics of melioidosis caused by gentamicin-susceptible *Burkholderia pseudomallei* in Sarawak, Malaysia. *Open Forum Infect Dis* 2021;8(10):ofab460.
- [37] Chierakul W, Anunnatsiri S, Short JM, Maharjan B, Mootsikapun P, Simpson AJ, et al. Two randomized controlled trials of ceftazidime alone versus ceftazidime in combination with trimethoprim-sulfamethoxazole for the treatment of severe melioidosis. *Clin Infect Dis* 2005;41(8):1105–13.
- [38] Mohan A, Podin Y, Tai N, Chieng CH, Rigas V, Machunter B, et al. Pediatric melioidosis in Sarawak, Malaysia: epidemiological, clinical and microbiological characteristics. *PLoS Negl Trop Dis* 2017;11(6):e0005650.
- [39] Canton R, Morosini MI. Emergence and spread of antibiotic resistance following exposure to antibiotics. *FEMS Microbiol Rev* 2011;35(5):977–91.
- [40] Mouton JW, den Hollander JG. Killing of *Pseudomonas aeruginosa* during continuous and intermittent infusion of ceftazidime in an in vitro pharmacokinetic model. *Antimicrob Agents Chemother* 1994;38(5):931–6.
- [41] Nicolau DP, Nightingale CH, Banevicius MA, Fu Q, Quintiliani R. Serum bactericidal activity of ceftazidime: continuous infusion versus intermittent injections. *Antimicrob Agents Chemother* 1996;40(1):61–4.
- [42] Bilbao-Meseguer I, Rodriguez-Gascon A, Barrasa H, Isla A, Solinis MA. Augmented renal clearance in critically ill patients: a systematic review. *Clin Pharm* 2018;57(9):1107–21.
- [43] Dance D. Treatment and prophylaxis of melioidosis. *Int J Antimicrob Agents* 2014;43(4):310–8.
- [44] Cheng AC, Currie BJ. Melioidosis: epidemiology, pathophysiology, and management. *Clin Microbiol Rev* 2005;18(2):383–416.
- [45] Jena J, Behera B, Nayak G, Mohanty S, Mahapatra A, Purushotham P, et al. In vitro susceptibility of *Burkholderia pseudomallei* isolates to cefiderocol and ceftazidime/avibactam from Odisha, India. *J Lab Physicians* 2023;15(4):573–7.