



Since January 2020 Elsevier has created a COVID-19 resource centre with free information in English and Mandarin on the novel coronavirus COVID-19. The COVID-19 resource centre is hosted on Elsevier Connect, the company's public news and information website.

Elsevier hereby grants permission to make all its COVID-19-related research that is available on the COVID-19 resource centre - including this research content - immediately available in PubMed Central and other publicly funded repositories, such as the WHO COVID database with rights for unrestricted research re-use and analyses in any form or by any means with acknowledgement of the original source. These permissions are granted for free by Elsevier for as long as the COVID-19 resource centre remains active.

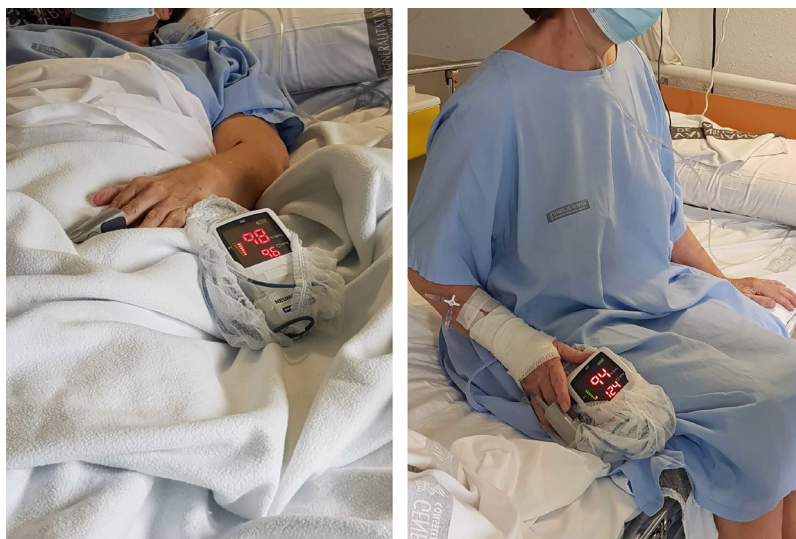

Figure 1. The difference in saturation in sedation from decubitus and the increase in heart rate can be observed.

no reports have appeared in the literature to date that relate POS with the anatomical and functional alterations associated with severe COVID-19 pneumonia.

References

1. Glenn RW. Teaching ventilation/perfusion relationships in the lung. *Adv Physiol Educ.* 2008;32:192–5.
2. De Vecchis R, Baldi C, Ariano C. Platypnea-orthodeoxia syndrome: multiple pathophysiological interpretations of a clinical picture primarily consisting of orthostatic dyspnea. *J Clin Med.* 2016;5:85.
3. Anthonisen NR, Milic-Emili J. Distribution of pulmonary perfusion in erect man. *J Appl Physiol.* 1966;21:760–6.
4. Agrawal A, Palkar A, Talwar A. The multiple dimensions of platypnea-orthodeoxia syndrome: a review. *Respir Med.* 2017;129:31–8.
5. Varga Z, Flammer AJ, Steiger P, Haberecker M, Andermatt R, Zinkernagel AS, et al. Endothelial cell infection and endotheliitis in COVID-19. *Lancet.* 2020;395(10234):1417–8.
6. Leisman DE, Deutschman CS, Legrand M. Facing COVID-19 in the ICU: vascular dysfunction, thrombosis, and dysregulated inflammation. *Intensive Care Med.* 2020;46:1105–8.
7. Ye Z, Zhang Y, Wang Y, Huang Z, Song B. Chest CT manifestations of new coronavirus disease 2019 (COVID-19): a pictorial review [published online ahead of print, 2020 Mar 19]. *Eur Radiol.* 2020;30:4381–9.
8. Minghini A, Britt LD, Hill MA. Interleukin-1 and interleukin-6 mediated skeletal muscle arteriolar vasodilation: in vitro versus in vivo studies. *Shock.* 1998;9:210–5.
9. Khan F, Parekh A. Reversible platypnea and orthodeoxia following recovery from adult respiratory distress syndrome. *Chest.* 1979;75:526–8.
10. Katsoulis K, Minasidis I, Vainas A, Bikas C, Kontakiotis T, Vakianis P. Platypnea and orthodeoxia associated with pneumocystis jiroveci and cytomegalovirus pneumonia: a case report. *J Med Case Rep.* 2009;3:9319.
11. Gadre A, Highland KB, Mehta A. Reversible platypnea-orthodeoxia syndrome from ventilation-perfusion mismatch in interstitial lung disease: a novel etiology. *Ann Am Thorac Soc.* 2016;13:137–8.

Julia Tarrasó Castillo,* Tomás José Posadas Blázquez, Carolina Lahosa Córdoba, Jaime Signes-Costa

Servicio de Neumología, Hospital Clínico Universitario INCLIVA, Valencia, Spain

* Corresponding author.

E-mail address: jutacas@alumni.uv.es (J. Tarrasó Castillo).

Twice Lucky: Elderly Patient Surviving Both COVID-19 and Serendipitous Lung Carcinoma



Sobrevivir a una infección COVID-19 conduce a curar un carcinoma pulmonar

Dear Editor:

As of 4 June 2020, the number of confirmed cases of severe acute respiratory syndrome coronavirus 2 (SARS-CoV-2) in Spain is 240,326, many of whom have developed the coronavirus disease 2019 (COVID-19).¹ Despite the high number of deaths (around 27,000), more than 120,000 patients have been cured.¹ Once the outbreak is over, the new situation we face is dealing with non-related COVID pathologies in patients diagnosed with COVID-19 or who have recently overcome the disease.

A 78-year old former smoker (cumulative cigarette smoking more than 30 pack-year) patient with medical history of chronic obstructive pulmonary disease (COPD) type emphysema (forced expiratory volume in the first second (FEV1)/forced vital capacity (FVC): 46%, FEV1: 70% and carbon monoxide diffusing capacity (DLCO): 49%) under bronchodilator treatment and periodical follow-up by a pulmonologist was admitted in a non-tertiary care hospital due to dyspnea, cough, myalgia and fever. The patient presented an acute respiratory failure with hypoxemia and hypocapnia. The polymerase chain reaction (PCR) microbiological test in nasopharyngeal exudate revealed SARS-CoV-2 nucleic acid and the chest radiography showed right basal opacities and a diffuse interstitial bilateral pattern (Fig. 1A). The patient was diagnosed with COVID-19 pneumonia and he was treated with hydroxychloroquine, lopinavir/ritonavir, interferon beta, corticoids and non-invasive ventilation. After 10 days of hospitalization, the patient was discharged with home oxygen and the recommenda-

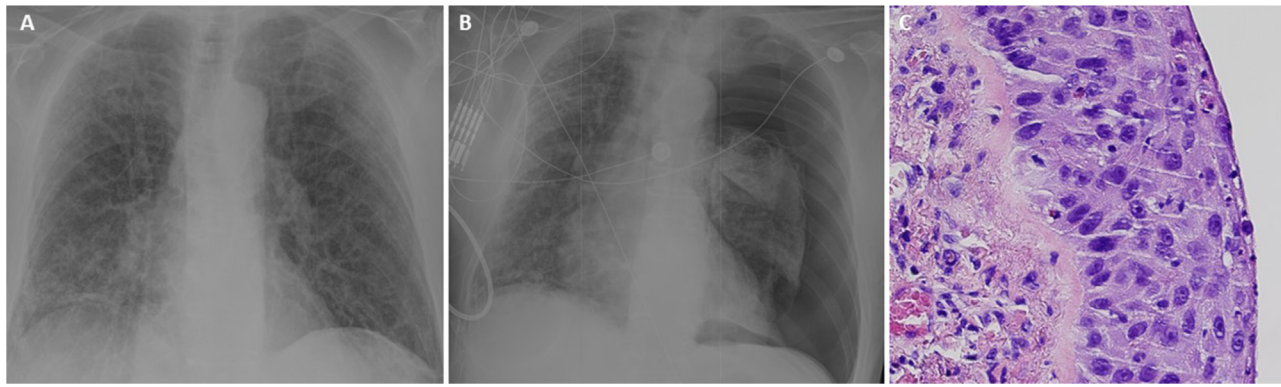


Fig. 1. (A) Chest radiography showing right basal opacities and a diffuse interstitial bilateral pattern compatible with COVID-19. (B) Chest radiography showing a left complete pneumothorax and persistence of the radiological changes due to the COVID-19. (C) Microscopical detailed view of atypical cellularity with a high mitotic index (squamous cell carcinoma).

tion of solitary confinement for 14 days. During the 4th day of individual isolation, he developed acute dyspnea and chest pain and he was transferred to the hospital again. A left complete pneumothorax was seen in the chest radiography (Fig. 1B). A 20F chest tube was inserted and a continuous 3/5 air leak was observed in the analogic drain. The patient was kept in isolation in a COVID-19 restricted area. After 6 days of prolonged air leak and incomplete pulmonary expansion, his general surgeon contacted us to transfer the patient to our third-level university hospital for surgical treatment.

To avoid virus spread, the procedure to transfer a patient from one to another hospital must follow all security protocols. So that, before transferring the patient we performed a new PCR test with a negative result. Once here, since the patient had not complied the 14 days of individual isolation after discharge, a serologic test was ordered to verify if the infection was active or passed; the result was positive, but unfortunately there was no possibility to know about which kind of immunoglobulins was elevated (Ig G or Ig M) due to the lack of reactants. So that, a new PCR test was performed to confirm the previous one with a delay less than 48 h. The result was negative. Regarding the two last negative tests and the time interval since the first positive test (more than three weeks), the patient was considered as a SARS-CoV-2 negative patient and treated with comprehensive protective measures but without strict isolation in the ward.

The patient underwent video-thoroscopic surgery. A 2 mm perforation was found in the left segment six in an emphysematous area and a wedge resection and chemical pleurodesis were performed. The patient was discharged the day after the operation with no complications. The anatomopathological report revealed a keratinizing squamous cell carcinoma in situ in an emphysematous bulla with free surgical margins (Fig. 1C). Non-tumoral parenchyma characterized by the subpleural cyst wall thickness.

After complete recovery of the patient, a thoraco-abdominal computerized tomography (CT) and a positron emission tomography-CT (PET-CT) were performed. No distant metastases or nodal disease were detected. Final staging was pTisN0M0 (stage 0).

As thoracic surgeons the new scenario we face is treating COVID-19 patients or patients who recently overcome the disease who present with non-related COVID-19 pathology which require urgent or preferential thoracic surgical intervention. A recent study has demonstrated that postoperative pulmonary complications occur in half of patients with perioperative SARS-CoV-2 infection and are associated with high mortality.² Moreover, Li et al.³ concluded that COVID-19 is associated with poor prognosis for patients undergoing thoracic operation, especially for those with COPD. So

that, unnecessary thoracic surgeries should be avoided. Besides, since it is imperative to ensure the safety of health-care workers not only to safeguard continuous patient care but also to ensure they do not transmit the virus, high-sensitivity diagnostic tests should be routinely performed to identify current and past infection (serologic tests) and to ensure that patients who have overcome the disease are no longer contagious (nucleic acid tests).

Until a few days ago, only urgent procedures and high priority oncological elective surgery in non-COVID-19 patients were performed and always balancing the risk of delaying therapy against the availability of hospital resources and potential exposure of COVID-19 on a case-by-case basis. In addition, whenever possible, the elective surgical activity has been transferred to COVID-free areas to avoid potential contracting intra-hospital infections. Since previous reports have revealed that there are asymptomatic patients infected with SARS-CoV-2,^{4,5} all patients needing a surgical intervention should be tested.

We report the case of a patient presented with left spontaneous pneumothorax after discharge for COVID-19 pneumonia that was managed surgically. We consider this therapy was non-delayable and, after microbiological verification of SARS-CoV-2 negativity, excision of a perforated bulla was performed. Pathological examination of the specimen revealed a lung carcinoma in situ whose prognosis is excellent.

Funding source

None.

Conflict of interest

The authors declare that they have no conflict of interest related directly or indirectly to the contents of the manuscript.

References

- Actualizacion_125_COVID-19.pdf [Internet]. Available from: https://www.mscbs.gob.es/en/profesionales/saludPublica/ccayes/alertasActual/nCov-China/documentos/Actualizacion_125_COVID-19.pdf [cited 4.06.20].
- Nepogodiev D, Glasbey JC, Li E, Omar OM, Simoes JF, Abbott TE, et al. Mortality and pulmonary complications in patients undergoing surgery with perioperative SARS-CoV-2 infection: an international cohort study. *Lancet*. 2020. [http://dx.doi.org/10.1016/S0140-6736\(20\)31182-X](http://dx.doi.org/10.1016/S0140-6736(20)31182-X). S014067362031182X. Online ahead of print.
- Li Y-K, Peng S, Li L-Q, Wang Q, Ping W, Zhang N, et al. Clinical and transmission characteristics of covid-19 – a retrospective study of 25 cases from a single thoracic surgery department. *Curr Med Sci*. 2020;40:295–300.
- Chang D, Xu H, Rebaza A, Sharma L, Dela Cruz CS. Protecting health-care workers from subclinical coronavirus infection. *Lancet Respir Med*. 2020;8:e13.
- Bai Y, Yao L, Wei T, Tian F, Jin D-Y, Chen L, et al. Presumed asymptomatic carrier transmission of COVID-19. *JAMA*. 2020;323:1406–7.

María Teresa Gómez-Hernández^{a,*} Nuria M. Novoa^a
 Patricia Antúnez^b Marcelo F. Jiménez^a

^a Service of Thoracic Surgery, Salamanca University Hospital, Salamanca, Spain

^b Service of Anatomical Pathology, Salamanca University Hospital, Salamanca, Spain

* Corresponding author.

E-mail address: mteresa.gomez.hernandez@gmail.com

(M.T. Gómez-Hernández).

<https://doi.org/10.1016/j.arbres.2020.07.009>

0300-2896/ © 2020 SEPAR. Published by Elsevier España, S.L.U. All rights reserved.

Ivermectin Treatment May Improve the Prognosis of Patients With COVID-19



El tratamiento con ivermectina puede mejorar el pronóstico de los pacientes con COVID-19

Dear Editor:

The pandemic coronavirus disease 19 (COVID-19), caused by severe acute respiratory syndrome coronavirus 2 (SARS-CoV-2), has been spread rapidly worldwide with considerable morbidity and mortality. COVID-19 patients have various clinical presentations: asymptomatic, exhibit mild flu-like symptoms, be severely ill or death.^{1,2} In addition to elder age and comorbidities, higher levels of D-dimer and C-reactive protein (CRP) and lower levels of lymphocyte and eosinophil as well as a cytokine storm are associated with disease severity in COVID-19 patients.^{3–6} The virus load may be a main determinant underlying the pathological diversity in COVID-19 patients.^{1,2,6} Thus, an effective antiviral treatment is essential to improve the prognosis of patients with COVID-19.⁷ In the absence of specific anti-SARS-CoV-2 agents, various drugs with antiviral potential are now used to contain the virus in COVID-19 patients. Ivermectin, a US FDA-approved anthelmintic, has garnered enormous interest for treating COVID-19 as it is safe and cheap and has strong antiviral activities against board ranges of viruses including SARS-CoV-2 *in vitro*.^{8–10} Despite the widespread use of ivermectin, to our knowledge, there is currently no published clinical reports of ivermectin in COVID-19 patients. Here, we assessed the clinical efficacy of ivermectin in COVID-19 patients.

This retrospective study enrolled a total of 325 consecutive patients with SARS-CoV-2 infection confirmed by polymerase chain reaction (PCR) of nasal swabs in SK hospital, a unit dedicated to COVID-19 at Mymensingh Medical College Hospital (MMCH), Mymensingh, Bangladesh, from April to June 2020. Of these, the present study included 248 adult COVID-19 patients free from any other serious pathological conditions: 115 received ivermectin plus standard care (SC), while 133 received only SC. Remaining 77 patients who were under 18 years of age or transferred from other facilities and received different management approaches including partial hospital stays or treated with different therapeutic agents prior to hospital admission were excluded from the analysis. The two groups were compared in terms of time to SARS-CoV-2 negativity, disease progression (develop pneumonia to severe respiratory distress), duration of hospital stays, and mortality rate. Ivermectin was given once at dose of 12 mg within 24-h after hospital admission. SC was provided as required and included antipyretics for fever, anti-histamines for cough, and antibiotics to control secondary infection. The study was approved by MMCH and informed consent was obtained from all patients or their relatives before starting treatment. Categorical variables are shown as frequencies and percentages and continuous variables as the median and interquartile range (IQR). Differences with 95% confidence intervals (CI) were computed to show the level of certainty. Paired *t*-tests or Pearson Chi-square test were used to analyze statistical differences. All calculations were performed using SAS, version 9.4 (Cary, NC, USA).

The median age of the patients was 35 (IQR 30–43) years and 60% were men. Table 1 summarizes the demographics and clinical presentations of the two groups. At the time of admission, all patients had comparatively mild/moderate disease with cough, headache, sore throat, anosmia, breathing difficulty, and pneumonia in different proportions. Some patients in both groups had underlying comorbidities like hypertension, diabetes mellitus, asthma, and hyperlipidemia. About 13% of the patients were current smokers. Also, about 58% had higher D-dimer and CRP levels, 51% had lymphopenia, and 47% had eosinopenia. However, at the time of admission, there were no significant differences in the patient profiles, presenting symptoms, comorbidities and hemato-biochemical parameters of the two treatment groups (Table 1).

The treatment did not produce any aberrant symptoms related to ivermectin use. None of the ivermectin-treated patients showed progressive pathology, such as pneumonia or cardiovascular complications (Table 1). On the other hand, 9.8% patient developed pneumonia and 1.5% had ischemic stroke those were not received ivermectin. Significantly fewer ivermectin-treated patients required oxygen inhalation (9.6% vs. 45.9%), developed respiratory distress (2.6% vs. 15.8%), or needed antibiotic treatment (15.7% vs. 60.2%) and intensive care management (0.9% vs. 8.3%). Interestingly, the patients receiving ivermectin became SARS-CoV-2 negative more quickly (median 4 vs. 15 days; 95% CI, 8.97–10.59; $P < 0.001$). The ivermectin-treated patients also had shorter hospital stays (median 9 vs. 15 days; 95% CI, 5.09–7.51; $P < 0.001$). Furthermore, the mortality rate was significantly lower in the ivermectin group than SC (0.9% vs. 6.8%; $P < 0.05$; Table 1). Of the ivermectin-treated patients, 61 were randomly assigned for follow-up assessment 10 and 20 days after discharge; none of them reported any complications.

After SARS-CoV-2 infection, the disease generally progresses within 1 week of symptom onset due to uncontrolled viral replication in the upper respiratory tract,^{2,6,11,12} followed by immune anomalies, and a cytokine storm.^{2,5,6} Thus, an effective antiviral therapy capable of blocking viral replication at the earliest time after infection may prevent disease progression. This study shows that ivermectin is safe in COVID-19 patients and efficient at rapidly clearing SARS-CoV-2 from nasal swabs (median 4 days). This was much shorter than in the COVID-19 patients receiving only SC (15 days) or receiving a combination of three antiviral drugs (7–12 days¹³). Furthermore, in terms of developing respiratory distress leading to ICU admission and the final outcome (discharge/death), we observed a significant clinical benefit of ivermectin in COVID-19 patients. In fact, with ivermectin, we observed quick hospital discharge (median 9 days) in 114 out of 115 patients; the remaining patient arrived with advanced disease.

Ivermectin induced rapid virological clearance that we observed in this study indicating that the preclinical efficacy of the drug against SARS-CoV-2⁹ may be mirrored in patients. Such rapid clearing of SARS-CoV-2 (median 4 days); this is much shorter than the median duration (20 days) of viral shedding in patients with COVID-19,¹⁴ indicate that ivermectin could limit the viral spreading. Collectively, the present findings suggest that ivermectin induced rapid SARS-CoV-2 clearance could reduce COVID-19 disease progression and community transmission.