

Ceftaroline-related acute eosinophilic pneumonia

Zaw Min¹, Rawiya Elrufay¹, Christian Y Cho², Subbarao Elapavaluru³, Nitin Bhanot¹

¹Division of Infectious Disease, Allegheny General Hospital, Allegheny Health Network, Pittsburgh, Pennsylvania, USA, ²Department of Pharmacy, Adventist Health Bakersfield, Bakersfield, California, USA, ³Department of Cardiothoracic Surgery, Allegheny General Hospital, Allegheny Health Network, Pittsburgh, Pennsylvania, USA

ABSTRACT

Ceftaroline fosamil is a novel 5th generation broad-spectrum oxymino-cephalosporin with activity against *Staphylococcus aureus*, including methicillin-resistant *S. aureus* (MRSA), *Streptococcus pneumoniae*, *Haemophilus influenzae*, and Gram-negative bacteria. It has been approved by the United States Food and Drug Administration for the treatment of acute bacterial skin and skin structure infections and community-acquired bacterial pneumonia. There have been reported cases of successful treatment of MRSA bacteremia with this agent. Common adverse drug reactions from ceftaroline include skin rash, hives, neutropenia, thrombocytopenia, and anemia. Acute eosinophilic pneumonia is a rare untoward drug reaction associated with it. We report a case of fever and acute hypoxic respiratory failure with bilateral interstitial pulmonary infiltrates while on ceftaroline therapy for sternal osteomyelitis and ascending aortic graft infection secondary to MRSA. Laboratory studies revealed peripheral blood eosinophilia (>3000 cells/mm³). After exclusion of infectious, autoimmune, and other extrinsic allergic causes of pneumonia, ceftaroline-related acute eosinophilic pneumonia was suspected. Ceftaroline was discontinued and a therapeutic trial of high-dose steroid was initiated. Significant improvement of clinical symptoms and hypoxia was achieved after 24 h of steroid therapy. There was no recurrence of clinical symptoms after completing steroid course, which supported our suspicion of acute eosinophilic pneumonia from ceftaroline. Radiographic improvement of pulmonary infiltrates occurred 4 weeks later with complete resolution at 3 months from the initial event. The current case adds to this rarely reported adverse effect from this relatively newer antimicrobial agent. Increased awareness, early recognition, discontinuation of medication, and steroid therapy are key in favorable clinical outcome and recovery.

KEY WORDS: Acute eosinophilic pneumonia, ceftaroline, peripheral blood eosinophilia

Address for correspondence: Dr. Zaw Min, Division of Infectious Disease, Allegheny General Hospital, Allegheny Health Network, 420, East North Avenue, East Wing, South Tower, Suite 407, Pittsburgh, Pennsylvania 15212, USA. E-mail: zaw.min@ahn.org

Submitted: 24-Nov-2020 **Accepted:** 05-Dec-2020 **Published:** 07-May-2021

INTRODUCTION

Among a wide array of potential adverse drug reactions from ceftaroline, acute eosinophilic pneumonia is probably the most uncommon. Herein, we present the third case of ceftaroline-related acute eosinophilic pneumonia reported in the literature to date.

CASE REPORT

A 65-year-old female presented with a 3-day history of progressive shortness of breath, productive cough, and fever. The patient did not have history of asthma or chronic obstructive pulmonary disease and did not

This is an open access journal, and articles are distributed under the terms of the Creative Commons Attribution-NonCommercial-ShareAlike 4.0 License, which allows others to remix, tweak, and build upon the work non-commercially, as long as appropriate credit is given and the new creations are licensed under the identical terms.

For reprints contact: WKHLRPMedknow_reprints@wolterskluwer.com

How to cite this article: Min Z, Elrufay R, Cho CY, Elapavaluru S, Bhanot N. Ceftaroline-related acute eosinophilic pneumonia. Lung India 2021;38:368-73.

Access this article online	
Quick Response Code: 	Website: www.lungindia.com
	DOI: 10.4103/lungindia.lungindia_908_20

smoke. She had been receiving intravenous ceftaroline 600 mg every 12 h for sternal osteomyelitis and ascending aortic graft infection due to methicillin-resistant *Staphylococcus aureus* (MRSA). About 1 year prior, she had undergone coronary bypass graft, repair of ascending aortic aneurysm, and bioprosthetic aortic valve replacement. Three months after surgery, unfortunately, the patient developed MRSA deep sternal surgical wound infection, sternal bone osteomyelitis, and mediastinitis, resulting in MRSA bacteremia. The minimal inhibitory concentration (MIC) of vancomycin to the MRSA isolate was 0.5 µg/mL (interpreted as susceptible on the VITEK®2 system, bioMérieux). Transesophageal echocardiogram showed well-seated prosthetic aortic valve with normal leaflet movement and transprosthetic gradients. The patient had extensive sternal wound and bone debridement. Intraoperatively, the sternal wound dehiscence was tracked deep down to the ascending aortic graft, but the aortic graft was not excised or resected. The patient was initially placed on a 6-week course of intravenous vancomycin and rifampin. As the retained ascending aortic graft was deemed to be infected with MRSA, a lifelong suppressive oral antibiotic (trimethoprim/sulfamethoxazole) was planned after completing IV vancomycin therapy to prevent relapse of MRSA infection.

The patient completed IV vancomycin therapy as planned. It was then transitioned to indefinite oral trimethoprim/sulfamethoxazole, but that was prematurely discontinued 2 months later due to miscommunication. The patient was then readmitted for recurrent MRSA bacteremia. The sternal surgical incision was well healed without drainage or swelling. Computed tomography (CT) of the chest did not show fluid collection within the mediastinum or sternum bone, and there was no evidence of mycotic aortic aneurysm. A repeat transesophageal echocardiogram again described well-seated aortic valve prosthesis without vegetation. The aortic graft was presumed to be infected given recurrent MRSA bacteremia. The cardiothoracic surgery team elected for medical therapy as repeat major aortic graft surgery was regarded as a very high-risk procedure. The vancomycin MIC of that MRSA isolates had increased to 2 µg/mL (susceptible on the VITEK®2 system, bioMérieux), that of trimethoprim/sulfamethoxazole was <0.5/9.5 µg/mL (susceptible on the VITEK®2 system, bioMérieux), that of linezolid was 2 µg/mL (susceptible on the VITEK®2 system, bioMérieux), and that of ceftaroline was 0.5 µg/mL (susceptible on the VITEK®2 system, bioMérieux). Given reported incidents of failure of vancomycin therapy in patients with MRSA infection with vancomycin MIC breakpoint of 2 µg/mL, the decision was made to use intravenous ceftaroline 600 mg every 12 h for an additional 6 weeks, followed by indefinite oral suppressive with trimethoprim/sulfamethoxazole.

Five weeks into ceftaroline therapy, the patient presented with progressive shortness of breath both at rest and exertion, productive cough, and a fever of 103°F for 3 days. The patient appeared dyspneic, tachypneic, as

well as orthopneic. There was no skin rashes or hives on cutaneous examination. There were no other new medications prescribed. The patient lived at home with her husband who denied similar symptoms. The patient did not have pets, birds, history of water damage at home or mold exposure, did not use hot tub or Jacuzzi, or did not have contact with farm animals. On examination, diffuse inspiratory crackles were heard throughout all lung fields. The patient was hypoxemic with partial pressure of oxygen (PaO₂) of 64.8 mmHg on 8 L (liter) of oxygen through a nasal cannula. The patient was then placed on nasal high-flow oxygen therapy (Optiflow™), and oxygenation improved to 98%. Laboratory studies showed leukocytosis of 23,000/mm³ (normal 4000–11,000) with elevated high absolute eosinophil count of 3200/mm³ (normal <350/mm³). Renal and hepatic function panels were within the normal range. Serum procalcitonin was normal. Chest X-ray showed bilateral multifocal pneumonic infiltrates. CT chest demonstrated extensive bilateral pulmonary infiltrates involving all lung segments without evidence of pulmonary embolism [Figure 1]. Ceftaroline was discontinued due to the concern for either ceftaroline-resistant bacterial pneumonia or ceftaroline-related acute eosinophilic pneumonia. Linezolid was substituted for ceftaroline, and levofloxacin was added for empiric coverage against *Pseudomonas aeruginosa* and atypical bacterial pneumonia pathogens, such as *Legionella pneumophila*, *Mycoplasma pneumoniae*, and *Chlamydia pneumoniae*.

The patient denied sick contacts with suspected respiratory tract infections. Nasopharyngeal swab for Influenza A and B PCR was negative. Nasal swab for respiratory virus panel (RVP) multiplex nucleic acid assay (GenMarkDx®, Carlsbad, California, USA; Food and Drug Administration [FDA] approved), that detects 14 different respiratory viruses, *M. pneumoniae*, and *C. pneumoniae*, was also tested and returned negative. This case occurred far before the severe acute respiratory

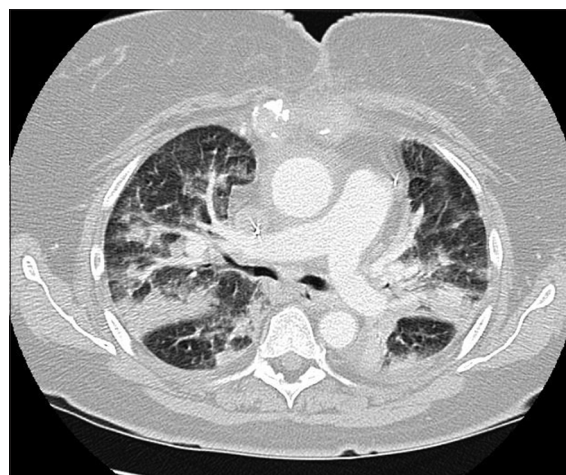


Figure 1: Computed tomography of the chest on admission showed bilateral diffuse extensive pulmonary infiltrates and consolidations without evidence of pulmonary embolism

syndrome coronavirus-2 (SARS-CoV-2) global pandemic. Sputum cultures revealed no bacterial growth. Sputum for *Legionella* culture and urine *L. pneumophila* antigen were negative. Levofloxacin was then discontinued since the workup for *L. pneumophila*, *M. pneumoniae*, and *C. pneumoniae* was negative.

Urine for pneumococcal antigen was negative. Blood cultures had no growth. Thus, ceftaroline-resistant bacterial pneumonia was less likely. HIV serology was nonreactive, which made opportunistic fungal or *Pneumocystis jirovecii* pneumonia improbable. Investigations for parasitic infestation and autoimmune disease were not performed as there was no evidence on clinical history or physical examination to suggest these pathologies. There was no history or clues of extrinsic allergen exposure, and hypersensitivity pneumonitis was thus less likely. A high clinical suspicion of acute eosinophilic pneumonia from ceftaroline was entertained.

We monitored the patient's respiratory status after discontinuation of ceftaroline in the hope of avoiding the use of steroid administration. Following 5 days after withdrawal of ceftaroline and negative infectious workups, the patient's respiratory status did not improve, and the patient continued to require high supplemental oxygen with bi-level positive airway pressure (BiPAP). Peripheral blood absolute eosinophil count was still elevated ($>2000/\text{mm}^3$). Bronchoscopy and bronchoalveolar lavage (BAL) for eosinophil percentage was considered, but not pursued by the intensivist due to tenacious respiratory status with the concern of mechanical intubation and prolonged respiratory ventilator support after bronchoscopy. Instead, a therapeutic trial of high-dose intravenous methylprednisolone 60 mg every 6 h was initiated. Within 24 h, supplemental oxygen requirement was down to 4 L from 10 L high-flow nasal cannula. A complete wean off of supplemental oxygen was achieved on day 5 of steroid therapy. Peripheral

blood eosinophilia also resolved after a day of intravenous methylprednisolone therapy. Methylprednisolone therapy was continued for 5 days until complete weaning off of supplemental oxygen therapy and was then transitioned to oral prednisone taper over 10 days. Linezolid was changed to oral sulfamethoxazole-trimethoprim (800 mg–160 mg) one tablet every 12 h as lifelong oral suppressive antibiotic therapy due to retained infected aortic graft. The repeat CT chest in 4 weeks and 12 weeks revealed near-complete resolution of pulmonary infiltrates [Figure 2] and complete resolution [Figure 3], respectively. There was no recurrence of respiratory symptoms and peripheral blood eosinophilia in 1-month, 3-month, 6-month, and 12-month clinic follow-up.

DISCUSSION

Eosinophilic pneumonia is defined as eosinophil infiltration of lung parenchyma, resulting in clinical symptoms (dyspnea, cough, chest pain, and fever) that radiographically presents as diffuse chest infiltrates.^[1,2] It is divided into acute (symptoms duration of <1 month) and chronic (symptoms duration of 7–8 months).^[1,3] The causes of eosinophilic pneumonia are extensive and overlap in patients with acute and chronic eosinophilic pneumonia. They include helminthic infestations, fungal infections, autoimmune diseases, malignancy, medications, toxins, environmental allergens, or idiopathic.^[3,4]

Drugs and toxins are the two most common causes of eosinophilic pneumonia.^[3] Eosinophil production is mainly regulated by interleukin (IL)-5 produced by T-helper type 2 (Th2) lymphocytes.^[2] Peripheral blood eosinophilia is defined as absolute peripheral blood eosinophil count $>500/\text{mm}^3$ (normal $<350/\text{mm}^3$).^[2] The percentage of eosinophil in peripheral blood is not used because eosinophil percentage is fluctuating with the total white blood cell (WBC) count and proportion of other WBC series (such as neutrophils, lymphocytes, etc.).^[2]

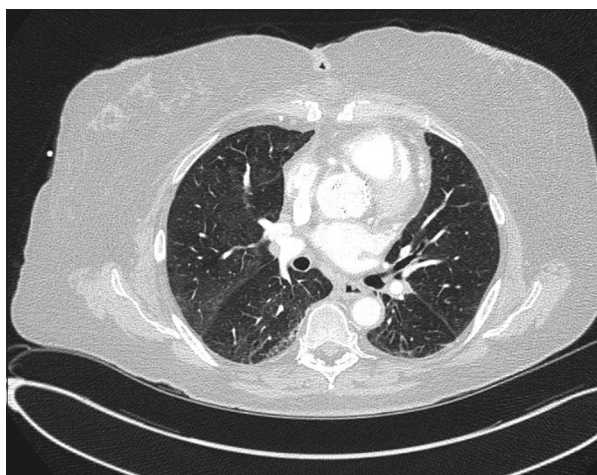


Figure 2: A 1-month follow-up computed tomography of the chest showed near-complete resolution with significant improvement of diffuse lung infiltrates

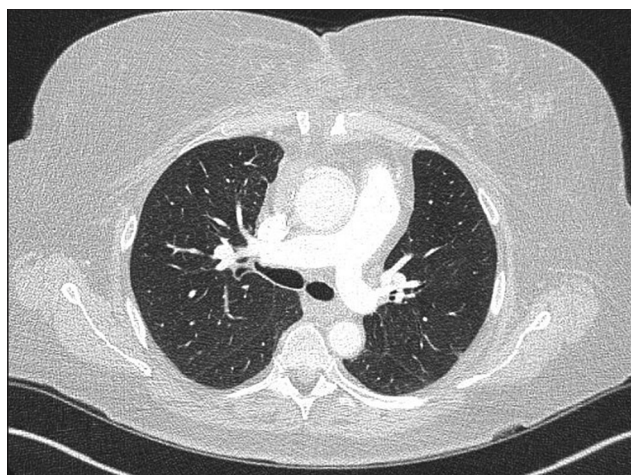


Figure 3: A 3-month follow-up computed tomography of the chest demonstrated a complete resolution of pulmonary infiltrates without sequelae

On the other hand, the eosinophil percentage, instead of absolute eosinophil count, is used to define high bronchoalveolar (BAL) eosinophilia.^[2] BAL eosinophilia considered if >5% of eosinophils in BAL differential cell count (normal <1%).^[1,2] However, >25% BAL eosinophilia is required as a diagnostic criterion for eosinophilic pneumonia or eosinophilic lung disease.^[1-4] The proposed underlying mechanism of drug-induced acute eosinophilic pneumonia is as follows: the alveolar macrophages phagocytose the drug and then present, as antigen-presenting cells, to Th2 lymphocytes. These, in turn, activate the production of IL-5 which induces abundant eosinophil production and release into the lung parenchyma, resulting in pulmonary consolidations, clinical manifestations, and radiographic abnormalities.^[2]

Among the etiologies of drug-induced eosinophilic pneumonia, antimicrobials, nonsteroidal anti-inflammatory drugs, and anti-epileptic medications are implicated as the most common causes.^[5] Daptomycin is one of the leading culprits of antibiotic-related acute eosinophilic pneumonia.^[5] There have been only two cases of acute eosinophilic pneumonia from ceftaroline antibiotic reported in the literature to date [Table 1].^[6,7] One poster presentation of a similar case was excluded because of confounding bias since the patient had concomitantly received daptomycin and ceftaroline

therapy, and daptomycin is frequently associated with acute eosinophilic pneumonia.^[5,8]

Ceftaroline fosamil is the novel 5th generation cephalosporin antibiotic which has activity against *S. aureus*, including MRSA, *Streptococcus pneumoniae*, *Haemophilus influenzae*, and Gram-negative bacteria.^[9] The United States FDA has approved ceftaroline for the treatment of community-acquired bacterial pneumonia and acute bacterial skin and skin structure infections.^[9] The premarketing ceftaroline phase III clinical trials reported peripheral blood eosinophilia in <2% of patients.^[9] However, the postmarketing real-life study demonstrated peripheral blood eosinophilia in 15% of patients receiving ceftaroline.^[10]

Our patient presented with a 3-day duration of respiratory distress and fever on day 35 of intravenous ceftaroline therapy for MRSA sternal bone osteomyelitis and ascending aortic graft infection. The patient had severe hypoxemia (PaO₂ of 64.8 mmHg on 8 L of supplemental oxygen) and peripheral blood eosinophilia >3000/mm³ along with leukocytosis, and imaging studies showed extensive diffuse pulmonary infiltrates. The initial concern was if the patient had bacterial pneumonia from ceftaroline-resistant MRSA, ceftaroline-resistant pneumococcus, or from atypical pathogens that ceftaroline

Table 1: Published reports of ceftaroline-induced acute eosinophilic pneumonia^[2,4,6,7,11]

References	Symptom onset	Dose of ceftaroline	Pertinent clinical features	Relevant laboratory/ BAL findings	Imaging studies	Treatment	Clinical outcomes
Desai et al. ^[6]	Day 39 of ceftaroline therapy	600 mg every 8 h	Progressive shortness of breath, hypoxia (oxygen saturation 90% on 5 L of oxygen by nasal cannula)	Absolute peripheral blood eosinophil count - 1500/mm ³ (normal, <350/mm ³) ^[2] BAL - 16% eosinophils (normal, <1%) ^[11]	CT chest—diffuse bilateral infiltrates and mediastinal lymphadenopathy	Ceftaroline was discontinued on the day of admission. IV methylprednisolone was started on day 3 of admission after BAL, followed by oral prednisone taper. Completed a total of 10 days of steroid therapy	Complete wean off of supplemental oxygen 5 days after steroid therapy. Complete radiographic resolution of pulmonary infiltrates in 7 weeks
Griffiths et al. ^[7]	Day 5 of ceftaroline therapy	600 mg every 12 h	Hypoxia	Peripheral eosinophilia - 40%. No absolute peripheral eosinophil count provided. BAL - 13% eosinophils (normal, <1%) ^[11]	CT chest - left lung infiltrates and right basilar pleural effusion	Ceftaroline was discontinued. IV methylprednisolone was started after BAL, followed by oral prednisone taper over 3 weeks	Due to underlying COPD, the patient continued to have respiratory symptoms, need supplemental oxygen support, and persistent radiographic infiltrates
Current case	Day 35 of ceftaroline therapy	600 mg every 12 h	Fever, dyspnea, orthopnea, tachycardia, productive cough, and profound hypoxia (PaO ₂ 64.8 mmHg on 8 L of nasal oxygen supplement)	Absolute peripheral blood eosinophil count - 3200/mm ³ (normal, <350/mm ³) ^[2] No BAL performed	CT chest - extensive bilateral diffuse pulmonary infiltrates.	Ceftaroline was discontinued on the day of admission. IV methylprednisolone was started on day 5 of admission, followed by a short course (10 days) of oral prednisone taper	Decrease supplemental oxygen requirement in 24 h of initiation of steroid treatment, and no supplemental oxygen needed on day 5 of steroid therapy. Peripheral eosinophilia resolved after a day of steroid injection. Complete resolution of radiographic infiltrates in 3 months

A normal blood absolute eosinophil count is <350/mm³; high peripheral blood eosinophilia is defined as an absolute eosinophil count >500/mm³.^[2,4] A normal BAL eosinophil percentage is <1%; high BAL eosinophilia is considered if >5% of eosinophils in BAL differential cell count.^[4,11] IV: Intravenous, BAL: Bronchoalveolar lavage, CT: Computed tomography, COPD: Chronic obstructive pulmonary disease

did not have activity against, such as *P. aeruginosa*, *L. pneumophila*, *M. pneumoniae*, or *C. pneumoniae*. We have ruled out those organisms as sputum cultures had no growth of these microbes. In addition, urinary antigen for *L. pneumophila* and *S. pneumoniae* was negative. We also ruled out *M. pneumoniae* and *C. pneumoniae* infection by negative nasal swab for RVP multiplex nucleic acid assay. The viral cause of diffuse pneumonia was eliminated as the RVP test reported negative for 14 different respiratory viruses. The case was encountered a year before the SARS-CoV-2 global pandemic. The patient did not have history of asthma or cutaneous eczema. There were no risk factors for parasitic infestations or clinical manifestations suggestive of autoimmune diseases. There was no history suggestive of exposure to environmental allergens, and thus the possibility of hypersensitive pneumonitis was low. The patient was discharged back to her house. Under the same environment, the patient had no recurrence of similar symptoms which made a diagnosis of hypersensitivity pneumonitis from environmental allergens more remote. No long-term respiratory sequelae were noted after completion of the short course steroid therapy. The absence of recurrent respiratory symptoms also suggests that it is much less likely of undiagnosed autoimmune disease or parasitic infestation.

Our patient fulfilled 7 out of 8 diagnostic criteria for acute eosinophilic pneumonia except high eosinophil percentage in BAL or evidence of eosinophilic pneumonia on lung biopsy as the patient did not undergo bronchoscopy or lung biopsy [Table 2].^[1,11] One of the criteria was PaO₂ <60 mmHg on the room air. Our patient's PaO₂ was 64.8 mmHg on 8 L of supplemental oxygen, and we can safely assume that PaO₂ would have been <60 mmHg if measured on the room air. Bronchoscopy and BAL were not performed in our patient because the intensivist had a concern of the requirement of unnecessary mechanical ventilation after the bronchoscopic procedure. Despite the lack of BAL study, the patient's whole clinical picture pointed to acute eosinophilic pneumonia from ceftaroline antibiotic based on peripheral blood eosinophilia in association with clinical symptoms and pulmonary infiltrates in conjunction with lack of an alternative diagnosis.^[2] It was confirmed by a rapid clinical response on steroid therapy. BAL for eosinophil study may not always be necessary, if peripheral blood eosinophilia is present, to confirm the diagnosis of eosinophilic pneumonia.^[2] Lung biopsy is only required if suspected acute eosinophilic pneumonia fails to respond to discontinuation of an insulting agent and corticosteroid therapy.^[3] Our case is the third reported case of ceftaroline-induced acute eosinophilic pneumonia. Unlike two previously reported cases, the current case established the diagnosis of ceftaroline-induced acute eosinophilic pneumonia without bronchoscopy. Among these three cases, it is observed that the eosinophilic pneumonia may occur as short as 5 days to as long

Table 2: The widely used diagnostic criteria for eosinophilic pneumonia^[1]

1. Acute febrile illness of <7 days
2. Severe hypoxemia (PaO₂ <60 mmHg on room air)
3. Diffuse pulmonary infiltrates on chest radiography
4. Pulmonary eosinophilia (>25% eosinophils on BAL differential cell count or evidence of eosinophilic pneumonia on lung tissue biopsy)
5. Exclusion of pulmonary or systemic infection
6. No history of asthma or other atopic illness
7. Prompt response to corticosteroid therapy
8. Subsequent resolution of pulmonary eosinophilia with no long-term respiratory sequelae

BAL: Bronchoalveolar lavage

as >5 weeks of ceftaroline therapy. It is also noted that this adverse reaction does not seem to be dependent on the amount of ceftaroline dosing.^[6,7] It appears to be an idiosyncratic reaction based on the limited case reports.

CONCLUSION

Antibiotics are commonly used drugs, and eosinophilic pneumonia is a very rare adverse drug reaction of antibiotic therapy. Ceftaroline is a newer antibiotic and thus awareness of the entire spectrum of its side effects is limited. Ceftaroline-induced acute eosinophilic pneumonia is a rare, but serious adverse effect. Our patient is the third reported case of such in the literature. It is observed to be a dose- or duration-independent idiosyncratic reaction. The cessation of causative drugs alone may not be adequate to reverse the clinical course, and addition of corticosteroid therapy is the mainstay therapeutic option for rapid clinical recovery. Pulmonary eosinophilia is one of the diagnostic criteria for eosinophilic pneumonia. Our case highlights that the diagnosis of eosinophilic pneumonia could possibly be established, in the presence of peripheral blood eosinophilia in conjunction with clinical manifestations and radiographic findings, without bronchoscopy study to demonstrate high BAL eosinophilia.

Acknowledgments

We would like to thank the patient and her husband for providing us a written signed consent for publication.

Declaration of patient consent

The authors certify that they have obtained all appropriate patient consent forms. In the form, the patient has given her consent for her images and other clinical information to be reported in the journal. The patient understand that name and initials will not be published and due efforts will be made to conceal identity, but anonymity cannot be guaranteed.

Financial support and sponsorship

Nil.

Conflicts of interest

There are no conflicts of interest.

REFERENCES

1. Allen JN, Pacht ER, Gadek JE, Davis WB. Acute eosinophilic pneumonia as a reversible cause of noninfectious respiratory failure. *N Engl J Med* 1989;321:569-74.
2. Allen JN. Drug-induced eosinophilic lung disease. *Clin Chest Med* 2004;25:77-88.
3. Allen JN, Wert M. Eosinophilic pneumonias. *J Allergy Clin Immunol Pract* 2018;6:1455-61.
4. De Giacomo F, Vassallo R, Yi ES, Ryu JH. Acute eosinophilic pneumonia. Causes, diagnosis, and management. *Am J Respir Crit Care Med* 2018;197:728-36.
5. Bartal C, Sagy I, Barski L. Drug-induced eosinophilic pneumonia. *Medicine (Baltimore)* 2018;97:e9688.
6. Desai KR, Burdette SD, Polenakovik HM, Hagaman J, Pleiman CM. Ceftaroline-induced eosinophilic pneumonia. *Pharmacotherapy* 2013;33:e166-9.
7. Griffiths CL, Gutierrez KC, Pitt RD, Lovell RD. Eosinophilic pneumonia induced by ceftaroline. *Am J Health Syst Pharm* 2014;71:403-6.
8. Pepper DJ, Delbecq E, Burke AP, White C, Britt EJ. Concomitant daptomycin and ceftaroline-induced eosinophilic pneumonia: A case report. *Am J Respir Crit Care Med* 193;2016:A1654.
9. Teflaro (Ceftaroline Fosamil) Package Insert. St. Louis: Forest Pharmaceuticals; 2010. Available from: https://media.allergan.com/actavis/actavis/media/allergan-pdf-documents/product-prescribing/Teflaro-USPI-09_2019-2.pdf. [Last accessed on 2020 Nov 24].
10. Blumental KG, Kuhlen JL, Weil AA, Varughese CA, Kubiak DW, Banerji A, *et al.* Adverse drug reactions associated with ceftaroline use: A 2-center retrospective cohort. *J Allergy Clin Immunol Pract* 2016;4:740-6.
11. Meyer KC, Raghu G, Baughman RP, Brown KK, Costabel U, du Bois RM, *et al.* An official American Thoracic Society clinical practice guideline: The clinical utility of bronchoalveolar lavage cellular analysis in interstitial lung disease. *Am J Respir Crit Care Med* 2012;185:1004-14.