

Available online at www.sciencedirect.com

ScienceDirect

journal homepage: www.elsevier.com/locate/radcr

Case Report

Pulsatile tinnitus and imaging diagnosis. A case report ^{☆,☆☆}

Jesus Dante Guerra-Leal*, Yehuda Jesus Garcia-Gutiérrez, Ulises Longoria-Estrada, Andrea Cecilia Garza Acosta, Estefanía Brosig García

Universidad Autonoma de Nuevo Leon, Facultad de Medicina y Hospital Universitario “Dr. Jose E. Gonzalez”, Radiology Department, Av. Madero y Gonzalitos s/n, Colonia Mitras Centro, Monterrey, Nuevo Leon, Mexico C.P. 64460

ARTICLE INFO

Article history:

Received 24 January 2022

Revised 25 February 2022

Accepted 2 March 2022

Keywords:

Tinnitus

Diagnostic imaging

Computed tomography

Magnetic resonance

Jugular bulb

ABSTRACT

Tinnitus is the perception of sound in one or both ears when no external noise exists to cause that perception. It can be otological, neurological, drug-related, traumatic, due to exposure to high decibel levels, or associated with a vascular abnormality—the latter usually causing pulsatile tinnitus. We present the diagnostic image of a patient with pulsatile tinnitus with terminal plate dehiscence of the jugular bulb and review the diagnostic workup. Jugular bulb dehiscence is a venous variant that consists of an upper and lateral extension of the jugular bulb into the middle ear through a dehiscent sigmoid plate. It is the most common vascular anatomical variant of the petrous portion of the temporal bone. Imaging studies are essential for establishing a diagnosis and defining possible anatomical variants.

© 2022 The Authors. Published by Elsevier Inc. on behalf of University of Washington.

This is an open access article under the CC BY-NC-ND license

(<http://creativecommons.org/licenses/by-nc-nd/4.0/>)

Introduction

Tinnitus is the perception of sound in one or both ears with no external causative agent [1]. The aetiology can be otological, neurological, stress-related, traumatic, impacted cerumen, a foreign body, drug-related, and overexposure to high decibel levels. It can also be cryptogenic with no radiologically identifiable cause [2]. Tinnitus can be of vascular aetiology associated with pulsatile tinnitus.

We present the case of a female patient with pulsatile tinnitus and review the diagnostic workup.

Case report

A 21-year-old female student with no relevant medical or personal history came to the otolaryngology clinic with a history of tinnitus. She said that her problem started gradually five years before when she noticed moderate-intensity pulsatile tinnitus in her left ear. The patient stated that it was constant and related to her heartbeat. The sound had a deep tone, similar to a heart murmur with increasing intensity. It was attenuated by pressing on the neck and turning her head to the left and worsened with moderate exercise. It was not obscured by

[☆] Acknowledgments: The authors thank Sergio Lozano-Rodriguez, M.D., for his help in translating and editing the manuscript.

^{☆☆} Competing Interests: None.

* Corresponding author.

E-mail address: jesusdante929@hotmail.com (J.D. Guerra-Leal).

<https://doi.org/10.1016/j.radcr.2022.03.004>

1930-0433/© 2022 The Authors. Published by Elsevier Inc. on behalf of University of Washington. This is an open access article under the CC BY-NC-ND license (<http://creativecommons.org/licenses/by-nc-nd/4.0/>)

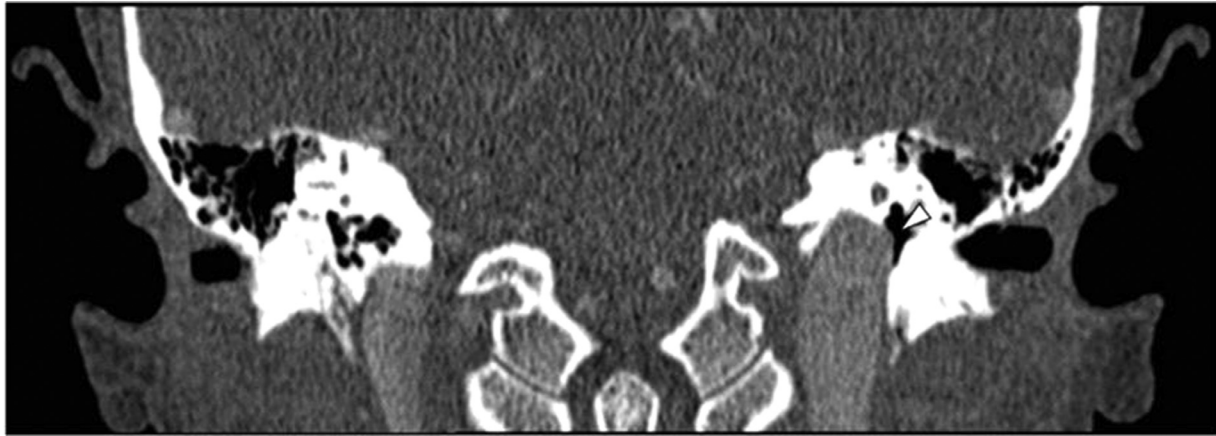

Fig. 1 – Coronal view of both middle ears by computed tomography in a patient with pulsatile tinnitus in the left ear. The asymmetry of both jugular bulbs can be observed at the level of the jugular foramen, with dominance and elevation of the left jugular bulb. Note the sigmoid plate dehiscence on the left side (white arrowhead), which conditions discrete protrusion of the left jugular bulb into the middle ear.

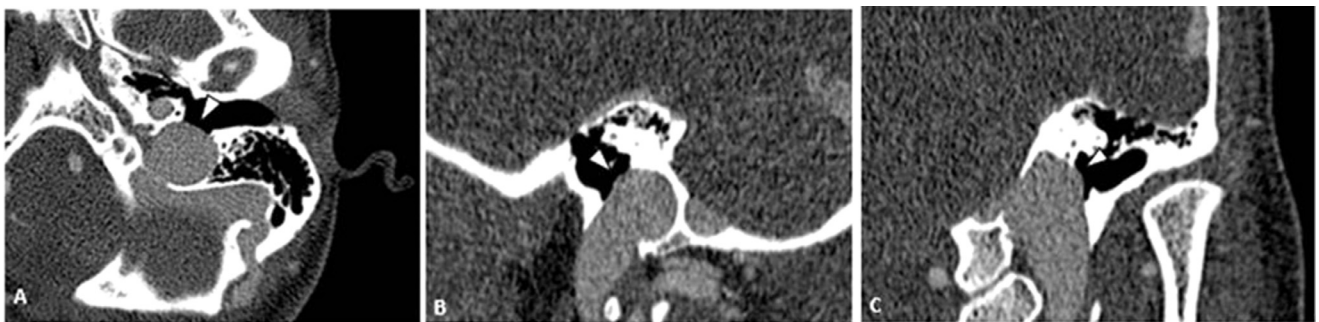


Fig. 2 – Contrast computed tomography of the left ear of the same patient, in axial (A), sagittal (B), and coronal (C) view by multiplanar reformatting, where sigmoid plate dehiscence is observed (white arrowhead).

external noise and affected her daily activities and sleep. She denied headache, vertigo, cervical pain, hearing loss, and loud noise exposure. She had no history of head trauma, use of ototoxic agents, otological surgery, previous infection, and there had been no discharge from the ear.

On physical examination, there were no relevant findings. Laboratory tests, including a thyroid function test, were normal. An audiogram with Warbie sound and a spoken audiogram to differentiate similar words were normal. A cardiac Doppler ultrasound and echocardiography to rule out internal jugular vein reflux and tricuspid valve insufficiency, respectively, did not show pathological data. Imaging studies, including contrasted computed tomography (CT) and contrast-enhanced magnetic resonance imaging (MRI), showed dehiscence of the sigmoid membrane with a high jugular dome above the level of the floor of the internal auditory canal (Figs. 1 and 2). Reformatted axial, sagittal, and coronal images of contrasted MR with T1 + C SPGR technique in the venous phase of the left ear showed a protrusion of the left jugular bulb towards the middle ear (Fig. 3). No specific treatment was provided since it was not considered necessary to correct the dehiscence of the jugular bulb. At follow-up,

the patient stated that she continues to control the noise by pressing on the neck and turning her head.

Discussion

Many individuals experience, after intense exercise, pulsatile tinnitus that stops when the heart regains its normal rhythm. An increase in its intensity can occur with hypertension, and it can disappear when normotension is achieved. Pulsatile tinnitus occurs in less than 10% of patients with tinnitus and can be unilateral or bilateral [3]. The workup of a patient includes a clinical examination and an audiological evaluation. It should also include a neurovascular and cardiac assessment [4]. Differential diagnoses include vascular abnormalities (stenosis, aneurysms, arteriovenous fistula, capillary hyperemia due to acute otitis, intracranial hypertension [3], or an anatomical malformation of the high jugular bulb secondary to dehiscence of the sigmoid membrane [5]). Other causes such as hyperthyroidism and cardiac valve disease should be considered [6].

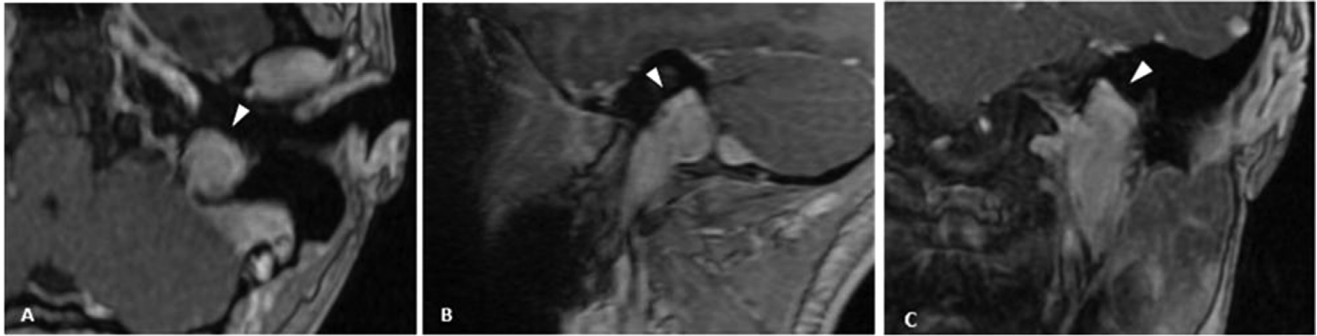


Fig. 3 – Reformatted images in axial (A), sagittal (B), and coronal (C) planes of a contrasted magnetic resonance with T1 + C SPGR technique in the venous phase of the left ear, where it is possible to observe elevation of the left jugular bulb and a discrete protrusion of the same towards the middle ear at the level of the hypotympanum (white arrowhead).

Jugular bulb dehiscence is a venous anatomical variant. It consists of an upper and lateral extension of the jugular bulb into the middle ear through a dehiscent sigmoid plate [3]. This defect does not usually grow, and although congenital, it can be diagnosed at any age by otoscopy or imaging studies [7]. Dehiscence of the vestibular aqueduct has been reported in up to 10% of patients with jugular vein bulb dehiscence. It is considered the most common vascular variant of the petrous portion of the temporal bone, being reported in 7% of autopsies [8].

The diagnosis of pulsatile tinnitus includes computed tomography and magnetic resonance [9–11]. A jugular vein Doppler can be necessary in some cases to rule out other causes [12]. In an unenhanced study, focal dehiscence of the sigmoid plate and an area with soft tissue density are observed. The jugular vein bulb extends superolateral towards the posteroinferior portion of the middle ear. After post intravenous contrast administration, the protruding mass can be observed through the dehiscence, similar to jugular bulb and sigmoid sinus enhancement [9,13,14].

A contrasted MRI venogram can also be used. However, the defect can be difficult to characterize due to the high blood flow of the jugular bulb and the sigmoid sinus [11]. In T1 and T2 sequences, the protruding mass can be observed through the dehiscence with a heterogeneous increase in its intensity. The T2 sequence can be useful to distinguish another vascular anatomical variant from jugular bulb thrombosis. In the contrasted T1 technique, the same intensity is observed between the protruding mass and the jugular bulb. In the coronal plane, a lobulation is visualised that project from the superior external margin of the jugular bulb towards the hypotympanum [10].

Interventions are rarely performed to correct jugular bulb dehiscence. However, when symptoms are severe, direct reconstruction of the middle ear floor can be done by placing a septal cartilage autograft on the sigmoid plate dehiscence.

Patient Consent

The authors confirm that written and signed consent for publication was obtained from the patient in this case report.

REFERENCES

- [1] Herraiz C. Mecanismos fisiopatológicos en la génesis y cronificación del acúfeno. *Acta Otorrinolaringol Esp* 2001;56:335–42.
- [2] Shulman A. Tinnitus: diagnosis/treatment. Martha Entenmann Research Center, Inc; 2004.
- [3] Hofmann E, Behr R, Neumann-Haefelin T, et al. Pulsatile tinnitus: imaging and differential diagnosis. *Deutsches Ärzteblatt International* 2013;110:451–8.
- [4] Kreuzer PM, Vielsmeier V, Langguth B. Chronic tinnitus: an interdisciplinary challenge. *Deutsches Ärzteblatt International* 2013;110:278–84.
- [5] Henry JA, Roberts LE, Caspary DM, et al. Underlying mechanisms of tinnitus: review and clinical implications. *J Am Acad Audiol* 2014;25:5–126.
- [6] Puebla JMM, Sánchez EMM, Colino LMM. Exploración y tratamiento del paciente con acúfenos. Oído [Internet] Toledo: Libro virtual de formación en ORL; 2008.
- [7] Reardon MA, Raghavan P. Venous abnormalities leading to tinnitus: imaging evaluation. *Neuroimaging Clin N Am* 2016;26:237–45.
- [8] Moonis G, Kim A, Bigelow D, et al. Temporal bone vascular anatomy, anomalies, and disease, with an emphasis on pulsatile tinnitus. *Imaging of the temporal bone*. New York: Thieme Medical publishers; 2009. p. 247–97.
- [9] Sandoval EG, Cianca RZ, González CS, et al. Análisis por tomografía computada del golfo de la yugular alto y su asociación con patología de oído. *Experiencia en el Hospital Juárez de México. Medicina Interna de México* 2009;25:197–201.
- [10] Dietz RR, Davis WL, Harnsberger HR, et al. MR imaging and MR angiography in the evaluation of pulsatile tinnitus. *American journal of neuroradiology* 1994;15: 879–889.
- [11] Pegge SAH, Steens SCA, Kunst HPM, et al. Pulsatile tinnitus: differential diagnosis and radiological work-up. *Curr Radiol Rep* 2017;5 5-5.
- [12] Terzi S, Arslanoğlu S, Demiray U, et al. Carotid Doppler ultrasound evaluation in patients with pulsatile tinnitus. *Indian J Otolaryngol Head Neck Surg* 2015;67:43–7.
- [13] Zhao P, Lv H, Dong C, et al. CT evaluation of sigmoid plate dehiscence causing pulsatile tinnitus. *Eur Radiol* 2016;26:9–14.
- [14] Singla A, Gupta T, Sahni D, et al. High jugular bulb: different osseous landmarks and their clinical implications. *Surg Radiol Anat* 2016;38:903–9.