

A 12-year-old boy with acute abdominal pain and distension

Ayadi Kamel Mohamed, Amouri Mariem, ben Mahfoudh Khaireddine, Mezghani Sana, Ahmedullah Ahmed, Jameledine Mnif

A 12-year-old boy was admitted for acute abdominal pain and distension. He reported similar episodes in the last two months, with spontaneous resolution. Physical examination revealed abdominal distension and no palpable mass. Multiple hyperpigmented round lesions were found around the mouth and in the buccal mucosa. Laboratory tests showed a moderate hypochromic microcytic anemia (9 g /dL). In light of these findings, an abdominal ultrasound scan (Figure 1) was followed by a barium meal and follow-through examination (Figure 2 and 3).

What is the diagnosis?

Answers on page 330.

*From the Radiology Department,
Habib Bourguiba Hospital, Tunisia*

*Correspondence and reprint
requests:*

*Ayadi Kamel Mohamed, MD
Radiology Department
Habib Bourguiba Hospital
30 Algeria Avenue Sfax-Tunisia
3000*

Tunisia

Tel: +216-9-897 2513

Fax: +216-7-424 3994

kamelayda@yahoo.com

Ann Saudi Med 2006;26(4):325

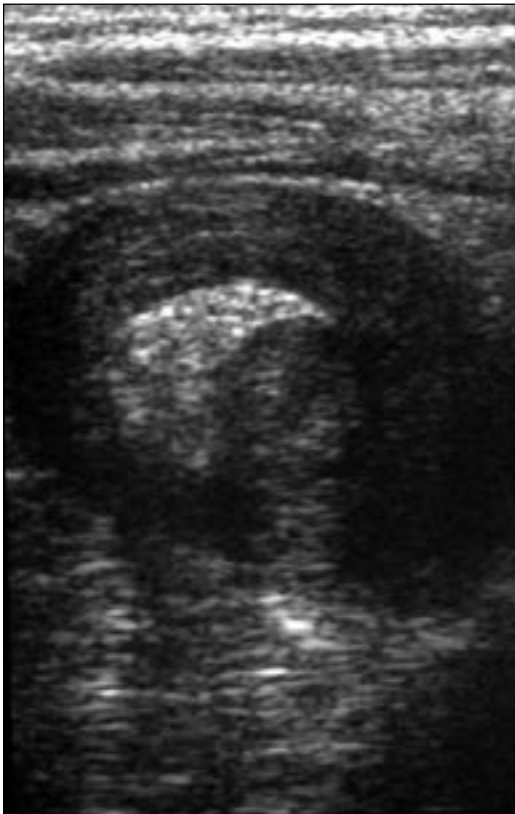
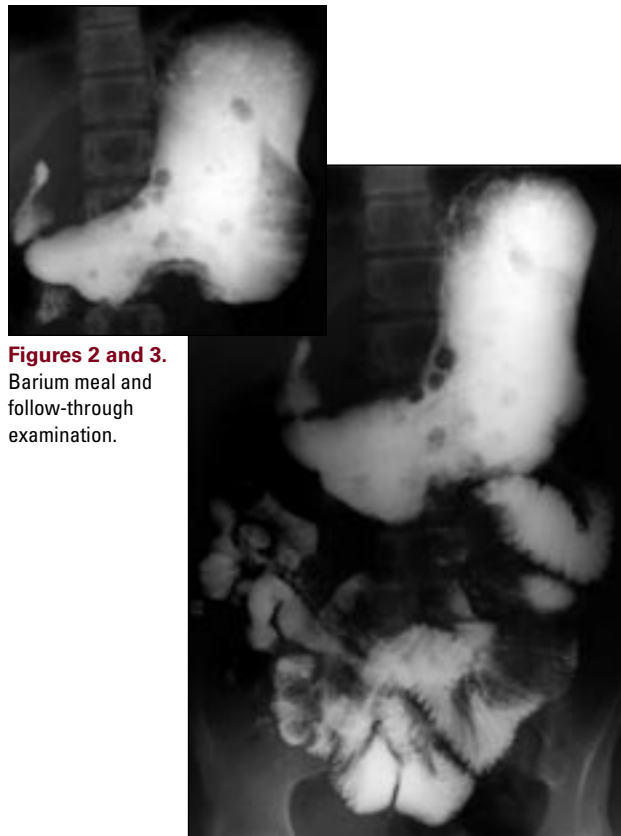


Figure 1. Abdominal ultrasound scan, transverse cut.



Figures 2 and 3. Barium meal and follow-through examination.