

ORIGINAL ARTICLE

Papillae alterations around single-implant restorations in the anterior maxillae: thick versus thin mucosa

Mi-Si Si¹, Long-Fei Zhuang², Xin Huang³, Ying-Xin Gu¹, Chung-Hao Chou¹ and Hong-Chang Lai¹

To evaluate the papilla alterations around single-implant restorations in the anterior maxillae after crown attachment and to study the influence of soft tissue thickness on the papilla fill alteration. According to the inclusion criteria, 32 patients subjected to implant-supported single-tooth restorations in anterior maxillae were included. The patients were assigned to two groups according to the mucosal thickness: (i) group 1, 1.5 mm ≤ mucosal thickness ≤ 3 mm; and (ii) group 2, 3 mm < mucosal thickness ≤ 4.5 mm. Assessments of interproximal papillae at the time of crown placement (baseline) and at 6-month postloading (follow-up) were made by two prosthodontists using papilla fill index (PFI). The mean mucosal thickness was (2.49 ± 0.31) mm (group 1) and (3.81 ± 0.31) mm (group 2) for the two groups respectively. A significant difference in PFI between the groups was detected at the baseline ($P < 0.001$). PFI improvements over time occurred after 6-month follow-up irrespective of the groups. When compared to group 1, the likelihood to obtain papilla fill was significantly higher for group 2 with an odds ratio of 6.05 ($P < 0.001$). The interproximal papilla level around single-implant restorations could improve significantly over time after 6-month restoration according to PFI assessment. The thicker mucosa before implant placement implied a more favorable esthetic outcome in papilla alteration.

International Journal of Oral Science (2012) 4, 94–100; doi:10.1038/ijos.2012.25; published online 25 May 2012

Keywords: esthetic outcome; papilla fill index; single-implant restoration; soft tissue thickness

INTRODUCTION

Single-implant restoration has been found highly predictable in terms of implant survival and peri-implant bone stability.^{1–3} Commonly used criteria for implant success include achievement of osseointegration, maintenance of stable peri-implant marginal bone level and high survival rate.^{4–5} However, nowadays, an implant that is osseointegrated does not always translate into success, especially in the maxillary anterior region. When dealing with implant-supported restorations in this area, success, to a large extent, depends on the esthetic outcome. Thus, Smith and Zarb⁶ once extended the success criteria by emphasizing that a successful implant must allow for adequate esthetic appearance. The demand for optimal esthetic outcome from both the professionals and the patients become an essential part and also a challenge of implant therapy.

Despite the great efforts made to achieve the esthetic outcome of implant-supported restorations, esthetic complications, however, may evolve even with the slightest negligence. Although a variety of surgical techniques, including bone augmentation, connective tissue grafting and papilla reconstruction, have been introduced to manipulate the peri-implant hard and soft tissues in an attempt to optimize the esthetic outcome, so far none of these techniques has been proved predictable to overcome this problem and ensure esthetic success. Therefore, it is important for clinicians to understand the different factors that can affect the implant esthetic outcome.

Distinct papilla is of great importance for obtaining a favorable esthetic outcome following implant treatment.⁷ When restoring single missing tooth in the anterior maxilla, partial or total loss of interproximal papilla is one of the most common esthetic complications. Missing papilla would surely cause cosmetic deficiency (so-called black triangle), as well as phonetic problem. The interproximal papilla recession has been the focus of attention in many studies, and a number of factors have been found related to the final esthetic outcome. The level of bone support around the implant-borne single-tooth restoration is the key factor suggested to be of importance.⁸ To accomplish surrounding bone preservation, an inter implant-tooth distance of 1–1.5 mm were recommended to ensure the presence of interproximal papilla.⁹ A facial bone thickness of at least 2 mm has also been recommended to avoid crest bone and soft tissue recession when considering the bucco-lingual position of implant placement.¹⁰ Besides, other factors like prosthetic contact point were indicated to influence the papilla topography.¹¹ Many authors have agreed that complete papilla fill could be achieved, when the distance from the contact point to the bone crest was <5 mm.^{12–15}

Although these surgery-related and prosthesis-related factors may possibly manipulate the peri-implant soft tissue to a significant degree, the biological factors are still primarily control the soft tissue position and dimensions.¹⁶ Jemt observed that peri-implant papilla may fill after crown attachment without making any further tissue

¹Department of Oral and Maxillofacial Implantology, Shanghai Ninth People's Hospital Affiliated Shanghai Jiao Tong University School of Medicine, Shanghai, China; ²Faculty of Dentistry, the University of Hong Kong, Hong Kong, China and ³Jing'an Dental Clinic, Shanghai, China

Correspondence: Professor HC Lai, Department of Oral and Maxillofacial Implantology, Shanghai Ninth People's Hospital Affiliated Shanghai Jiao Tong University School of Medicine, 639 Zhizaoju Road, Shanghai 200011, China
E-mail: lhc9@hotmail.com

Received 20 December 2011; Accepted 27 April 2012

manipulation.¹⁷ In addition, data reported by Choquet *et al.*¹² showed the presence of a mean proximal soft tissue height of about 4 mm is independent of the degree of papilla fill adjacent to single implants. These studies may indicate that the interproximal papilla may have a self-repaired capacity, and this capacity might be determined by some patient-related biological factors which could not be manipulated by additional techniques.

The soft tissue biotype is one of the biological factors, which has been suggested to influence the presence of the interproximal papilla.^{18–19} Kois described the gingival biotype as being thick or thin.¹⁸ Compared with the thin mucosa, the thick mucosa implies more fibrotic tissue, more vascularization and thicker underlying hard tissue, while the thin mucosa presents the opposite. Therefore, a thin soft tissue biotype may be frequently associated with a tendency of severe recession and a higher esthetic risk than a thick one. Many studies have been involved in this topic, but the high-level evidence is scarce. The relationship between the soft tissue biotype and the esthetic outcome of interproximal papilla after single-implant restoration is still controversial.

Thus, in the present prospective study, we aimed to investigate the peri-implant papilla alterations from the time of supra-structure placement to 6-month postloading at single-implant restoration in the anterior maxilla, and to assess the influence of soft tissue biotype on the alteration pattern after controlling other prosthetic or surgical factors.

MATERIALS AND METHODS

Preliminary study

In order to identify the true soft tissue thickness after single tooth missing in the anterior maxilla, a preliminary study was conducted before further analysis. Forty adults with single missing tooth in the anterior maxilla and good overall oral health were included between June 2010 and November 2010 at the Department of Oral and Maxillofacial Implantology, Shanghai Ninth People's Hospital Affiliated Shanghai Jiao Tong University School of Medicine, China. Any patients with presence of periodontal inflammation or large amount of bone loss were excluded.

Direct measurement of the facial soft tissue thickness was performed at the midpoint of a reference area showed on Figure 1. A smooth broach with a rubber stopper was punctured into the facial soft tissue until it reached the bone. The rubber stopper was put on the soft tissue surface to mark the position. The thickness of facial soft tissue was equal to the distance between the pinpoint and the rubber

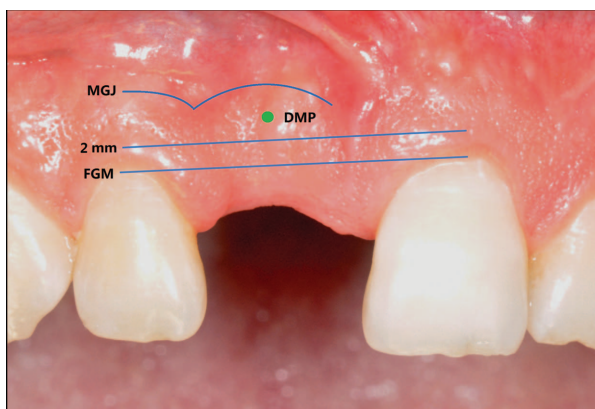


Figure 1 Direct measurement of soft tissue thickness. DMP, direct measurement point; FGM, free gingival margin; MGJ, mucogingival junction.

stopper recorded by a digital caliper to the nearest 0.1 mm. The measurement was made twice by two experienced implant surgeons. The range and mean value of soft tissue thickness in all the subjects were calculated. The soft tissue biotype of the edentulous site was classified into thick or thin by the mean value.

At the same time, the soft tissue biotype of the counter-lateral tooth was evaluated by periodontal probe transparency described by Kan *et al.*²⁰ and De Rouck *et al.*²¹ The soft tissue biotype was categorized as either thin (visible) or thick (not visible) according to the visibility of the underlying periodontal probe (CPU 15 UNC; Hu-Friedy, Chicago, IL, USA).

The two methods on soft tissue biotype assessment were compared using the Cohen's κ statistics.

Patient selection

The patients visited and consecutively treated with single implant (SLA, Standard Plus, Straumann; Insitut Straumann AG, Basel, Switzerland) in the anterior maxilla during December 2009 and March 2011, at the Department of Oral and Maxillofacial Implantology, Shanghai Ninth People's Hospital, Shanghai Jiaotong University, China, were recruited in the present study.

The inclusion criteria were as follows: (i) at least 18 years old; (ii) single missing tooth in the anterior maxilla with both neighboring teeth present; (iii) the extraction socket has fully healed according to the pre-treatment intra-oral radiographs or computer tomography (CT) scans; and (iv) signed informed consent.

The exclusion criteria were as follows: (i) medical conditions that would contraindicate dental surgery, e.g., uncontrolled diabetes, uncontrolled hypertension, pregnancy; (ii) smokers; (iii) untreated periodontal diseases and/or caries; (iv) need of restorative treatment of adjacent teeth; and (v) need to perform any form of bone augmentation before or in conjunction with implant surgery. The study was conducted in accordance with the Helsinki Declaration of 1975 as revised in 2000, and all patients signed the informed consent form and received oral hygiene instructions before entering the study. The study design had been approved by the Ethics Boards of Shanghai Ninth People's Hospital Affiliated Shanghai Jiao Tong University School of Medicine.

Pre-operative evaluation

All patients received examinations regarding periodontal diseases, caries and soft tissue disorders, and then accepted appropriate treatment and oral hygiene. Intra-oral and panoramic radiographs or CT scans were obtained before implant installation. A complete examination of hard and soft oral tissues was conducted for each patient to assess the soft tissue biotype and bone volume of the intended implant sites. The thickness of the soft tissue was measured before surgery directly using the same method described in the preliminary study. The measurement was made twice by two experienced implant surgeons. The patients were divided into two groups according to the thickness of soft tissue: (i) $1.5 \text{ mm} \leq \text{thickness of soft tissue} \leq 3 \text{ mm}$; and (ii) $3 \text{ mm} < \text{thickness of soft tissue} \leq 4.5 \text{ mm}$.

Implant placement

The implant placement was planned based on clinical and radiographic evaluation. All surgeries were performed using a midcrestal incision following local xylocaine infiltration anesthesia. No releasing incisions were used. After full-thickness flaps were elevated labially and lingually to expose the bone ridge, the implants were placed according to the standard surgical procedures defined by the

manufacturer. Briefly, a round bur was first used to mark the implant positions. Then, a pilot drilling (Φ 2.2 mm) was performed to the depth designed from the presurgical radiograph or CT scan. The implant bed was further prepared with drills in different widths in accordance to the implant diameters (Φ 2.8 mm drill for Φ 3.3 mm implants, Φ 3.5 mm drill for Φ 4.1 mm implants). A correct three-dimensional implant position was considered of pivotal importance in all cases. The neighboring teeth essentially served as a reference for correct implant position. In the mesio-distal dimension, a minimum distance of 1.5 mm between the implant shoulder and the adjacent tooth was pursued. In the oro-facial dimension, the implant shoulder was placed palatal to the point of emergence at the adjacent tooth. In the apico-coronal dimension, the implant shoulder was located at the level 1–2 mm apical position from the cement–enamel junction of the neighboring teeth. The patient with edentulous site which could not ensure correct three-dimensional position was excluded. Finally, the SLA implants were placed in the prepared sites using a hand ratchet without tapping. All implants achieved good primary stability. Cases of fenestration or dehiscence where implant threads had been exposed that needed any grafting were excluded from the study. Non-submerged technique and one-stage procedure were used. A panoramic and a periapical radiograph were immediately taken of all the cases.

Postsurgical procedure

After surgery, antibiotics amoxicillin (Xinya Co., Shanghai, China; 500 mg, four times a day for 7 days) and metronidazole (Xinyiwangxiang, Shanghai, China; 400 mg, three times a day for 7 days) were used. Chlorhexidine oral rinse (0.12%) was prescribed for 60 s 5–6 times a day for 14 days. Sutures were removed 7–10 days after surgery. Patients were not allowed to use any removable prostheses during healing period. The patients were encouraged to perform personal teeth cleaning and to maintain good oral hygiene during healing period.

Prosthetic procedure

Intra-oral and panoramic radiographs were taken of all the patients 10–14 weeks after implant placement, to evaluate the healing of the implants. The absence of implant mobility and pain was considered indicative of adequate osseointegration. Implants with any peri-implant inflammation symptoms were excluded at this time. The peri-implant inflammation symptoms include bleeding on probing, increased probing depth and suppuration on probing. Implant-level impression was taken and the porcelain (Ivoclar-Vivadent AG, Schaan, Lichtenstein) fused to noble metal (Heraeus-Kulzer Corporation, Hanau, Germany) single crown was fabricated. The contact point area of the crown was carefully designed by the technician. The most coronal bone-to-implant contact is thought to be located at the junction of implant body and machined neck in an osseointegrated implant, and the crest bone level should be higher than or at this level. Thus, a maximal distance of 3 mm was set from the crown margin to the contact point to ensure the 5-mm distance from the contact point to the bone crest, after adding a 1.8-mm implant neck. The crown was cemented 10 days after impression taking.

Papilla fill index assessment

Digital clinical photographs were used to evaluate the papilla levels. The photographs were taken at a 1:1 magnification perpendicular to the buccal surface of the single-tooth implant crown, using a Nikon D90 digital camera (Nikon Inc., Tokyo, Japan) with macro lens and ring flash. The images of implant crowns and soft tissue, including at

least one adjacent tooth on each side, were obtained at two time points: 0.5 h after the crown attachment (baseline) and 6 months after (follow-up). At each time point, the patient was positioned in front of the camera in a reproducible manner. One assistant was responsible for taking the photographs. When taking photographs, a bite fork with or without a face bow was used to orientate the maxillary occlusal plane. A tripod was used to steady the camera in a constant distance from the dental chair. The shooting direction of the camera was adjusted according to the bite fork handle to obtain reproducible results.

Two prothodontists blind to the soft tissue biotype classification were responsible for assessing the papilla fill index (PFI) according to the photographs as the method suggested by Jemt.¹⁷ PFI score ranges from 0 to 4. Index score 0 denotes no soft tissue in the area; index score 1 denotes soft tissue reaching less than half the distance between the reference line and the contact point; index score 2 denotes more soft tissue than indicated by index score 1 but not extending all the way to the contact point; index score 3 denotes tissue filling the entire embrasure; and index score 4 denotes a hyperplastic papilla. The mesial and distal papilla at each site of one implant was considered as individual unit of analysis. A total of 64 papillae (i.e., 32 papillae of each group) were available for evaluation at each time point of healing.

Statistical analysis

Data collection was performed by two independent examiners. The descriptive and the quantitative data were recorded in a patient chart individually for later analysis. The inter-examiner agreement was analyzed by intraclass correlation coefficient for continuous variables (soft tissue thickness). For qualitative variables (PFI), the inter-examiner agreement was evaluated by Cohen's κ statistics. Descriptive statistics were performed, and absolute and relative frequency distributions were calculated for qualitative variables. Mean and standard deviation were calculated for quantitative variables. Wilcoxon signed ranks test was used to compare the differences of PFI assessments between the baseline and follow-up. To compare the difference between the two groups, Fisher's exact test was performed. SPSS statistics 17.0 was used to perform the statistical analyses. Statistical analysis of a possible influence of independent variables ('time point' and 'group of soft tissue thickness') on the dependent variables (PFI) was performed using an ordinal logistic regression model. Pearson and deviance Chi-square tests for goodness of fit of the model were conducted. A Wald test was used to assess the statistical significance of each factor. The significance level was set at 0.05.

RESULTS

Preliminary study

Twenty-eight women and 12 men, aged 20–46 years were included in the preliminary study. The mean value of soft tissue thickness was (3.0 ± 1.1) mm (range from 1.2 to 4.8 mm). Therefore, the cut-off line used to distinguish 'thin biotype' from 'thick biotype' was set at 3 mm. Frequency distribution of the soft tissue thickness from direct measurement versus soft tissue biotype (thin or thick) assessed by periodontal probe transparency was showed in Table 1. Cohen's κ statistics showed that the agreement of the two methods was high ($\kappa=0.75$, $P<0.000$).

Patients' information

Thirty-two patients (eight women and 24 men), aged 21–40 years (mean 31.1 years), subjected to single-implant placement in the anterior maxilla, were included in the present study between December 2010 and June 2011. There were four patients with treated

Table 1 Comparison of frequency distribution of soft tissue biotype measured by DM against PT^a

Soft tissue biotype (DM)	Soft tissue biotype (PT)		
	Thin	Thick	Total
Thin (≤ 3 mm)	19	4	23
Thick (> 3 mm)	1	16	17
Total	20	20	40

DM, direct measurement; PT, probe transparency.

^a Cohen's $\kappa = 0.75$ ($P < 0.001$).

periodontal diseases included in the present study (two in group 1 and two in group 2). The periodontal parameters assessed before implant installation were nearly normal and stable. The average healing time before loading was 11.5 weeks, the follow-up time was 6 months after loading. There were no exclusions in the patients because of insufficient bone volume or primary stability. No patient dropped out during the follow-up period.

Inter-examiner agreement

The inter-examiner agreement was evaluated in all the subjects. Intraclass correlation coefficient was 0.997 ($P < 0.001$) for soft tissue thickness. A κ of 0.955 ($P < 0.001$) was found for PFI. The measurements of two examiners showed high agreement for both continuous variables and qualitative variables.

Implant distribution and success rate

All the patients were treated with a soft-tissue level titanium implant with moderate rough surface and a machined neck of 1.8 mm in height. Table 2 showed that the distribution of inserted implants. Marked variability was noted in the implant sizes selected for placement, although 12 mm length and Φ 4.1 mm diameter were most commonly used. Central incisors were replaced most often (18 central incisors), whereas only two implants were placed in the canine sites. Twelve implants were distributed in lateral incisor sites.

Table 2 Distribution of inserted implants

Implant number	Length/mm		Diameter/mm		Location		
	10	12	3.3	4.1	Central incisor	Lateral incisor	Canine
Group 1	3	13	4	12	10	4	2
Group 2	1	15	6	10	8	8	0
Total	4	28	10	22	18	12	2

Table 3 A summary of PFI scores at baseline and 6-month follow-up in groups 1 and 2

PFI	Group 1				Group 2			
	Baseline		Follow-up		Baseline		Follow-up	
	Number of implant	%	Number of implant	%	Number of implant	%	Number of implant	%
0	7	22	3	9	1	3	0	0
1	18	56	13	41	11	34	4	12
2	7	22	10	31	17	53	13	41
3	0	0	6	19	3	9	15	47
4	0	0	0	0	0	0	0	0
Wilcoxon signed ranks test	Z = -4.559 ($P < 0.001$) ^a				Z = -4.583 ($P < 0.001$) ^a			

PFI, papilla fill index.

^a Wilcoxon signed ranks test showed that significant differences between baseline and follow-up were found for both groups.

All of 32 implants represented sign of osseointegration after 10–14 weeks of healing, and no implant lost or mobility has been found in the observation period, pointing to an implant success rate of 100% using the criteria of Albrektsson *et al.*⁴ None of the implants was involved in peri-implant inflammations during the observation.

Soft tissue biotype and PFI assessment

The mean mucosal thickness was (2.5 \pm 0.3) mm for group 1 and (3.8 \pm 0.3) mm for group 2 respectively. A total of 64 papillae were available for evaluation (32 papillae in each group). The PFI scores at baseline and at the follow-up were presented in Table 3. At baseline, 22% of the interproximal papillae in group 1 had $> 50\%$ papilla fill (scores 2–4) and none shown a completely filled of the interpapilla space between the implant and the tooth. While in group 2, 62% of the interproximal papillae showed $> 50\%$ papilla fill, in which three papillae were filled completely (score 3). After 6-month healing, 50% and 88% of the interproximal sites show a papilla fill of $> 50\%$ in thin and thick mucosa biotype, respectively, in which there were 19% and 47% demonstrating a complete papilla fill in groups 1 and 2, respectively.

Significant difference between baseline and follow-up for the two groups was found ($P < 0.001$). Table 4 showed that the PFI score variation between baseline and follow-up in two groups. In both groups, PFI scores variation represented positive alterations. No negative alteration was detected. Significant difference in the PFI scores was found between the two groups both at baseline and follow-up ($P < 0.001$), but no statistic difference was detected in PFI variation ($P = 0.797$).

Logistic regression results

Pearson and deviance Chi-square results showed high goodness-of-fit of the regression model (Pearson Chi-square: 0.699, $P = 0.705$; residual deviance: 0.560, $P = 0.756$). Ordinal logistic regression analysis showed that the independent variables ‘time point’ and ‘group of soft tissue thickness’ has significant association with the dependent variable ‘PFI’ ($P < 0.001$) (Table 5). When dividing the soft tissue thickness into two groups, the likelihood to obtain papilla fill was significantly higher for

Table 4 PFI scores at baseline, follow-up and the variation in groups 1 and 2

Group 1			Group 2		
Baseline	Follow-up	Variation	Baseline	Follow-up	Variation
0	0	0	0	1	1
0	0	0	1	1	0
0	0	0	1	1	0
0	1	1	1	1	0
0	1	1	1	2	1
0	1	1	1	2	1
0	1	1	1	2	1
1	1	0	1	2	1
1	1	0	1	2	1
1	1	0	1	2	1
1	1	0	1	2	1
1	1	0	2	2	0
1	1	0	2	2	0
1	1	0	2	2	0
1	1	0	2	2	0
1	2	1	2	2	0
1	2	1	2	3	1
1	2	1	2	3	1
1	2	1	2	3	1
1	2	1	2	3	1
1	2	1	2	3	1
1	2	1	2	3	1
1	2	1	2	3	1
2	2	0	2	3	1
2	3	1	2	3	1
2	3	1	2	3	1
2	3	1	2	3	1
2	3	1	3	3	0
2	3	1	3	3	0
2	3	1	3	3	0
Fisher's exact test			$P=0.003^a$	$P=0.005^a$	$P=0.797$

Abbreviation: PFI, papilla fill index.

^aFisher's exact test showed that significant difference in the PFI variation was found between the two groups.

group 2 (odds ratio: 6.05; 95% confidence interval (CI): 2.94–12.45). Moreover, a recovery period of time (6 month) was statistically significantly ($P<0.001$) associated with a higher PFI score, with an odds ratio of 4.65 (95% CI: 2.30–9.42).

Figures 2 and 3 show the clinical photographs of the implant supported crowns and peri-implant soft tissue at baseline and follow-up in two groups.

Table 5 Logistic regression for explanatory variables effect on PFI

Variables	B	Odds ratio	95% CI	P value
Group of soft tissue thickness				0.001 ^a
Group 1	0	1		
Group 2	1.80	6.05	2.94–12.45	
Time point				0.001 ^a
Baseline	0	1		
Follow-up	1.54	4.65	2.30–9.42	

B, regression coefficients; CI, confidence interval; PFI, papilla fill index.

^aPearson and deviance Chi-square results showed high goodness-of-fit of the regression model (Pearson Chi-square: 0.699, $P=0.705$; residual deviance: 0.560, $P=0.756$).

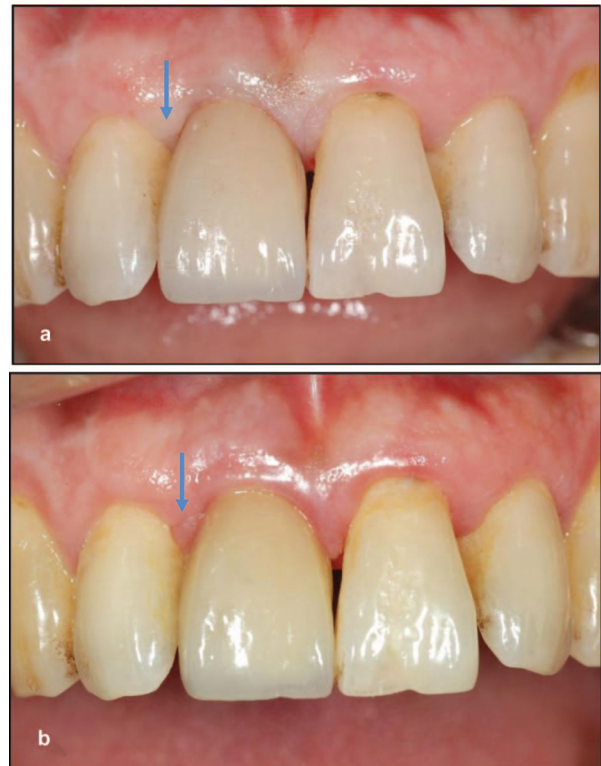

Figure 2 View of the implant-supported crown in the region of upper right central incisor in group 1. The distal papilla (blue array) variation: (a) baseline PFI scores: 1; (b) follow-up PFI score: 2. PFI, papilla fill index.

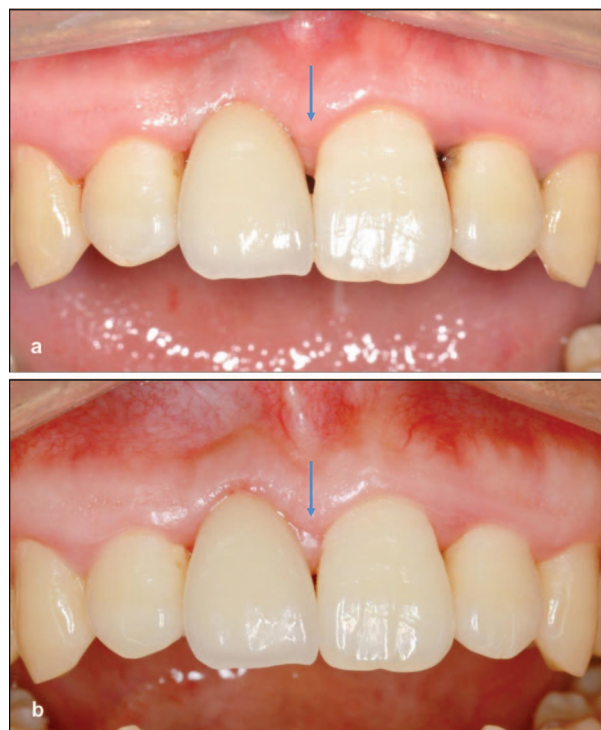

Figure 3 View of the implant-supported crown in the region of upper right incisor in group 2. The mesial papilla (blue array) variation: (a) baseline PFI scores: 1; (b) follow-up PFI score: 2. PFI, papilla fill index.

DISCUSSION

Achieving optimal soft tissue esthetics around anterior single implant is a challenging procedure, and it is even demanding to maintain the esthetic outcome over time. Despite the high success of the osseointegrated implants, the peri-implant mucosa recession has been often reported.²² The relevant influence factors and the mucosa response have not been clarified.

The esthetic appearance of peri-implant tissue, including health, height, volume, color, and contour, are supposed to be in harmony with the healthy surrounding dentition. The papilla with perfect shape is deemed important for obtaining a favorable esthetic result.¹⁷ Missing papilla will cause a 'black triangle' apical to the contact point of the implant-supported crown, which could be detected by the patients and the professionals most easily of any other esthetic complications. Since the crucial and independent feature of interproximal papilla, in the present study, we chose only the papilla to be the subject and investigated its spontaneous alterations during a 6-month post-loading period after single-implant restoration in the anterior maxilla without any intervention. We also evaluate the soft tissue thickness impact on papilla alteration pattern.

The ITI Consensus Conference suggested that soft tissue stability around implant restorations and adjacent teeth is of paramount importance in the anterior maxilla.^{23–24} Whether the peri-implant soft tissue changes in a regular pattern has been the focus of many researches.^{25–27} They found that, after the final restoration, there might exist significant changes in soft tissue levels, and most of the variation occurred during the first 3–6 months postloading. The results of the present study also showed that, after 6-month observation, a significant improvement in papilla fill was detected around single-implant crowns. Significant difference in PFI scores was also found between the baseline and the follow-up for both thin and thick mucosa. These findings also agreed with our previous study in 2008: the esthetic outcome of soft tissue around the non-submerged implant had improved significantly according to pink esthetic score assessment and the pink esthetic score score for mesial and distal papilla increased significantly at 6- to 8-month follow-up.²⁸ Thus, it can be seen that the papilla might have the potential of spontaneous rebound and could improve without any manipulation. It is supposed that the establishment of a stable biological dimension around the implant-supported restoration may contribute to this improvement in papilla fill. Kourkouta *et al.*²⁹ demonstrated in their study that, the biological capacity for generation of an interproximal papilla was related to the biological width, which equaled 7 mm distance from the papilla tip to the apical bone level (sulcus depth + epithelial attachment + the connective tissue contact). Besides, it is interesting that all the PFI score variations in the present study represented positive alterations. No negative alteration was detected. In addition, there was no papilla with a score of 4, and no sign or symptom of soft tissue inflammation was presented during 6 months. This may revealed that, the interproximal papilla level could gain constant improvement in good health. The misinterpretation of increased papilla volume due to inflammation should be avoided. However, an observation of 6 months is not enough to come to the final conclusion. The stability of peri-implant soft tissue should be future studied in long-term observation.

The interproximal papilla level around anterior single-tooth implants was influenced by multiple factors. Buser *et al.*⁹ has suggested that adequate bone volume is essential for esthetic outcomes, as it constitutes the base for supra-crest soft tissue. In the present study, we try to control the influence from bone volume and manipulate the surgical and restorative factors by following the recommendations

from other studies.^{9–10,30} Any patients with edentulous site which could not ensure correct three-dimensional position were excluded. At the crown fabrication, the distance from the prosthesis contact point to the bone crest was also controlled to eliminate the confounding factors.

Soft tissue biotype is used to describe the thickness of mucosa in a bucco-lingual dimension, which is thought to be one of the factors impact esthetic outcomes. Comparing to other factors related to surgery and restoration, the soft tissue thickness is biological and hard to be manipulated by any procedures. The gingival biotype of a nature tooth is often diagnosed by the transparency of a periodontal probe.²⁰ It has been revisited by De Rouck *et al.*²¹ in 2009, but still be hardly applied in an edentulous region. In the present study, we evaluate the soft tissue thickness at the edentulous site by direct measurement, and divided them into 'thick' or 'thin' using the cut-off line at 3 mm. The results of the preliminary study showed no appreciable difference in the reproducibility of interpretation by these two classification methods. In addition, the true value of the soft tissue thickness could be recorded using direct measurement and might help to analyze its influence on papilla alteration. In the current study, the influence of the soft tissue thickness on interproximal papilla alteration after single-implant restoration in the anterior maxilla was addressed. The interproximal papilla heights at baseline and follow-up were both significantly higher in the group with the thick mucosa than with the thin one. The logistic regression results also showed that the thicker soft tissue was strongly correlated with higher PFI score. These results revealed that the patients with thicker mucosa in the anterior maxilla could achieve more favorable esthetic outcome of papilla than those with thin mucosa. The finding of the present study is in line with other studies which indicated that a thin soft tissue biotype was more prone to recession after implant-supported restoration.^{18–19} Romeo *et al.*³¹ also studied 48 single-tooth implants in 2008, and also agreed that the thick biotype was significantly correlated with papilla presence.

The reason of this phenomenon might be explained by the soft tissue capacity to resist the recession result from trauma and bacteria after implant surgery. According to Goaslin's study in 1977, a desirable esthetic outcome can be expected in 'thick, flat' biotype, because it tends to insult by pocket formation instead of recession.³² In contrast, the 'thin' biotype is often subject to gingival recession following the mechanical and surgical manipulation.³³ Bashutski *et al.*³⁴ has suggested that the patient's biotype determines how the periodontium will respond to implant placement. The peri-implant mucosa might behave in a similar manner as the periodontium after implant surgery. But the detailed mechanism is still unknown. Clinical relevance of these observations has to be tested in longitudinal studies.

Although many investigators tried to make objective judgment using reproducible assessment system, it is well known that esthetics is, by definition, subjective. Chang *et al.*¹¹ also addressed that, factors which are considered by professionals to be of significance for the esthetic outcome of implant-supported restorations may not be of decisive importance for patient satisfaction. Therefore, evaluation of patient's subjective satisfaction should also be future integrated in the comprehensive assessment of esthetic outcome in the anterior maxilla.

With regard to patients' periodontal status, the sample size in the present study is not sufficient to investigate the influence of periodontal disease on papillar alteration. Further study should be conducted to analyze this issue. In addition, there were no considerations of some factors which may confound the findings, e.g., patients' oral hygiene habits, alcohol intake or smoking status in the present study. Further study is needed to take these variables into account.

CONCLUSION

In conclusion, within the limitation of the present study, the esthetic outcome of the papilla around a single-tooth implant was significantly improved after a 6-month follow-up compared with the baseline according to PFI assessment. The thicker mucosa implied a significantly more favorable papilla fill. Long-term studies with a bigger sample size will be needed to confirm the results.

ACKNOWLEDGMENTS

This study has been jointly supported by Science and Technology Commission of Shanghai Municipality (09411955000 and 1052nm04500), National Natural Science Foundation of China (31070842), and National Basic Research Program of China (2012CB933604).

- 1 Creugers NH, Kreulen CM, Snoek PA *et al*. A systematic review of single tooth restorations supported by implants. *J Dent* 2000; **28**(4): 209–217.
- 2 Berglundh T, Persson L, Klinge B. A systematic review of the incidence of biological and technical complications in implant dentistry reported in prospective longitudinal studies of at least 5 years. *J Clin Periodontol* 2002; **29**(Suppl 3): 197–212.
- 3 Jung RE, Pjetursson BE, Glauser R *et al*. A systematic review of the 5-year survival and complication rate of implant-supported single crowns. *Clin Oral Implants Res* 2008; **19**(2): 119–130.
- 4 Albrektsson T, Zarb G, Worthington P *et al*. The long-term efficacy of currently used dental implants: a review and proposed criteria of success. *Int J Oral Maxillofac Implants* 1986; **1**(1): 11–25.
- 5 Lang NP, Berglundh T, Heitz-Mayfield LJ *et al*. Consensus statements and recommended clinical procedures regarding implant survival and complications. *Int J Oral Maxillofac Implants* 2004; **19**(Suppl): 150–154.
- 6 Smith DE, Zarb GA. Criteria for success of osseointegrated endosseous implants. *J Prosthet Dent* 1989; **62**(5): 567–572.
- 7 Schropp L, Isidor F, Kostopoulos L. Interproximal papilla levels following early versus delayed placement of single-tooth implants: a controlled clinical trial. *Int J Oral Maxillofac Implants* 2005; **20**(5): 753–761.
- 8 Belsler UC, Buser D, Hess D *et al*. Esthetic implant restorations in partially edentulous patients—a critical appraisal. *Periodontol* 2000 1998; **17**(1): 132–150.
- 9 Buser D, Martin W, Belsler U. Optimizing esthetics for implant restorations in the anterior maxilla: anatomic and surgical considerations. *Int J Oral Maxillofac Implants* 2004; **19**(Suppl): 43–61.
- 10 Spray JR, Black CG, Morris HF *et al*. The influence of bone thickness on facial marginal bone response: stage 1 placement through stage 2 uncovering. *Ann Periodontol* 2000; **5**(1): 119–128.
- 11 Chang M, Wennström JL, Ödman P *et al*. Implant supported single-tooth replacements compared to contralateral natural teeth. Crown and soft tissue dimensions. *Clin Oral Implants Res* 1999; **10**(3): 185–194.
- 12 Choquet V, Hermans M, Adriaenssens P *et al*. Clinical and radiographic evaluation of the papilla level adjacent to single-tooth dental implants. A retrospective study in the maxillary anterior region. *J Periodontol* 2001; **72**(10): 1364–1371.
- 13 Ryser MR, Block MS, Mercante DE. Correlation of papilla to crestal bone levels around single tooth implants in immediate or delayed crown protocols. *Int J Oral Maxillofac Surg* 2005; **63**(8): 1184–1195.
- 14 Palmer RM, Farkondeh N, Palmer PJ *et al*. Astra tech single-tooth implants: an audit of patient satisfaction and soft tissue form. *J Clin Periodontol* 2007; **34**(7): 633–638.
- 15 Nisapakultrorn K, Suphanantachat S, Silkosessak O *et al*. Factors affecting soft tissue level around anterior maxillary single-tooth implants. *Clin Oral Implants Res* 2010; **21**(6): 662–670.
- 16 Cardaropoli G, Lekholm U, Wennström JL. Tissue alterations at implant-supported single-tooth replacements: a 1-year prospective clinical study. *Clin Oral Implants Res* 2006; **17**(2): 165–171.
- 17 Jemt T. Regeneration of gingival papillae after single-implant treatment. *Int J Periodontics Restorative Dent* 1997; **17**(4): 326–333.
- 18 Kois JC. Predictable single tooth periimplant esthetics: five diagnostic keys. *Compend Contin Educ Dent* 2001; **22**(3): 199–206.
- 19 Zetu L, Wang HL. Management of interdental/inter-implant papilla. *J Clin Periodontol* 2005; **32**(7): 831–839.
- 20 Kan JY, Rungcharassaeng K, Umezue K *et al*. Dimensions of peri-implant mucosa: an evaluation of maxillary anterior single implants in humans. *J Periodontol* 2003; **74**(4): 557–562.
- 21 De Rouck T, Eghbali R, Collys K *et al*. The gingival biotype revisited: transparency of the periodontal probe through the gingival margin as a method to discriminate thin from thick gingiva. *J Clin Periodontol* 2009; **36**(5): 428–433.
- 22 Goodacre CJ, Kan JYK, Rungcharassaeng K. Clinical complications of osseointegrated implants. *J Prosthet Dent* 1999; **81**(5): 537–552.
- 23 Belsler U, Buser D, Higginbottom F. Consensus statements and recommended clinical procedures regarding esthetics in implant dentistry. *Int J Oral Maxillofac Implants* 2004; **19**(Suppl): 73–74.
- 24 Belsler U, Schmid B, Higginbottom F *et al*. Outcome analysis of implant restorations located in the anterior maxilla: a review of the recent literature. *Int J Oral Maxillofac Implants* 2004; **19**(Suppl): 30–42.
- 25 Small PN, Tarnow DP. Gingival recession around implants: a 1-year longitudinal prospective study. *Int J Oral Maxillofac Implants* 2000; **15**(4): 527–532.
- 26 Oates TW, West J, Jones J *et al*. Long term changes in soft tissue height on the facial surface of dental implant. *Implant Dent* 2002; **11**(3): 272–279.
- 27 Priest G. Predictability of soft tissue form around single tooth implant restorations. *Int J Periodontics Restorative Dent* 2003; **23**(1): 19–27.
- 28 Lai HC, Zhang ZY, Wang F *et al*. Evaluation of soft-tissue alteration around implant-supported single-tooth restoration in anterior maxilla: the pink esthetic score. *Clin Oral Implants Res* 2008; **19**(6): 560–564.
- 29 Kourkouta S, Dedi KD, Paquette DW *et al*. Interproximal tissue dimensions in relation to adjacent implants in the anterior maxilla: clinical observations and patient aesthetic evaluation. *Clin Oral Implants Res* 2009; **20**(12): 1375–1385.
- 30 Tarnow DP, Magner AW, Fletcher P. The effect of the distance from the contact point to the crest of bone on the presence or absence of the interproximal dental papilla. *J Periodontol* 1992; **63**(12): 995.
- 31 Romeo E, Lops D, Rossi A *et al*. Surgical and prosthetic management of interproximal region with single-implant restorations: 1-year prospective study. *J Periodontol* 2008; **79**(6): 1048–1055.
- 32 Goaslind GD, Robertson PB, Mahan CJ *et al*. Thickness of facial gingiva. *J Periodontol* 1977; **48**(12): 768–771.
- 33 Müller HP, Heinecke A, Schaller N *et al*. Masticatory mucosa in subjects with different periodontal phenotypes. *J Clin Periodontol* 2000; **27**(9): 621–626.
- 34 Bashutski JD, Wang HL. Common implant esthetic complications. *Implant Dent* 2007; **16**(4): 340–348.



This work is licensed under a Creative Commons Attribution-NonCommercial-NoDerivative Works 3.0 Unported License. To view a copy of this license, visit <http://creativecommons.org/licenses/by-nc-nd/3.0>