



Long-term Results in Children with Henoch-Schönlein Nephritis

Henoch-Schönlein Nefriti Olan Çocuk Hastaların Uzun Dönem İzlem Sonuçları

Caner ASLAN¹, Nilufer GOKNAR², Emre KELESOGLU², Diana UCKARDES², Cengiz CANDAN²

¹Istanbul Goztepe Prof. Dr. Suleyman Yalcin City Hospital, Clinic of Pediatrics, Istanbul, Turkey

²Istanbul Medeniyet University Faculty of Medicine; Istanbul Goztepe Prof. Dr. Suleyman Yalcin City Hospital, Clinic of Pediatric Nephrology, Istanbul, Turkey

ABSTRACT

Objective: Henoch-Schönlein purpura (HSP) is a small vessel vasculitis and palpable purpura, with arthritis, gastrointestinal as abdominal pain, and renal involvement as typical clinical findings. The most important prognostic factor for HSP vasculitis is renal involvement. This study aimed to investigate the relationship between clinical, laboratory, and histopathologic findings of children with HSP nephritis with long-term renal prognosis.

Methods: This retrospective study included children with HSP nephritis between January 2010 and December 2019. Initial clinical presentation, laboratory findings, and kidney biopsy results were obtained, and treatment modalities were recorded and classified using the Meadow classification and grouped into mild and severe cases. Additionally, data at the last follow-up were analyzed and classified.

Results: A total of 90 children (59 male) with a mean age of 8.8±3.2 years were included. According to initial clinical findings, 18 children were in the Meadow's severe group. Fifteen (15/72) children in the mild group and all children in the severe group had undergone kidney biopsy. The severe group had higher histopathologic stages compared to the mild group (p=0.022). Immunosuppressive treatments were used in 44.4% of mild cases and 100% of severe cases (p<0.01). On follow-up, only four children (two in the mild group) had persistent proteinuria.

Conclusions: Severe clinical findings in the initial presentation were related to more intensive immunosuppressive treatment. Additionally, renal histopathological stages were higher in the severe group. Long-term follow-up for proteinuria is mandatory for all children with HSP nephritis, even with mild initial clinical findings.

Keywords: Henoch-Schönlein purpura, proteinuria, chronic kidney disease

ÖZ

Amaç: Henoch-Schönlein purpurası (HSP) küçük damarları tutan bir vaskülit olup palpabl purpura, artrit, karın ağrısının belirgin olduğu gastrointestinal tutulum ve renal hastalık en sık görülen klinik bulgularıdır. Bu çalışmada HSP nefriti olan çocuklarda klinik, laboratuvar ve histopatolojik bulguların uzun dönem renal prognoz ile ilişkisini irdeledik.

Yöntemler: Bu retrospektif çalışmaya Ocak 2010 ile Aralık 2019 tarihleri arasında HSP nefriti tanısı alan çocuk hastalar dahil edildi. Başlangıçtaki klinik bulgular, laboratuvar sonuçları, yapıldıysa böbrek biyopsi sonuçları kaydedildi ve tüm hastalar Meadow sınıflamasına göre hafif ve ağır olarak gruplandırıldı. Ayrıca son kontroldeki klinik ve laboratuvar durumları değerlendirildi ve sınıflandırıldı.

Bulgular: Yaş ortalaması 8,8±3,2 yıl olan 90 çocuk (59 erkek) dahil edildi. Başlangıç bulgularına göre 18 çocuk Meadow ağır gruptaydı. Hafif gruptaki on beş çocuğa (15/72) ve ağır gruptaki tüm çocuklara böbrek biyopsisi yapıldı. Ağır grupta yer alanların böbrek biyopsilerinin histopatolojik evrelemesi hafif gruba göre daha yüksekti (p=0,022). İmmünoşpresif tedavi hafif gruptakilerin %44,4'üne, ağır gruptakilerin ise %100'üne uygulanmıştı (p<0,01). Persistan proteinüri uzun dönem izlemde ikisi hafif ikisi ağır grupta olan toplam dört çocukta vardı.

Sonuçlar: Başvurudaki klinik bulguların şiddetinin daha yoğun immünoşpresif tedavi ile ilişkili olduğu ve ağır klinik bulguları olanların renal histopatolojik değerlendirmede daha ileri evrede olduğu gösterilmiştir. HSP nefriti geçiren çocuklar başlangıç klinik bulguları hafif olsa dahi proteinüri açısından uzun dönem izlenmelidir.

Anahtar kelimeler: Henoch-Schönlein purpura, proteinüri, kronik böbrek yetmezliği

Presented in: This study was presented at the 53rd European Society of Pediatric congress in the format of oral pitch & poster presentation. The name of our poster was "The Evaluation of Clinical, Laboratory, and Pathologic Findings of Children with Henoch-Schönlein Nephritis and Investigating the Effect on Prognosis." Additionally, we performed an oral presentation of this study in the "1st Çocuk Medeniyeti Çevrim içi Sempozyumu."

Address for Correspondence: N. Goknar, Istanbul Medeniyet University Faculty of Medicine; Istanbul Goztepe Prof. Dr. Suleyman Yalcin City Hospital, Clinic of Pediatric Nephrology, Istanbul, Turkey
E-mail: nilufergoknar@gmail.com **ORCID ID:** orcid.org/0000-0003-4376-1216

Received: 09 December 2022
Accepted: 08 May 2022
Online First: 20 May 2022

Cite as: Aslan C, Goknar N, Kelesoglu E, Uckardes D, Candan C. Long-term Results in Children with Henoch-Schönlein Nephritis. Medeni Med J 2022;37:159-164

INTRODUCTION

Henoch-Schönlein purpura (HSP) is a common small vessel vasculitis with an incidence of 135 per 1 million children¹. Kidney involvement is the most important complication. Hematuria and mild proteinuria may be observed in 30%-50% of cases^{1,2}. These findings are mostly self-limiting. However, sequelae remain long-term in patients with nephrotic-range proteinuria and severe renal involvement^{2,3}. Meanwhile, long-term follow-up studies surprisingly show that patient prognoses may be independent of acute clinical and histopathological findings^{4,5}. Additionally, findings related to renal involvement have been observed to recur after a while, following complete recovery⁶. Therefore, predicting the potential complications and specifying the follow-up time may be difficult.

This retrospective study aimed to investigate the relationship of laboratory, clinical, and histopathological findings with the long-term prognosis in children who were diagnosed with HSP nephritis.

MATERIALS and METHODS

This retrospective study included patients who were presented to Istanbul Medeniyet University, Division of Pediatric Nephrology between January 2010 and January 2019 and were diagnosed with HSP nephritis. HSP diagnosis was made using the criteria specified in Ankara 2008 Consensus Conference Report⁷. Renal involvement was defined as the presence of one of the following findings: hematuria, proteinuria, renal function disruption, and hypertension development in the acute phase. The patients' clinical and laboratory findings in the acute phase and during the follow-up period were recorded from patient files with the demographic data.

Red blood cell of >5 per microscopic field at 40×10 magnification in centrifuged urine was considered hematuria. Quantitative evaluation (spot protein/creatinine and 24-h urine protein) was made in all patients who were found to have proteinuria using a dipstick test. Hypertension was defined as a systolic and diastolic blood pressure measured by an aneroid type sphygmomanometer above the 95th percentile when compared with the reference values specified by age, sex, and height.

Serum creatinine and albumin levels were specified by the photometric method. The Schwartz formula was used to calculate the glomerular filtration rate (GFR)⁸.

According to the clinical and laboratory findings at the presentation, the patients were divided into five grades⁹.

Grade I was defined as isolated hematuria (macroscopic or microscopic), grade II as hematuria and non-nephrotic-range proteinuria (4-40 mg/m²/h), grade III as a nephritic syndrome (hematuria, reduced GFR, oliguria, hypertension, and edema), grade IV as a nephrotic syndrome (>40 mg/m²/h proteinuria, hypoalbuminemia, hyperlipidemia, and edema), and grade V as nephritic/nephrotic syndrome. According to this grading, grades I and II were classified as mild groups and grades III, IV, and V were classified as severe groups. Renal biopsy was performed in the severe group of patients in the acute phase and all patients with persistent (>20 mg/m²/h for 4 weeks) or nephrotic-range proteinuria. Light and immunofluorescence examination was performed on all renal biopsy specimens. Histopathological properties were graded according to the International Study of Kidney Disease in Children (ISKDC) classification¹⁰.

The patients' long-term treatment plans were constituted with treatment methods that are specified according to acute clinical findings and biopsy findings if present. Results in this period were graded following the Meadow chronic classification. Accordingly, the grades were defined as follows: grade A: normal GFR, blood pressure, and physical examination and no pathological finding in urine; grade B: minor urine findings, normal physical examination (proteinuria of <20 mg/m²/h ± hematuria); grade C: active renal disease (hypertension, proteinuria >20 mg/m²/h and reduced GFR); grade D: chronic renal disease (GFR of <60 mL/min/1.73 m²).

Ethical approval was obtained from the Istanbul Medeniyet University Goztepe Training and Research Hospital Clinical Research Ethics Committee (decision no: 2020/0105, date: 19.02.2020).

Statistical Analysis

Statistical Package for Social Sciences program (SPSS) for Windows version 17.0 (SPSS Inc.; Chicago, IL, USA) software program was used to evaluate the research data. The normal distribution of continuous variables was evaluated with the Shapiro-Wilk normality test. Normally distributed variables were defined as mean ± standard deviation, and categorical data were defined by number and percentage (%). The chi-square test was used to evaluate categorical variables. A p-value of <0.05 was considered statistically significant.

RESULTS

This study included 90 patients, of whom 59 were males (65.6%). The male/female ratio was 1.9, and the mean age at the time of diagnosis was 8.8±3.2 years. Renal findings were present in 22% of the patients at the

time of presentation, while they occurred in all patients after a mean period of 3.3±27 (0-15) weeks. The patients' demographic data are summarized in Table 1.

The evaluation of renal involvement findings in the acute phase using the Meadow acute phase classification revealed that 46 (51.1%), 26 (28.9%) (all had proteinuria of >20 mg/m²/day), 4 (4.4%), 9 (10.0%), and 5 (5.6%) patients were in grades I, II, III, IV, and V, respectively. Additionally, 72 (80%) patients were in the mild group and 18 (20%) in the severe group (Table 2). The comparison of mild and severe groups in terms of nonrenal findings revealed that joint findings were statistically significantly higher rate in the severe group (72%) compared to the mild group (43%) (p=0.027). A significant difference was not found between the two groups in terms of gastrointestinal findings (p=0.596).

A kidney biopsy was performed in the acute phase in 33 patients (21 males and 12 females). A biopsy was performed in 15 (58%) of 26 patients who had a proteinuria level above >20 mg/m²/day in Meadow

grade 2 because their proteinuria persisted and increased to nephrotic-range levels, whereas in all 18 patients in the severe group (Table 2).

The groups' numerical distributions by the ISKDC classification from the histopathological finding evaluation of patients who underwent biopsy are shown in Figure 1. The most common histopathological grade detected by renal biopsy was ISKDC 3B. Of the 33 patients who underwent biopsy, 14 (42%) patients had grade 3B findings. According to the acute phase Meadow findings, grade 3B findings were found in only 4 (25%) patients in the mild group, while pathological findings of grade 3 and above were found in 12 (75%) patients in the severe group. The histopathological grades of the patients who had severe clinical findings according to the Meadow classification in the acute phase were statistically significantly more severe compared to the mild group (p=0.022).

The examination of the specific therapy distribution applied in the acute phase revealed that immunosuppressive treatment was given to 32 (58%)

Table 1. Demographic data and system involvements of patients who were diagnosed with Henoch-Schönlein purpura.	
Demographics and system involvements	n=90
Age at the time of diagnosis, years	8.8±3.2 (2.6-16)
Observation of renal findings, weeks	3.3±2.7 (0-15)
Male/female, n/n (%/%)	59/31 (66/34)
Time of presentation	
Summer, n (%)	14 (16)
Fall, n (%)	29 (32)
Winter, n (%)	26 (29)
Spring, n (%)	21 (23)
System involvements in the acute phase	
Skin lesions, n (%)	90 (100)
Renal involvement, n (%)	90 (100)
Joint involvement, n (%)	44 (49)
Gastrointestinal involvement, n (%)	40 (44)

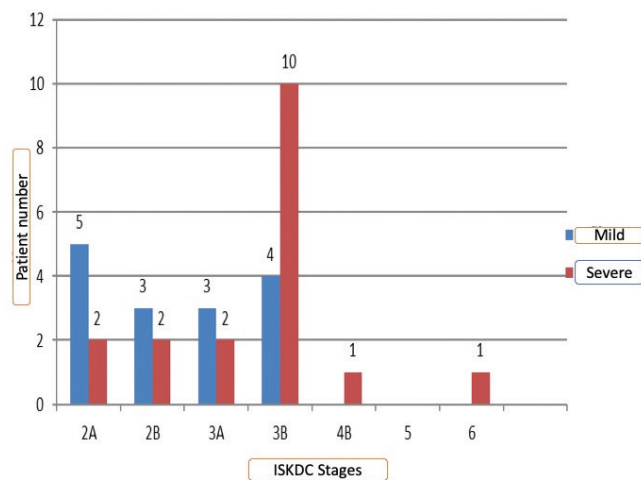


Figure 1. Histopathologic classification according to the International Study of Kidney Disease in Children.

ISKDC: International Study of Kidney Disease in Children

Table 2. Meadow's score for initial presentation.				
Stage	Kidney involvement	Patient n (%)	Kidney biopsy n (%)	Kidney biopsy n (%)
1	Microscopic/macrosopic hematuria	46 (51.1)	0	15/72 (21)
2	Proteinuria of <20 mg/m ² /h ± hematuria	26 (28.9)	15	
3	Nephritic syndrome	4 (4.4)	4	18/18 (100)
4	Nephrotic syndrome	9 (10)	9	
5	Nephritic/nephrotic syndrome	5 (5.6)	5	

patients in the mild group, whereas in all 18 patients (100%) in the severe group. Angiotensin-converting enzyme inhibitor or angiotensin receptor blocker (ACEI/ARB) therapy was also simultaneously initiated in all patients with proteinuria. Treatment distribution in the mild and severe groups is shown in Table 3. A statistically significant difference was found between the mild and severe groups in terms of the presence of treatment needs and applied schedules ($p < 0.001$ for both).

All patients were followed up for 58.6 ± 35.8 months following the acute disease process. Patients were divided into four groups according to the chronic phase Meadow grading to specify renal sequelae findings. Accordingly, 86 (95.6%) patients were classified as group A and 4 (4.4%) as group B (Table 4). We did not have any patients who had compatible findings with groups C and D in the chronic phase. Two of our patients who had grade 4B and 6 findings indicating severe histopathological involvement continue to have non-nephrotic-range proteinuria. Our other two patients were surprisingly considered grade 3A and 2B in the acute phase (Table 5). Reduced proteinuria occurred following steroid treatment; however, non-nephrotic-range proteinuria continued long-term. Additionally, all patients had severe findings in the acute phase; therefore, received cyclophosphamide treatment and achieved remission in the long-term.

DISCUSSION

This study evaluated the clinical findings, proteinuria levels, and long-term results of patients with renal involvement of HSP vasculitis. Renal involvement is present in 18%-81% of the cases in children with HSP and is mostly accompanied by hematuria and mild proteinuria, limiting itself^{1,7}. The treatment plan and long-term follow-up depend on the clinical and histopathological findings at the presentation. Majority of our patients were presented with microscopic hematuria and non-nephrotic-range proteinuria similar to other series in the literature.

Renal biopsy was performed in 33 patients with HSP who had persistent proteinuria and who were in the severe group according to the Meadow classification. Additionally, ISKDC stage 3B was the most common histopathological grade. The histopathological grades of patients with severe clinical findings in the acute phase were higher compared to those in the mild group. However, the presenting symptoms were not always compatible with staging in some patients. For example, crescents were surprisingly observed with up to 40% rate in kidney biopsy samples in some patients in the mild group with increased proteinuria. Only mesangial proliferation was observed in some patients with more severe clinical

Table 3. Comparisons of treatments according to initial clinical presentation severity.

		Mild n %	Severe n %	p-value
Treatment	Yes	32 (44.4)	18 (100)	<0.001
	No	40 (55.6)	0 (0.0)	
Immunosuppressive treatment	Oral steroids	24 (75.0)	5 (27.8)	<0.001
	IV + oral steroids	4 (12.5)	4 (22.2)	
	IV + oral steroids + cyclophosphamide	4 (12.5)	7 (38.9)	
	IV + oral steroids + cyclophosphamide + azathioprine	0 (0.0)	2 (11.1)	

Chi-square test, IV: Intravenous

Table 4. Clinical outcome according to Meadow's score.

Stage	Meadow classification	Patient n (%)
A	Normal (no clinical or laboratory abnormality)	86 (95.6)
B	Minor urinary abnormalities (proteinuria of $<20 \text{ mg/m}^2/\text{h} \pm$ hematuria)	4 (4.4)
C	Active kidney disease (proteinuria of $>20 \text{ mg/m}^2/\text{h}$, hypertension or elevated plasma creatinine with eGFR of $>60 \text{ mL/min/1.73 m}^2$)	-
D	Abnormal kidney function (eGFR of $<60 \text{ mL/min/1.73 m}^2$)	-

eGFR: Estimated glomerular filtration rate

Table 5. The clinical and pathological findings of children who had persistent proteinuria and classified as Meadow stage B.

	1 st patient	2 nd patient	3 rd patient	4 th patient
Sex	Male	Male	Female	Female
Age at onset, y	7.5	4.5	7.7	11
Meadow at initial presentation	5	6	3	3
ISKDC stages	4B	6	2B	3A
Disease course	Rapidly progressive GN	Rapidly progressive GN	Persistent proteinuria	Persistent proteinuria
Treatment protocols	IV + oral steroid + CFM + AZA	IV + oral steroids + CFM + AZA + plasmapheresis	IV + oral steroid	IV + oral steroid
eGFR (mL/min/1.72 m ²)	143	101	111	140
eGFR: Estimated glomerular filtration rate, IV: Intravenous, CFM: Cyclophosphamide, AZA: Azathioprine, GN: Glomerulonephritis, ISKDC: International Study of Kidney Disease in Children				

findings, while more severe findings were observed in a portion of the patients in the mild group, indicating that HSP nephritis might have a heterogeneous structure. Renal biopsy showed ISKDC stage 2B and grade 3A in two of our patients with persistent proteinuria. A correlation may not be necessary between presentation symptoms and histopathological and follow-up findings in patients with HSP nephritis¹¹⁻¹³. Edström Halling et al.¹² found that active disease findings continued long term in 18% of the patients with mild symptoms at presentation, while Tudorache et al.¹³ showed that proteinuria might persist long-term in patients with mild histological findings. Additionally, some of the patients with mild findings who achieved remission in the acute stage might become proteinuric in the long-term^{14,15}. Therefore, patients with hematuria and mild proteinuria should be followed up for a long period, and biopsy should be considered if proteinuria increases or persists.

Some studies emphasized that long-term findings might be related to clinical findings at presentation rather than to biopsy findings^{16,17}. Wakaki et al.¹⁷ found that clinical prognosis in the long-term was related to the period of nephrotic-range proteinuria rather than to pathological findings. Ronkainen et al.¹⁸ argued that some patients with nephrotic-range proteinuria and low-grade pathological findings might paradoxically show poorer prognosis in the follow-up and therefore, the decision of immunosuppressive treatment should be made depending on nephrotic-range proteinuria rather than biopsy findings. High remission rates were obtained in patients with nephrosis in studies that used early and combined immunosuppressive therapies¹⁹. We demonstrated that severe clinical findings in the

initial presentation were related to more intensive immunosuppressive treatment. Our series frequently used cyclophosphamide with IV methylprednisolone and oral steroid therapy in patients with crescents, and these patients still have a good prognosis in the acute stage. Our treatment protocol is rather aggressive compared with the schedule recommended by Kidney Disease: Improving Global Outcomes (KDIGO)²⁰. Severe glomerular inflammation in the acute phase can be improved with early and intensive treatment, while treatment inadequacy and delay in milder cases may lead to persistently active glomerular lesions and result in fibrotic changes²¹. In such patients, functional results of structural loss arising from inadequate immunosuppressive treatment are initially compensated with hyperfiltration, while findings may become prominent in time when this process falls short. Therefore, using only ACEI/ARB treatment in patients with significant proteinuria in the acute phase as recommended by KDIGO may lead to risky and irreversible outcomes²¹.

Another explanation of the heterogeneous course in patients with similar histopathological appearance may be because ISKDC grading evaluates only glomerular changes and neglects tubulointerstitial and vascular changes²². Additionally, severe proteinuria leads to severe toxicity in the interstitial area.

The most important study limitation is that a limited number of patients were included. More patients with similar clinical and histological findings could yield more objective and comparable results. Additionally, the interpretations proposed could be transformed into more objective data if we could reexamine the

patients' histopathological appearances in terms of tubulointerstitial and vascular changes.

CONCLUSIONS

Patients with mild clinical and histological findings should also be followed-up long term in renal disease. Severe clinical findings in the initial presentation were related to more intensive immunosuppressive treatment and higher renal histopathological stages. Randomized controlled studies, including large patient series and using detailed histopathological methods should be conducted to establish treatment and follow-up protocols.

Ethics

Ethics Committee Approval: Ethical approval was obtained from the Istanbul Medeniyet University Goztepe Training and Research Hospital Clinical Research Ethics Committee (decision no: 2020/0105, date: 19.02.2020).

Informed Consent: Retrospective study.

Peer-review: Externally and internally peer-reviewed.

Author Contributions

Surgical and Medical Practices: C.A., N.G., E.K., D.U., C.C., Concept: C.A., N.G., E.K., D.U., C.C., Design: C.A., N.G., E.K., D.U., C.C., Data Collection and/or Processing: C.A., N.G., E.K., D.U., C.C., Analysis and/or Interpretation: C.A., N.G., E.K., D.U., C.C., Literature Search: C.A., N.G., E.K., D.U., C.C., Writing: C.A., N.G., E.K., D.U., C.C.

Conflict of Interest: The authors have no conflict of interest to declare.

Financial Disclosure: The authors declared that this study has received no financial support.

REFERENCES

- Batu ED, Ozen S. Pediatric vasculitis. *Curr Rheumatol Rep.* 2012;14:121-9.
- Narchi H. Risk of long term renal impairment and duration of follow up recommended for Henoch-Schonlein purpura with normal or minimal urinary findings: a systematic review. *Arch Dis Child.* 2005;90:916-20.
- Davin JC. Henoch-Schonlein purpura nephritis: pathophysiology, treatment, and future strategy. *Clin J Am Soc Nephrol.* 2011;6: 679-89.
- Butani L, Morgenstern BZ. Long-term outcome in children after Henoch-Schonlein purpura nephritis. *Clin Pediatr (Phila).* 2007;46:505-11.
- Ronkainen J, Nuutinen M, Koskimies O. The adult kidney 24 years after childhood Henoch-Schönlein purpura: a retrospective cohort study. *Lancet.* 2002;360:666-70.
- Goldstein AR, White RH, Akuse R, Chantler C. Long-term follow-up of childhood Henoch-Schönlein nephritis. *Lancet.* 1992;339:280-2.
- Ozen S, Pistorio A, Iusan SM, et al. EULAR/PRINTO/PRES criteria for Henoch-Schönlein purpura, childhood Polyarteritis nodosa, childhood Wegener granulomatosis and childhood Takayasu arteritis: Ankara 2008. Part II: Final classification criteria. *Ann Rheum Dis.* 2010;69: 798-806.
- Schwartz GJ, Brion LP, Spitzer A. The use of plasma creatinine concentration for estimating glomerular filtration rate in infants, children, and adolescents. *Pediatr Clin North Am.* 1987;34: 571-90.
- Meadow SR, Glasgow EF, White RH, Moncrieff MW, Cameron JS, Ogg CS. Schönlein- Henoch nephritis. *Q J Med.* 1972;41:241-58.
- Haas M. IgA nephropathy and Henoch-Schönlein Purpura nephritis. In: Jennette JC, Olson JC, Schwartz MM, Silva FG, editors. *Heptinstall's Pathology of the Kidney.* Philadelphia: Lippincott, Williams & Wilkins; 2007. p. 423-86.
- Soylemezoglu O, Ozkaya O, Ozen S, et al. Henoch-Schönlein nephritis: a nationwide study. *Nephron Clin Pract.* 2009;112:c199-c204.
- Edström Halling S, Söderberg MP, Berg UB. Predictors of outcome in Henoch-Schönlein nephritis. *Pediatr Nephrol.* 2010;25:1101-8.
- Tudorache E, Azema C, Hogan J, et al. Even mild cases of paediatric Henoch-Schönlein purpura nephritis show significant long-term proteinuria. *Acta Paediatr.* 2015;104:843-8.
- Kurt-Şükür ED, Sekar T, Tullus K. Biopsy-proven Henoch-Schönlein purpura nephritis: a single center experience. *Pediatr Nephrol.* 2021;36:1207-15.
- Delbet JD, Hogan J, Aoun B, et al. Clinical outcomes in children with Henoch-Schönlein purpura nephritis without crescents. *Pediatr Nephrol.* 2017;32:1193-9.
- Mir S, Yavascan O, Mutlubas F, Yeniay B, Sonmez F. Clinical outcome in children with Henoch-Schönlein nephritis. *Pediatr Nephrol.* 2007;22:64-70.
- Wakaki H, Ishikura K, Hataya H, et al. Henoch-Schönlein purpura nephritis with nephrotic state in children: predictors of poor outcomes. *Pediatr Nephrol.* 2011;26:921-5.
- Ronkainen J, Ala-Houhala M, Huttunen NP, et al. Outcome of Henoch-Schoenlein nephritis with nephrotic-range proteinuria. *Clin Nephrol.* 2003;60:80-4.
- Feng D, Huang WY, Hao S, et al. A single-center analysis of Henoch-Schonlein purpura nephritis with nephrotic proteinuria in children. *Pediatr Rheumatol Online J.* 2017;15:15.
- Chapter 11: Henoch-Schönlein purpura nephritis. *Kidney Int Suppl* (2011). 2012;2:218-20.
- Davin JC, Coppo R. Henoch-Schönlein purpura nephritis in children. *Nat Rev Nephrol.* 2014;10:563-73.
- Lim BJ, Shin JI, Choi SE, et al. The significance of tubulointerstitial lesions in childhood Henoch-Schönlein nephritis. *Pediatr Nephrol.* 2016;31:2087-93.