

Familial dysalbuminemic hyperthyroxinemia confounding management of coexistent autoimmune thyroid disease

Serena Khoo¹, Greta Lyons¹, Andrew Solomon², Susan Oddy³, David Halsall³,
Krishna Chatterjee¹ and Carla Moran¹

¹Wellcome-MRC Institute of Metabolic Science, University of Cambridge, Cambridge, UK, ²Department of Medicine and Endocrinology, Lister Hospital, Stevenage, UK, and ³Department of Clinical Biochemistry, Addenbrooke's Hospital, Cambridge, UK

Correspondence
should be addressed
to C Moran
Email
cm682@medschl.cam.ac.uk

Summary

Familial dysalbuminemic hyperthyroxinemia (FDH) is a cause of discordant thyroid function tests (TFTs), due to interference in free T4 assays, caused by the mutant albumin. The coexistence of thyroid disease and FDH can further complicate diagnosis and potentially result in inappropriate management. We describe a case of both Hashimoto's thyroiditis and Graves' disease occurring on a background of FDH. A 42-year-old lady with longstanding autoimmune hypothyroidism was treated with thyroxine but in varying dosage, because TFTs, showing high Free T4 (FT4) and normal TSH levels, were discordant. Discontinuation of thyroxine led to marked TSH rise but with normal FT4 levels. She then developed Graves' disease and thyroid ophthalmopathy, with markedly elevated FT4 (62.7 pmol/L), suppressed TSH (<0.03 mU/L) and positive anti-TSH receptor antibody levels. However, propylthiouracil treatment even in low dosage (100 mg daily) resulted in profound hypothyroidism (TSH: 138 mU/L; FT4: 4.8 pmol/L), prompting its discontinuation and recommencement of thyroxine. The presence of discordant thyroid hormone measurements from two different methods suggested analytical interference. Elevated circulating total T4 (TT4), (227 nmol/L; NR: 69–141) but normal thyroxine binding globulin (TBG) (19.2 µg/mL; NR: 14.0–31.0) levels, together with increased binding of patient's serum to radiolabelled T4, suggested FDH, and *ALB* sequencing confirmed a causal albumin variant (R218H). This case highlights difficulty ascertaining true thyroid status in patients with autoimmune thyroid disease and coexisting FDH. Early recognition of FDH as a cause for discordant TFTs may improve patient management.

Learning points:

- The typical biochemical features of familial dysalbuminemic hyperthyroxinemia (FDH) are (genuinely) raised total and (spuriously) raised free T4 concentrations due to enhanced binding of the mutant albumin to thyroid hormones, with normal TBG and TSH concentrations.
- Given the high prevalence of autoimmune thyroid disease, it is not surprising that assay interference from coexisting FDH may lead to discordant thyroid function tests confounding diagnosis and resulting in inappropriate therapy.
- Discrepant thyroid hormone measurements using two different immunoassay methods should alert to the possibility of laboratory analytical interference. The diagnosis of FDH is suspected if there is a similar abnormal familial pattern of TFTs and increased binding of radiolabelled 125I-T4 to the patient's serum, and can be confirmed by *ALB* gene sequencing.
- When autoimmune thyroid disease coexists with FDH, TSH levels are the most reliable biochemical marker of thyroid status. Measurement of FT4 using equilibrium dialysis or ultrafiltration are more reliable but less readily available.

Background

Familial dysalbuminemic hyperthyroxinemia (FDH) is a dominantly-inherited condition, which results in enhanced affinity of the mutant albumin for thyroid hormone. It was first described by Hennemann (1) and Lee (2) in 1979, and the first causal *ALB* mutation (an arginine to histidine substitution at codon 218, R218H) was discovered in 1994 (3). Since then, 67 cases from 24 families have been reported (4). This *ALB* variant is reported to be present in 1 in 1000 Caucasians but is even more common in Hispanic individuals (4).

FDH causes an increase in circulating total T4 and total T3 concentrations because of a 10-fold and 5-fold greater affinity of mutant albumin for binding to T4 and T3 respectively (3, 5). Despite elevated iodothyronines, production, cellular uptake and action of thyroid hormones are all normal, resulting in normal TSH levels and supporting the notion that affected individuals are completely euthyroid (4). Importantly, when free thyroid hormones are measured by many current immunoassay methods, spuriously high FT4 and FT3 concentrations are recorded (6). In contrast, measurements of free thyroid hormones by 'gold standard' methods such as ultrafiltration and equilibrium or symmetric dialysis are usually normal (6).

In population studies, the incidence of hypothyroidism and hyperthyroidism is common (7). Accordingly, it is not surprising that primary thyroid dysfunction and FDH can coexist. Very few cases of thyroid disease with coexistent FDH have previously been reported: three members of an FDH family developed different thyroid disorders (non-toxic goitre requiring thyroidectomy, Graves' disease and Hashimoto's thyroiditis) (8), FDH with multinodular goitre; and FDH with postpartum thyroiditis (9). Here we describe a complex case of Hashimoto's thyroiditis evolving to Graves' disease with discordant thyroid function, eventually resulting in diagnosis of coexistent FDH, highlighting challenges in diagnosis and management.

Case presentation

A 42-year-old lady presented with tiredness, weight gain and fatigue prompting a diagnosis of hypothyroidism (TFTs at diagnosis unknown), necessitating thyroxine treatment. She has an aunt with Hashimoto's thyroiditis and is a smoker.

Over the subsequent decade, due to discordant TFTs, dosage of thyroxine replacement required frequent

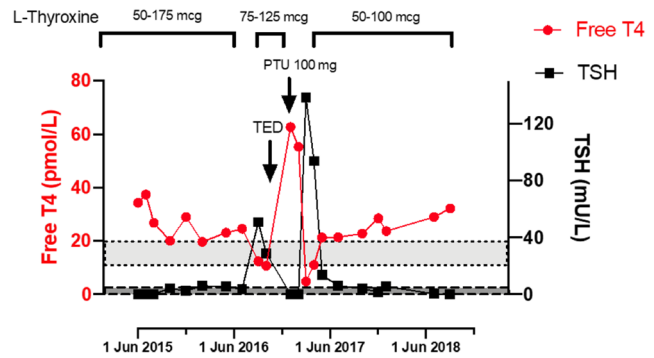


Figure 1

Fluctuating FT4 and TSH levels in the patient, with thyroxine and propylthiouracil (PTU) treatment indicated. Reference ranges for FT4 (shaded light grey) and TSH (shaded dark grey) are marked. TED: Thyroid eye disease.

adjustment (ranging from 25 µg to 175 µg daily), resulting in persistent symptoms (fatigue, low mood and fluctuating weight). Serial, discordant TFTs measured using a one-step immunoassay method (Siemens: ADVIA Centaur XP) are shown in Fig. 1. In June 2016, while taking 75 µg thyroxine daily, elevated FT4 24.6 pmol/L (RR: 10.0–19.8) with non-suppressed TSH levels 3.61 mU/L (RR: 0.35–5.5) were recorded. Discontinuation of thyroxine resulted in markedly raised TSH (50.63 mU/L) but normal FT4 (12.4 pmol/L) levels. Thyroxine therapy was recommenced due to clinical symptoms of hypothyroidism.

In October 2016, she developed excessive lacrimation, exposure symptoms and asymmetric proptosis (Fig. 2A), together with thyrotoxic symptoms (restlessness, insomnia and muscle weakness), suggestive of Graves' disease (GD) with Graves' ophthalmopathy (GO). On 125 µg thyroxine replacement, elevated FT4 (62.7 pmol/L), suppressed TSH (<0.03 mU/L), positive thyroid autoantibody levels (anti-TSH receptor antibody, 4.8 IU/L (RR 0.0–1.0) and anti-thyroid peroxidase antibody 690 IU/mL (RR 0–60)) were documented. Discontinuation of thyroxine and treatment with propylthiouracil (100 mg daily) resulted in markedly elevated TSH (138 mU/L) and low FT4 (4.8 pmol/L) levels (Fig. 1). Antithyroid drug treatment was stopped and thyroxine therapy was restarted.

Investigation

Ultrasound of the thyroid revealed a small gland with heterogeneous background echotexture (Fig. 2B).

Thyroid hormone levels in the patient, measured simultaneously using two different immunoassay methods (Siemens ADVIA Centaur XP; Perkin Elmer DELFIA), both recorded high but with widely

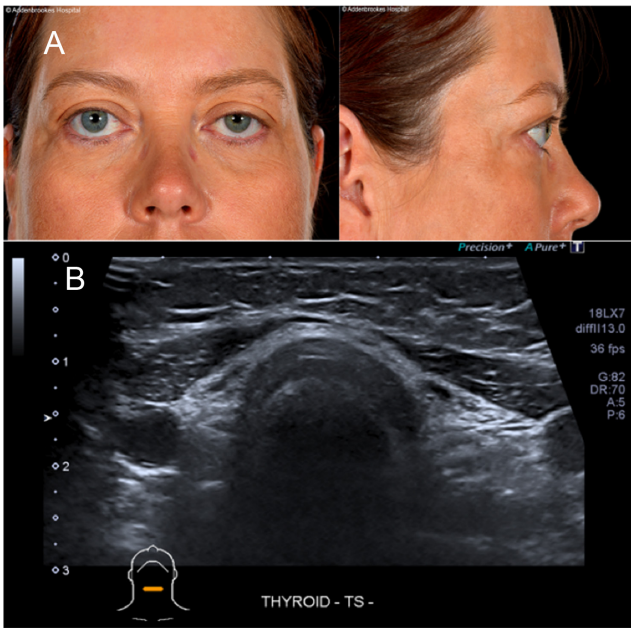


Figure 2
(A) Clinical photograph showing features of Graves' ophthalmopathy including mild asymmetric exophthalmos and bilateral lower eyelid retraction. (B) Transverse ultrasound scan image in our patient, showing a small thyroid gland consistent with longstanding thyroxine therapy and heterogeneous background echotexture.

divergent FT4 results raising the possibility of assay interference (Fig. 3A).

However, expected results following serial dilution and polyethylene glycol (PEG) precipitation of the patient's serum suggested that anti-T4 or anti-TSH antibody interference was unlikely.

Raised TT4 (227 nmol/L; RR 69–141) but with normal TBG levels (19.2 µg/mL; RR14.0–31.0) raised the possibility of an alternative thyroid hormone binding protein abnormality.

Markedly increased binding of radiolabelled T4 (¹²⁵I-T4) to patient's serum, comparable to that from a known, genetically-proven FDH case, suggested that T4 binding to albumin is enhanced (Fig. 3B). Sequencing of the *ALB* gene showed heterozygosity for a recognized mutation (R218H) in the patient and screening of first-degree relatives showed concordance of R218H FDH genotype with the hyperthyroxinaemia phenotype (Fig. 4).

Treatment and outcome

Following diagnosis of FDH, the patient's thyroxine therapy was adjusted based on TSH results alone, with resultant clinical euthyroidism (TSH 2.7 mU/L, FT4 23 pmol/L on thyroxine 87.5 µg daily).

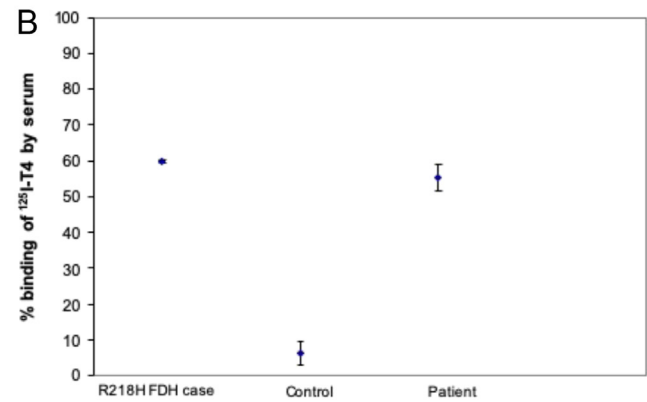
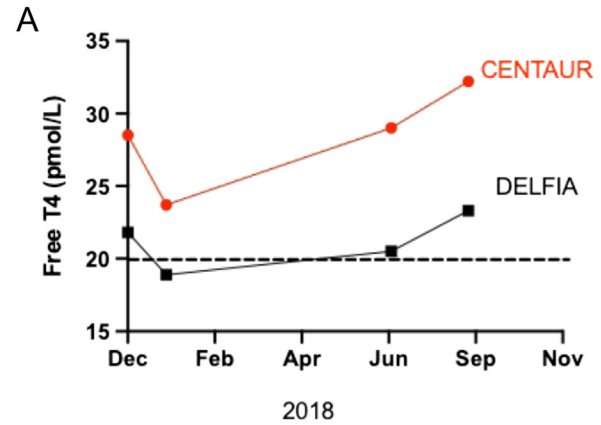


Figure 3
(A) Free T4 measurements using two different assay methods (Siemens Centaur; Perkin-Elmer Delfia). The dotted line shows the upper limit of the normal reference range for both assays. (B) Results of radiolabelled T4 binding studies from a genetically-proven R218H FDH case, control subject with known normal albumin and our patient (Proband). Mean and s.d. of duplicate binding assays is shown.

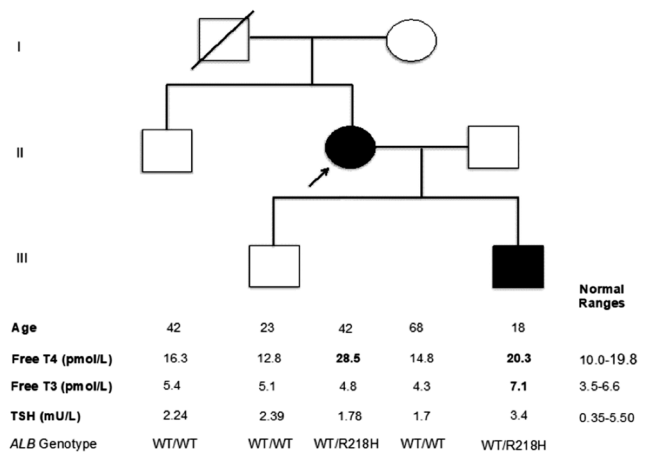


Figure 4
Family pedigree showing genotype of individuals (Open symbols: Wild type *ALB* sequence; Filled black symbols R218H mutant *ALB*), with corresponding thyroid biochemical phenotype below. The Proband (index patient) is arrowed. WT denotes Wildtype.



Discussion

We have described a case of longstanding Hashimoto's thyroiditis, transitioning to Graves' disease and Graves' ophthalmopathy, with discordant thyroid function tests due to assay interference from coexistent FDH.

Hashimoto's thyroiditis (HT), characterized by destructive lymphocytic infiltration of the thyroid gland, typically results in irreversible hypothyroidism. When our patient transitioned to clinical and biochemical hyperthyroidism, additional features (concurrent ophthalmopathy, positive anti-TSH receptor antibody levels) suggested that this was due to development of Graves' disease rather than excessive thyroxine replacement. Occurrence of Graves' disease following Hashimoto's thyroiditis is uncommon and suggests either stimulation of residual function of her thyroid gland by TRAB, despite destruction by the previous autoimmune process, or that a change from blocking to stimulating anti-TSH receptor antibody activity has mediated transition from hypo- to hyperthyroidism.

Throughout its course, management of this patient's thyroid dysfunction was confounded by discordant thyroid function tests. Clinical history excluded recognised causes of hyperthyroxinaemia (e.g. amiodarone, heparin and psychiatric illness). Discrepant thyroid hormone measurements using two different assay methods suggested analytical interference. Heterophile or endogenous antibody-mediated assay interference were excluded. Elevated TT4 but normal TBG levels excluded TBG excess. Knowing that two-step FT4 immunoassays remain susceptible to interference from dysalbuminaemia, we proceeded to radiolabelled T4 binding studies of patient's serum and ALB sequencing to identify the R218H FDH albumin variant.

In isolation, biochemical features of FDH comprise elevated serum TT4 levels, FT4 and (in some assays) FT3 measurements but with normal TSH levels. Thus, when FDH and thyrotoxicosis coexist, FT4 levels are exaggeratedly high with undetectable/low TSH concentrations. On the other hand, FDH and coexistent hypothyroidism can manifest with normal or even slightly raised FT4 measurements with disproportionately high TSH levels. Thyroxine treatment normalises TSH levels but can result in a dramatic elevation in FT4 measurements. Therefore, TSH levels are the most reliable biochemical marker of thyroid status. Measurement of FT4 using equilibrium dialysis or ultrafiltration are more reliable but less readily available. Equilibrium dialysis methods have also been shown to be dependent on buffer composition (10).

Failure to recognise FDH as a cause for assay interference has led to many patients being treated inappropriately with antithyroid drugs, surgery and radioactive iodine therapy. In our patient, the delay in diagnosis of FDH led to inappropriate adjustments in thyroxine dosage associated with incorrect clinical thyroid status and later unnecessary withdrawal of thyroxine therapy. Identification of FDH in the patient enabled physicians to ignore falsely elevated FT4 results and confidently use TSH alone to guide management.

Declaration of interest

The authors declare that there is no conflict of interest that could be perceived as prejudicing the impartiality of the research reported.

Funding

This work was supported by the NIHR Cambridge Biomedical Research Centre (K C and C M).

Patient consent

The authors confirm that written informed consent has been obtained from the patient for publication of the submitted article. Consent to publish the case history and photographs were obtained from the patient described in our report.

Author contribution statement

C M designed the report. S K, G L, A S, S O and D H collected and analysed clinical and laboratory data. S K drafted the manuscript which was revised by D H, K C and C M.

References

- 1 Hennemann G, Docter R, Krenning EP, Bos G, Otten M & Visser TJ. Raised total thyroxine and free thyroxine index but normal free thyroxine. A serum abnormality due to inherited increased affinity of iodothyronines for serum binding protein. *Lancet* 1979 **1** 639–642. ([https://doi.org/10.1016/s0140-6736\(79\)91080-8](https://doi.org/10.1016/s0140-6736(79)91080-8))
- 2 Lee WN, Golden MP, Van Herle AJ, Lippe BM & Kaplan SA. Inherited abnormal thyroid hormone-binding protein causing selective increase of total serum thyroxine. *Journal of Clinical Endocrinology and Metabolism* 1979 **49** 292–299. (<https://doi.org/10.1210/jcem-49-2-292>)
- 3 Sunthornthepvarakul T, Angkeow P, Weiss RE, Hayashi Y & Refetoff S. An identical missense mutation in the albumin gene results in familial dysalbuminemic hyperthyroxinemia in eight unrelated families. *Biochemical and Biophysical Research Communications* 1994 **202** 781–787. (<https://doi.org/10.1006/bbrc.1994.1998>)
- 4 Kragh-Hansen U, Galliano M & Minchiotti L. Clinical, genetic, and protein structural aspects of familial dysalbuminemic hyperthyroxinemia and hypertriiodothyroninemia. *Frontiers in Endocrinology* 2017 **8** 297. (<https://doi.org/10.3389/fendo.2017.00297>)



- 5 Petersen CE, Ha CE, Jameson DM & Bhagavan NV. Mutations in a specific human serum albumin thyroxine binding site define the structural basis of familial dysalbuminemic hyperthyroxinemia. *Journal of Biological Chemistry* 1996 **271** 19110–19117. (<https://doi.org/10.1074/jbc.271.32.19110>)
- 6 Stockigt JR, Stevens V, White EL & Barlow JW. 'Unbound analog' radioimmunoassays for free thyroxine measure the albumin-bound hormone fraction. *Clinical Chemistry* 1983 **29** 1408–1410. (<https://doi.org/10.1093/clinchem/29.7.1408>)
- 7 Vanderpump MPJ. The epidemiology of thyroid disease. *British Medical Bulletin* 2011 **99** 39–51. (<https://doi.org/10.1093/bmb/ldr030>)
- 8 Young RA, Stoffer SS & Braverman LE. Familial dysalbuminemic hyperthyroxinemia associated with primary thyroid disease. *American Journal of Medicine* 1987 **82** 221–223. ([https://doi.org/10.1016/0002-9343\(87\)90059-3](https://doi.org/10.1016/0002-9343(87)90059-3))
- 9 Langsteger W, Semlitsch G, Költringer P, Meister E & Eber O. Postpartum thyroiditis and familial dysalbuminemic hyperthyroxinemia. *Journal of Clinical Endocrinology and Metabolism* 1994 **78** 58–62. (<https://doi.org/10.1210/jcem.78.1.8288714>)
- 10 Rajatanavin R, Young RA & Braverman LE. Effect of chloride on serum thyroxine binding in familial dysalbuminemic hyperthyroxinemia. *Journal of Clinical Endocrinology and Metabolism* 1984 **58** 388–391. (<https://doi.org/10.1210/jcem-58-2-388>)

Received in final form 23 December 2019

Accepted 7 February 2020