

Isolated *Streptococcus agalactiae* tricuspid endocarditis in elderly patient without known predisposing factors: Case report and review of the literature



Leila Abid^{a,*}, Salma Charfeddine^a, Samir Kammoun^a

^a Cardiology Department, University Hédi Chaker Hospital, Sfax

^a Tunisia

Group B streptococcal (GBS) tricuspid infective endocarditis is a very rare clinical entity. It affects intravenous drug users, pregnant, *postpartum* women, and the elderly. We report the case of a 68-year-old patient without known predisposing factors who presented a GBS tricuspid endocarditis treated by penicillin and aminoglycosides with no response. The patient was operated with a good evolution. Our case is the 25th reported in the literature. GBS disease is increasing in the elderly and is mainly associated to comorbid conditions. Tricuspid infective endocarditis with Group B streptococcus predominantly presents as a persistent fever with respiratory symptoms due to pulmonary embolism. Therefore, it requires a medicosurgical treatment and close follow-up.

© 2015 The Authors. Production and hosting by Elsevier B.V. on behalf of King Saud University. This is an open access article under the CC BY-NC-ND license (<http://creativecommons.org/licenses/by-nc-nd/4.0/>).

Keywords: Tricuspid endocarditis, Elderly patient, Group B streptococcus, *Streptococcus agalactiae*, Surgery

Introduction

Right-sided infective endocarditis (RSIE) is a rare clinical entity that occurs predominantly in intravenous drug users and involves mainly the tricuspid valve [1]. Pathogenesis, clinical features, and prognosis of RSIE occurring in nondrug users are not well known [2]. In fact, there are only a few studies on RSIE in nondrug users without human

immunodeficiency virus infection. *Staphylococcus aureus* is the most common microbiological pathogen. Other causes of RSIE include coagulase-negative staphylococci and streptococci [3,4]. Group B *Streptococcus* (*Streptococcus agalactiae*) is a β -hemolytic Gram-positive bacterium [5]. This pathogen is a member of the genitourinary female tract and gastrointestinal normal flora in some humans [5]. *S. agalactiae* is one of the major causes of neonatal bacterial

Disclosure: Authors have nothing to disclose with regard to commercial support.

Received 28 July 2015; revised 24 September 2015; accepted 12 November 2015.

Available online 2 December 2015

* Corresponding author at: Cardiology Department, Hédi Chaker Hospital, Route Elain, Km 0.5, 3029 Sfax, Tunisia.
E-mail address: leilaabid@yahoo.fr (L. Abid).



P.O. Box 2925 Riyadh – 11461KSA
Tel: +966 1 2520088 ext 40151
Fax: +966 1 2520718
Email: sha@sha.org.sa
URL: www.sha.org.sa



1016–7315 © 2015 The Authors. Production and hosting by Elsevier B.V. on behalf of King Saud University. This is an open access article under the CC BY-NC-ND license (<http://creativecommons.org/licenses/by-nc-nd/4.0/>).

Peer review under responsibility of King Saud University.

URL: www.ksu.edu.sa

<http://dx.doi.org/10.1016/j.jsha.2015.11.003>



Production and hosting by Elsevier

septicemia and meningitis [6]. Group B streptococcal disease (GBS), once rare in adults, is actually in perpetual increase, especially in the elderly [7]. However, GBS infective endocarditis remains a rare clinical entity (3% of GBS invasive infections) [7]. It mainly affects the left-sided heart valves and rarely the tricuspid valve [8]. In this paper we report the case of an elderly patient without known comorbidities who presented with tricuspid endocarditis due to *S. agalactiae*. The pathophysiology, clinical features, and therapeutic options are reviewed.

Case report

A 68-year-old man was admitted with prolonged fever, arthralgia, headache, and asthenia of 3 weeks' duration. The patient had no history of cardiovascular disease or illicit drugs abuse. There was no notion of recent hospitalization or intravenous catheter placement. On admission, the patient was pale with dyspnea at rest. On examination, his temperature, blood pressure, pulse, respiratory rate, and oxygen saturation while breathing room air were, respectively: 39.2 °C; 115/70 mmHg; 96 beats/min; 24 breaths/min; and 96%. Auscultation of lung fields was normal. Cardiac auscultation revealed a systolic murmur at the left lower sternal border increasing with inspiration. Physical examination revealed jugular veins distension with a hepatojugular reflux and a mild painful hepatomegaly. The electrocardiogram showed a sinus tachycardia. Chest X-ray revealed a mild cardiomegaly. Laboratory tests revealed leukocytosis of 13.2×10^9 , anemia with hemoglobin of 9.3 g/dL, erythrocyte sedimentation rate of 90 mm/h, and C-reactive protein of 260 mg/L. On transthoracic and transesophageal

echocardiography, there was a large, mobile, and pedunculated vegetation measuring 15 mm \times 10 mm attached to the anterior tricuspid valve with severe regurgitation (Fig. 1) and severe pulmonary hypertension (systolic pulmonary arterial pressure = 55 mmHg). The right ventricle had normal size and function (tricuspid annular plane systolic excursion = 25 mm; S wave = 13 cm/s). The left ventricle and aortic and mitral valves were normal. The diagnosis of right-sided infective endocarditis was made. Treatment with vancomycin and gentamycin was started after several blood culture series and urine analysis. There were no organisms in the urine. *S. agalactiae* was isolated in three blood cultures. Since this bacterium was sensitive to penicillin and aminoglycosides, vancomycin was stopped and changed to penicillin. Abdominal and cerebral CT scans were normal. Human immunodeficiency virus and tumor markers were negative and digestive exploration including colonoscopy was normal. After 2 weeks with appropriate antibiotic treatment, the patient complained of fever and dyspnea. A ventilation-perfusion lung scan showed matched ventilation and perfusion defect at the lingual secondary to septic pulmonary embolism. A control transesophageal echocardiography revealed a further increase in the vegetation of the tricuspid valve and there was no inflammatory resolution: C-reactive protein rate remained 180 mg/L after an initial decrease. Medical treatment was changed again to daily vancomycin, gentamycin, and rifampicin and the patient underwent surgery. Large vegetation was attached to the tricuspid valve (Fig. 2). The surgery had consisted at a resection of the vegetation, tricuspid valve repair and annuloplasty with a Carpentier-Edwards ring No. 28.

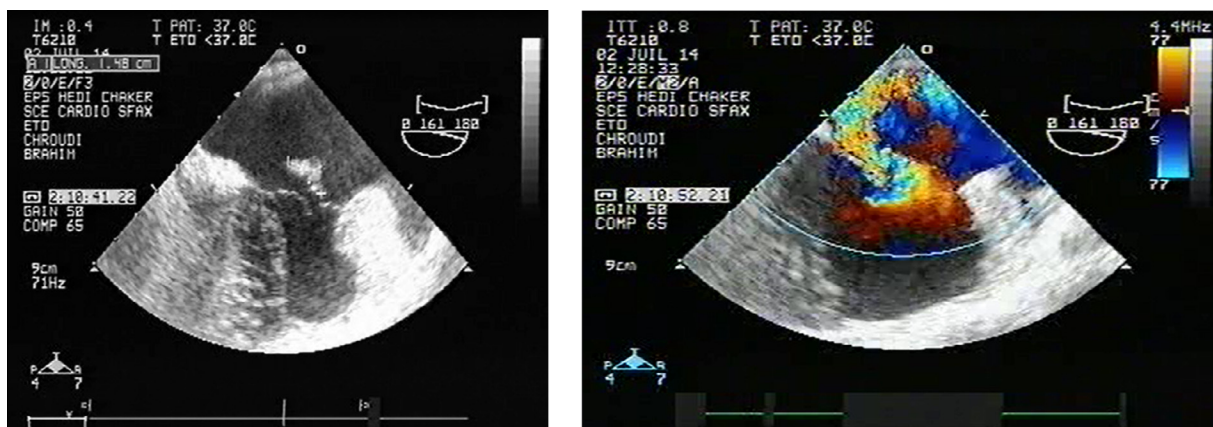


Figure 1. Transesophageal echocardiography revealing a large, mobile and pedunculated vegetation measuring 15 mm \times 10 mm attached to the anterior tricuspid valve with severe regurgitation.

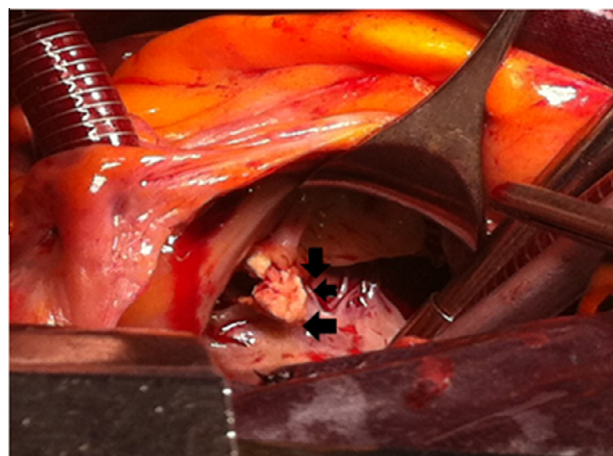


Figure 2. Surgery revealed large vegetation attached to the anterior tricuspid valve.

The postoperative course was uneventful. Control transthoracic echocardiography revealed a mild tricuspid regurgitation without residual vegetation (Fig. 3). Bacteriological analysis of the vegetation revealed the presence of neutrophils and organisms. Antibiotics were continued until 6 weeks, and the patient was discharged after total clinical and biological recovery. The patient was regularly followed-up. Six months later he was doing well with stable vital signs and no dyspnea or fever. The transthoracic echocardiogram at follow-up demonstrated a moderate tricuspid valve regurgitation.

Discussion

RSIE is rarer than left-sided involvement, accounting for around 5–10% of all cases of infec-

tive endocarditis [1]. It occurs predominantly in intravenous drug users and where intravenous devices (e.g., pacemakers, central venous catheters) are used. *S. aureus* is the most common microbiological organism. Other pathogenic bacteria of RSIE are streptococci [3,4].

S. agalactiae is a β -hemolytic Gram-positive bacterium [5]. It colonizes the female genitourinary tract, throat, and rectum of some humans [5]. It was first identified as the major cause of bovine endocarditis [9]. Later, it was described as a human pathogen that principally caused sepsis and meningitis in neonates, and could lead to death or long-term sequelae [6]. The susceptibility of infants and women who are pregnant and after obstetrical intervention to GBS disease depends on the level of capsular-type-specific antibodies in maternal serum [10]. Recently, the incidence of the GBS invasive infections in adults who are not pregnant is increasing [7]. In fact, a two to four-fold increase in the incidence of invasive GBS disease in adults has been reported during the past two decades; most infections are unrelated to pregnancy and occur in adults aged ≥ 65 years [7,11]. The pathogenesis of GBS invasive disease in the elderly is multifactorial and is still poorly understood. It has been established that complement receptors present in neutrophils play a specific role in the susceptibility to the GBS disease. The chronic underlying diseases such as diabetes mellitus, malignancy, cardiac, gastrointestinal diseases, and neurological impairment frequent in elderly adults compromise the mechanisms of host-defense and alter the function of the neutrophils [10]. In addition, the reduced physical capacity, altered integrity of anatomical barriers in the elderly, and intrinsic virulence of *S. agalactiae*

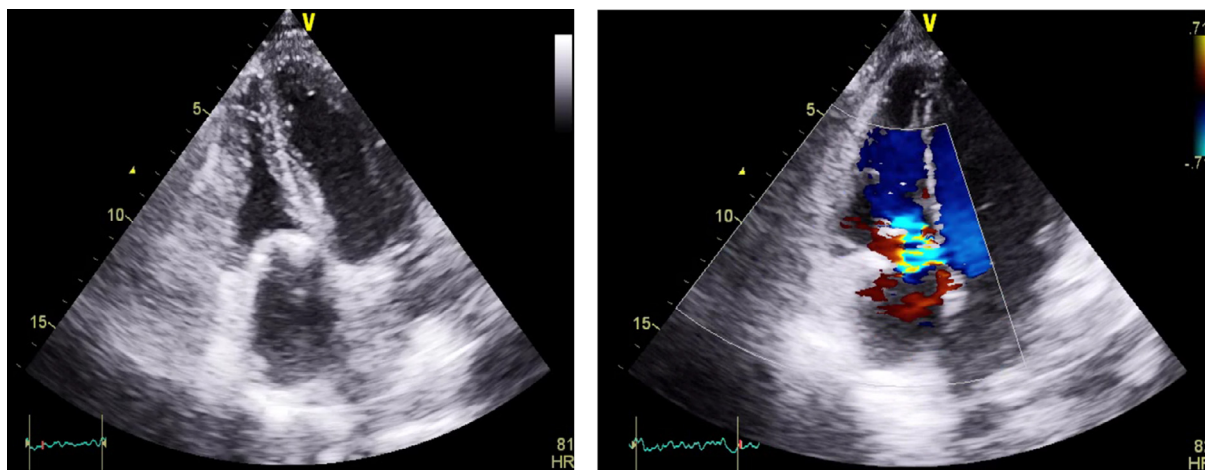


Figure 3. Control transthoracic echocardiography revealed: (A) tricuspid ring without residual vegetation; and (B) persistence of a mild tricuspid regurgitation after annuloplasty.

Table 1. Different cases of group B *Streptococcus tricuspid* infective endocarditis reported in the literature.

Case No./ Refs.	Age (y)	Sex	IV drug abuse	Underlying disease/ circumstance	Clinical presentation	Pulmonary embolism	Antibiotic	Surgery	Evolution
1 [19]	24	F	No	Cesarean	Acute	Yes	Penicillin	Yes	Recovery
2 [20]	19	F	Yes	Abortion	Subacute	Yes	Penicillin + gentamicin	Yes	Recovery
3 [8]	35	M	Yes	None	Acute	Yes	Penicillin	No	Recovery
4 [21]	65	F	No	Alcoholism/ breast cancer	—	—	Penicillin	Yes	Recovery
5 [18]	32	F	Yes	None	Subacute	Yes	Penicillin + gentamicin	No	Recovery
6 [18]	56	M	No	Diabetes	Acute	Yes	Ampicillin	No	Death
7 [18]	54	M	No	Diabetes, alcoholism	Acute	Yes	Penicillin + tobramycin	No	Recovery
8 [22]	22	F	Yes	None	Acute	Yes	Penicillin + gentamicin	No	Death
9 [22]	13	F	No	None	Acute	No	Penicillin	No	Recovery
10 [22]	32	F	Yes	None	Acute	Yes	Penicillin	No	Recovery
11 [23]	24	F	No	Abortion	Acute	Yes	Penicillin + gentamicin	No	Recovery
12 [24]	30	F	No	Abortion	Subacute	Yes	Vancomycin	Yes	Recovery
13 [14]	—	F	—	—	—	—	Yes	—	—
14 [13]	33	F	No	Abortion	Acute	Yes	Penicillin + gentamicin	Yes	Recovery
15 [5]	18	F	No	Abortion	Acute	Yes	Yes	Yes	Recovery
16 [25]	25	M	Yes	None	Acute	No	Penicillin + gentamicin	No	Recovery
17 [25]	22	M	Yes	None	Acute	No	Penicillin	No	Recovery
18 [5]	53	F	No	Alcoholism	Acute	Yes	Penicillin + tobramycin	No	Death
19 [26]	19	F	No	None	Acute	Yes	Yes	No	Death
20 [27]	22	F	No	Abortion	Acute	Yes	Penicillin + gentamicin	No	Recovery
21 [28]	27	F	No	None	Acute	Yes	Penicillin + gentamicin	No	Recovery
22 [15]	—	F	No	Papanicolaou smear	—	—	Yes	Yes	Recovery
23 [16]	36	F	No	Postpartum	Acute	No	Ceftriaxone + gentamicin + metronidazole	No	Death
24 [17]	30	F	No	Postpartum	Acute	Yes	Ceftriaxone + gentamicin + vancomycin	Yes	Recovery
25 ^a	68	M	No	None	Acute	Yes	Vancomycin + rifampicin + gentamicin	Yes	Recovery

Ref = reference.

^a Case reported in this article.

due to specific capsular polysaccharides of the GBS may contribute to the occurrence of GBS invasive infections in the elderly [12]. Despite the recent increase in GBS invasive disease, infective endocarditis remains uncommon (3% of clinical manifestations of invasive GBS infections) [7]. *S. agalactiae*-infective endocarditis is a very aggressive clinical entity characterized by acute onset, large vegetations, and severe valve mutilations and reaches old patients with chronic underlying diseases, mostly rheumatic heart disease [5]. The mitral and aortic valves are the most involved (77% of all cases) [5].

S. agalactiae RSIE is very rare and involves either drug users, pregnant women, and elderly adults [13]. Only 24 cases of GBS infective endocarditis involving the tricuspid valve have been reported in the literature [14–17]; our case is the 25th to be described (Table 1) [5,8,13–28].

Only seven patients were intravenous drug abusers and four had underlying chronic diseases. Most patients (19 of 24) were female and infective endocarditis occurred after obstetrical intervention in 10 of them [16,17]. The clinical presentation was severe with acute onset, large vegetation, and tricuspid valve mutilation in most patients (88%). Seventeen patients presented pulmonary embolism. The antibiotic of choice was an association of penicillin and aminoglycoside [13]. Surgical treatment were indicated in seven cases and consisted in valve excision and replacement with a bioprosthesis or tricuspid annuloplasty according to valve anatomy. All patients who underwent surgery had a good evolution [15–17]. Five patients who received only medical treatment died (29.4%) [16]. Our patient was the oldest described in the literature. He had no debilitating disease and did not consume any illicit drugs. In

our patient, surgical treatment was indicated because of ongoing infection, increasing size of tricuspid vegetation, occurrence of pulmonary embolism, and right heart failure despite adapted antibiotics. The indication of surgery in GBS RSIE is less established than in left-sided endocarditis [8,13]. The mortality in GBS tricuspid valve endocarditis is also lower than the left-sided endocarditis in which mortality rate can reach 50–100% if medical treatment only [5,8,18]. These data suggest that a combined medical-surgical treatment with early surgery could be the strategy of choice when *S. agalactiae* is responsible of the infection. Because of the frequent association with predisposing conditions and comorbidities, a close follow-up of our patient is necessary in order to detect on time a possible underlying malignancy that may be revealed by GBS tricuspid infective endocarditis.

Conclusion

GBS infective endocarditis is an aggressive clinical entity. Tricuspid valve involvement is rare and frequently occurs in *postpartum* and older patients with debilitating diseases. Because of the high probability of valve mutilation, severe complications, and poor prognosis, an appropriate medical-surgical approach seems to be the strategy of choice in this infection.

References

- [1] Akinosoglou K, Apostolakis E, Marangos M, Pasvol G. Native valve right sided infective endocarditis. *Eur J Intern Med* 2013;24:510–9.
- [2] Lee MR, Chang SA, Choi SH, Lee GY, Kim EK, Peck KR, et al. Clinical features of right-sided infective endocarditis occurring in non-drug users. *J Korean Med Sci* 2014;29:776–81.
- [3] Revilla A, López J, Villacorta E, Gómez I, Sevilla T, delPozo MA, et al. Isolated right-sided valvular endocarditis in non-intravenous drug users. *Rev Esp Cardiol* 2008;61:1253–9.
- [4] Murdoch DR, Corey GR, Hoen B, Miró JM, Fowler Jr VG, Bayer AS, et al. Clinical presentation, etiology, and outcome of infective endocarditis in the 21st century: the International Collaboration on Endocarditis—Prospective Cohort Study. *Arch Intern Med* 2009;169:463–73.
- [5] Rollán MJ, San Román JA, Vilacosta I, Sarriá C, López J, Acuna M, et al. Clinical profile of *Streptococcus agalactiae* native valve endocarditis. *Am Heart J* 2003;146:1095–8.
- [6] Grossman J, Tompkins RL. Group B beta hemolytic streptococcal meningitis in mother and infant. *N Engl J Med* 1974;29:387.
- [7] Skoff TH, Farley MM, Petit S, Craig AS, Schaffner W, Gershman K, et al. Increasing burden of invasive group B streptococcal disease in nonpregnant adults, 1990–2007. *Clin Infect Dis* 2009;49:85–92.
- [8] Gallagher PG, Watanakunakorn C. Group B streptococcal endocarditis: report of seven cases and review of the literature 1962–1985. *Rev Infect Dis* 1986;8:175–88.
- [9] Pringle SD, McCartney AC, Marshel DA, Cobbe SM. Infective endocarditis caused by *Streptococcus agalactiae*. *Intl J Cardiol* 1989;24:179–83.
- [10] Edwards MS, Baker CJ. *Streptococcus agalactiae* (Group B *Streptococcus*). In: Mandell GL, Bennet JE, Dolin R, editors. *Mandell, Douglas, and Bennett's principles and practice of infectious diseases*. Philadelphia: Churchill Livingstone; 2000. p. 2156–67.
- [11] Farley MM. Group B streptococcal disease in nonpregnant adults. *Clin Infect Dis* 2001;33:556–61.
- [12] Edwards MS, Baker CJ. Group B streptococcal infections in elderly adults. *Clin Infect Dis* 2005;41:839–47.
- [13] Azzam ZS, Ron Y, Oren I, Sbeit W, Motlak D, Krivoy N. Group B streptococcal tricuspid valve endocarditis: a case report and review of literature. *Int J Cardiol* 1998;64:259–63.
- [14] Vilde JL, Roujeau JC, Bure A, Verriac F, Bastin R. Infections graves et septicémies a streptocoque du groupe B chez l'adulte: à propos de quatre observations, dont une endocardite tricuspidienne compliquée de glomérulonéphrite. *Sem Hop* 1974;50:355–62 [In French].
- [15] Mong K, Taylor D, Muzyka T, Freed D, Koshal A. Tricuspid endocarditis following a Papanicolaou smear: case report. *Can J Cardiol* 1997;13:895–6.
- [16] Salih H, Guellab D, Zoubidi M, Bennis A. Endocardite tricuspidale du post-partum à streptocoque B. *Ann Cardiol Angéiol* 2012;61:121–4 [In French].
- [17] Vincent P, Davis R, Roy D. Group B *Streptococcus* tricuspid endocarditis presenting with arthralgia in a postpartum woman: a case report. *J Med Case Rep* 2012;6:242.
- [18] Scully BE, Spriggs D, Neu HC. *Streptococcus agalactiae* (group B) endocarditis: a description of 12 cases and review of the literature. *Infection* 1987;15:175–88.
- [19] Acar J, Antebi L, Cabrol C, Vilde JL, Monin B, Damelon F, et al. Endocardite aiguë tricuspidienne post-partum à streptocoque du groupe B. *Ann Med Interne* 1972;123:217–24 [In French].
- [20] Jemsek JG, Gentry LO, Greenberg SB. Malignant group B streptococcal endocarditis associated with saline-induced abortion. *Chest* 1979;76:695–7.
- [21] Farley MM, Harvey RC, Stull T, Smith JD, Schuchat A, Wenger JD, et al. A population-based assessment of invasive disease due to group B *Streptococcus* in non-pregnant adults. *N Engl J Med* 1993;328:1807–11.
- [22] Watanakunakorn CH, Hapte-Gabr E. Group B streptococcal endocarditis of tricuspid valve. *Chest* 1991;100:569–71.
- [23] Kangavari S, Collins J, Cercek B, Atar S, Siegel R. Tricuspid valve group B streptococcal endocarditis after an elective termination of pregnancy. *Clin Cardiol* 2000;23:301–3.
- [24] Vartian C, Septimus E. Tricuspid valve group B streptococcal endocarditis following elective abortion. *Rev Infect Dis* 1991;13:997–8.
- [25] Sambolla A, Miro JM, Tornos MP, Almirante B, Moreno-Torrico A, Gurgui M, et al. *Streptococcus agalactiae* infective endocarditis: analysis of 30 cases and review of the literature, 1962–1998. *Clin Infect Dis* 2002;34:1576–84.
- [26] Andresen K, Balf D, Marcu CB. Massive pulmonary embolism in a patient with *Streptococcus agalactiae* tricuspid valve endocarditis. *Heart* 2005;91:279.
- [27] Palys EE, Li J, Gaut PL, Hardy WD. Tricuspid valve endocarditis with Group B *Streptococcus* after an elective abortion: the need of new data. *Infect Dis Obstet Gynecol* 2006;2006:1–3.
- [28] Ribas N, Arribasy C, Murillas J. *Streptococcus agalactiae* tricuspid valve endocarditis. A case report and review of literature. *Enferm Infect Microbiol Clin* 2009;27(3):191–4.