



Since January 2020 Elsevier has created a COVID-19 resource centre with free information in English and Mandarin on the novel coronavirus COVID-19. The COVID-19 resource centre is hosted on Elsevier Connect, the company's public news and information website.

Elsevier hereby grants permission to make all its COVID-19-related research that is available on the COVID-19 resource centre - including this research content - immediately available in PubMed Central and other publicly funded repositories, such as the WHO COVID database with rights for unrestricted research re-use and analyses in any form or by any means with acknowledgement of the original source. These permissions are granted for free by Elsevier for as long as the COVID-19 resource centre remains active.



Available online at  
**ScienceDirect**  
[www.sciencedirect.com](http://www.sciencedirect.com)

Elsevier Masson France  
**EM|consulte**  
[www.em-consulte.com/en](http://www.em-consulte.com/en)



SFORL Guidelines

# Guidelines of the French Society of Otorhinolaryngology (SFORL) for teleconsultation in patients with vertigo during the COVID-19 pandemic



P. Bertholon<sup>a</sup>, H. Thai-Van<sup>b,c,d,e,\*</sup>, D. Bouccara<sup>f</sup>, M.-J. Esteve-Fraysse<sup>g</sup>,  
 S.R. Wiener-Vacher<sup>h</sup>, E. Ionescu<sup>b,c,e</sup>

<sup>a</sup> Service d'ORL et de Chirurgie Cervico-Faciale, Hôpital Nord, CHU Saint-Étienne, Avenue A Raimond, 42270 Saint Priest en Jarez, France

<sup>b</sup> Service d'Audiologie et d'Explorations Otoneurologiques, Hôpital Edouard Herriot, 69003 Lyon, France

<sup>c</sup> Hôpital Femme Mère Enfant, 69500 Bron, France

<sup>d</sup> Université Claude Bernard Lyon 1, 69100 Villeurbanne, France

<sup>e</sup> Institut de l'Audition, Centre de recherche de l'Institut Pasteur, Inserm U1120, 75012 Paris, France

<sup>f</sup> Service d'ORL et de Cancérologie Cervico-Faciale, AP-HP, Hôpitaux Universitaires Paris-Ouest, Hôpital européen Georges-Pompidou, 20, rue Leblanc, 75015 Paris, France

<sup>g</sup> Service d'ORL et de Chirurgie Cervico-Faciale, Hôpital Purpan, 1, place du Docteur Baylac, 31300 Toulouse, France

<sup>h</sup> Service d'ORL et de Chirurgie Cervico-Faciale, Centre d'exploration de l'équilibre de l'enfant (EFEE), Hôpital Universitaire Robert Debré, 48, boulevard Sérurier, 75019 Paris, France

## ARTICLE INFO

**Keywords:**  
 Telemedicine  
 Teleconsultation  
 Neurotology  
 Vertigo  
 COVID-19  
 SARS-CoV-2  
 Coronavirus  
 Pandemic  
 Epley manoeuvre

## ABSTRACT

**Objectives:** In the context of the SARS-CoV-2 pandemic, patients may have been dissuaded from seeking consultation, thus exposing themselves to a risk of loss of chance. This guide aims to define how teleconsultation can assist in assessing vertiginous adults or children, and to gather the information needed to provide quick medical care.

**Methods:** These recommendations rely on the authors' experience as well as on literature. A survey on otoneurologic approach via telemedicine has been conducted based on a literature search until March 2020.

**Results:** The first clinical assessment of the vertiginous patient via teleconsultation can only be successful if the following conditions are met: initial contact to verify the feasibility of the assessment at a distance, the presence of a caregiver in order to assist the patient, the possibility of making video recordings. Medical history via telemedicine, as in a face-to-face assessment, allows to assess the characteristics, duration, frequency, and potential triggering factors of the vertigo, in both children and adults. During teleconsultation, the following tests can be carried out: oculomotricity evaluation, assessment of balance, simple neurological tests, checking for positional vertigo/nystagmus and, eventually to perform canalith-repositioning procedures. In children, the following should be searched for: history of hearing or visual impairment, a context of fever or trauma, otorrhea, signs of meningeal irritation.

**Conclusion:** The neurotologic telemedicine relies on the accuracy of the clinical assessment, which is based on history taking and a few simple tests, encouraging the development of a decision-making algorithm adapted for teleconsultation. However, the latter has its limitations during an emergency examination of a new patient presenting vertigo, and, at least in some cases, cannot replace a face-to-face consultation. Teleconsultation is often adapted for follow-up consultations of previously selected vertiginous patients during face-to-face assessment.

© 2020 Published by Elsevier Masson SAS.

\* Corresponding author at: Service d'Audiologie et d'Explorations Otoneurologiques, Hôpital Edouard Herriot, 69003 Lyon, France.  
 E-mail address: [hung.thai-van@chu-lyon.fr](mailto:hung.thai-van@chu-lyon.fr) (H. Thai-Van).

## 1. Introduction

Since its appearance, the objective of modern telemedicine has been to assist in providing healthcare to people geographically isolated from physicians or medical centers (<https://www.who.int/tb/areas-of-work/digital-health/definitions>). In the beginning of

the 1970s, experiments with modern communication methods were designed to provide medical care to a greater number of patients [1]. With now widespread high-speed internet access and a growing number of users, telemedicine has rapidly developed all over the world in recent years [2]. With regard to its utility and effectiveness, recent studies have shown:

- a significant degree of satisfaction from 79% [3] to 87% [4] among patients who have used it and;
- its effectiveness in countries where it has been introduced [5].

The current SARS-CoV-2 pandemic (also called COVID-19), by imposing measures limiting the spread of the virus in the population, as well as among the medical staff, has created new indications for teleconsultation (TC). Vertigo is one of the most common reasons for seeking medical attendance in adults [6]. It is thus essential to define how TC can assist in managing vertigo, and in particular, in assessing the signs of severity likely to impact not only the quality of life, but also the prognosis, depending on the rapidity of response to treatment. In Neurotology, the main objective in adults is to bring out the etiologies of vertigo that constitute a life-threatening emergency, particularly strokes, which represent 3–5% of vestibular emergencies [7]. In children, the challenge is to recognize vertigos linked to a central nervous system disorder (1–3%) [8,9] in particular, a brain tumor whose incidence has been evaluated to be 5.6/100,000 in the 0 to 14 age range [10].

The goal is to identify the TC methods that are now available in neurotology and are applicable in the context of the pandemic. The TC relies on the accuracy of clinical assessment, which is based on history taking and a few simple tests [11–13], because there are evident limitations regarding imaging and laboratory tests [14–16]. After a brief anatomical, clinical and epidemiological reminder, the methods and conditions for TC will be discussed. We will then establish the patient history taking and clinical examination and suggest simple decision-making algorithms [11–13,17]. Finally, we will outline the current limitations of TC.

## 2. Anatomic-clinical and epidemiological background

### 2.1. Anatomic-clinical reminder

Vertigo is considered to have a peripheral vestibular origin (PVO) if it is caused by an inner ear or vestibular nerve impairment, and a central nervous system origin, if the lesion involves the vestibular nuclei, the vestibular connections in the brainstem, and/or the cerebellar circuits. For emergency management, it should be kept in mind that vertigo due to PVO impairment has essentially two clinical presentations. The first clinical presentation is an overall dysfunction of the inner ear or vestibular nerve: the patient complains of persistent vertigo and examination shows a peripheral vestibular syndrome, as observed in vestibular neuritis or Ménière's disease (Box 1). The second clinical presentation is a dysfunction localized in a semicircular canal (by otolith debris displacement): the patient complains of brief vertigo during head movement (less than a minute), and the positional manoeuvres indicate the impaired canal, as observed in benign paroxysmal positional vertigo (BPPV). Other than these two clinical situations, the patient suffers a priori from a central neurological impairment [17].

### 2.2. Epidemiology

#### 2.2.1. Adults

A meta-analysis conducted in 2019 shows the extreme variability in the distribution of vertigo etiologies depending on the speciality (ENT, Neurology, emergency medicine, etc.) and the

#### **Box 1: Clinical arguments for differentiation between a peripheral vestibular syndrome through overall injury of the inner ear (excluding benign paroxysmal positional vertigo) or of the vestibular nerve, and a central vestibular syndrome.**

Peripheral Vestibular Syndrome (Injury of the inner ear or the vestibular nerve)

- Rotatory vertigo with neurovegetative symptoms (vomiting, sweating, paleness)
- Peripheral vestibular syndrome = Horizontal-torsional nystagmus whose quick phase is opposite to the postural deviation
- Halmagyi test is usually positive (refixation catch-up saccade)
- Possible auditory symptoms


Central Vestibular Syndrome (Injury to the vestibular nuclei or their connections)

- Instability (but associated rotatory vertigo is possible)
- Central vestibular syndrome = no systematisation between the postural deviation and the direction of the nystagmus
- Central nystagmus = purely vertical, horizontal, torsional a fortiori multi-directional (horizontal gaze-evoked nystagmus...)
- Halmagyi test is usually negative
- Exceptional auditory symptoms
- Possible neurological impairments: dysarthria, dysmetria, Claude Bernard Horner syndrome... .

changes in diagnostic criteria [18]. Nevertheless, six situations [19] represent almost  $\frac{3}{4}$  of vertiginous patients (the remaining  $\frac{1}{4}$  corresponding to rare and often indeterminate etiologies). The first cause is BPPV (20 to 30%) with brief and positional vertigo. Neurological vertigo (excepting the vestibular migraine), represents approximately 5 to 15% of vertiginous patients and appears as a first episode of long lasting vertigo/instability. In almost half of the cases, this type of vertigo has a vascular origin and a cerebellar stroke can be misleading (pseudo-labyrinthine forms). The remaining is represented by tumorous, inflammatory, or degenerative pathologies. Vestibular migraine represents around 10% of vertiginous patients [19,20]. Diagnosis requires a history of migraine and at least 5 attacks of vertigo lasting from 5 min to 72 h, associated in at least half of the cases with headaches and/or photophobia and phonophobia and/or visual aura [20]. The new concept of 'Persistent Postural-Perceptual Dizziness' (PPPD)' (5 to 15%), which includes previous conditions (phobic postural vertigo, chronic subjective dizziness, space-motion discomfort and visual vertigo) is now defined by specific clinical criteria [21]. The vertigo should be a disabling non-spinning sensation, lasting for more than three months, exacerbated by upright posture, active or passive motion and exposure to moving visual stimuli, noting that it often occurs after a previous peripheral or central vertigo [21]. Ménière's disease (5 to 10%) must combine vertigo lasting 20 min to 12 h with fluctuating auditory manifestations on one side (fullness, tinnitus, and hearing loss documented by audiometry) [22,23]. Finally, vestibular neuritis (5 to 10%) is characterized by a single episode of vertigo lasting several days with a typical peripheral vestibular syndrome (Box 1) [24].

#### 2.2.2. Children

The etiologies of vertigo in children, described in a French series of more than 2000 children [8], are presented in Fig. 1. In terms of the distribution of the etiologies, there are some differences compared to adults. First place is occupied by vestibular migraine



Sylvette R. Wiener-Vacher

**Vestibular disorders in children**

International Journal of Audiology 2008; 47:578–583

**Fig. 1.** Prevalence for vertigo aetiologies in children. The migraine equivalent is in the first position (>25%), followed by the benign paroxysmal vertigo of childhood (BPVC) [8] formerly known as idiopathic paroxysmal vertigo of childhood\* (15%) [25], and by vertigo after a head trauma (15%). There is a low incidence of “central nervous system” aetiologies (CNS tumours, epilepsies, and haemorrhages), less than 10%, as well as a very low incidence (< 5%) of endolymphatic hydrops (Menière’s Disease and Delayed Vertigo). Be aware of a possible ophthalmological origin (vergence insufficiency and/or refraction problem).

and migraine-equivalent vertigo (25%) and benign paroxysmal vertigo of childhood (BPVC) (15 to 20%) [8,9,25] takes second place. It involves very sudden bouts of loss of balance lasting several minutes, generally in children under 4 years of age; they are typical because they are not accompanied or preceded by headaches or influenced by changes in head position. They are usually well tolerated and cure spontaneously. A very low BPPV incidence (less than 5%) is found, generally in the context of recent cranial trauma. Other peripheral etiologies are possible but rare (labyrinthitis, endolymphatic hydrops, autoimmune impairment). Posterior cranial fossa tumors should be suspected in case of worsening imbalance, progressive walking disorders, headaches or vomiting (predominantly in the morning), and visual impairments, which point to an intracranial hypertension syndrome. In the event of vertigos occurring predominantly at night and without obvious neurological signs, differential diagnosis should include childhood epilepsy. Cerebrovascular accidents are exceptional in children but should be considered in the context of cardiac or intracranial arteriovenous malformations. The most common “non-vestibular” cause (10%) of balance disorders in children is the existence of a visual impairment: uncorrected or undetected ametropia, or vergence dysfunction.

At this time, it does not appear that COVID-19 infection causes specific vestibular pathologies.

**3. TC methods**

Telemedicine procedures are medical procedures performed from a distance, through a device using information and communication technologies (article L. 6313-1 of the Public Health Code). The quality of the communication between the patient and the physician is crucial, as well as the protection and security of personal data. The platforms offering the most complete services are: Doctolib, AvecMonDoc, Clickdoc, eConsult Sara (Auvergne-Rhône-Alpes region), Livi, MaQuestionMedicale.fr, Ordoclic, or TokTokDoc. As a reminder, throughout the coronavirus pandemic, it was not necessary for a patient to go through their attending physician and to have had a face-to-face consultation in the 12 months

preceding the TC. These TC platforms are secured and approved for hosting healthcare data. The TC is invoiced by the physician; the reimbursement is the same as for a traditional consultation (<https://www.ameli.fr/assure/remboursements/rembourse/telemedecine/teleconsultation>).

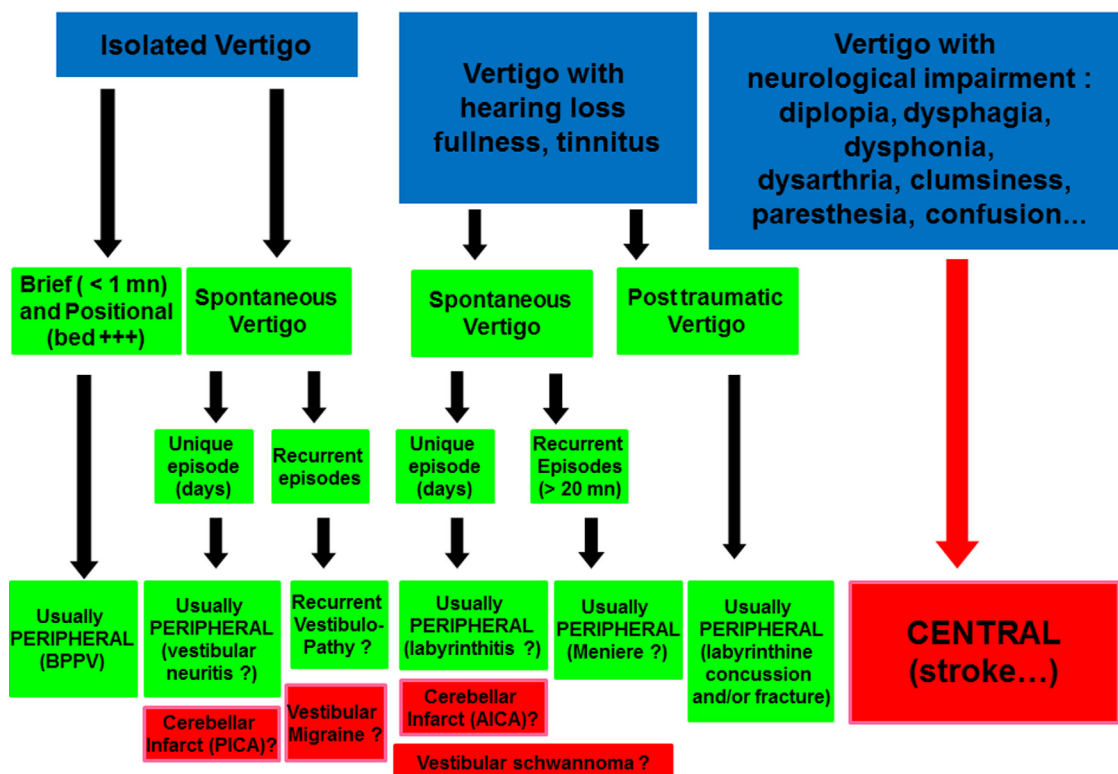
**4. Prerequisites for TC**

In order to enable TC, the patient must first be contacted beforehand through text message, email, or phone call to provide the necessary instructions so that they have a good understanding of how their smartphone (or their caregiver’s) should be used; the proper functioning of the patient’s and the physician’s webcam should be ensured in case the patient is not used to handling connected devices; The patient must be accompanied by a caregiver during the TC to avoid any accident during the diagnostic manoeuvres for BPPV and assessment of postural stability (for static and dynamic balance). The patient should choose a quiet room with sufficient but not excessive lighting (good quality video image), that is private (conforming to the confidentiality terms of exchanging personal information), and with a large enough bed for examination. A short high-quality video recording will be able to provide the physician consulting via TC essential clinical information to make the diagnosis. For example, video sequences in the event of suspected BPVC will stereotypically show children that are unbalanced, putting their head into their hands while crying and/or sitting on the floor during the attacks.

**5. Medical History****5.1. For adults**

Particularly useful in a context of vertigo and/or imbalance, it will be as effective via TC as in a traditional consultation (Fig. 2). A few questions will allow the practitioner to identify the personal background, both medical and surgical. From the beginning, the following are to be identified: vascular risk factors (risk of stroke), a history of migraine (vestibular migraine), the

## SYMPTOMS



**Fig. 2.** Decision-making algorithm based on the symptoms (vertigo, hearing impairment or neurological complaints) focusing on the duration, frequency, and triggering factors of the vertigo. PICA: Postero-inferior cerebellar artery. AICA: Antero-inferior cerebellar artery.

psychological context (PPPD, Meniere’s disease), previous tumors (risk of cerebellar metastasis), or trauma (labyrinthine fracture and/or concussion, BPPV). Current medication should be systematically checked, paying particular attention to aminoglycosides (risk of bilateral vestibular areflexia) and antiepileptics including carbamazepine or Tegretol® (risk of central cerebellar-vestibular syndrome in the event of overdose identified by blood test).

The patient’s medical history will provide information useful for the identification of the cause. Rotatory vertigo can correspond to a cause of PVO, while a minimal sensation of dizziness, in contrast to a significant imbalance, pertains more to a neurological cause. Imminent feeling of fainting/loss of consciousness supports a cardiac cause, orthostatic hypotension or vagal malaise. Atypical vertiginous sensations such as floating or weightlessness are potentially of psychogenic origin.

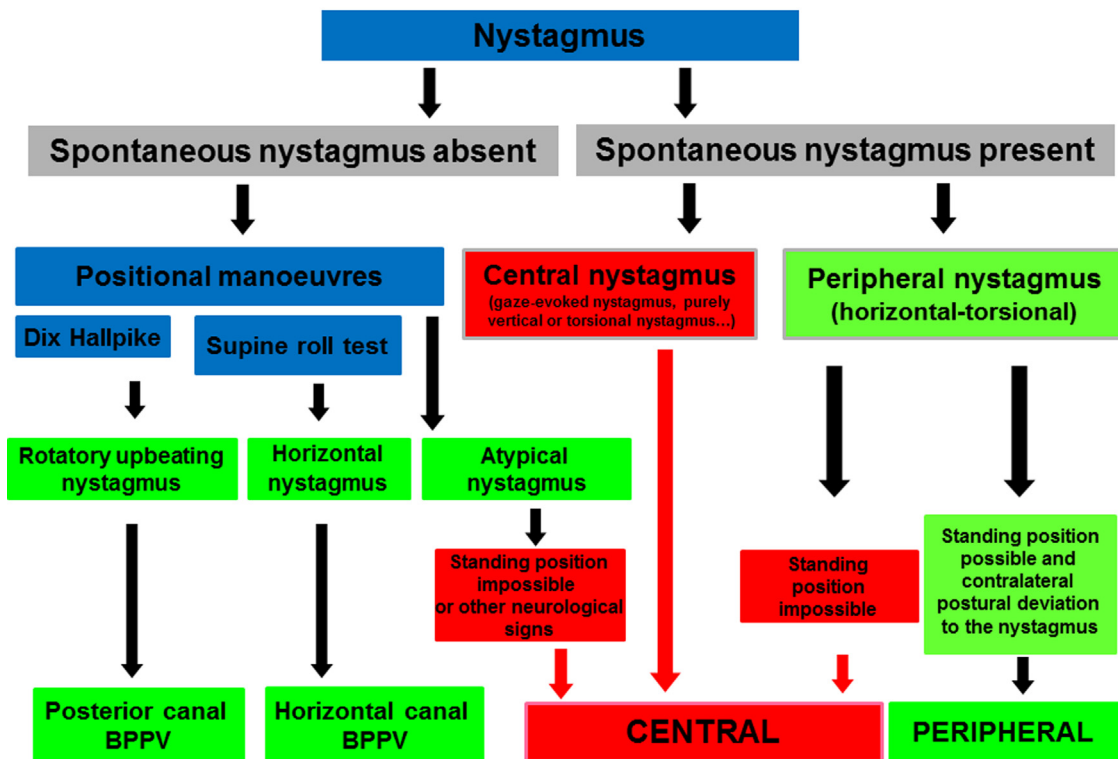
It is often difficult to accurately identify vertigo and criteria such as duration (seconds, more than 20 min, several days), frequency/recurrence, the potential trigger (positional? loud noise? coughing? sneezing? etc.) are more pertinent [11]. As such, vertigo lasting a few seconds, triggered by movement, especially at night, suggests a BPPV, while a sensation of vertigo/fainting occurring electively while standing up would suggest orthostatic hypotension. More rarely, vertigo caused by variations in pressure (coughing, sneezing) and/or loud noise favors an inner ear abnormality such as superior canal dehiscence, enlarged vestibular aqueduct or perilymph fistula. Vertigo occurring spontaneously and recurrently, in a context of migraines could suggest a vestibular migraine, but attention should be given to unusual headaches with acute onset and/or prolonged duration. A recurring vertigo associated with unilateral auditory manifestations suggests Meniere’s disease, but may also indicate a tumor of the cerebellopontine angle. A disabling vertigo lasting several days suggests vestibular

neuritis, but a stroke should be eliminated, particularly a cerebellar one. The presence of a vertical and/or oblique diplopia, a dysarthria, phonation and/or swallowing disorders, sensory disturbance, clumsiness of hands, a confusional component, will require emergency neurological assessment.

### 5.2. Special features in children

In children, medical history is crucial but difficult to obtain before the age of 5 and even more complicated when using a webcam. Therefore, talking to the parents is indispensable to identify the circumstances in which the vertigo/balance disorders appear. Indeed, vertigo secondary to a recent cranial trauma and associated with deterioration or fluctuation in hearing, should invoke a concussion of the inner ear or a perilymph fistula. The history taking should also consider recent headaches, background of fever, recent or chronic otorrhea, recent or progressive hearing loss (a progressive hearing impairment is to be suspected in a child who begins to ask their parents to repeat themselves). Children presenting sensorineural hearing loss, often have an associated uni- or bilateral vestibular impairment [26]; this can worsen during progressive flare-ups, manifesting itself through instabilities while walking accentuated by head movements. An inner ear deformity should be searched for in children presenting hearing impairment and episodes of vertigo, the most frequent being an enlarged vestibular aqueduct, isolated or in association with other abnormalities. It is also important to inquire about the age for onset of walking because a delayed posturo-motor development syndrome (onset of walking after eighteen months) can be due to complete bilateral peripheral vestibular loss that can be mistaken for neurological impairment. The history taking should also gather family background information such as hereditary hearing impairment,

# SIGNS



**Fig. 3.** Decision-making algorithm based on oculomotor signs and analysis of standing position. The analysis of spontaneous nystagmus sometimes immediately permits the identification of a central (gaze-evoked, vertical, or torsional) or peripheral (horizontal-torsional) nystagmus. In the event of horizontal-torsional nystagmus, a Romberg test must be performed to ensure the patient's ability to stand upright, alone, with eyes opened (being unable to do this suggests a central nervous system impairment), then obtain one with the eyes closed (Romberg and/or Fukuda test), to ensure a postural deviation in the opposite direction of the horizontal-torsional nystagmus (peripheral-type vestibular syndrome). In the absence of spontaneous nystagmus, positional manoeuvres are performed. BPPV: Benign Paroxysmal Positional Vertigo.

background of migraines or existence of familial episodic ataxia. A well-conducted interview should allow for a diagnostic, which the clinical examination will then reinforce.

## 6. The clinical Neurotologic examination adapted for TC

The technical aspects of otoscopy, acoumetry and audiometry, which are essential for the etiological diagnosis of vertigo patients are developed in a specific article [27] (Fig. 2).

### 6.1. Adults

It will include the oculomotor examination followed by postural deviations as well as some simplified neurological tests [28]. The practitioner should require video recordings of the eye movements of the patient when looking straight ahead for 5 to 10 s, then in different gaze directions (up, down, left, right). The patient or the caregiver should slowly swing the phone camera from left to right and vice versa, at a distance of around 25 cm (ocular pursuit). This very simple examination allows the practitioner to ensure the absence of Claude Bernard Horner syndrome, which, in a context of vertigo/imbalance, signals a Wallenberg syndrome. It can also find an abnormality in eye alignment, in particular a vertical divergence of the eyes (“skew deviation”), considered a sign of central neurological impairment as it is very rare in peripheral otolith dysfunction [15]. This test highlight flutter or opsoclonus (exceptional), a gaze-evoked nystagmus, or an upbeat or downbeat nystagmus (increased and sometimes only visible in lateral gaze), which indicates central neurological impairment. If ocular pursuit is irregular or saccadic, this could also indicate a neurological

dysfunction. Observation of horizontal-torsional spontaneous nystagmus responding to Alexander’s law (increased intensity when the eye moves in the direction of the fast phase), is in favor of a PVO. In the absence of spontaneous nystagmus and in the event of positional vertigo, the positional manoeuvres, performed on a bed, will allow the impaired canal to be identified. Observation of a rotatory upbeat nystagmus during the Dix Hallpike Manoeuvre argues for a posterior canal BPPV, while a horizontal nystagmus during lateral rotation manoeuvres of the head, while lying down, suggests a horizontal canal BPPV.

The patient is then asked to stand up with his eyes open, in close proximity to the caregiver. If it is possible to stand up with the eyes open, the patient is then asked to close his eyes (Romberg test), or even to perform a Fukuda test (walking on the spot). This is particularly useful in the event of horizontal-torsional spontaneous nystagmus to support a PVO (Box 1 and Fig. 3). The inability to stand up alone with his eyes open should be considered a sign of central neurological impairment (in particular a stroke) [13]. Some neurological tests can be checked: cerebellar dysmetria using the finger-to-nose test and the heel-knee test, facial asymmetry at rest and during voluntarily contractions and/or sensory facial impairment disorder (rough tactile sensations or hot/cold).

At the end of this assessment, and depending on the algorithms suggested (Figs. 2 and 3), it is often possible to know if the practitioner is dealing with a peripheral vestibular or a central neurological impairment, and to identify most peripheral causes of vertigo (BPPV, recurring vertigo in Menière’s disease, vestibular neuritis, etc.). In the event of posterior canal BPPV, Epley-type therapeutic manoeuvres are indicated because are easily self-performed [29]. In any case, the patient is recommended to remain

seated, in bed, for 30 min after finishing the therapeutic manoeuvre [30].

This TC enables the immediate transmission of a medical and/or vestibular rehabilitation prescription.

## 6.2. Special features in children

Certain causes that have a potentially serious prognosis should be searched for. A background of fever and the presence of local signs ease the teleconsulting ENT specialist's etiopathogenetic reasoning. As such, in the event of an initially "trivial" otitis complicated by the appearance of a prolonged otorrhea, the diagnosis of labyrinthitis or cholesteatoma will be considered. If the child also presents with headaches, a nuchal sensitivity or rigidity during active or passive movement, vomiting, and photophobia, the diagnosis of meningitis is to be suspected. If intense vertigo is present without any other local ENT or neurological abnormality, but associated with gastrointestinal manifestations, the most probable diagnosis is vestibular neuritis, which may be mistaken with gastroenteritis. The observation of instability, always on the same side, when walking and nystagmus is essential for the diagnosis of vestibular neuritis.

Finally, visual impairment is an increasing cause of dizziness/instability and/or headache with the ever-growing popularity of all types of recreational activities based on small video screens (e.g., video games, mobile phones, TV... It is necessary to search for refractive disorders (myopia, hyperopia and astigmatism) and/or vergence dysfunction [31,32].

## 7. Current limitations of teleconsultation in Neurotology

There are at least three kinds. First of all, there is the difficulty to make a reliable video recording of the patient's eyes in complete darkness (videonystagmography), which is essential in revealing a spontaneous nystagmus of PVO. The recently developed device in the United States is very simple and adequate for this purpose. It consists in a plastic holder—<https://www.dizzydoctor.com/that> allows attaching a smartphone to ensure a significant reduction of the luminosity, similarly to a videonystagmoscope system. Although the visual suppression may still be insufficient to assure careful observation of spontaneous nystagmus, this system is sensible enough to detect specific nystagmus, especially in case of BPPV. However, it is hoped that the iOS or Android smartphone cameras will soon benefit from infra-red recording devices to enable filming in complete darkness. In a known patient, loaning adapted videonystagmography glasses has proved its value in observing nystagmus during a vertigo episode [33]. Secondly, there is the difficulty in performing a Halmagyi test that requires the observation of catch-up ocular saccades (favoring a PVO) during quick and especially unpredictable movements of the patient's head [34]. It will be noted that it is sometimes possible to observe catch-up saccades on one side during repeated horizontal movements of the head [28]. Last but not least, there is the necessity of secure and high-capacity transfer to ensure the reception of video data while guaranteeing the confidentiality and protection of patient data. In any case, the vestibular and clinical acquired data can and should be stored only on a server located in Europe with the Healthcare Data Hosting (HDS: Hébergement des Données de Santé) accreditation from the Health Ministry and in accordance with the European regulation (EU 2016/679) on the Protection of Personal Data (GDPR).

## 8. Conclusion

The current SARS-CoV-2 pandemic has led to an increasing demand in otoneurologic consultations by telemedicine. Facing a

vertiginous patient in emergency, TC is sometimes sufficient but has limitations regarding clinical examination, and, in a number of cases, cannot currently fully replace a face-to-face consultation. Algorithms are proposed to help for correct decision making. Undoubtedly, TC is adapted to carry out follow-up consultation for selected vertiginous patients previously assessed face-to-face.

## Disclosure of interest

The authors declare that they have no competing interest.

## Acknowledgement

The authors are thankful to Ruxandra - Cecilia Ionescu for proof-reading.

## References

- [1] Zundel KM. Telemedicine: history, applications, and impact on librarianship. *Bull Med Libr Assoc* 1996;84:71–9.
- [2] Wootton R. Telemedicine support for the developing world. *J Telemed Telecare* 2008;14(3):109–14, <http://dx.doi.org/10.1258/jtt.2008.003001>.
- [3] Donelan K, Barreto EA, Sosong S, et al. Patient and clinician experiences with telehealth for patient follow-up. *Care* 2019;25(1):40–4.
- [4] Fieux M, Duret S, Bawazeer N, Denoix L, Zaouche S, Tringali S. Telemedicine for ENT: Effect on quality of care during Covid-19 pandemic. *Eur Ann Otorhinolaryngol Head Neck Dis* 2020;137(4):257–61, <http://dx.doi.org/10.1016/j.anorl.2020.06.014>.
- [5] O'Cathail M, Sivanandan MA, Diver C, Patel P, Christian J. The Use of Patient-Facing Teleconsultations in the National Health Service: Scoping Review. *JMIR Med Inform* 2020;8(3):e15380, <http://dx.doi.org/10.2196/15380>.
- [6] Rubin F, Vellin JF, Berkaoui J, et al. Impact of the SARS-CoV-2 epidemic on private ENT consulting practice during the first month of lockdown in Réunion Island in 2020. *Eur Ann Otorhinolaryngol Head Neck Dis* 2020;137(4):251–6, <http://dx.doi.org/10.1016/j.anorl.2020.06.01>.
- [7] Tehrani ASS, Kattah JC, Kerber KA, et al. Diagnosing Stroke in Acute Dizziness and Vertigo Pitfalls and Pearls. *Stroke* 2018;49:788–95.
- [8] Wiener-Vacher SR. Vestibular disorders in children. *Int J Audiol* 2008;47(9):578–83, <http://dx.doi.org/10.1080/14992020802334358>.
- [9] O'Reilly RC, Morlet T, Nicholas BD, et al. Prevalence of vestibular and balance disorders in children. *Otol Neurotol* 2010;31:1441–4.
- [10] Ostrom QT, Gittleman H, Fulop J, et al. CBRUS statistical report: primary brain and central nervous system tumors diagnosed in the United States in 2008–2012. *Neuro Oncol* 2015;17(Suppl 4):iv1–62.
- [11] Newman-Toker DE, Edlow JA. TiTraTE: a novel approach to diagnosing acute dizziness and vertigo. *Neurol Clin* 2015;33:577–99.
- [12] Kattah JC, Talkad AV, Wang DZ, Hsieh YH, Newman-Toker DE. HINTS to diagnose stroke in the Acute Vestibular syndrome. Three-step bedside oculomotor examination more sensitive than early MRI diffusion-weighted imaging. *Stroke* 2009;40:3504–10.
- [13] Vanni S, Pecci R, Casati C, Moroni F, et al. STANDING, a four-step bedside algorithm for differential diagnosis of acute vertigo in the emergency department. *Acta Otorhinolaryngol Ital* 2014;34:419–26.
- [14] Muncie HL, Sirmans SM, James E. Dizziness: approach to evaluation and management. *Am Fam Physician* 2017;95:154–62.
- [15] Hoffman RM, Einstadter D, Kroenke K. Evaluating dizziness. *Am J Med* 1999;107:468–78.
- [16] Ahsan SF, Syamal MN, Yaremchuk K, Peterson E, Seidman M. The cost and utility of imaging in evaluating dizzy patients in the emergency room. *Laryngoscope* 2013;123:2250–3.
- [17] Venhovens J, Meulstee J, Verhagen WIM. Acute vestibular syndrome: a critical review and diagnostic algorithm concerning the clinical differentiation of peripheral versus central aetiologies in the emergency department. *J Neurol* 2016;263:2151–7.
- [18] Parker IG, Hartel G, Paratz J, Choy NL, Rahmann A. A systematic review of the reported proportions of diagnoses for dizziness and vertigo. *Otol Neurotol* 2019;40:6–15.
- [19] Strupp M, Dieterich M, Brandt T. The treatment and natural course of peripheral and central vertigo. *Dtsch Arztebl Int* 2013;110:505–16.
- [20] Lempert T, Olesen J, Furman J, et al. Vestibular migraine. Diagnostic criteria. Consensus document of the Barany society and the international headache society. *J Vest Res* 2012;22:167–72.
- [21] Staab JP, Eckhardt-Henn A, Horii A, et al. Diagnostic criteria for persistent postural-perceptual dizziness (PPPD). Consensus document of the committee for the classification of the vestibular disorders of the Barany society. *J Vest Res* 2017;27:191–218.
- [22] Committee on hearing and equilibrium guidelines for the diagnosis and evaluation of therapy in Meniere's, disease. *Otolaryngol Head Neck Surg* 1995;113:181–5.

- [23] Lopez-Escamez JA, Carey J, Chung WH, et al. Diagnostic criteria for Meniere's disease. *J Vest Res* 2015;25:1–7.
- [24] Jeong SH, Kim HJ, Kim JS. Vestibular neuritis. *Semin Neurol* 2013;33:185–94.
- [25] Jahn K. Vertigo and dizziness in children. *Handb Clin Neurol* 2016;137:353–63.
- [26] Cushing SL, Gordon KA, Rutka JA, James AL, Papsin BC. Vestibular end-organ dysfunction in children with sensorineural hearing loss and cochlear implants: an expanded cohort and etiologic assessment. *Otol Neurotol* 2013;34:422–8.
- [27] Thai-Van H, Bakhos D, Bouccara D, Loundon N, Marx M, Mom T, et al. Telemedicine in Audiology. Best Practice recommendations from the French Society of Audiology (SFA) and the French Society of Otorhinolaryngology Head and Neck Surgery (SFORL). *Eur Ann Otorhinolaryngol Head Neck Dis* 2020, <http://dx.doi.org/10.1016/j.anorl.2020.10.007>. S1879-7296(20)30244-1].
- [28] Shaikh AG, et al. Consensus on virtual management of vestibular disorders: urgent versus expedited care. *Cerebellum* 2020:1–5, <http://dx.doi.org/10.1007/s12311-020-01178-8>.
- [29] Radtke A, Von Brevern M, Tiel-Wilck K, Mainz-Perchalla A, Neuhauser H, Lempert T. Self-treatment of benign paroxysmal positional vertigo. Semont maneuver vs Epley procedure. *Neurology* 2004;63:150–2.
- [30] Uneri A. Falling sensation in patients who undergo the Epley manoeuvre: a retrospective study. *Ear Nose Throat J* 2005;84:84–5.
- [31] Wiener-Vacher SR, Quarez J, Le Priol A. Epidemiology of Vestibular Impairments in a Pediatric Population. *Semin hear* 2018;39:229–42.
- [32] Wiener-Vacher SR, et al. Dizziness and convergence insufficiency in children: screening and management. *Front Integr Neurosci* 2019;10:13–25.
- [33] Young AS, Lechner C, Bradshaw AP, et al. Capturing acute vertigo. A vestibular event monitor. *Neurology* 2019;92:e2743–53.
- [34] Halmagyi GM, Chen L, MacDougall HG, et al. The video-head impulse test. *Front Neurol* 2017;8:258, <http://dx.doi.org/10.3389/fneur.2017.00258>.