



# Anterior approaches to the acetabulum: which one to choose?

Tim Pohlemann\*  
Steven C. Herath\*  
Benedikt J. Braun  
Mika F. Rollmann  
Tina Histing  
Antonius Pizanis

- Surgical treatment of acetabular fractures remains challenging even for experienced surgeons.
- Whilst the ilioinguinal and the Kocher-Langenbeck approach remain the standard procedures to expose the anterior or posterior aspects of the acetabulum, some modified anterior approaches for the stabilization of the acetabulum have been introduced.
- This article will provide an overview of approaches to the anterior aspect of the acetabulum and explain the efforts that have been made to improve the surgeon's options for certain fracture modifications, such as fractures with separation of the quadrilateral surface.

**Keywords:** acetabular fracture; approach; osteosynthesis

Cite this article: *EFORT Open Rev* 2020;5:707-712.

DOI: 10.1302/2058-5241.5.190061

According to Emile Letournel, fractures of the acetabulum can be subdivided into ten fracture types.<sup>1</sup> There are five elementary fracture types, highlighted by a singular fracture line separating either the posterior or anterior wall or column, or involving both columns with a transverse fracture pattern, and combined fracture types which represent the five most frequent combinations of the elementary fracture lines. Depending on the classification and specific additional fracture pattern, such as marginal impactions, intraarticular fragments and cartilage damage, the attending surgeon has to choose between the different options of anterior/posterior or rarely extended or combined surgical approaches. While the Kocher-Langenbeck approach remains the standard approach to the dorsal aspect of the acetabulum, there are several anterior approaches which can be utilized for the stabilization of fractures which involve anterior structures of the acetabulum or both column fractures.

## Ilioinguinal approach: the standard

The ilioinguinal approach as described by Letournel allows the visualization of the iliac fossa, the entire anterior column and the quadrilateral surface of the acetabulum from the pubic symphysis to the sacroiliac (SI) joint. The posterior column can only be palpated at the sciatic notch, but reduction and preliminary stabilization can be achieved using specific reduction clamps ('King Tongs', 'Colinear clamps') after anatomic reduction of the anterior column. The ilioinguinal approach does not allow any visualization of the hip joint itself, therefore the correct reduction of the articular surface must be verified using absolute anatomic reduction and alignment of all accessible fracture lines as well as fluoroscopic control.

For the ilioinguinal approach, the patient is positioned supine on a radiolucent carbon table. As an alternative option, the operation can be carried out on a specified traction table allowing for longitudinal and lateral traction of the hip. This option is not applied in the authors' own practice, as the option to modify the direction of traction through the full range of motion of the hip joint allows for more specific reduction manoeuvres, and static traction can easily be maintained by the use of sterile table attachments.

Disinfection and draping should allow access to the whole abdominal area in order to facilitate an extension of the surgical exposure in case of intraoperative vessel injuries. The ipsilateral leg is draped free into the surgical field to allow for hip flexion and traction.

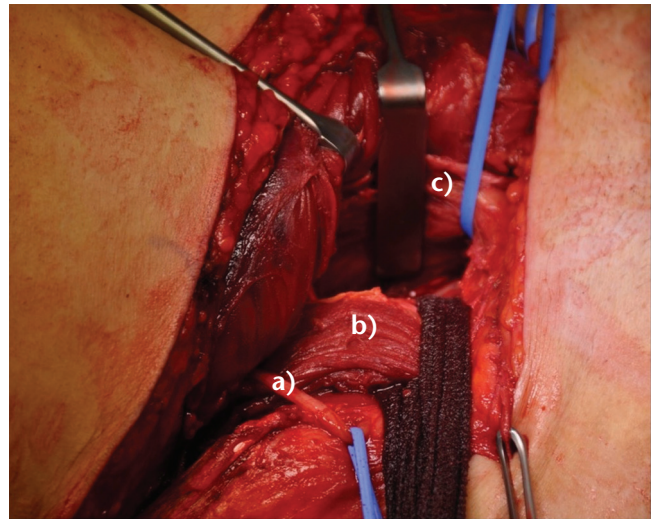
Anatomical landmarks for the ilioinguinal approach are the pubic symphysis, the anterior superior iliac spine (ASIS) and the iliac crest. The incision starts from the posterior third of the iliac crest to the ASIS. From there, it continues along the inguinal ligament to the midline, ending approximately two centimetres cranial to the pubic symphysis.

With further exposure, the ilioinguinal approach opens three windows, which are used to visualize the anterior column, anterior wall and the quadrilateral surface by alternating retraction of soft tissue.

For the first window, the insertion of the external oblique muscle is released from the iliac crest. Care must be taken to stay within the intertendinous plane between the abdominal wall and the abductor muscles and to release the abdominal wall in the subperiosteal plane from the iliac crest. This preserves a layer of stable tissue for later reattachment of the abdominal wall directly to the fascia of the abductor muscles, ensuring a reliable coverage of the iliac crest. The iliac fossa is exposed by subperiosteal mobilization of the iliac muscle using a long Cobb Elevator.

After temporarily packing the first window with a sponge, the aponeurosis of the external oblique muscle is further incised from the ASIS to the lateral aspect of the rectus sheath. The incision should run about one centimetre cranial to the external inguinal ring. Medially, the spermatic cord or round ligament is mobilized. Starting from the ASIS, the inguinal ligament is incised and, proceeding further medially, approximately at the border of the proximal to the middle third of the distance from the ASIS to the pubic tubercle, the posterior wall of the inguinal canal is opened by releasing the transversus abdominis from the inguinal ligament, taking about two millimetres of the ligament with the tendon to facilitate repair. Laterally, the lateral cutaneous nerve of the leg is identified and marked. After that, proceeding medially, the psoas muscle with the femoral nerve on it is identified. Medial to the psoas muscle, the iliopectineal fascia separates the neural from the vascular compartment. It must be divided in order to gain access to the true pelvis. By retraction of the psoas and femoral nerve laterally and the vessels medially, the fascia can and must be divided safely down to the pubic bone. The psoas muscle's fascial attachment to the pelvic brim is then divided to facilitate access to the true pelvis. Exposure of the iliac vessels should be minimized to reduce the risk of injuries to the vessels and the lymphatic structures. By flexion of the hip, the psoas muscle can be undermined to place a sling around it for retraction (Fig. 1).

To expose the third window, the vessels are undermined with a finger to identify the lateral border of the rectus abdominis muscle, where dissection continues down to the pubic bone. In our own hands, only a short (4 cm) longitudinal incision at the lateral fascia of the rectus abdominis muscle is required to gain minimal access to the pubic symphysis area. The third window being so small, it allows only for directing and fixing the plate in the symphysis region. Other authors describe an extended third window, which would enable a similar exposure to that provided by the 'Stoppa approach'. According to the individual techniques of reduction and stabilization, various modifications can be applied.

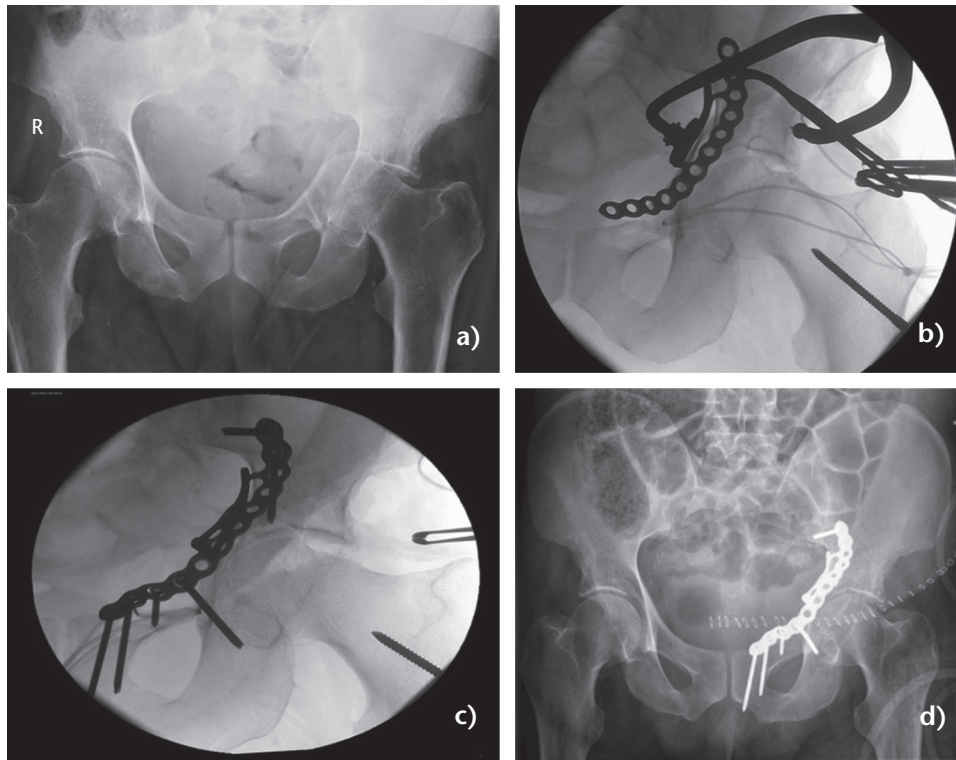


**Fig. 1** Second window of the ilioinguinal approach. (a) Lateral cutaneous nerve of the leg in this case found 1.5 centimetres medial to the anterior superior iliac spine. (b) Psoas muscle and femoral nerve with a sling placed around them to facilitate lateral retraction. (c) Langenbeck retractors expose the second window between the psoas muscle and the vessels, which are retracted medially.

When continuing dissection on the upper surface of the os pubis, care must be taken not to injure an eventual anastomosis between the external iliac artery and the obturator artery (*corona mortis*), which, if present, can be found at the posterior surface of the pubic bone. If the anastomosis is present, it should be coagulated or ligated.

After exposing the three windows of the ilioinguinal approach, reduction and stabilization of the anterior column and the quadrilateral surface is performed using alternating retraction of the soft tissues. In principle, the first step is an absolutely anatomic reduction of the anterior column from posterior to anterior with some preliminary plate fixation, using a long plate spanning from the area of the SI joint to the pubic symphysis. In a second step, if required, the posterior column is de-rotated and pulled 'upwards' by the use of the special clamps and finally fixed by the use of long lag screws connecting the anterior and posterior columns. The quadrilateral surface, rarely bearing cartilage, is in principle of secondary importance, but can be controlled using additional clamps and will stay in place after a solid fixation of the anterior and posterior columns. To achieve additional stabilization of a completely separated quadrilateral surface, different spring plates have been introduced (Fig. 2).<sup>2</sup>

For wound closure, after placement of drains, a careful reconstruction of the inguinal canal is mandatory. Therefore, the conjoint tendon is reattached to the inguinal ligament and a tight fascial repair is carried out to restore the floor of the inguinal canal. During the subsequent repair of the oblique aponeurosis and rectus sheath, great care



**Fig. 2** (a) Fracture of the anterior column with associated hemitransverse fracture and displaced quadrilateral surface. (b) Reduction of the quadrilateral surface using an asymmetric pelvic reduction clamp and a plate designed to address the quadrilateral surface. (c) Fixation of the plate after reduction of the fracture and (d) postoperative result.

must be taken not to entrap the spermatic cord or the round ligament. Furthermore, the abdominal wall should be reattached to the iliac crest in an overlapping way. A thorough subcutaneous and skin closure is performed.

The ilioinguinal approach remains the standard anterior approach to the acetabulum. Typically, it is chosen to address not only fractures of the anterior column or the anterior wall, but also transverse fractures with mainly anterior displacement, combined fractures with a minor displacement of the posterior part and associated both column fractures.

### Iliofemoral approach

The iliofemoral approach is a modification of the Smith-Petersen approach, which was described in 1917.<sup>3</sup> In contrast to the Smith-Petersen approach, the iliofemoral approach exposes the iliac fossa instead of the lateral bony surface of the ilium. Exposure is limited to the iliac crest, the cranial aspect of the anterior column and the cranial margin of the iliopectineal eminence.<sup>4</sup> The iliofemoral approach is suitable for the reduction and fixation of isolated fractures of the anterior column or anterior wall of the acetabulum.

The patient is positioned supine on a radiolucent table with the ipsilateral leg draped free into the surgical field. The iliac crest, the ASIS and the area in between the sartorius and tensor fasciae latae muscles serve as landmarks. The skin incision runs from the lateral aspect of the iliac crest to the ASIS and continues between the sartorius and tensor fasciae latae to a point approximately 15 centimetres distal to the ASIS.

As for the first window of the ilioinguinal approach, the insertion of the external oblique muscle is released from the iliac crest and the iliac fossa is exposed. At the ASIS, the inguinal ligament, together with the origin of the sartorius muscle, is mobilized and either dissected or released through an osteotomy, which facilitates refixation.

The inguinal ligament and the sartorius muscle are retracted medially. Because of the iliopsoas muscle, the possible exposure to the medial side is limited, so that only the iliopectineal eminence can be reached. In order to visualize the joint, the distal part of the approach can be extended equivalent to the anterior approach to the hip. By releasing the origin of the adductor muscles, the lateral surface of the ilium can be visualized as originally described by Smith-Petersen. However, this extension will not be sufficient to address the posterior column or posterior wall.

For closure, after placement of drains, a thorough refixation of the rectus femoris muscle at the anterior inferior iliac spine and the joint capsule is performed. The osteotomized ASIS is refixed using either a screw or transosseous sutures. Comparable to the closure of the first window of the ilioinguinal approach, the fascia of the abdominal wall is reattached to the iliac crest. Distally, the fascia at the level of the thigh is closed before wound closure is completed using subcutaneous and skin sutures.

## Intrapelvic approaches

Particularly taking into account the invasiveness of classic approaches to the acetabulum and the rising number of elderly patients with fractures of the acetabulum, there has been a trend over recent years to establish modified and less invasive surgical approaches for stabilization of the acetabulum. Hereafter, the two most common modified anterior approaches to the acetabulum shall be explained.

### *Modified Stoppa approach*

In 1973, Stoppa et al described an extension of the Pfannenstiel incision to perform hernia repair, which included a detachment of the rectus abdominis muscle attachment from the pubic bone.<sup>5</sup> Later on, Hirvensalo et al modified the approach Stoppa had described and thereby extended the indication to stabilization of the antero-lateral aspect of the pelvis.<sup>6</sup> Furthermore, the modified Stoppa approach can be used to reduce and stabilize anterior fracture modifications of the acetabulum. In particular, it offers a good exposure of the quadrilateral surface. It has been demonstrated that using the modified Stoppa approach, about 80% of the true pelvis, including the complete pelvic brim, can be exposed. Additionally, visualization up to two centimetres above the pelvic brim is possible.<sup>7</sup>

For the modified Stoppa approach, the patient is placed supine on a radiolucent table. As for the ilioinguinal approach, the ipsilateral leg is draped free to allow for movement of the hip joint and access to the proximal femur in order to insert Schanz screws for applying lateral traction. The position of the surgeon is on the contralateral side of the injury.

Landmarks are the pubic symphysis and the ASIS. The incision is seven to ten centimetres long and extends asymmetrically from the pubic symphysis to the side of the injury and runs about two centimetres cranial to the symphysis. After dissection of the subcutaneous fat and identification of the linea alba, it is incised longitudinally. Both bellies of the rectus abdominis muscle are retracted. As the approach must stay in the preperitoneal space, care must be taken not to open the peritoneum, which can be challenging, especially in the proximal part of the

approach. On the injured side, the rectus muscle is partially detached from the pubic bone to facilitate further lateral retraction. After identification of the pecten ossis pubis, blunt dissection is advanced laterally. Care must be taken to identify and ligate the aforementioned corona mortis vessels above the fascia where necessary. After this, the strong periosteum of the pubic bone can be opened sharply to allow for further blunt dissection. The dissection is carried laterally along the pubic bone to reach the pelvic brim. Advancing laterally, the iliopectineal fascia is dissected from the bone to enable elevation of the femoral vessels and nerve. The entire quadrilateral surface can be exposed through elevation of the obturator vessels and nerve and subperiosteal elevation of the internal obturator muscle. Great care must be taken not to injure the external iliac vessels when placing retractors on the iliac side of the pelvic ring.

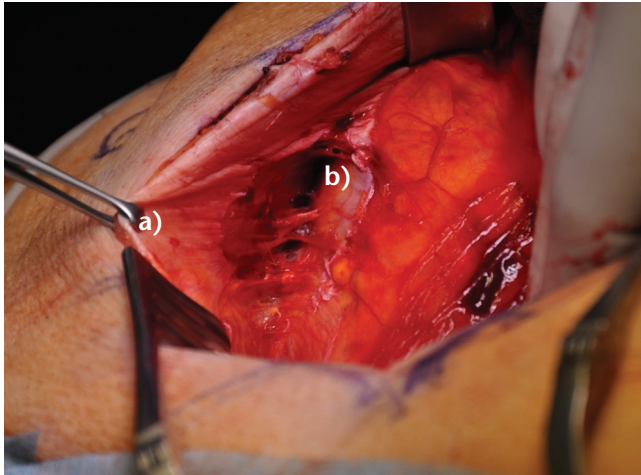
The modified Stoppa approach is often supplemented by the abovementioned first window of the ilioinguinal approach. This extends the visualization of the iliac fossa and gives more options for the reduction of the innominate bone. Another possibility to extend the modified Stoppa approach is a digastric osteotomy of the ASIS.<sup>8,9</sup> However, this is not common in the authors' own practice.

For closure, the longitudinal incision in the rectus muscle and the more superficial tissues are carefully closed in layers. Great care must be taken to protect the urinary bladder and the peritoneum. If the first window of the ilioinguinal approach has been opened to extend the approach, the abdominal wall is reattached to the iliac crest in an overlapping way.

## Pararectus approach

In 2012, the Bernese Group published a modified anterior approach to the acetabulum, which they named the Pararectus approach.<sup>10</sup> The particularity of this approach lies in its excellent exposure of the quadrilateral surface. The Pararectus approach enables the surgeon to place and fix plates below the pelvic brim, which is very helpful when it comes to addressing a completely separated quadrilateral surface. It has been demonstrated that using the Pararectus approach, when compared to the modified Stoppa approach, a greater exposure of the false pelvis can be achieved.<sup>11</sup>

For the Pararectus approach, the patient is positioned supine on a radiolucent table and the leg of the injured side is draped free. The surgeon stands on the uninjured side of the patient. Landmarks for the incision are the umbilicus, the ASIS and the pubic symphysis. The skin incision refers to the lateral border of the rectus abdominis muscle and begins cranially at the point which divides a line between the umbilicus and the ASIS in the ratio of one



**Fig. 3** Pararectus approach. After incising the aponeurosis of the external oblique muscle, the anterior layer of the rectus sheath (a) is opened. The peritoneum (b) is retracted medially.

third (laterally) to two thirds (medially). The incision is continued in a slightly curved fashion distally and medially to the point which divides a line between the pubic symphysis and the ASIS in the ratio of one third (medially) and two thirds (laterally). If necessary, the incision can be extended cranially and caudally.

After dissection of the subcutaneous tissue, the aponeurosis of the external oblique muscle and the anterior layer of the rectus sheath are opened (Fig. 3) The fascia of the transversus abdominis muscle is incised longitudinally. Now, the epigastric vessels and the peritoneum as well as the spermatic cord / round ligament are identified. The peritoneum is carefully mobilized and retracted cranially and medially in order to continue blunt extraperitoneal dissection. After identification of the external iliac vessels, the iliopsoas muscle is undermined in the lateral aspect of the surgical field. At this stage, it is crucial to identify and preserve the ilioinguinal nerve, the femoral nerve and the genitofemoral and lateral cutaneous nerve. To expose the iliac fossa, the iliacus muscle is subperiosteally elevated. The iliopectineal fascia is incised and the pectineus muscle is mobilized. A potentially present corona mortis can be visualized and ligated at this stage. After identifying the obturator neurovascular bundle, it can be retracted medially together with the urinary bladder. The internal obturator muscle is then elevated by subperiosteal dissection and the infrapectineal bone can be exposed as far posterior as the sacroiliac joint.

For closure, taking care not to injure the peritoneum, a tight repair of the rectus and external oblique fasciae is carried out in order to avoid postoperative herniation. Further wound closure is carried out in multiple layers of subcutaneous and skin sutures.

## Conclusions

### *Which one to choose?*

The ilioinguinal approach remains the standard anterior approach to the acetabulum. It should be mastered by all surgeons conducting acetabular surgery before thinking about the described modifications and reduced exposures. When performed correctly, it is still a very atraumatic approach, respecting interstructural planes and usually provides a fast recovery for patients. It provides a good exposure of the anterior parts of the acetabulum and allows for palpation of additional regions to check the result of reduction manoeuvres. Its limitations are the limited visualization of the quadrilateral plate and the missing possibility to fix infrapectineal implants.

The iliofemoral approach, as well as the Smith-Petersen approach, provides limited exposure of the acetabulum and should therefore only be chosen to address isolated fractures of either the anterior column or the anterior wall. Because of the limited exposure and a significant risk of heterotopic ossification, neither the iliofemoral, nor the Smith-Petersen approach are routinely used in the authors' practice.

The modified Stoppa approach provides a good exposure of the inferior parts of the anterior column and the quadrilateral surface. Infrapectineal placement and fixation of plates is possible through the modified Stoppa approach. However, if a significant dislocation of the innominate bone necessitates extensive reduction manoeuvres, the modified Stoppa approach will most likely have to be supplemented by the first window of an ilioinguinal approach.

The Pararectus approach is a good option for acetabular fractures with a completely mobile quadrilateral plate fragment, as the visualization and accessibility of the area below the pelvic brim is excellent. However, the orthopaedic trauma surgeon will usually need some time to become used to the Pararectus approach because of the unfamiliar perspective and wide exposure of vessels and nerves within the surgical field.<sup>10</sup> When not performed exactly, the Pararectus approach bears a considerable risk of extended blood loss.

### **AUTHOR INFORMATION**

Department of Trauma, Hand and Reconstructive Surgery, Saarland University Hospital, Homburg, Germany.

\* Tim Pohlemann and Steven C. Herath contributed equally to this paper.

Correspondence should be sent to: Tim Pohlemann, Department of Trauma, Hand and Reconstructive Surgery, Saarland University Hospital, D-66421 Homburg/Saar, Germany.

Email: tim.pohlemann@uks.eu

**ICMJE CONFLICT OF INTEREST STATEMENT**

TP reports unrestricted research grants from AO Foundation, Werner, Siemens Stiftung, outside the submitted work.

The other authors declare no conflict of interest relevant to this work.

**FUNDING STATEMENT**

No benefits in any form have been received or will be received from a commercial party related directly or indirectly to the subject of this article.

**LICENCE**

©2020 The author(s)

This article is distributed under the terms of the Creative Commons Attribution-Non Commercial 4.0 International (CC BY-NC 4.0) licence (<https://creativecommons.org/licenses/by-nc/4.0/>) which permits non-commercial use, reproduction and distribution of the work without further permission provided the original work is attributed.

**REFERENCES**

1. **Judet R, Judet J, Letournel E.** Fractures of the acetabulum: classification and surgical approaches for open reduction. Preliminary report. *J Bone Joint Surg Am* 1964;46:1615–1646.
2. **White G, Kanakaris NK, Faour O, Valverde JA, Martin MA, Giannoudis PV.** Quadrilateral plate fractures of the acetabulum: an update. *Injury* 2013;44:159–167.
3. **Smith-Petersen M.** A new supra-articular subperiosteal approach to the hip joint. *Am J Orthop Surg (Phila Pa)* 1917;15:592–595.

4. **Tscherne H, Pohlemann T.** *Tscherne Unfallchirurgie: Becken und Acetabulum.* Berlin: Springer, 1998.
5. **Stoppa R, Petit J, Abourachid H, et al.** [Original procedure of groin hernia repair: interposition without fixation of Dacron tulle prosthesis by subperitoneal median approach]. *Chirurgie* 1973;99:119–123.
6. **Hirvensalo E, Lindahl J, Böstman O.** A new approach to the internal fixation of unstable pelvic fractures. *Clin Orthop Relat Res* 1993;297:28–32.
7. **Bible JE, Choxi AA, Kadakia RJ, Evans JM, Mir HR.** Quantification of bony pelvic exposure through the modified Stoppa approach. *J Orthop Trauma* 2014;28:320–323.
8. **Sagi HC, Bolhofner B.** Osteotomy of the anterior superior iliac spine as an adjunct to improve access and visualization through the lateral window. *J Orthop Trauma* 2015;29:e266–e269.
9. **Sheean AJ, Hurley RK, Collinge CA, Beltran MJ.** Increased anterior column exposure using the anterior intrapelvic approach combined with an anterior superior iliac spine osteotomy: a cadaveric study. *J Orthop Trauma* 2017;31:565–569.
10. **Keel MJ, Ecker TM, Cullmann JL, et al.** The Pararectus approach for anterior intrapelvic management of acetabular fractures: an anatomical study and clinical evaluation. *J Bone Joint Surg Br* 2012;94:405–411.
11. **Bastian JD, Savic M, Cullmann JL, Zech WD, Djonov V, Keel MJ.** Surgical exposures and options for instrumentation in acetabular fracture fixation: Pararectus approach versus the modified Stoppa. *Injury* 2016;47:695–701.