



Case report

Adult small bowel obstruction due to congenital peritoneal belt: A case report

D. Hadded^a, M. Mesbahi^{a,*}, A. Zouaghi^a, M. Marouani^b, C. Chamekhi^b, A. Ben Maamer^a

^a Department of General Surgery at Habib, Thameur Hospital, Tunisia

^b Radiology Department at Habib Thameur Hospital, Tunisia

ARTICLE INFO

Keywords:

Congenital band
Intestinal obstruction
Small bowel obstruction
Virgin abdomen

ABSTRACT

Introduction: Peritoneal bands on the virgin abdomen are an extremely rare etiology of occlusive syndrome. Congenital bridles can be in 0.7 to 2% a cause of small bowel obstruction.

Presentation of case: We report a case of a 21-year-old woman who was admitted with symptoms of bowel obstruction. The patient had no surgical or traumatic history. Laparotomy was done and the findings showed a congenital belt extending from the antimesenteric wall of the ileum to the vesical dome, causing bowel strangulation. Band's ligation proceeded smoothly after the operation.

Discussion: Congenital flanges present an uncommon situation. These bands are usually difficult to classify and define. They are usually observed in childhood. Therefore, this situation represents an unusual surgical problem in diagnosing clinically unexpected elderly patients.

Conclusion: Congenital or spontaneous flanges are an uncommon cause of occlusion, which presents a challenging diagnosis. Exploratory laparotomy or laparoscopy is mandatory.

1. Introduction

Acute intestinal obstruction is a frequent emergency. It can be due to functional disorders or mechanical causes such as obstruction or strangulation, which are frequently due to post-operative flanges [1]. Some patients with no medical history of open surgery can develop adhesions, this can be explained by congenital, or spontaneous, or initial flanges [1]. The congenital band is an extreme cause of bowel obstruction in adults [2,3]. We report a case of a 20-year-old patient who had no prior surgical history and suffered acute intestinal obstruction due to a congenital belt. This work has been reported concerning the SCARE 2020 criteria [4].

2. Case report

A 21-year-old woman was admitted to our surgery department with a 1-day history of abdominal fullness, left iliac fossa, and vomiting. She had a history of pleural lymphoma for which systemic chemotherapy is undergone. She had no history of abdominal surgery or abdominal trauma, and the patient denied any allergies or drug history. Physical examination revealed tenderness over the left iliac fossa, a temperature

of 37.0 °C, a blood pressure of 100/60 mm Hg, and a pulse rate of 120 beats/min. Laboratory data showed that the white blood cell (WBC) count was 13,100/mL, and the CRP level was 75 mg/l.

Abdominal plain X-ray film showed an ileus pattern with distended small bowel loops and multiple air-fluid levels (Fig. 1). A contrast-enhanced CT of the abdomen showed: Distention of small bowel loops with a transition point in the left iliac fossa with U-shaped ileal loop without 'whirl sign' (Fig. 2A), Pneumoperitoneum in perihepatic and in the left iliac fossa (Fig. 2B), Peritoneal thickening and fat stranding around the transitional point (Fig. 2C). However, The normal bowel wall enhancement was preserved, and there was Moderated free intraperitoneal fluid effusion. CT had concluded of an aspect of small bowel volvulus in the left iliac fossa which is complicated by small bowel perforation and localized peritonitis.

She underwent surgery after initial treatment with electrolyte supplements, intravenous fluids, and nasogastric suction.

A laparotomy was performed in our surgical department at Habib Thameur Hospital and revealed: localized purulent effusion, Distended small bowel loops with swelling, and hyperemic change of bowel wall (Fig. 3A). There was a band extending from the vesical dome (Fig. 3B) to the mesentery of the ileum causing volvulus and strangulation (Fig. 3C)

* Corresponding author.

E-mail address: amar.mesbahi@gmail.com (M. Mesbahi).

<https://doi.org/10.1016/j.ijscr.2021.106016>

Received 11 April 2021; Received in revised form 22 May 2021; Accepted 22 May 2021

Available online 26 May 2021

2210-2612/© 2021 Published by Elsevier Ltd on behalf of IJS Publishing Group Ltd. This is an open access article under the CC BY-NC-ND license

(<http://creativecommons.org/licenses/by-nc-nd/4.0/>).

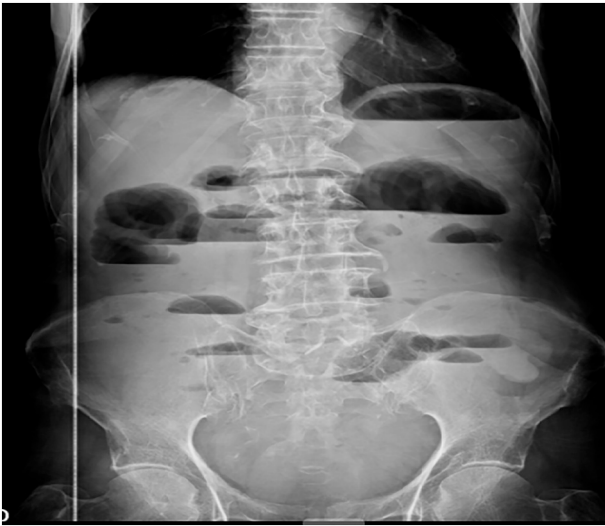

Fig. 1. Abdominal plain X-ray film: an ileus pattern with distended small bowel loops and multiple air-fluid levels.

of the entrapped bowel loop which was perforated (Fig. 3D). The band was ligated and divided, segmental resection carrying the perforated segment of the small bowel with manual grelogrelic anastomosis. The patient reported being satisfied with the intervention, and the post-operative course was uneventful. Pathologic analysis revealed necrosis in the segment resected. Since the operation, the patient has been asymptomatic.

3. Discussion

Congenital peritoneal bands are not common in adults, they cause 3% of intestinal obstruction. They are defined as intraperitoneal adhesions not related to abdominal procedures [5].

These bands are difficult to classify and define [3]. Referring to Lorimier there are two types of congenital adhesions due to the involution of the omphalo-mesenteric duct or omental malformations which are called Ladd flanges and associated generally with other congenital abnormalities [1]. In no one of these situations, we can concern adhesions as initial or spontaneous bands [1].

Obstruction causing by these bands explaining by the compression or the collapse of the intestines between the band and the mesentery or any other organ [5,6].

There are many sites of obstruction due to bands, referring to the literature, Akgur et al. reported eight sites of bands: Between the right colon and ileum, between Treitz angle and terminal ileum, Between the right lobe of the liver and the terminal ileum, and right lobe of the liver and right colon [7]. Bands site has not any effect on clinical manifestations or management [5].

Symptoms are the same as acute intestinal obstruction, which leads to miss diagnosis [6].

There are no specific complementary tests to diagnose bowel obstruction due to congenital bands, so that imaging tests are not useful, and may cause management delay of bowel obstruction [5].

X-ray of the abdomen without preparation is the gold standard to confirm bowel obstruction which demonstrated: bowel distension, hydro-air levels, or sub-diaphragmatic free air which signs perforation [1], but it can be also normal.

CT scan is important to confirm the diagnosis; it is recommended as the initial examination in suspected intestinal obstruction and may specify location, etiology, and severity signs of occlusion such as parietal ischemia, peritonitis [1,5].

Management of these bands is based on surgical treatment consisting of flange's section, or resection of the responsible bowel associated with

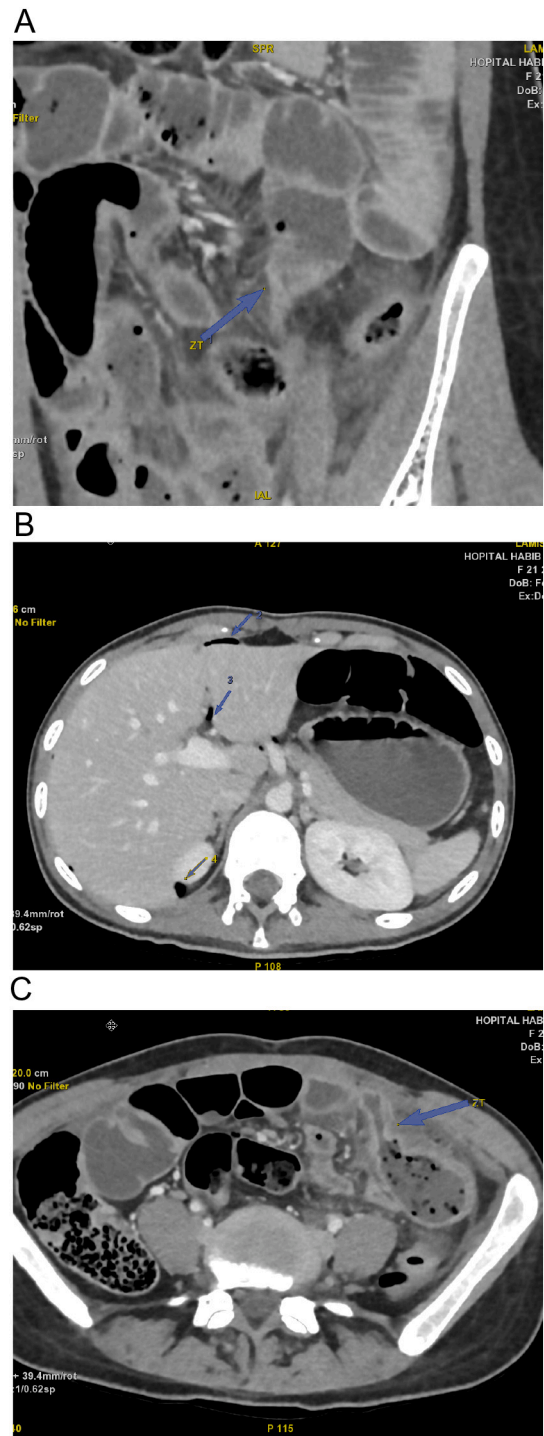


Fig. 2. A: Abdominal computed tomography: Distention of small bowel loops with a transition point and U-shaped ileal loop without 'whirl sign' B: Abdominal computed tomography: Pneumoperitoneum C: Abdominal computed tomography: Peritoneal thickening around the transitional point.

anastomosis as in our case [1].

Nowadays laparoscopy is much more preferred because of its safety, shorter operative time, shorter stay in hospital [2,6].

Surgery should not be delayed to avoid possible strangulation and necrosis of the small bowel [6].

Therefore, it is important to maintain high suspicion in patients presenting with small bowel obstruction symptoms, with no surgical history, keeping obstruction bowel due to bands as the differential

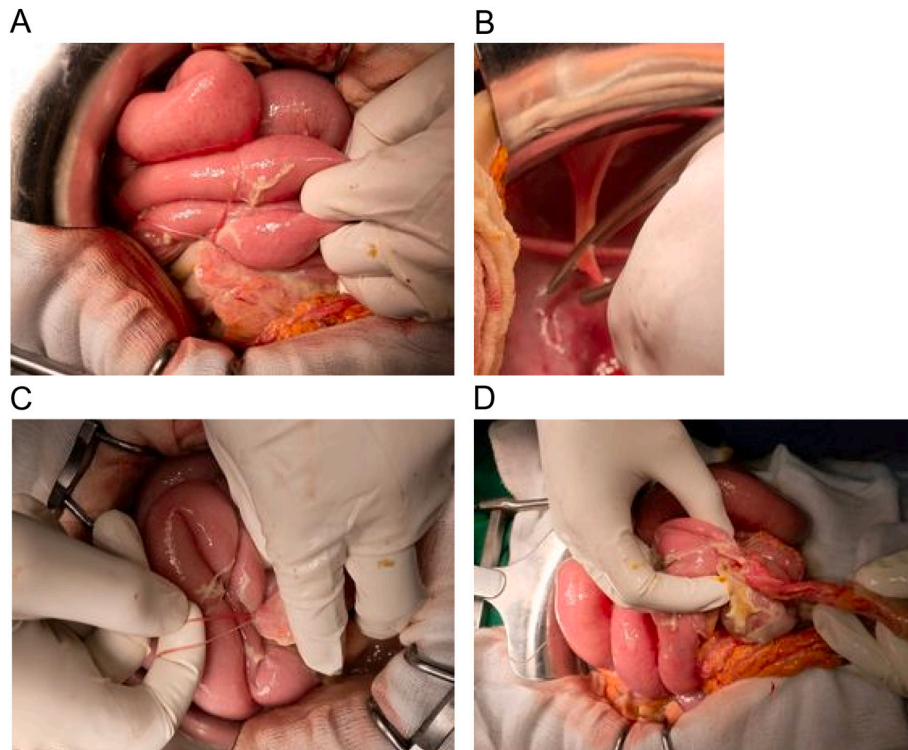


Fig. 3. A: Intra-operative clinical photograph: Distended small bowel loops B: Intra-operative clinical photograph: A band extending from the vesical dome C: Intra-operative clinical photograph: The ileal volvulus D: Intra-operative clinical photograph: The perforated small bowel.

diagnosis, and the only way to confirm it is by surgical procedure [6].

4. Conclusion

Occlusion due to congenital or spontaneous flanges is especially seen in patients without a history of laparotomy and having an occlusive syndrome. Only surgery can confirm diagnoses and avoid complications such as strangulation and bowel gangrene.

Funding

None.

Compliance with ethical standards

The patient has provided both verbal and written consent for the publication of This article. It was made sure that his identity will be kept a secret at all levels.

Consent

Written informed consent was taken from the patient regarding the publication of this case report and accompanying images. It was made sure that his identity will be kept a secret at all levels. A copy of a written request is available for review if requested.

CRedit authorship contribution statement

All authors were involved in the researching, writing, and editing of the manuscript.

Research registration

Not applicable.

Guarantor

Meryam Mesbahi.

Declaration of competing interest

The authors declare no competing interest.

Acknowledgments

There were no acknowledgments to mention it.

References

- [1] O. Ekuke, M. Lhaine, H. El Bouhaddouti, Occlusion of the small bowel on a virgin abdomen: case report, *J. Surg. Med.* 2 (3) (2018) 399–400.
- [2] M.I.E. Mouzan, Mofleh IAA, *Saudi J. Gastroenterol.* 14 (1) (2008) 5.
- [3] S. Sozen, S. Emir, F.M. Yazar, H.B. Altinsoy, O. Topuz, U.E. Vurdem, et al., Small bowel obstruction due to anomalous congenital peritoneal bands – case series in adults, *Bratisl. Med. J.* 113 (03) (2012) 186–189.
- [4] R.A. Agha, T. Franchi, C. Sohrabi, G. Mathew, A. Kerwan, A. Thoma, et al., The SCARE 2020 guideline: updating consensus surgical CAse REport (SCARE) guidelines, *Int. J. Surg.* 84 (2020) 226–230 (déc).
- [5] K.-H. Yang, T.-B. Lee, S.-H. Lee, S.-H. Kim, Y.-H. Cho, H.-Y. Kim, Congenital adhesion band causing small bowel obstruction: what's the difference in various age groups, pediatric and adult patients? *BMC Surg.* 16 (1) (2016) 79 (déc).
- [6] G. Nicolas, T. Kfoury, R. Shimlati, E. Koury, M. Tohme, E. Gharios, et al., Diagnosis and treatment of small bowel strangulation due to congenital band: three cases of congenital band in adults lacking a history of trauma or surgery, *Am. J. Case Rep.* 17 (7 oct 2016) 712–719.
- [7] F.M. Akgür, F. Cahit Tanyel, N. Büyükpamukçu, A. Hiçsönmez, Anomalous congenital bands causing intestinal obstruction in children, *Eur. J. Pediatr. Surg.* 27 (4) (1992) 471–473 (avr).