

Received: 2019.01.01
Accepted: 2019.01.30
Published: 2019.02.19

Glottic Obstruction from Fibroepithelial Polyp

Authors' Contribution:
Study Design A
Data Collection B
Statistical Analysis C
Data Interpretation D
Manuscript Preparation E
Literature Search F
Funds Collection G

ABDEF 1 **Joe Jabbour**
ABDEF 2 **James R. Chappell**
AB 1 **Michael Busby**
AE 2 **Nathan W. McCubbery**
E 2 **Daniel F. Brown**
E 3 **Serena J.K. Park**
ADE 1 **John G. O'Neill**

1 Department of Otolaryngology, The Tweed Hospital, Tweed Heads, NSW, Australia
2 Department of Anaesthetics, The Tweed Hospital, Tweed Heads, NSW, Australia
3 Department of Pathology, The Tweed Hospital, Tweed Heads, NSW, Australia

Corresponding Author: Joe Jabbour, e-mail: joejabbour@icloud.com
Conflict of interest: None declared

Patient: Male, 39
Final Diagnosis: Pharyngeal fibroepithelial polyp
Symptoms: Dysphagia • stridor
Medication: —
Clinical Procedure: Excision of pharyngeal fibroepithelial polyp
Specialty: Otolaryngology

Objective: Rare disease
Background: Fibroepithelial polyps are benign lesions of mesodermal origin, which have been reported in the head and neck area. The aim of this study is to describe the management of an oropharyngeal fibroepithelial polyp causing stridor.
Case Report: A 39-year-old male presented with 24 hours of stridor and dysphagia. Flexible laryngoscopy revealed a pedunculated sessile polyp on the posterior oropharynx. The mass was excised using bipolar diathermy and histopathology revealed a fibroepithelial polyp. The differential diagnoses for stridor are extensive. Although uncommon, a fibroepithelial polyp should be considered.
Conclusions: We present a rare case of a fibroepithelial polyp causing stridor and imminent airway obstruction. We recommend the use of Spontaneous Respiration using IntraVenous anaesthesia and High-flow nasal oxygen (STRIVE Hi) for general anaesthesia and resection of pharyngeal polyps.

MeSH Keywords: Adult • Glottis • Neoplasms, Fibroepithelial • Polyps

Full-text PDF: <https://www.amjcaserep.com/abstract/index/idArt/914907>

1282 1 2 18



Background

Fibroepithelial polyps are benign lesions of mesodermal origin, which have been reported in the head and neck area [1]. Usually, the polyp is an incidental finding on the skin of the neck, trunk, or face. This benign and nonspecific growth pattern is also known as a fibroma or acrochordon. Infrequently, it is found within the genitourinary system or bronchus [2–4]. Clinical presentation is usually indolent; a patient with a pharyngeal fibroepithelial polyp usually presents with dyspnoea, choking, snoring, and sleep-disordered breathing. However, if they present in the airway, they can cause obstruction and subsequent respiratory distress.

At present and to the best of our knowledge, there are no published reports of fibroepithelial polyps in the pharynx presenting with ball-valving within the glottis. However, there are 2 case reports of fibroepithelial polyps on the epiglottis and in the piriform fossa [5,6]. Therefore, we present this rare case and present an updated review of the literature of fibroepithelial polyps occurring within the head and neck area. A discussion of our approach to airway management in this case is also included.

Case Report

A 39-year-old man presented to the emergency department with stridor. Clinical history revealed coughing, choking, and spluttering out of food over the last 48 hours. There were no coryzal symptoms or fevers noted. Of note, the patient had trisomy 21. He was also obese and had hypothyroidism. Family history was unremarkable.

Physical examination revealed increased work of breathing, stridor, and tachypnoea. The otologic and nasal exams were

normal. On flexible laryngoscopy there was a pedunculated lesion attached to the right posterior pharyngeal wall causing ball-valving into the glottis on inspiration and expiration (Figure 1).

Anaesthetic management

Positive pressure ventilation via a face mask was relatively contraindicated as it may have resulted in complete airway obstruction via forcing the lesion irreversibly into the glottis via a positive pressure gradient [7]. A spontaneously breathing induction technique was used, thereby maintaining positive intrathoracic pressure during expiration, which favors relief of the obstruction. A decision was made to proceed with endotracheal intubation via a spontaneously breathing propofol TIVA (total intravenous anaesthesia) technique with HFNP, based on the STRIVE Hi method described by Booth et al. [8].

With the patient in a reverse Trendelenburg position and HFNP *in situ*, propofol TIVA was commenced via an infusion pump using the Marsh Model. The glottis was then sprayed with 2 aliquots of 3 mL of 1% lignocaine before the laryngoscope was withdrawn and propofol up-titration was continued. At an effect site of 3.5 mcg/mL, laryngoscopy was successfully performed with the C-mac 4 blade. The intermittently obstructing lesion was again noted and the trachea was intubated at the appropriate phase of the respiratory cycle (when the glottis was unobstructed) with a size 6.0 microlaryngoscopy endotracheal tube. Intubation was performed 20–25 minutes after the propofol titration was commenced.

Surgical management

The lesion was causing intermittent obstruction of the upper airway and progression to further airway compromise was likely. Therefore, we proceeded to immediate surgical resection.

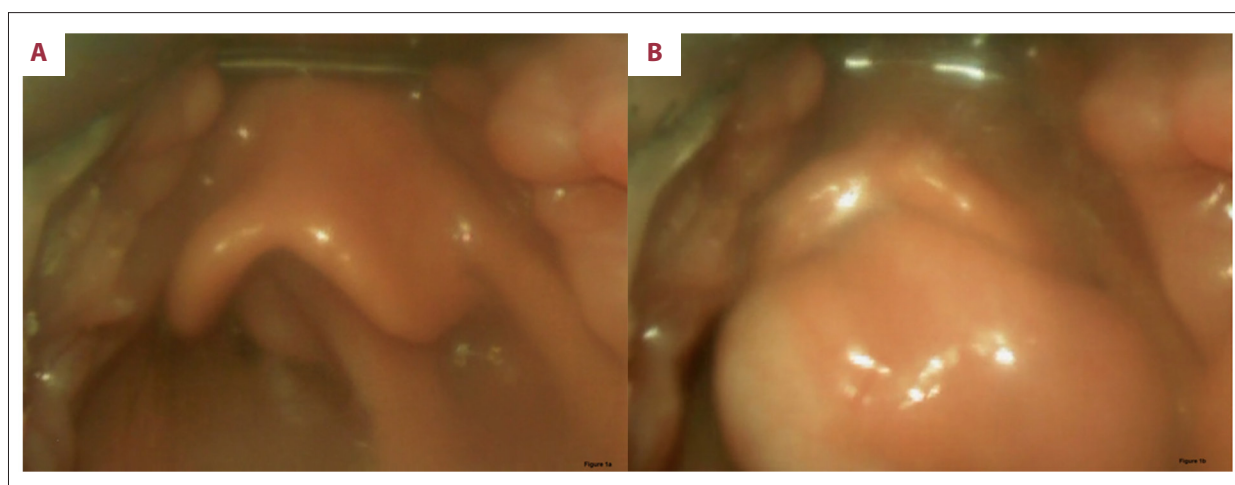


Figure 1. (A) Large pharyngeal mass moving into glottis with inspiration. (B) Large pharyngeal mass moving out of glottis with expiration.

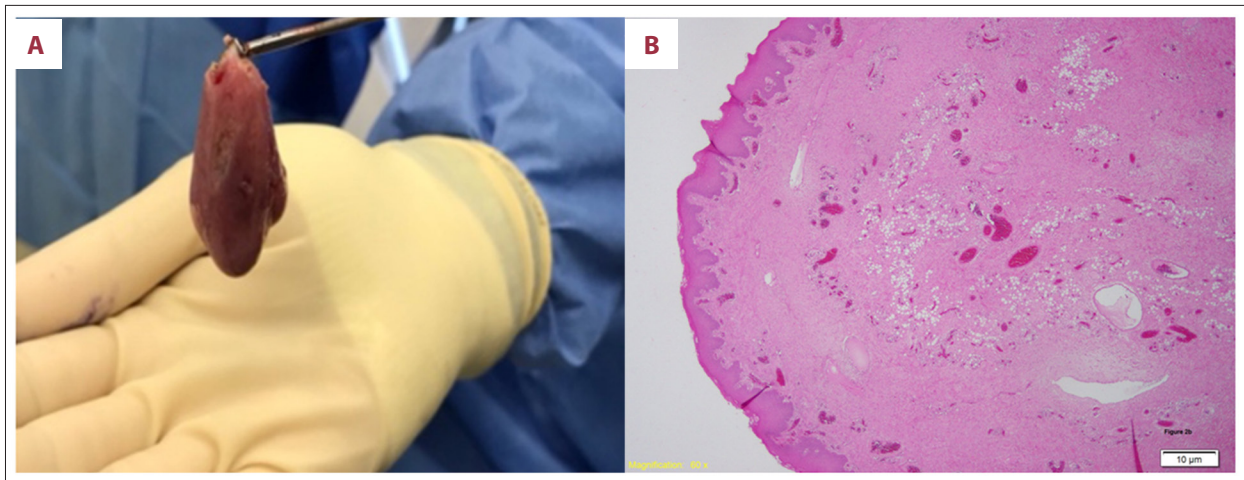


Figure 2. (A) Macroscopic view of pharyngeal polyp. (B) Microscopic hematoxylin and eosin stain of fibroepithelial polyp ($\times 60$ magnification). Focally ulcerated fibrolipomatous (fibroepithelial) regions are demonstrated.

Table 1. Summary of fibroepithelial polyps occurring independently within the head and neck area literature (excluding skin) since 2000.

Nature of specimen	Age/sex	Anaesthesia for surgery	Treatment	References
Tongue	42/M	Unknown	Excision	Lloyd et al. 2001 [1]
Piriform fossa	60/M	General	Excision	Mangar et al. 2004 [6]
Inferior nasal turbinate	69/F	General	Excision	Peric et al. 2009 [15]
Tonsil	33/M	Unknown	Tonsillectomy	Farboud et al. 2010 [16]
Nasopharynx	42/M	General	Excision	Jain and Shetty 2012 [17]
External auditory canal	16/F	Local	Excision	Tanaka et al. 2013 [18]
Epiglottis	11/F	General	Excision	Farzal et al. 2014 [5]

Emergency examination under general anaesthesia, as described above, was performed. Prior to endotracheal intubation and paralysis, a 3-cm pedunculated lesion arising from the right posterior pharyngeal wall was moving into the glottis on inspiration and moving outwards on expiration (Figure 1). The lesion was cauterized at its base using bipolar diathermy and sent for histopathological analysis. Postoperatively, the patient was monitored with 2 L/min supplemental oxygen via nasal prongs. This small overnight oxygen requirement was presumed due to atelectasis. He was discharged uneventfully the following day.

Pathology

Macroscopic examination revealed a papillomatous nodule that was 30 \times 22 \times 18 mm with a base 14 \times 7 mm (Figure 2A). Microscopic examination revealed a polypoid piece of lesional tissue composed of surface non-keratinised squamous epithelium over fibrovascular stroma. There was parakeratosis of surface squamous epithelium, but no definitive dysplasia.

The underlying fibrovascular stroma was collagenous and relatively cellular, with short spindle cells with minimal atypia in among the collagen bundles (Figure 2B). The immunohistochemistry was positive for CD34 and desmin. Immunohistochemistry was negative for beta-catenin, SMA, and STAT6. There was no evidence of malignancy.

Discussion

Fibroepithelial polyps are benign and indolent tumors of the head and neck region. One study reported the estimated prevalence of 12 per 1000 population, with an increased male predilection [9]. A literature review using Medline revealed 7 other reported cases in the literature (Table 1). The sites of occurrence are variable (e.g., ear, nasal cavity, oral cavity, oropharynx, and hypopharynx) and the majority were excised, with 1 case being resected with the tonsil. Similar to previous studies, there was no biopsy taken due to the imminent risk of airway compromise [5,6].

Histologically, fibroepithelial polyps are lined by squamous epithelium with the following 3 features: dyskeratosis, epithelial hyperplasia, and lymphocytic epitheliotropism. The stromal pattern consists of collagen, smooth muscle, and adipocytes [6]. The differential diagnoses for fibroepithelial polyps include angiofibroma and solitary fibrous tumor. Lack of nuclear positivity for beta-catenin and STAT6 immunohistochemistry rules out angiofibroma and solitary fibrous tumor, respectively.

Airway management of intermittent ball valve lesions causing airway occlusion and stridor requires a specialized management plan [10]. Differential diagnoses for stridor can be classified into 3 main categories: 1) anatomic (complete tracheal ring, laryngeal cyst/web, laryngeal cancer, subglottic hemangioma, subglottic stenosis, vascular rings, and vocal cord/s paralysis; 2) infective (epiglottitis, infective mononucleosis, papillomatosis, peritonsillar abscess, retropharyngeal abscess, and tracheitis; and 3) other (anaphylaxis, angioedema, and foreign body). Factors contributing to total airway obstruction on induction of general anaesthesia include loss of spontaneous ventilation, flaccid hypopharyngeal tone, initiation of positive pressure ventilation, and trisomy 21 facies. Complex airway management can be aided with videolaryngoscopy (VL) [11,12]. The presence of both a surgeon and an anaesthetist during endotracheal intubation allows for immediate surgical input if intubation fails, particularly with respect to front of neck airway rescue techniques such as tracheostomy. A rescue laryngeal mask airway in this scenario was unlikely to have been successful, as intermittent obstruction was occurring due to a supraglottic lesion.

A novel technique has recently been described: 'Spontaneous Respiration using IntraVenous anaesthesia and High-flow nasal oxygen' (STRIVE Hi) [8]. In a retrospective observational study of 30 cases (including 2 ball valve-obstructing lesions), STRIVE Hi was reported to preserve adequate oxygen saturation,

end-tidal carbon dioxide, and airway patency, with the margin of safety being increased by high-flow nasal oxygen (HFNO) [8]. The benefits of HFNO include: increased FiO₂, generation of positive airway pressure, improved respiratory mechanics, and reduced upper airway resistance [13,14]. STRIVE Hi was used in our case as an alternative to an inhalational induction, to maintain spontaneous respiration and therefore maintain upper airway patency to facilitate endotracheal intubation and allow excision of the polyp [8]. One particular advantage of the STRIVE Hi method in this case of an uncooperative intellectually impaired man, compared with other spontaneous breathing techniques, is that it minimizes patient contact during the induction phase. Nevertheless, we deviated from the STRIVE Hi technique by administering midazolam and fentanyl immediately prior to induction to improve compliance. To compensate for the effects of these agents and because the patient had trisomy 21, we set our initial propofol target concentration at 1.0 mcg/mL. This is significantly lower than that described in the STRIVE Hi technique, in which starting concentration targets are set at 2–3 mcg/mL [11]. Subsequently, in our case, no apnoea was observed and spontaneous ventilation was maintained throughout induction and laryngoscopy. The induction duration of 20–25 minutes was similar to the median induction time reported for STRIVE Hi (20 minutes).

Conclusions

We present a rare case of a fibroepithelial polyp causing stridor and imminent airway obstruction. We recommend the use of STRIVE Hi for general anaesthesia and surgical resection of pharyngeal polyps.

Conflict of interest

None.

References:

1. Lloyd S, Lloyd J, Dhillon R: Chondroid metaplasia in a fibroepithelial polyp of the tongue. *J Laryngol Otol*, 2001; 115: 681–82
2. Al-Awadhi NM, Al-Brahmi N, Ahmad MS, Yordanov E: Giant fibroepithelial polyp of the penis associated with long-term use of condom catheter. Case report and literature review. *Can J Urol*, 2007; 14: 3656–59
3. Nowak MA, Marzich CS, Scheetz KL, McElroy JB: Benign fibroepithelial polyps of the renal pelvis. *Arch Pathol Lab Med*, 1999; 123: 850–52
4. Amin PB, Baciewicz F: Benign fibroepithelial polyp arising in the bronchus: A case report and review of the literature. *Arch Surg*, 2009; 144: 1081–83
5. Farzal Z, Uluulp SO, Rakheja D: Fibroepithelial polyp of the epiglottis. *Am J Case Rep*, 2014; 15: 340–42
6. Mangar W, Jiang D, Lloyd RV: Acute presentation of a fibroepithelial pharyngeal polyp. *J Laryngol Otol*, 2004; 118: 727–29
7. Wong P, Wong J, Mok MU: Anaesthetic management of acute airway obstruction. *Singapore Med J*, 2016; 57: 110–17
8. Booth AWG, Vidhani K, Lee PK, Thomsett CM: Spontaneous Respiration using IntraVenous anaesthesia and Hi-flow nasal oxygen (STRIVE Hi) maintains oxygenation and airway patency during management of the obstructed airway: An observational study. *Br J Anaesth*, 2017; 118: 444–51
9. Bouquot JE, Gundlach KKH: Oral exophytic lesions in 23,616 white Americans over 35 years of age. *Oral Surg Oral Med Oral Pathol*, 1986; 62: 284–91
10. Dalmeida RE, Mayhew JF, Driscoll B, McLaughlin R: Total airway obstruction by papillomas during induction of general anesthesia. *Anesth Analg*, 1996; 83: 1332–34
11. Dimitriou VK, Zogogiannis ID, Liotiri DG: Awake tracheal intubation using the Airtraq laryngoscope: A case series. *Acta Anaesthesiol Scand*, 2009; 53: 964–67
12. Li SQ, Chen JL, Fu HB et al: Airway management in pediatric patients undergoing suspension laryngoscopic surgery for severe laryngeal obstruction caused by papillomatosis. *Pediatr Anesth*, 2010; 20: 1084–91
13. Roca O, Hernández G, Díaz-Lobato S et al: Current evidence for the effectiveness of heated and humidified high flow nasal cannula supportive therapy in adult patients with respiratory failure. *Crit Care*, 2016; 20: 109

14. Nishimura M: High-flow nasal cannula oxygen therapy in adults: Physiological benefits, indication, clinical benefits, and adverse effects. *Respir Care*, 2016; 61: 529–41
15. Perić A, Matković-Jožin S, Vukomanović-Đurđević B: Fibroepithelial polyp arising from the inferior nasal turbinate. *J Postgrad Med*, 2010; 55: 288–89
16. Farboud A, Trinidad A, Harris M, Pfeleiderer A: Fibroepithelial polyp of the tonsil: Case report of a rare, benign tonsillar lesion. *J Laryngol Otol*, 2010; 124: 111–12
17. Jain R, Shetty S: Nasopharyngeal fibroepithelial polyp in a New Zealand Maori man. *NZ Med J*, 2012; 125: 93–96
18. Tanaka N, Matsunobu T, Shiotani A: Fibroepithelial polyp of the external auditory canal: A case report and a literature review. *Case Rep Otolaryngol*, 2013; 2013: 818197