

Mucinous urachal adenocarcinoma: A potential nonfluorodeoxyglucose-avid pitfall on ¹⁸fluorine-fluorodeoxyglucose positron emission tomography/computed tomography

ABSTRACT

Mucinous adenocarcinoma of the urachal remnant is a nonurothelial malignancy that may be asymptomatic until locally advanced or metastatic. We describe a 37-year-old woman with invasive ductal breast carcinoma who underwent ¹⁸Fluorine-fluorodeoxyglucose (¹⁸F-FDG) positron emission tomography (PET) computed tomography (CT) demonstrating a non-FDG avid pelvic mass, initially suspected to represent a pedunculated uterine fibroid. Magnetic resonance imaging revealed a mixed solid-cystic mass separate from the uterus, suspicious for urachal neoplasm, confirmed as mucinous adenocarcinoma on histopathology. Urachal tumors may not be FDG-avid and represent a potential pitfall on FDG PET/CT.

Keywords: ¹⁸Fluorine-fluorodeoxyglucose, mucinous neoplasm, positron emission tomography/computed tomography, urachal adenocarcinoma

INTRODUCTION

Urachal cancer is a rare clinical entity usually identified as a midline, supravescical mass, with mixed solid-cystic components that may be difficult to confidently diagnose from other benign urachal pathology or more commonly encountered urothelial bladder neoplasms. Adenocarcinoma accounts for up to 80% of urachal tumors with over two-thirds producing mucin. On computed tomography (CT), urachal adenocarcinoma can demonstrate low-attenuation due to mucinous or necrotic components. Intrinsic calcification can be seen in the majority of cases with solid tumor demonstrating variable enhancement on postintravenous contrast imaging. On magnetic resonance imaging (MRI), solid components of urachal adenocarcinoma exhibit intermediate T2 signal with the presence of hyperintense T2 signal suggesting necrotic constituent, high mucin content, or cystic change.

CASE REPORT


A 37-year-old woman with a history of the right invasive ductal breast carcinoma surgically managed with right mastectomy and axillary lymph node dissection presented for follow-up. Laboratory hematological and serum biochemical analyses were unremarkable. ¹⁸Fluorine-fluorodeoxyglucose (¹⁸F-FDG) positron emission tomography (PET) CT was performed for the purpose of restaging. No hypermetabolic disease was demonstrated,

JEEBAN PAUL DAS^{1,2}, HEBERT ALBERTO VARGAS^{1,2}, GARY A. ULANER^{1,2}

¹Department of Radiology, Memorial Sloan Kettering Cancer Center, ²Department of Radiology, Weill Cornell Medical College, New York, USA

Address for correspondence: Dr. Jeeban Paul Das, Department of Radiology, Memorial Sloan Kettering Cancer Center, New York, USA.
E-mail: jeeban.paul.das@gmail.com

Submission: 26-Jul-2019, **Accepted:** 25-Oct-2019, **Published:** 14-Sep-2020

Access this article online	
Website: www.wjnm.org	Quick Response Code 
DOI: 10.4103/wjnm.WJNM_60_19	

This is an open access journal, and articles are distributed under the terms of the Creative Commons Attribution-NonCommercial-ShareAlike 4.0 License, which allows others to remix, tweak, and build upon the work non-commercially, as long as appropriate credit is given and the new creations are licensed under the identical terms.

For reprints contact: WKHLRPMedknow_reprints@wolterskluwer.com

How to cite this article: Das JP, Vargas HA, Ulaner GA. Mucinous urachal adenocarcinoma: A potential nonfluorodeoxyglucose-avid pitfall on ¹⁸fluorine-fluorodeoxyglucose positron emission tomography/computed tomography. World J Nucl Med 2020;19:432-4.

however, a calcified, non-FDG-avid pelvic lesion was revealed, possibly representing a subserosal pedunculated partially calcified uterine leiomyoma [Figure 1]. Following multidisciplinary discussion, further cross-sectional imaging was considered.

Subsequently performed pelvic MRI demonstrated a well-defined, multilobulated, predominantly T2 hyperintense mass arising from the anterosuperior bladder dome, extending into the space of Retzius suspicious for a primary mucinous neoplasm [Figure 2]. Percutaneous CT-guided biopsy of the mass was performed. Histopathology showed the presence of invasive adenocarcinoma with mucinous features invading into the lamina propria with no evidence of urothelial component consistent with urachal mucinous adenocarcinoma. Immunohistochemistry was positive for CK7 and CK20 and negative for GATA3.

The partial bladder dome cystectomy and excision of the urachus and umbilicus were performed. The final Sheldon stage was T3N0.

DISCUSSION

The urachus is a fibrous cord extending from the anterosuperior bladder dome to umbilicus that obliterates during normal fetal development. Incomplete obliteration of this channel can result in persistent urachal pathology. Urachal adenocarcinoma, a rare nonurothelial tumor accounting for <0.5% of bladder cancers, can develop in this vestigial remnant and occurs almost twice as common in men with a median age of onset between 45 and 56 years.^[1,2] Urachal adenocarcinoma can

present with nonspecific lower urinary tract symptoms with almost 30% of patients present with locally advanced or distant metastatic disease at the time of the initial investigation.^[2,3]

The current series have demonstrated a 10-year survival rate of up to 49% with surgical treatment. Salvage chemotherapeutic agents are rarely effective with a <10% success rate for patients with systemic metastases, which occur most commonly in the liver and lung.^[1-3]

Urachal remnant pathology demonstrates a characteristic location in the midline, superior to the bladder dome, extending into Retzius space toward the umbilicus. On CT, urachal adenocarcinoma usually exhibits central or peripheral calcifications, seen in up to 70% of cases. Urachal cancer may contain both solid and cystic components, demonstrating low attenuation and heterogeneous enhancement on postcontrast imaging. Potentially mimicking other benign and malignant pelvic pathology.^[2-5]

Notably, the majority (69%) of urachal adenocarcinomas are mucin-producing.^[2,5] Although FDG PET/CT may be helpful in diagnosing urachal adenocarcinoma,^[6-8] it is important to highlight that up to 59% of mucinous malignancies demonstrate low FDG avidity because of tumor hypocellularity compared to other nonmucinous tumor types, which may limit the diagnostic efficacy of FDG PET/CT.^[9,10]

This case highlights the challenge of differentiating mucinous urachal neoplasms from other benign low-FDG avid pelvic pathology on FDG PET/CT.

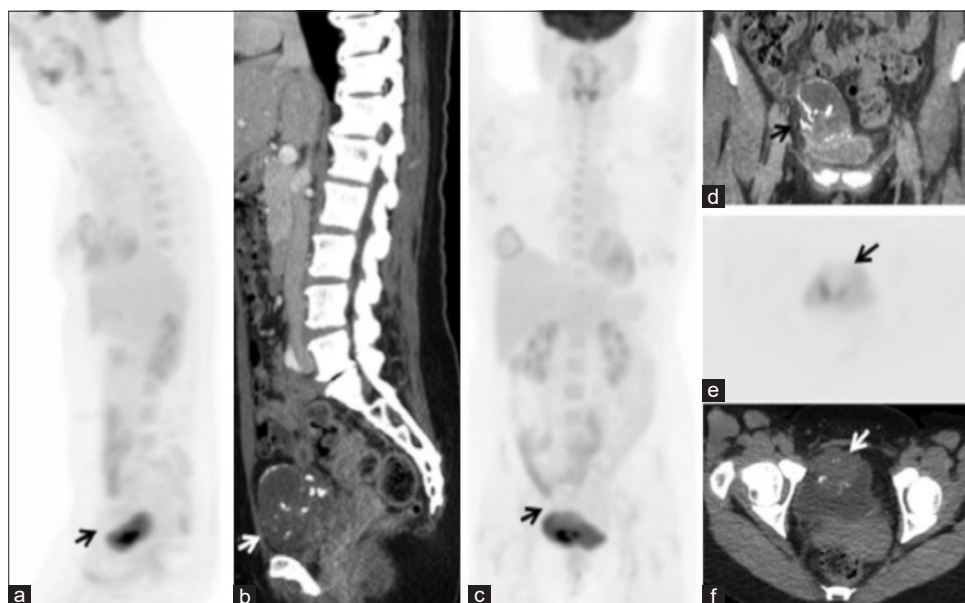


Figure 1: Sagittal positron emission tomography (a) and computed tomography (b) images, coronal positron emission tomography (c) and computed tomography (d) images, as well as axial positron emission tomography (e) and computed tomography (f) images, demonstrate a well-defined soft-tissue density (arrows) in the midline pelvis, superior to the bladder, exhibiting coarse central and peripheral calcification, and without abnormal fluorodeoxyglucose avidity

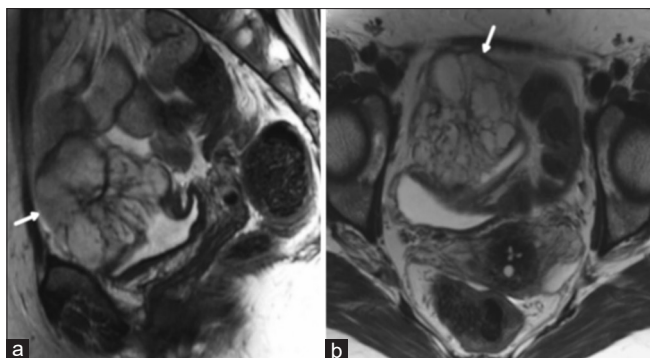


Figure 2: Sagittal (a) and axial (b) T2 weighted magnetic resonance imaging of the pelvis demonstrating a lobulated supravescical lesion (arrows) with heterogeneous hyperintense signal abnormality representing mucin

Physicians and PET readers should be aware of the limitations of FDG PET/CT in detecting mucinous tumors and consider further evaluation of non-FDG avid calcified pelvic pathology with additional cross-sectional imaging, such as MRI, to address the possibility of mucinous malignancy.

Declaration of patient consent

The authors certify that they have obtained all appropriate patient consent forms. In the form the patient(s) has/have given his/her/their consent for his/her/their images and other clinical information to be reported in the journal. The patients understand that their names and initials will not be published and due efforts will be made to conceal their identity, but anonymity cannot be guaranteed.

Financial support and sponsorship

This research was in part funded through the NIH/NCI Cancer Center Support Grant P30 CA008748.

Conflicts of interest

There are no conflicts of interest.

REFERENCES

1. Niedworok C, Panitz M, Szarvas T, Reis H, Reis AC, Szendrői A, *et al.* Urachal carcinoma of the bladder: Impact of clinical and immunohistochemical parameters on prognosis. *J Urol* 2016;195:1690-6.
2. Ashley RA, Inman BA, Sebo TJ, Leibovich BC, Blute ML, Kwon ED, *et al.* Urachal carcinoma: Clinicopathologic features and long-term outcomes of an aggressive malignancy. *Cancer* 2006;107:712-20.
3. Dhillon J, Liang Y, Kamat AM, Siefker-Radtke A, Dinney CP, Czerniak B, *et al.* Urachal carcinoma: A pathologic and clinical study of 46 cases. *Hum Pathol* 2015;46:1808-14.
4. Yu JS, Kim KW, Lee HJ, Lee YJ, Yoon CS, Kim MJ, *et al.* Urachal remnant diseases: Spectrum of CT and US findings. *Radiographics* 2001;21:451-61.
5. Parada Villavicencio C, Adam SZ, Nikolaidis P, Yaghmai V, Miller FH. Imaging of the urachus: Anomalies, complications, and mimics. *Radiographics* 2016;36:2049-63.
6. Guimarães MD, Bitencourt AG, Lima EN, Marchiori E. 18FDG PET/CT findings in the unusual urachal adenocarcinoma. *Clin Nucl Med* 2014;39:831-4.
7. Li X, Liu S, Yao S, Wang M. A rare case of urachal mucinous adenocarcinoma detected by 18F-FDG PET/CT. *Clin Nucl Med* 2015;40:282-5.
8. Yang G, Wang Z, Liu S, Wu F, Li D. A rare case of urachal carcinoma metastatic to thoracic vertebra detected by FDG PET/CT. *Clin Nucl Med* 2017;42:544-6.
9. Berger KL, Nicholson SA, Dehdashti F, Siegel BA. FDG PET evaluation of mucinous neoplasms: Correlation of FDG uptake with histopathologic features. *AJR Am J Roentgenol* 2000;174:1005-8.
10. Lakhani A, Khan SR, Bharwani N, Stewart V, Rockall AG, Khan S, *et al.* FDG PET/CT pitfalls in gynecologic and genitourinary oncologic imaging. *Radiographics* 2017;37:577-94.