



## CLINICAL ARTICLE

# Young's Modulus of Bilateral Infraspinus Tendon Measured in Different Postures by Shear Wave Elastography Before and After Exercise

Menglei Yu<sup>1</sup> , Jiayi Wu<sup>2</sup>, Jingyi Hou<sup>1</sup>, Yiyong Tang<sup>3</sup>, Fangqi Li<sup>1</sup>, Chuanhai Zhou, Qingyue Li<sup>1</sup>, Yi Long<sup>1</sup>, Congda Zhang<sup>1</sup>, Yuanhao Zhang<sup>1</sup>, Yamuhanmode Alike<sup>1</sup> , Bing Ou<sup>2</sup>, Rui Yang<sup>1</sup>

Department of <sup>1</sup>Sport Medicine and <sup>2</sup>Ultrasound, Sun Yat-sen Memorial Hospital of Sun Yat-sen University, Guangzhou and <sup>3</sup>Department of Orthopedics, The Eighth Affiliated Hospital, Sun Yat-sen University, Shenzhen, China

**Objective:** To investigate the Young's modulus value of infraspinus tendons using shear wave elastography (SWE) technique in normal adults, and to analyze the influence of gender, postures, exercise, and dominant side on Young's modulus of infraspinus tendons.

**Methods:** This is a prospective cross-sectional study. From January 2019 to July 2020, 14 healthy subjects were identified, including seven males and seven females aged between 24 to 34, with a mean age of  $27.67 \pm 3.08$  years. The Young's modulus of their infraspinus tendons was measured by two operators using SWE in neutral and maximum external rotation positions of both sides before exercise and the dominant side after exercise. The Young's modulus values in different sexes, different postures, before vs after exercise, and dominant vs non-dominant side were statistically analyzed.

**Results:** All 14 subjects completed the data collection process. The mean Young's modulus values of infraspinus tendon for dominant sides in neutral position were  $33.04 \pm 3.01$  kPa for males and  $28.76 \pm 3.09$  kPa for females. And for non-dominant sides in the neutral position, the values were  $33.02 \pm 2.38$  kPa for males and  $28.86 \pm 2.47$  kPa for females. In the maximum external rotation position, the values for dominant sides were  $50.19 \pm 4.86$  kPa for males and  $42.79 \pm 4.44$  kPa for females, and for non-dominant sides were  $50.95 \pm 3.24$  kPa for males and  $42.42 \pm 3.66$  kPa for females. After exercise, the mean Young's modulus values of infraspinus tendon for dominant sides in neutral position were  $54.56 \pm 3.76$  kPa for males and  $46.66 \pm 5.99$  kPa for females. And for the maximum external rotation position, the values were  $59.13 \pm 3.78$  kPa for males and  $54.49 \pm 5.67$  kPa for females. The Young's modulus of infraspinus tendon in the neutral and maximum external rotation positions showed statistically significant differences in males and females, as well as before and after exercise ( $P < 0.05$ ). However, the difference in Young's modulus between the dominant and non-dominant sides was not statistically significant ( $P > 0.05$ ). Intergroup reliability between both operators was excellent ( $ICC > 0.85$ ).

**Conclusion:** There are gender-related differences and post-exercise increase in Young's modulus, yet such a difference cannot be witnessed between the dominant and non-dominant sides.

**Key words:** Infraspinus tendon; Shear wave elastography; Young's modulus value

**Address for correspondence:** Rui Yang, Department of Sport Medicine, Sun Yat-sen Memorial Hospital of Sun Yat-sen University, 107# Yanjiang Xi Road, Guangzhou, China 515000 Tel: 86-020-81332315; Fax: 86-020-81332199; Email: yangr@mail.sysu.edu.cn; Bing Ou, Department of Ultrasound, Sun Yat-sen Memorial Hospital of Sun Yat-sen University, 107# Yanjiang Xi Road, Guangzhou, China 515000 Tel: 86-020-81332516; Fax: 86-020-81332199; Email: oubing@mail.sysu.edu.cn

Menglei Yu and Jiayi Wu contributed equally to this work.

**Disclosure:** Each author certifies that he or she has no commercial associations (e.g. consultancies, stock ownership, equity interest, patent/licensing arrangements, etc.) that might pose a conflict of interest in connection with the submitted article.

Received 6 October 2020; accepted 18 February 2021

## Introduction

Shear Wave Elastography (SWE) is one of the new functional ultrasound techniques developed in recent years, which is the only test method that can objectively and quantitatively evaluate the Young's modulus<sup>1,2</sup>. At the same time, Young's modulus is a parameter commonly used in the expression of tissue elasticity<sup>3,4</sup>. The elasticity of tissue is often closely related to its functional state, and the detection of Young's modulus of tissue carries important clinical significance<sup>5-7</sup>. Using the acoustic radiation force of focused ultrasound beams, the supersonic shear imaging (SSI) technique generates shear waves. Using ultrafast ultrasound imaging, the shear wave propagation is measured, typically 1000 of frames per second. Then shear wave velocity (V) is measured on the acquired shear wave propagation movie. By considering the medium as elastic and homogeneous, the shear modulus ( $\mu$ ) given in kPa is deduced using the equation:  $\mu = \rho V^2$ , where  $\rho$  is the density (assuming  $\rho = 1000 \text{ kg m}^{-3}$ )<sup>2</sup>. Several studies have shown the SWE could be used to evaluate the normal and various traumatic and pathologic conditions of the tendons, muscles, peripheral nerves, ligaments and joints, as well as a few soft-tissue and bone masses or mass-like conditions<sup>4</sup>. And the SWE technique has been shown to provide reliable measurements of Young's modulus in a variety of resting muscles<sup>8</sup> and has also provided evidence of a strong linear relationship between muscle Young's modulus and muscle activity or electromyography activity levels<sup>9-11</sup>.

Recently, SWE has been used to assess the mechanical properties of the tendon in healthy volunteers<sup>12,13</sup>. Prior studies have identified a strong linear relationship between passive muscle tension and the shear elastic modulus measured by SWE *in vitro*<sup>4,14,15</sup>, and SWE has been utilized in many studies of skeletal muscle stretching<sup>16-19</sup>. However, as far as we are aware, no one else has focused on the Young's modulus measurement on shoulder tendon with SWE.

The shoulder is the most flexible joint in the human body. The mechanical properties of soft tissue structures around the shoulder joint are very important for its function. For example, patients with frozen shoulder, which is characterized by significant restriction of both active and passive shoulder motion, typically experience insidious shoulder stiffness. The infraspinatus tendon is one of the most important tendons around the shoulder, and its primary function is to rotate the shoulder joint externally. The chronic strain is one of the critical causes of soft tissue injury and changes in tendon, and Young's modulus affects its elasticity to a certain extent. In some disease states, the strength of the supraspinatus tendon can increase significantly, such as frozen shoulder<sup>20</sup>. The infraspinatus tendon is the shallowest part of the rotator cuff and is not easily obscured by other bony structures, which makes it easier to measure its Young's modulus using SWE compared with the supraspinatus and subscapular muscle. Previous studies showed that the technology of SWE could be applied to detect the Young's modulus value of a normal infraspinatus tendon and its fat<sup>18,20,21</sup>.

Therefore, it is indispensable to utilize a testing device to perform an objective evaluation of Young's modulus of muscle and tendon on the shoulder joint.

Short-term exercise can cause muscle and tendon fatigue, but regular and long-term exercise increases muscle and tendon inducing long-lasting adaptations<sup>22</sup>. Exercise leads to changes in the Young's modulus of muscle tendons, which in turn affects their function. Therefore, choosing the right intensity and duration of exercise is very important to achieve the purpose of exercise and avoid sports injuries. Monitoring the Young's modulus of muscles and tendons is a good indicator of judgment.

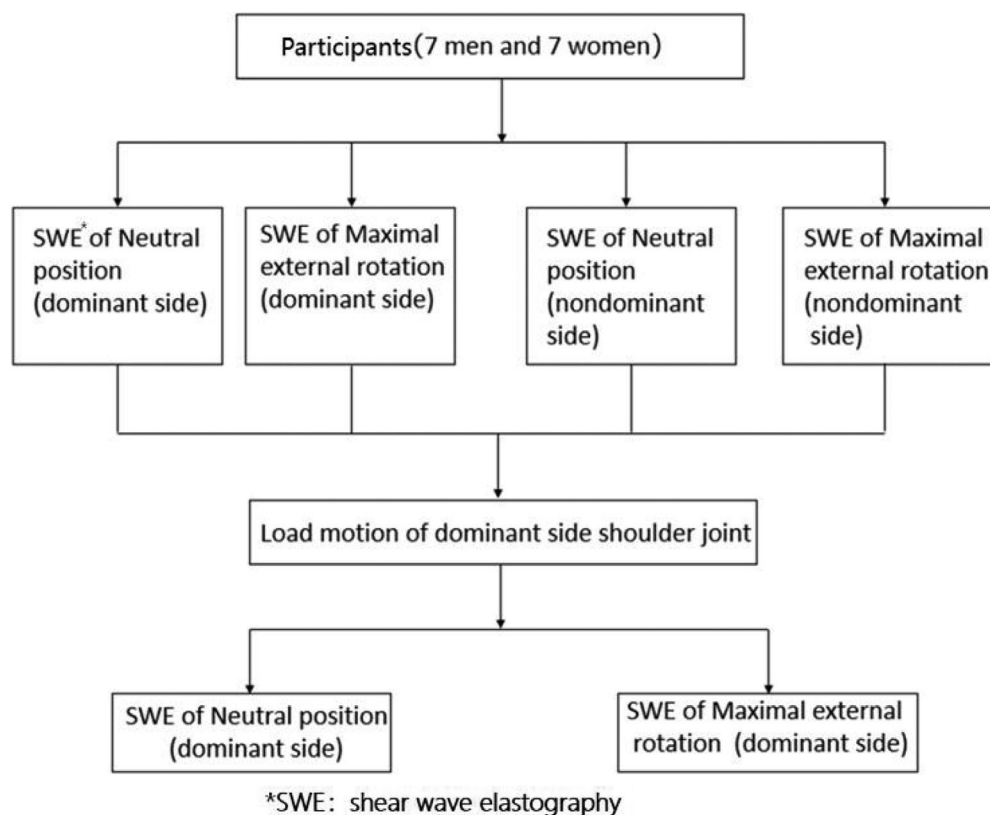
At the same time, the difference in tendon between males and females has long been a concern. It is generally believed that male tendon tissue has stronger toughness than female tendon tissue and can withstand greater pulling force<sup>23,24</sup>. And the properties of the dominant and non-dominant tendons are also generally considered to be different. Previous studies have found that numerous advantages of the dominant limb in the generation of motor output, including increased strength, rate, and consistency of movement<sup>25</sup>, but there is also a lack of quantitative and effective parameters to help further study.

For these reasons mentioned above, we have tried to explore the use of SWE to measure Young's modulus of tissue, compare differences between the sexes, and guide exercise. Taking advantage of this unique technique, the purposes of this study were to attempt to: (i) measure the Young's modulus values of the infraspinatus tendon in normal adults; (ii) explore the influence of gender, body position, exercise, and side dominance on the Young's modulus values at a preliminary stage; (iii) discuss the possibility of using SWE to monitor the Young's modulus of infraspinatus tendon in exercise.

## Patients and Methods

### Patients

This study was designed as a prospective cross-sectional study. The schematic diagram of the data collection was shown in Fig. 1. Fourteen graduate volunteers of good health were selected randomly from our hospital from January 2019 to July 2020, including seven males and seven females aged between 24 to 34, with a mean age of  $27.67 \pm 3.08$  years. All subjects were enrolled through hospital recruitment and voluntary registration. The study conformed with the Helsinki II Declaration, and all subjects gave written informed consent to participate. The study was approved by the Ethics Committee of Sun Yat-sen Memorial Hospital of Sun Yat-sen University (ID: SYSEC-KY-KS-2020-054). All subjects provided written informed consent prior to the experiment and confirmed that they complied with the inclusion criteria as follows: age ranging from 18 to 35. Exclusion criteria were as follows: (i) have difficulty in target tendon measurement; (ii) have taken muscle relaxation drugs within half a month; (iii) have participated in competitions that required intense



**Fig. 1** A graph depicting schematic diagram of the data collection: Firstly, Young's modulus values of subjects' dominant/non-dominant sides were examined both in neutral/external rotatory positions. Then the subjects carried out load motion tests with their dominant shoulders. And Young's modulus values in both the neutral and external rotatory positions were immediately measured.

shoulder joint movement within half a month; (iv) have been pregnant or unable to sit still for 10 minutes; (v) rotated the shoulder joint externally less than 45°; (vi) inability to complete the shoulder joint load movement required by the study; (vii) there was shoulder injury or pain within 3 months. General information of the participants was shown in Table 1. Examinations were performed by two independent operators after consistency training.

### Radiologists and Instrumentation

Two radiologists (Y. M. and W. J.), both with more than 5 years of clinical experience, independently measured the Young's modulus of infraspinatus tendons using the same technique after consistency training. The radiologists were asked to evaluate the Young's modulus of each infraspinatus tendon. The Young's modulus was measured by using the

Aixplorer US system (SuperSonic Imagine, Aix-en-Provence, France) with a 4–15 MHz linear transducer.

### Methodology

#### Data Collection Before Exercise

After scanning the shoulder joint with conventional ultrasound, the examinee was instructed to keep their shoulder joints naturally drooped, relaxed, and not exert any force (neutral position, Fig. 2A). Then active external rotation was adopted and was kept fixed and stable at 45° (external rotatory position, Fig. 2B). During the measurement, the examinee was asked to adopt a sitting position with straightened chest and head, back supported and turned to the examiner, while keeping head and body parallel, and looking straight ahead (Fig. 2C). The Young's modulus values of the infraspinatus tendon were measured with SWE in both dominant and non-dominant sides.

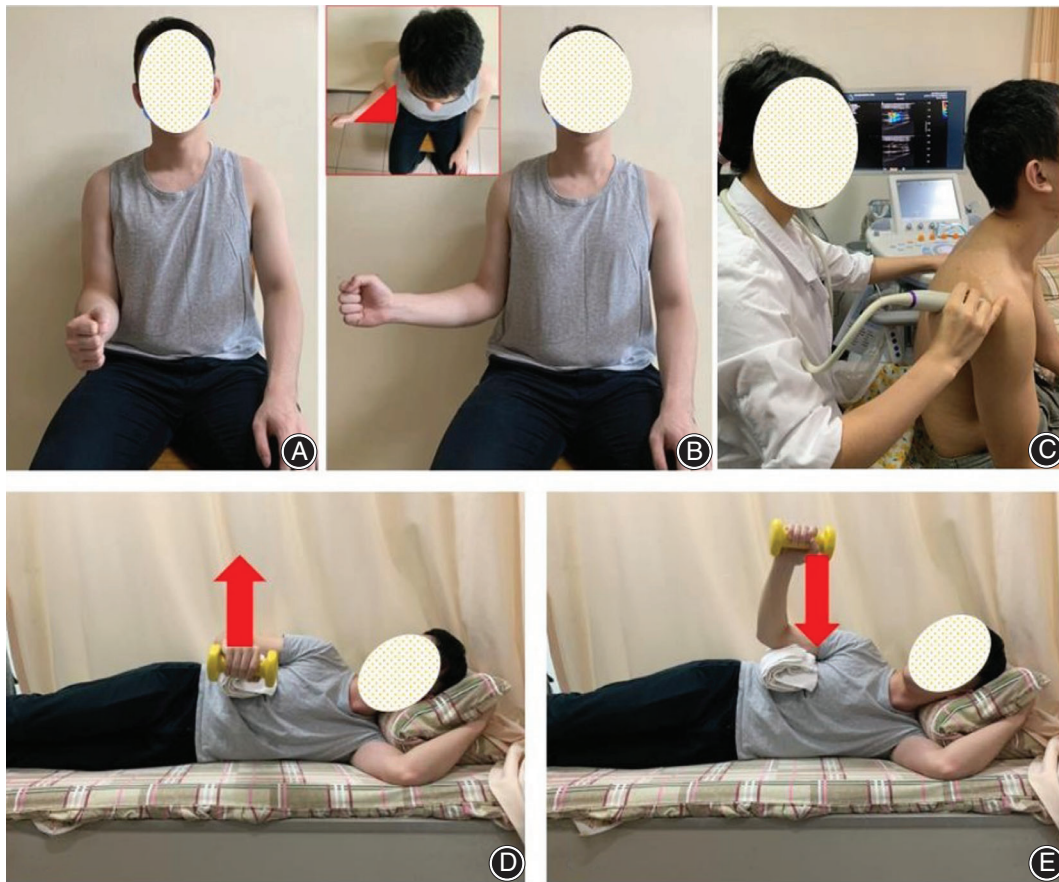
#### Key Details During Data Collection

The probe should be gently placed on the shoulder of the patient, and the examiner's hand should exert as little pressure on the skin of the examined area as possible, in order to reduce the effect of external pressure on the shear wave value of the infraspinatus tendon. The Young's modulus display was default at 60 kPa, and the probe was placed in line with the infraspinatus tendon fiber. The acoustic beam plane was perpendicular to the tendon surface, and the anisotropic pseudo-

**TABLE 1** Demographic data of participants

Characteristic	Male (N = 7)*	Female (N = 7)*	P value
Age, y	26.57 ± 2.37	26.86 ± 2.04	0.322
Height, m	1.68 ± 0.08	1.61 ± 0.03	<0.001
Weight, kg	66.43 ± 12.49	49.86 ± 6.31	<0.001
BMI, kg/m <sup>2</sup>	23.27 ± 3.05	19.17 ± 2.42	<0.001

\* Mean ± SD, SD, Standard Deviation.



**Fig. 2** (A–C) depicting one example of the examinee's and the subject's posture and position for the measurement of the infraspinatus muscle shear modulus. This test was conducted on a 21-year-old male volunteer. A: Neutral position; B: Maximum external rotation; C: Posture and position of the doctor and the subject. (D, E) depicting one participant carrying out load motion of shoulder on the dominant side.

image of the tendon was excluded to display the infraspinatus tendon fiber clearly<sup>26</sup>. The size of the sampling box was set to 2 cm × 1 cm in the SWE program. After the image was stabilized (color stabilized in the frame), the image was frozen, and the Young's modulus of the infraspinatus tendon was measured. The location that was 2 cm away from the attachment point of the infraspinatus tendon was selected. Each sampling site was measured three times, and the mean value of the Young's modulus (E mean) was calculated and recorded.

#### Data Collection After Exercise

After the rest position test, the subjects carried out load motion tests with their dominant shoulder joints. The subjects were in left lateral decubitus on the examination bed, holding a 2 kg dumbbell in their dominant hand. They performed reciprocating motion involving the neutral position (Fig. 2D) and external rotation position (Fig. 2E) 30 times in 1 minute and then take a 30-second break for five cycles. The shear wave values of the tendons in both the neutral and external rotatory positions were immediately measured with three repetitions and calculation of mean value.

#### Statistical Analysis

All measured data were analyzed with the SPSS Statistics software (version 22; IBM, Armonk, NY, USA), and the sample size was calculated with PASS 15 software (NCSS, Kaysville, UT) and expressed in terms of Mean ± SD. Independent sample *t*-tests were used to compare the differences in Young's modulus values between groups. Differences were considered statistically significant when  $P < 0.05$ . Intra-rater and inter-rater reliability were assessed by the intraclass correlation coefficient (ICC). An ICC value of 0 means not trusted, and 1 means fully trusted. It is generally believed that ICC lower than 0.4 indicates poor reliability, while greater than 0.75 indicates good reliability.

#### Results

##### Patients' Demographics

At last, all 14 subjects (seven males and seven females) completed the data collection process according to the experimental design requirements as described in the previous section. There was a significant difference in height, weight,

and BMI ( $P < 0.001$ , Table 1), but there was not a significant difference in age ( $P = 0.322$ , Table 1). During the enrollment, however, there was a volunteer with a height of 191 cm, which yielded a BMI value of 28.78, leading to the inability of the shear wave to fill the sample frame in the process of shear wave measurement. The patient had to be excluded.

### Consistency Analysis

The real-time data of Young's modulus for infraspinatus tendon before and after movement were obtained at the neutral and external rotatory position. Both examiners had mastered similar operational skills from unified training prior to this study, which yielded excellent intergroup reliability between the two examiners with an intraclass correlation coefficient (ICC) greater than 0.85. The intraclass correlation coefficients (ICC) were excellent for the Young's modulus. The intra-rater ICC for the Young's modulus was 0.972 (95% confidence interval [CI], 0.957–0.982), while the inter-rater ICC for the Young's modulus was 0.963 (95% CI, 0.944–0.976). And the line chart of Young's modulus values measured by two examiners also proved that the results measured by two examiners maintain consistency, and this measurement is repeatable (Fig. 3).

### Young's Modulus Values in Dominant/Non-Dominant Side and Neutral/External Rotatory Position

The mean Young's modulus values of infraspinatus tendon for dominant sides in neutral position were  $33.04 \pm 3.01$  kPa for males and  $28.76 \pm 3.09$  kPa for females (females were 14.87% lower than males). And for non-dominant sides in the neutral position, the values were  $33.02 \pm 2.38$  kPa for males and  $28.86 \pm 2.47$  kPa for females (females were 14.41% lower than males). In the maximum external rotation position, the values for dominant sides were  $50.19 \pm 4.86$  kPa for males and  $42.79 \pm 4.44$  kPa for females (females were 17.29% lower than males), and for non-dominant sides were  $50.95 \pm 3.24$  kPa for males and  $42.42 \pm 3.66$  kPa for females (females were 20.11% lower than males). For males, the mean Young's modulus values of infraspinatus tendon at maximum external rotation position were 51.91% higher than neutral position, and for females the mean Young's modulus values increased by 48.78%. The difference between males and females at neutral position and maximum external rotation position was statistically significant for both sides ( $P < 0.05$ , Table 2). However, there were no significant differences between the Young's modulus on the dominant compared with the non-dominant side in both the neutral position and maximum external rotation position ( $P > 0.05$ , Table 2).

### Young's Modulus Values Before and After Exercise

After exercise, the mean Young's modulus values of infraspinatus tendon for dominant sides for males were  $54.56 \pm 3.76$  kPa in neutral position and  $59.13 \pm 3.78$  kPa in maximum external rotation position (neutral position were 8.38% lower than maximum external rotation position). And

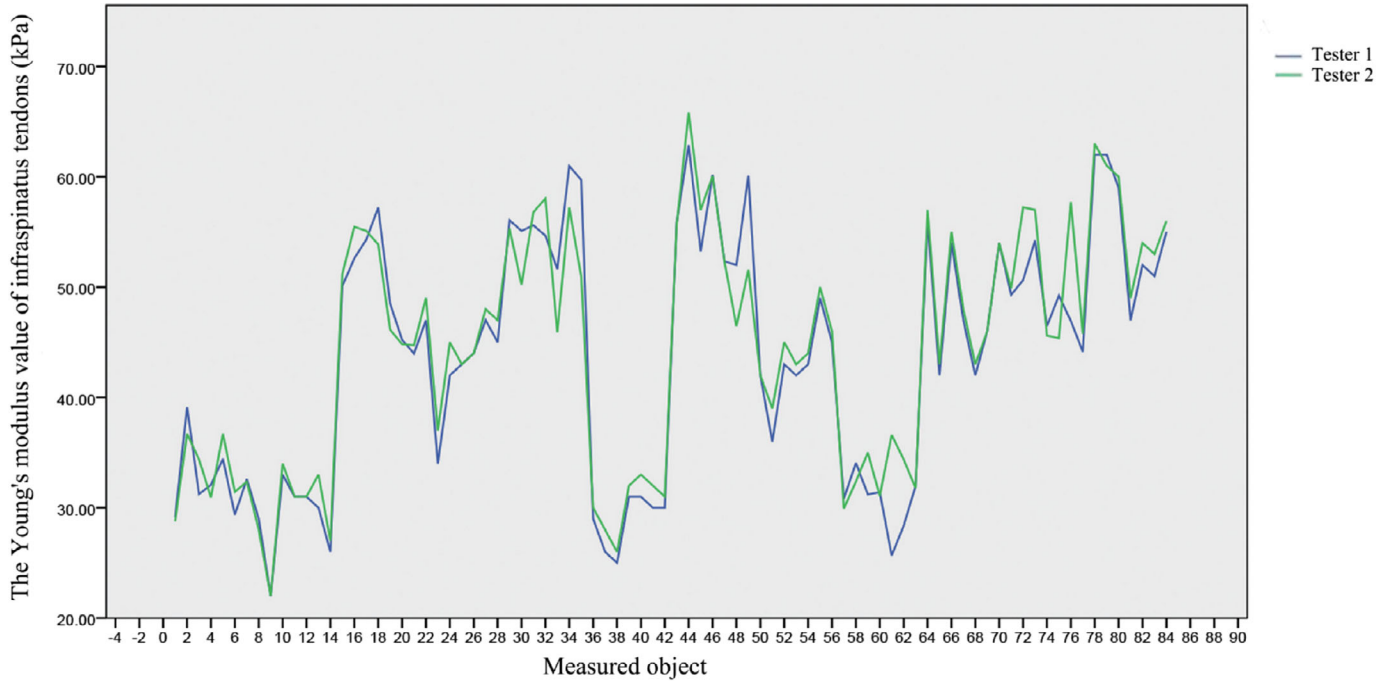
for females, the values were  $46.66 \pm 5.99$  kPa in neutral position and  $54.49 \pm 5.67$  kPa in the maximum external rotation position (neutral position were 16.78% lower than maximum external rotation position). For males, the mean Young's modulus values of infraspinatus tendon at neutral position were 65.13% higher than before exercise, and at maximum external rotation position, the mean Young's modulus values were 17.81% higher than before exercise. For females, the mean Young's modulus values of infraspinatus tendon at neutral position were 62.24% higher than before exercise, and at maximum external rotation position, the mean Young's modulus values were 27.34% higher than before exercise (Table 3). There were significant differences between before and after exercise in the Young's modulus of the infraspinatus tendon at both positions ( $P < 0.05$ , Table 3). No matter before or after exercise, there were significant differences between neutral and maximum external rotation position ( $P < 0.05$ , Table 3). A scatter plot of Young's modulus data was shown in Fig. 4 and one subject's SWE images were shown in Fig. 5.

### Discussion

SWE is an ultrasonic elastography technique that utilizes shear waves to quantitatively measure Young's modulus of tissue, which is unique among current imaging techniques, especially in assessing diseases of the skeletal muscle system<sup>27</sup>. It possesses the advantages of being non-invasive and affordable, in addition to providing a real-time and dynamic evaluation. The traditional method used by orthopaedic surgeons to evaluate Young's modulus of tissue is usually subjective and imprecise and is often carried out during surgery. SWE can achieve the same quantitative objective by being non-invasive, making it potentially useful for preoperative and postoperative evaluation, rehabilitation guidance, and so on. Therefore, more and more attention has been paid to its application in the musculoskeletal system<sup>27–29</sup>.

Because the shoulder joint is coordinated by the most complex dynamic muscle-tendon structure in the whole body with a relatively shallow position, the application of SWE in the shoulder joint has a good prospect in the evaluation of Young's modulus of soft tissue<sup>30</sup>. Baumer *et al.* evaluated the supraspinatus muscle both in healthy subjects and patients suffering from rotator cuff injury with SWE<sup>31</sup>. Meanwhile, Leong *et al.* used SWE to evaluate the Young's modulus of the superior trapezius muscle in healthy athletes and athletes with rotator cuff tendinopathy, and their results showed a higher shear wave Young's modulus of the superior trapezius muscle in athletes with the disease compared with those in asymptomatic athletes<sup>32</sup>. Takenaga *et al.* applied SWE to measure the elasticity of the posterior shoulder capsule among college baseball players, proposing it as a novel method to analyze the under rotation of the humerus<sup>33</sup>. Moreover, Hou *et al.* utilized SWE as a mode to evaluate the rotator cuff tendon and discovered the decrease of Young's modulus of rotator cuff in patients with rotator cuff tendonitis<sup>34</sup>. Besides that, SWE was also applied by Umehara *et al.*

Line chart of Young's modulus values measured by two testers



**Fig. 3** Line chart of Young's modulus values measured by two testers. Two radiologists independently measured Young's modulus of the infraspinatus tendon in six states of 14 patients. Each participant measured a total of 84 values, and the corresponding points of each value were linked together to produce a broken line. The two broken lines show the consistency of the two subjects' measurements.

**TABLE 2 Mean and standard deviation for the Young's modulus of infraspinatus measured during passive arm positioning at different positions (Mean ± SD) kPa**

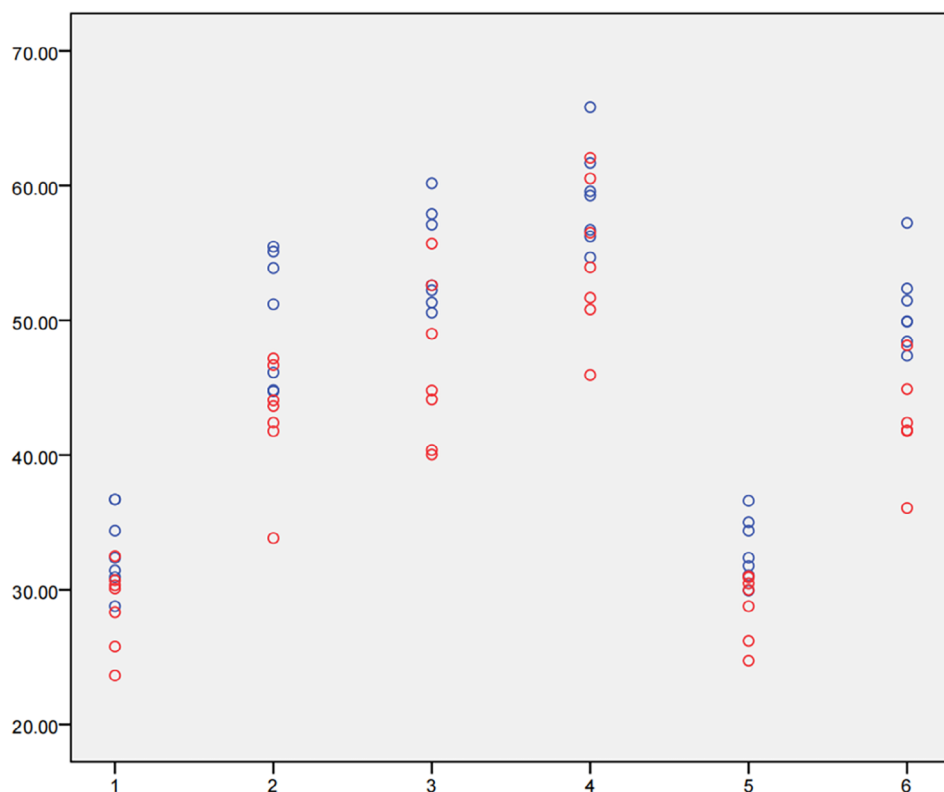
Gender	Neutral position			Maximum external rotation		
	Dominant side	Non-dominant side	P value	Dominant side	Non-dominant side	P value
Male	33.04 ± 3.01	33.02 ± 2.38	0.988	50.19 ± 4.86	50.95 ± 3.24	0.736
Female	28.76 ± 3.09	28.86 ± 2.47	0.947	42.79 ± 4.44	42.42 ± 3.66	0.867
Difference (%)	14.87	14.41		17.29	20.11	
P value	<b>0.022</b>	<b>0.008</b>		<b>0.012</b>	<b>0.001</b>	

SD, Standard Deviation.

**TABLE 3 Comparison of the Young's modulus values in different positions after exercise between males and females at the dominant side (Mean ± SD) kPa**

Before and after exercise	Male			P value	Female			P value
	Neutral position	Maximum external rotation	Difference (%)		Neutral position	Maximum external rotation	Difference (%)	
Before exercise	33.04 ± 3.01	50.19 ± 4.86	51.91	<b>&lt;0.01</b>	28.76 ± 3.09	42.79 ± 4.44	48.78	<b>&lt;0.01</b>
After exercise	54.56 ± 3.76	59.13 ± 3.78	8.38	<b>0.042</b>	46.66 ± 5.99	54.49 ± 5.67	16.78	<b>0.027</b>
Difference (%)	65.13	17.81			62.24	27.34		
P value	<b>&lt;0.001</b>	<b>0.002</b>			<b>&lt;0.001</b>	<b>0.001</b>		

SD, Standard Deviation



**Fig. 4** Scatter plot of Young's modulus values. The data were divided into six groups based on the status of the subjects. Each group had 14 dots, each representing a patient's Young's modulus of the infraspinatus tendon. The blue dots represent males, and the red dots represent females.

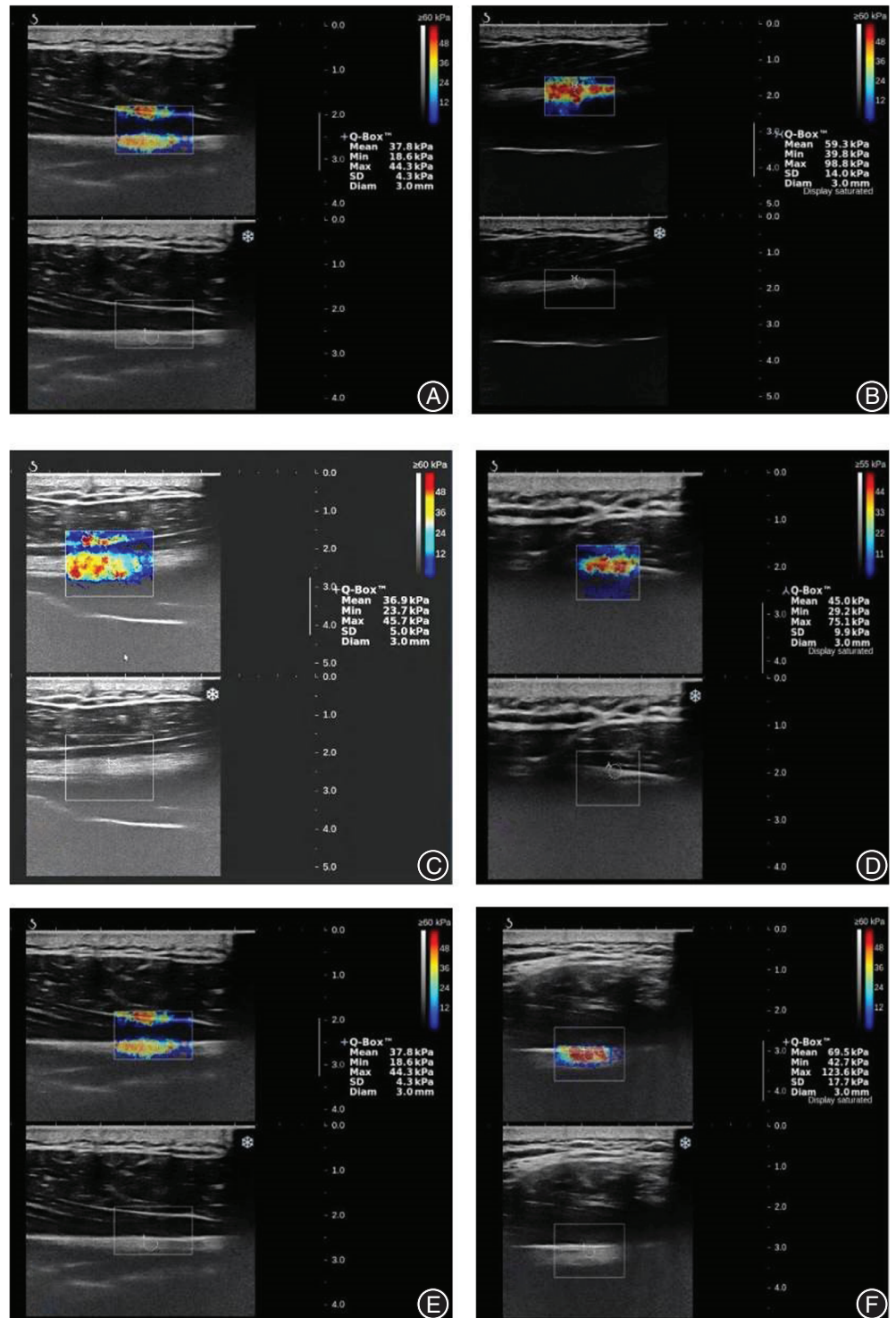
to assess the effect of different shoulder joint exercises on the Young's modulus of the pectoralis minor muscle. They confirmed that both 90° and 150° horizontal abduction of the shoulder are the most effective stretching positions of the pectoralis minor muscle.

At present, there are a few published studies on Young's modulus testing in the supraspinatus muscle by SWE. Kusano *et al.* measured the Young's modulus of the infraspinatus muscle in 20 healthy men with the help of SWE and discovered that extension and internal rotation of the shoulder could effectively reduce the Young's modulus of the infraspinatus muscle<sup>18</sup>. Seong Jong Yun *et al.* used SWE to compare the Young's modulus of the supraspinatus tendon (SST) and the infraspinatus tendon (IST) in patients with idiopathic adhesive capsulitis of the shoulder and discovered that the Young's modulus of both the SST and IST were higher in ACS patients than in healthy people<sup>20</sup>. Additionally, they also evaluated the relationship between Young's modulus in tissue and age.

Our preliminary study showed that the differences between the Young's modulus of the infraspinatus tendons both in men and women were statistically significant for neutral and maximum external rotation position. Still, no statistical significance was observed between the dominant and non-dominant sides. There was also no statistical significance between the Young's modulus in the neutral and external rotation positions after exercise, but statistically significant

differences were identified in every position for both men and women when compared to that before exercise. The Young's modulus of tissue values for men and women significantly increased after exercise both in the neutral and external rotation position. This points out that exercise can significantly increase the Young's modulus of the infraspinatus muscle. In this study, only 14 volunteers (seven males and seven females) were enrolled. Multi-center data collection and analysis with a larger sample population are required to reach more objective conclusions. The recovery of Young's modulus of infraspinatus tendon after exercise may be the direction for further studies. Moreover, using the SWE to check the Young's modulus value at different time points after certain movements will be helpful in rehabilitation programs of the infraspinatus tendon and provide more insights and guidance for sports training by dynamic Young's modulus assessment of soft tissue.

Despite various novel applications that look promising, SWE faces some limitations for its clinical application. First, data obtained by different operators vary greatly. Centralized and unified training and practices are needed to reduce the bias between operators. Secondly, shear wave data for people with a large BMI, who may be obese or tall, is difficult to measure. In our study, a volunteer who was 191 cm in height with a BMI of 28.78 was unable to fill the sampling box with shear wave during data measurement, so he was excluded. This might indicate that



**Fig. 5** (A–E) depicting one 32-year-old male subject's shear wave elastography images of the infraspinatus tendon. A: Neutral position (dominant side), B: Maximum external rotation (dominant side), C: Neutral position (non-dominant side), D: Maximum external rotation (non-dominant side), E: Neutral position after exercise (dominant side), F: Maximum external rotation after exercise (dominant side).

SWE detecting infraspinatus tendon may not be suitable for the extremely tall or overweight, whose subcutaneous fat may cover the target tendon and make detection difficult. Thirdly, the SWE requires the subject to comply with instructions before the examination because the Young's

modulus value of muscle tendons or other soft tissues to be tested are easily affected by recent sports activities and load conditions. If we want to obtain an objective and comparable result, we must make the conditions consistent before the inspection.



In conclusion, SWE is a real-time and non-invasive quantitative method to test the Young's modulus of the infraspinatus tendon dynamically. High-intensity exercise in a short time increased the Young's modulus of the supraspinatus tendon. There was no significant difference between the dominant and non-dominant sides, and there were differences between males and females in the sup-

raspinatus Young's modulus. The supraspinatus Young's modulus in the external rotation position was greater than that in the neutral position.

### Acknowledgments

The authors acknowledge Dr. Phei Er Saw for proofreading and improving the language in this article.

### References

1. Sarvazyan AP, Rudenko OV, Swanson SD, Fowlkes JB, Emelianov SY. Shear wave elasticity imaging: a new ultrasonic technology of medical diagnostics. *Ultrasound Med Biol*, 1998, 24: 1419–1435.
2. Bercoff J, Tanter M, Fink M. Supersonic shear imaging: a new technique for soft tissue elasticity mapping. *IEEE Trans Ultrason Ferroelectr Freq Control*, 2004, 51: 396–409.
3. Pass B, Jafari M, Rowbotham E, Hensor EM, Gupta H, Robinson P. Do quantitative and qualitative shear wave elastography have a role in evaluating musculoskeletal soft tissue masses? *Eur Radiol*, 2017, 27: 723–731.
4. Taljanovic MS, Gimber LH, Becker GW, et al. Shear-wave Elastography: basic physics and musculoskeletal applications. *Radiographics*, 2017, 37: 855–870.
5. Wada T, Itoigawa Y, Yoshida K, Kawasaki T, Maruyama Y, Kaneko K. Increased stiffness of rotator cuff tendons in frozen shoulder on shear wave Elastography. *J Ultrasound Med*, 2020, 39: 89–97.
6. Kanazawa K, Hagiwara Y, Sekiguchi T, et al. Correlations between range of motion and elasticity of the Coracohumeral ligament evaluated with shear-wave Elastography. *J Sport Rehabil*, 2020, 30: 9–15.
7. Krepkin K, Bruno M, Raya JG, Adler RS, Gyftopoulos S. Quantitative assessment of the supraspinatus tendon on MRI using T2/T2\* mapping and shear-wave ultrasound elastography: a pilot study. *Skeletal Radiol*, 2017, 46: 191–199.
8. Lacourpaille L, Hug F, Bouillard K, Hogrel JY, Nordez A. Supersonic shear imaging provides a reliable measurement of resting muscle shear elastic modulus. *Physiol Meas*, 2012, 33: N19–N28.
9. Bouillard K, Hug F, Guevel A, Nordez A. Shear elastic modulus can be used to estimate an index of individual muscle force during a submaximal isometric fatiguing contraction. *J Appl Physiol* (1985), 2012, 113: 1353–1361.
10. Lapole T, Tindel J, Galy R, Nordez A. Contracting biceps brachii elastic properties can be reliably characterized using supersonic shear imaging. *Eur J Appl Physiol*, 2015, 115: 497–505.
11. Yoshitake Y, Takai Y, Kanehisa H, Shinohara M. Muscle shear modulus measured with ultrasound shear-wave elastography across a wide range of contraction intensity. *Muscle Nerve*, 2014, 50: 103–113.
12. Aubry S, Risson JR, Kastler A, et al. Biomechanical properties of the calcaneal tendon in vivo assessed by transient shear wave elastography. *Skeletal Radiol*, 2013, 42: 1143–1150.
13. Hug F, Lacourpaille L, Maisetti O, Nordez A. Slack length of gastrocnemius medialis and Achilles tendon occurs at different ankle angles. *J Biomech*, 2013, 46: 2534–2538.
14. Eby SF, Song P, Chen S, Chen Q, Greenleaf JF, An KN. Validation of shear wave elastography in skeletal muscle. *J Biomech*, 2013, 46: 2381–2387.
15. Koo TK, Guo JY, Cohen JH, Parker KJ. Quantifying the passive stretching response of human tibialis anterior muscle using shear wave elastography. *Clin Biomech (Bristol, Avon)*, 2014, 29: 33–39.
16. Nishishita S, Hasegawa S, Nakamura M, Umegaki H, Kobayashi T, Ichihashi N. Effective stretching position for the supraspinatus muscle evaluated by shear wave elastography in vivo. *J Shoulder Elbow Surg*, 2018, 27: 2242–2248.
17. Dirrachs T, Quack V, Gatz M, et al. Shear wave Elastography (SWE) for monitoring of treatment of Tendinopathies: a double-blinded, longitudinal clinical study. *Acad Radiol*, 2018, 25: 265–272.
18. Kusano K, Nishishita S, Nakamura M, Tanaka H, Umehara J, Ichihashi N. Acute effect and time course of extension and internal rotation stretching of the shoulder on infraspinatus muscle hardness. *J Shoulder Elbow Surg*, 2017, 26: 1782–1788.
19. Umegaki H, Ikezoe T, Nakamura M, et al. Acute effects of static stretching on the hamstrings using shear elastic modulus determined by ultrasound shear wave elastography: differences in flexibility between hamstring muscle components. *Man Ther*, 2015, 20: 610–613.
20. Yun SJ, Jin W, Cho NS, et al. Shear-wave and strain ultrasound Elastography of the supraspinatus and Infraspinatus tendons in patients with idiopathic adhesive capsulitis of the shoulder: a prospective case-control study. *Korean J Radiol*, 2019, 20: 1176–1185.
21. Arda K, Ciledag N, Aktas E, Aribas BK, Kose K. Quantitative assessment of normal soft-tissue elasticity using shear-wave ultrasound elastography. *AJR Am J Roentgenol*, 2011, 197: 532–536.
22. McGee S, Hargreaves M. Exercise adaptations: molecular mechanisms and potential targets for therapeutic benefit. *Nat Rev Endocrinol*, 2020, 16: 495–505.
23. Westh E, Kongsgaard M, Bojsen-Moller J, et al. Effect of habitual exercise on the structural and mechanical properties of human tendon, in vivo, in men and women. *Scand J Med Sci Sports*, 2007, 18: 23–30.
24. Hansen M, Kjaer M. Sex hormones and tendon. *Adv Exp Med Biol*, 2016, 920: 139–149.
25. Bravi R, Cohen EJ, Martinelli A, Gottard A, Minciacci D. When non-dominant is better than dominant: Kinesiotape modulates asymmetries in timed performance during a synchronization-continuation task. *Front Integr Neurosci*, 2017, 11.
26. Aubry S, Nueffer JP, Carrie M. Evaluation of the effect of an anisotropic medium on shear wave velocities of intra-muscular gelatinous inclusions. *Ultrasound Med Biol*, 2017, 43: 301–308.
27. Brandenburg JE, Eby SF, Song P, et al. Ultrasound elastography: the new frontier in direct measurement of muscle stiffness. *Arch Phys Med Rehabil*, 2014, 95: 2207–2219.
28. Drakonaki EE, Allen GM, Wilson DJ. Ultrasound elastography for musculoskeletal applications. *Br J Radiol*, 2012, 85: 1435–1445.
29. Lalitha P, Reddy M, Reddy KJ. Musculoskeletal applications of elastography: a pictorial essay of our initial experience. *Korean J Radiol*, 2011, 12: 365–375.
30. Gilbert F, Klein D, Weng AM, et al. Supraspinatus muscle elasticity measured with real time shear wave ultrasound elastography correlates with MRI spectroscopic measured amount of fatty degeneration. *BMC Musculoskelet Disord*, 2017, 18: 549.
31. Baumer TG, Dischler J, Davis L, et al. Effects of age and pathology on shear wave speed of the human rotator cuff. *J Orthop Res*, 2018, 36: 282–288.
32. Leong HT, Tsui SS, Ng GY, Fu SN. Reduction of the subacromial space in athletes with and without rotator cuff tendinopathy and its association with the strength of scapular muscles. *J Sci Med Sport*, 2016, 19: 970–974.
33. Takenaga T, Sugimoto K, Goto H, et al. Posterior shoulder capsules are thicker and stiffer in the throwing shoulders of healthy college baseball players: a quantitative assessment using shear-wave ultrasound Elastography. *Am J Sports Med*, 2015, 43: 2935–2942.
34. Hou SW, Merkle AN, Babb JS, McCabe R, Gyftopoulos S, Adler RS. Shear wave ultrasound Elastographic evaluation of the rotator cuff tendon. *J Ultrasound Med*, 2017, 36: 95–106.