

Diagnostic dilemma: Saccular aneurysm or pseudoaneurysm of the ascending aorta with dissection above level of leaflets

Maryam Mehrpooya⁽¹⁾, Mehrdad Salehi⁽²⁾, Ramin Eskandari⁽³⁾, Zeinab Shajirat⁽⁴⁾, Allahyar Golabchi⁽⁵⁾, Majid Mazoochi⁽⁶⁾

Abstract

BACKGROUND: In true aneurysm, the wall of aneurysm is composed of the normal histological components of aorta. A false aneurysm (pseudoaneurysm) represents a rupture which does not contain the normal histological components of aorta. It is a fibrous peel that has formed from a small perforation of aorta. We describe an unusual presentation that has signs which some of them are only manifested in true aneurysm and some others only in pseudoaneurysm.

CASE REPORT: An 85-year-old man underwent elective coronary angiography for chest pain work-up. Our evaluation by invasive angiography and CT angiography showed aortic dissection. In surgery we found that dissection flap was composed of some parts of intima and media layers. These signs led to confusing symptoms. Localized bulging of ascending aorta had continued to brachiocephalic artery (transverse arch involvement). Dissection flap was composed of some part of intima and media layers. It was a strange case, it was not solely a perivascular hematoma and it did not have all three layers of aorta wall. Partial aorta replacement was performed. The operation and recovery was uneventful.

CONCLUSION: This unusual presentation of disease has not been mentioned in literatures. Our experience can help to manage similar cases. This case was the first unusual presentation of its type.

Keywords: Saccular Aneurysm, Aortic Dissection, Pseudoaneurysm, Aneurysm

ARYA Atherosclerosis Journal 2012, 8(3): 167-169

Date of submission: 28 May 2012, *Date of acceptance:* 30 Jul 2012

Introduction

In true aneurysm, the wall of aneurysm is composed of the normal histological components of aorta. A false aneurysm (pseudoaneurysm) represents a contained rupture which does not contain the normal histological components of aorta. It is a fibrous peel that has formed from a small perforation of aorta. True aneurysm can be divided in two kinds, fusiform (most common) and saccular. Saccular aneurysm is an outpouching of a portion of aortic circumference. Frequently, the small neck provides continuity between aortic lumen and saccular aneurysm.¹ It is asymmetrical (uneven). Saccular aneurysms typically are caused by trauma such as a car accident or by a penetrating aortic ulcer.² A naturally occurring saccular aneurysm at the ascending aorta is an extremely rare clinical entity.³ Our

case was not pseudoaneurysm, because it was not solely perivascular hematoma. On the other hand, it was not the true aneurysm, because it did not have all three layers of the wall of aorta. Such case has not been reported so far.

Case Report

An 85-year-old Kurdish man lived in Iran, had been referred for elective coronary angiography and was admitted because of typical chest pain but with mild intensity. One year ago he had experienced an episode of chest pain accompanied by troponin elevation that had been considered acute coronary syndrome. However, he had not been underwent coronary angiography, with any reason that we do not know. After that event, he did not have typical coronary

1- Assistant Professor, Department of Cardiology, School of Medicine, Imam Khomeini Hospital Complex, Tehran University of Medical Sciences, Tehran, Iran

2- Associate Professor, Department of Cardiac Surgery, Cardiology Department of Imam Khomeini Hospital Complex, Tehran University of Medical Sciences, Tehran, Iran

3- Cardiologist, Department of Cardiology, School of Medicine, Imam Khomeini Hospital Complex, Tehran University of Medical Sciences, Tehran, Iran

4- MSc, Department of Cardiology, School of Advanced Medical Technologies, Tehran University of Medical Sciences, Tehran, Iran

5- Fellowship of Interventional Electrophysiology, Cardiac Electrophysiology Research Center, Rajaie Cardiovascular Medical and Research Center, Tehran University of Medical Sciences, Tehran, Iran

6- Fellowship of Interventional Cardiology, Department of Cardiology, Kashan University of Medical Sciences, Kashan, Iran

Correspondence To: Maryam Mehrpooya, Email: maryammehrpooya@yahoo.com

symptoms until current presentation. He was scheduled for angiography because of typical chest pain and old electrocardiographic (ECG) changes.

Initially, His physical exam was unremarkable, ECG showed normal sinus rhythm with Q waves and inversion of T waves in II, III and aVF leads without any acute or new findings. Chest X-ray revealed the bulge aortic knob contour (Figure 1). Routine transthoracic echocardiography, including the suprasternal view, showed dilated ascending aorta (4.6 cm) (Figure 2) and mild commissural aortic regurgitation preserved left ventricular systolic function. During catheterization, the left Judkins catheter passed without any problem, but we could not pass the right Judkins catheter, hence pigtail catheter was inserted and aortic root angiography showed the localized bulging of ascending aorta, but we were not sure whether it is dissection with true aneurysm or pseudoaneurysm? The findings on coronary artery angiography were unremarkable.

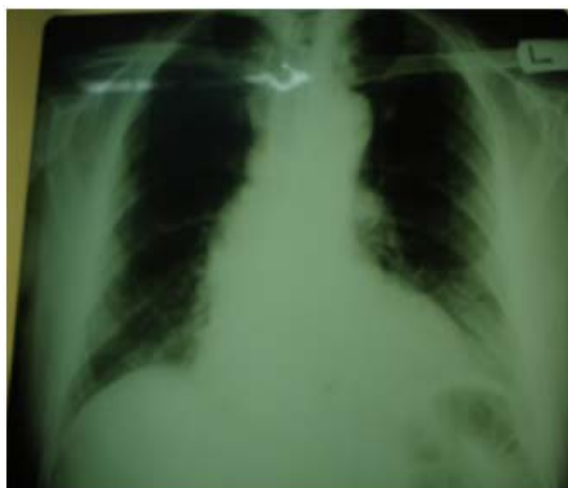


Figure 1. Chest X-ray at presentation

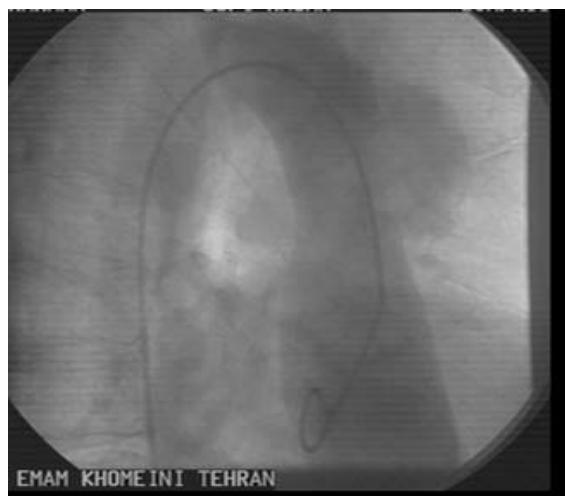


Figure 2. Conventional aortography

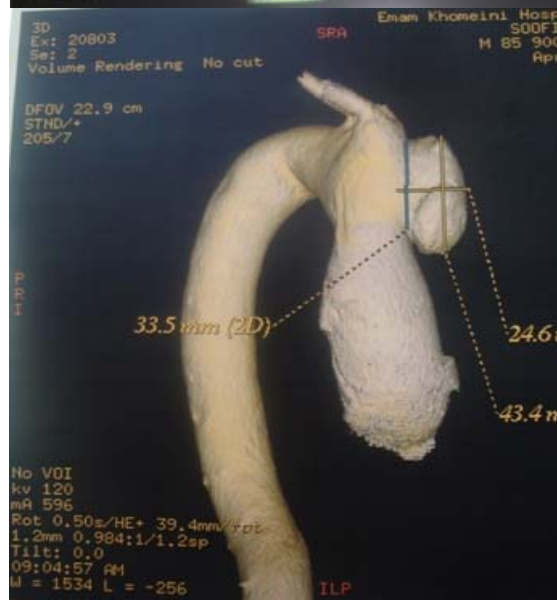
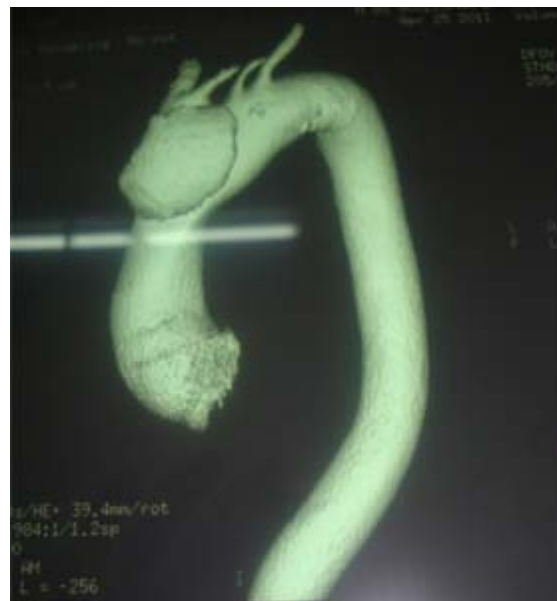

Figure 3. CT-angiography of aorta at presentation

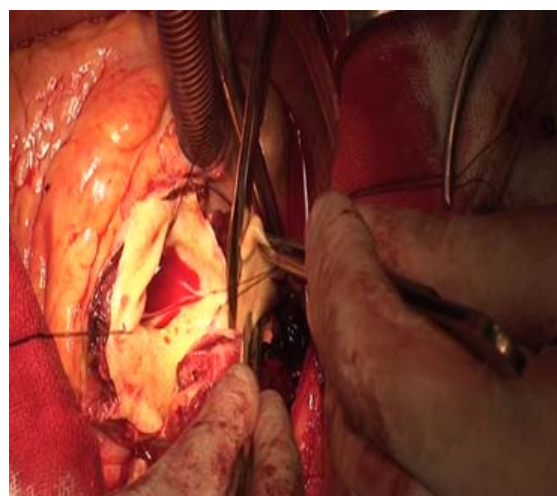


Figure 4. View of flap inside aorta during surgery

Multislice spiral CT angiography revealed aneurysmal dilation of ascending aorta from sinotubular junction with the saccular aneurysm at the proximal part of arch with a 37 mm per 56 mm maximum diameter (Figure 3). There was extension of thrombosis into the proximal part of right brachiocephalic artery, but ostia of both arteries did not involve with the aneurysm. The patient had been referred for surgery.

During surgery we found the dissection of ascending aorta till distal to brachiocephalic artery (transverse arch involvement). Dissection flap was composed of some parts of intima and media layers (Figure 4). Replacement of ascending and transverse aorta was performed with interposition tubular graft 30 and valve sparing. The operation and recovery was uneventful.

Discussion

We described an unusual presentation that had signs that some of them are only manifested in true aneurysm and some other only in pseudoaneurysm. These signs caused confusing symptoms. As mentioned, none of physical exam, chest x-ray and echocardiography could help us to detect aneurysm. Echocardiography showed dilated ascending aorta. Aortic root angiography showed localized bulging of ascending aorta, but we were not sure whether it is dissection and with true aneurysm or pseudoaneurysm. Only in surgery, we found the unusual presentation and confusing symptoms.

We found the dissection of ascending aorta till distal to brachiocephalic artery (transverse arch involvement). Dissection flap was composed of some parts of intima and media layers. Replacement of ascending and transverse aorta was performed with interposition tubular graft 30 and valve sparing. Ultimately, we could manage our case with surgery and replacement procedure.

Aortic dissection refers to splitting of the layers of the aortic wall (within the media) which permits longitudinal propagation of the filled space with blood within the aortic wall.¹ Now, is it correct to call

this entity true aneurysm? Certainly, this bulging could not be a true aneurysm, because it did not have all three layers, and distal flow that passed through the lumen did not have free contact with the pouch. On the other hand, we cannot certainly use the term of pseudoaneurysm for this case. In fact, it was not pseudoaneurysm, because it was not solely a perivascular hematoma. This case or similar cases has not been mentioned in literatures, but we think the term of aneurysm is more logic for our case. We cannot find a specific etiology (e.g. trauma, collagen vascular disease and etc.) for our case. Replacement of ascending and transverse aorta was performed successfully.

It was strange and original case that expanded the knowledge of interventional cardiology, cardiac surgery and general cardiology. In other cases like this, angiography and echocardiography cannot be completely helpful.

Conflict of Interests

Authors have no conflict of interests.

References

1. Fuster V, O'Rourke R, Walsh R, Poole-Wilson P. *Hurst's the Heart*. Philadelphia, PA: Saunders; 2011. p. 167-17.
2. Borrello B, Nicolini F, Beghi C, Gherli T. Saccular ascending aorta aneurysm: report of an unusual presentation. *Interact Cardiovasc Thorac Surg* 2008; 7(3): 508-9.
3. Ting AC, Cheng SW, Ho P, Poon JT. Endovascular repair for multiple Salmonella mycotic aneurysms of the thoracic aorta presenting with Cardiovascular syndrome. *Eur J Cardiothorac Surg* 2004; 26(1): 221-4.

How to cite this article: Mehrpooya M, Salehi S, Eskandari R, Shajirat Z, Golabchi A, Mazoochi M. **Diagnostic dilemma: Saccular aneurysm or pseudoaneurysm of the ascending aorta with dissection above level of leaflets.** *ARYA Atherosclerosis Journal* 2012; 8(3): 167-169.