



Predictors for margin of resection >4 mm in the management of periocular basal cell carcinoma

Radwan Almousa

Department of Ophthalmology, Queen's Hospital, Barking, Havering and Redbridge University Hospitals NHS Trust, Romford, UK

Purpose: To determine the margin of resection (MOR) for periocular basal cell carcinoma (BCC) and compare the outcomes of BCC treatment, namely Mohs micrographic surgery (MMS) and wide excision with later reconstruction (WELR).

Methods: This is a retrospective, comparative, interventional study of patients who underwent surgical treatment of periocular BCC. One hundred forty-two patients were included. One hundred patients were treated with MMS and 42 with WELR. Inclusion criteria were primary periocular BCC with postoperative follow-up of ≥ 6 months, age more than 18-year-old. Exclusion criteria were, orbital extension, BCC origin outside the periocular area, or those associated with Gorling or nevoid BCC. The main outcome measure was variables associates with MOR >4 mm.

Results: There was a positive correlation between the preoperative tumor horizontal and vertical diameter with the corresponding MOR, of 0.27 ($p = 0.01$) and 0.28 ($p = 0.007$), respectively. Receiver operating characteristics suggest that a tumor with a horizontal diameter ≥ 5 mm or a vertical diameter of ≥ 6 mm, might need MOR >4 mm. One patient in the MMS group had BCC recurrence compared to none in the WELR group, and one patient in the WELR had a positive surgical margin, which was cleared during the reconstruction.

Conclusions: BCC tumor margins may extend far beyond clinical margins and the MOR required is often more than 3–4 mm. MMS ensures clear tumor margins but is not practical for all patients. A stratification system could help divide patients between the treatment strategies.

Key Words: Basal cell carcinoma, Carcinoma, Eyelids

It has been reported that 5% to 10% of all skin cancers occur in the periocular region, and these in turn represent more than 90% of all ophthalmic tumors [1,2]. The vast majority of these tumors, 85% to 90%, are basal cell carcinomas (BCCs) [3]. Considering the large burden of this dis-

ease, it is paramount to have safe and cost-effective treatment options.

The aim of BCC treatment is generally total tumor eradication whilst ensuring the lowest recurrence risk. The current standard of care for BCC in the UK is either surgical excision with a predefined safety margin of resection (MOR) or surgical excision with microscopic tissue margin control. The latter is achieved by Mohs micrographic surgery (MMS). The MMS technique utilizes systematic frozen section control to ensure negative surgical margins whilst preserving the maximum amount of healthy tissue to facilitate easier reconstruction [4]. MMS offers the low-

Received: February 22, 2021 Final revision: June 27, 2021
Accepted: July 9, 2021

Corresponding Author: Radwan Almousa, MD, FRCOphth, CertLRS, Department of Ophthalmology, Queen's Hospital, Barking, Havering and Redbridge University Hospitals NHS Trust, Rom Valley Way, Romford RM7 0AG, UK. Tel: 44-7799-641635, Fax: 44-2039-238755, E-mail: Radwan.almousa1@nhs.net

© 2021 The Korean Ophthalmological Society

This is an Open Access article distributed under the terms of the Creative Commons Attribution Non-Commercial License (<http://creativecommons.org/licenses/by-nc/3.0/>) which permits unrestricted non-commercial use, distribution, and reproduction in any medium, provided the original work is properly cited.

est recurrence risk for BCC and is the standard against which other treatments are compared [5].

An area of controversy surrounding BCC treatment is the appropriate MOR to use. BCCs have traditionally been excised with 3–4 mm margins, combined with primary repair [6]. However, it has been shown that this may be inadequate for complete excision in up to 54% of tumors [7]. This calls into question whether the standard MOR used should be revised.

The purpose of the study is to analyze variables affecting the size of the MOR required for complete tumor excision to identify whether there is a need for a more tailored approach to determining the correct MOR for BCCs. We have also reviewed the outcomes of our patients with periocular BCC who have undergone both treatment strategies, namely MMS and Wide excision with later reconstruction (WELR), in a tertiary referral center in the UK.

Materials and Methods

These data were reviewed as part of a service evaluation. It was approved by the audit review board of Barking, Havering and Redbridge University Hospitals NHS Trust (280316) and followed the tenets of Helsinki declaration. All patients provided written informed consent at the time of surgery and agreed to use of their records for statistical analysis.

This is a retrospective review of patients' outcomes, all of whom underwent surgical treatment of periocular BCC between June 2013 and June 2015. Patients were listed for MMS surgery, which was done by the dermatologist and the reconstruction carried out by the oculoplastic surgeon 1 day later. In case if the MMS surgeon was not available or if there was a long waiting list, the patients were allocated for wide excision with WELR by the oculoplastic surgeon.

We did not include patients with recurrent tumor, tumor extension to the orbit, age less than 18 years, presence of regional or distant metastases, origin outside the periocular area (the cheek, temple, or nose), or those with Gorlin or nevoid BCC syndromes. Patients with follow-up of less than 6 months were not included in the recurrence analysis; however, they were included in the measurement of the tumor and the postoperative defect size.

All relevant data from each patient's case notes and surgical records were abstracted into a standardized data col-

lection excel spreadsheet that was used for analysis. Patient data recorded from office charts on initial presentation included the following: patient age, sex, involved eye, histological pattern (nodular and morpheaform), surgical procedure, follow-up time, and site of BCC (upper lid, lower lid, medial canthus, lateral canthus, and brow). Tumors overlapping the boundary of two areas were allocated to the most involved area for statistical reasons. The horizontal and vertical diameters of each tumor were measured at the initial clinical visit using a standard surgical ruler (Fig. 1). Tumors and defects with an oblique orientation were measured in the orientation of the longest axis, with the secondary axis being measured perpendicular to it, and then assigned to the vertical and horizontal group based on the degree of the axis. Findings used to document the tumor edges included transition in surface contour, vascularization, skin color, and surface texture by light reflection.

Prior to WELR, the average MOR used was 4 ± 0.5 mm (range, 2–5 mm), which was marked with the skin under tension. Majority of BCC lesions were taken with surgical margin of 4–5 mm and smaller margins (2–3 mm) were taken in sites where reconstructive options were limited [8,9]. The excision specimen was marked with a suture to provide orientation, then it was submitted for histologic confirmation of the diagnosis and examination for clearness of the surgical margins. The surgical defect was dressed with a non-sticky dressing after application of chloramphenicol ointment. The defect was then reconstructed 4 to 7 days later. In case of positive margin, another 2 mm margin was taking from the same area at the time of reconstruction.

For patients who had MMS, the reconstruction was undertaken the next day, whereas it was done later for WELR patients. One expert dermatologist performed the MMS and one oculoplastic surgeon performed the reconstruction. For both procedures, local anesthesia was obtained with infiltration of a 50 / 50 mixture of bupivacaine 0.5% and lignocaine 0.1% with adrenaline 1 : 100,000, which was injected beneath and around the area of excision and subsequent reconstruction.

The MOR was measured only for the MMS group, as it represents a true tumor free area, hence further analysis for MOR correlation with tumor size was done only for the MMS group. For MMS patients, the horizontal and vertical diameters of the post-Mohs defect were measured using a standard surgical ruler (Fig. 2). The tumor and the post-Mohs defect area were measured using the formula for that

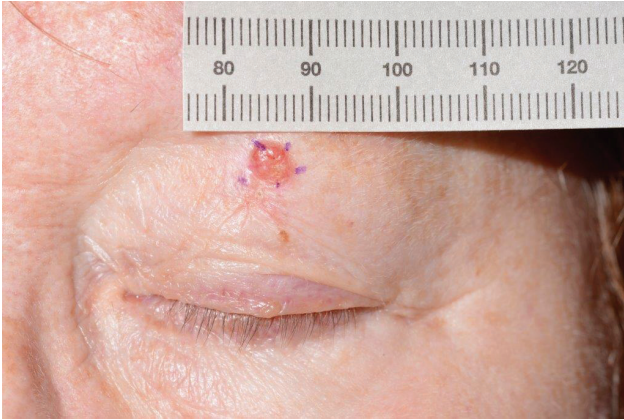

Fig. 1. Measurement of horizontal diameter of preoperative basal cell cancer using surgical ruler. Informed consent for publication of the clinical image was obtained from the patient.

of an ellipse. The post-Mohs defect were measured at the time of excision to respect the normal tone of the surrounding tissue, so that to reduce the overestimation of the defect.

The MOR for each tumor treated by MMS was measured according to the Sines et al. [10] description, as follows: $MOR = (PMDD - POTD) / 2$

In this equation, PMDD means post-Mohs defect diameter and POTD means preoperative tumor diameter [10].

Ocular examinations were performed at baseline and subsequently at 1 week, 1 month, 2 months, 6 months, and then yearly. The postoperative complications and the rate of recurrence were noted for both groups. They were also compared in terms of demographic features and site involvement.

The distribution of data was examined using the Shapiro-Wild test of normality. Categorical data are expressed as an absolute number, and continuous data are expressed as mean \pm standard deviation (95% confidence interval). The chi-square test and Mann-Whitney *U*-test were used to compare variables between both groups. Pearson chi-square test was used to check the correlation between the preoperative tumor size and the MOR required. Multivariable logistic regression analysis was used to check the association of histology type and tumor site with $MOR > 4$ mm. Receiver operating characteristics curve (ROC) was used to predict the cutoff value of the preoperative tumor size associated with $MOR > 4$ mm. Tests used to check the association with $MOR > 4$, were done for MMS groups only. A *p*-value less than 0.05 was considered significant. All statistical analysis was performed using XLSTAT 2014

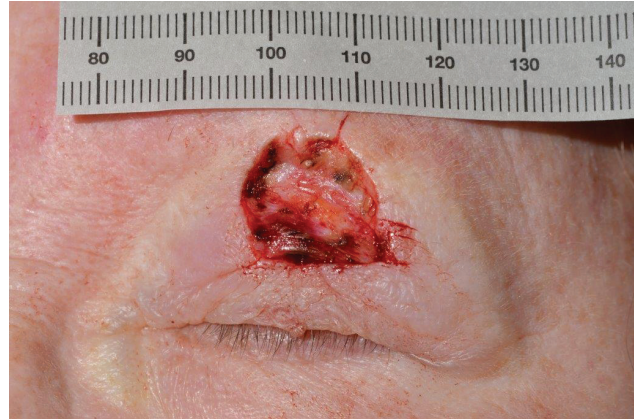


Fig. 2. Measurement of horizontal diameter of postoperative basal cell cancer defect using surgical ruler. Informed consent for publication of the clinical image was obtained from the patient.

Mac software (Addinsoft, New York, NY, USA).

Results

One hundred fifty-one patients with the diagnosis of periocular BCC were reviewed. Nine cases were excluded; six were recurrent tumors, one was diagnosed as a fibrosis lesion, and two had insufficient tumor measurements. This left a total of 142 patients were included in the study. Mean age at the time of surgery was 70.9 ± 12.6 in the MMS group and 78.7 ± 9.4 in the WELR group. There were 89 females and 53 males. Seventy-three patients had the BCC on the right side and 68 on the left side. The mean follow-up time was 18.1 ± 3.16 months. One hundred patients underwent MMS and 42 patients had WELR. Table 1 shows the demographic characteristics of the 142 study participants. Almost half of the BCC tumors were excised from the lower lid in both groups (Table 1), then from the medial canthus (33% and 21.4% for MMS and WELR, respectively).

In the MMS group, the average pre-Mohs tumor horizontal diameter was 7.26 ± 3.9 mm and vertical diameter was 6.92 ± 4.8 mm with a mean tumor area of 230.5 ± 311.4 mm². The average post-Mohs defect horizontal diameter was 16.79 ± 9.5 mm and the vertical diameter was 12.6 ± 7.17 mm with a mean defect area of $825.09 \pm 1,089.18$ mm². On average, the post-MMS defect was 6.3 ± 8 times greater than the tumor area. More specifically, post-MMS defect was 6.06 ± 8.18 times greater than the tumor area for nodular BCCs and

7.38 ± 7.44 times bigger for the morpheaform type.

The average MOR was 4.3 ± 3.5 mm for the horizontal diameter and 3.54 ± 2.5 mm for the vertical diameter. The average MOR for morpheaform tumors was larger than the nodular type at the horizontal diameter (5.3 ± 3.07 vs. 3.9 ± 2.8 mm, *p* = 0.032) and the vertical diameter (3.5 ± 1.8 vs.

2.9 ± 2.4 mm, *p* = 0.06).

When comparing the preoperative tumor diameter to the corresponding MOR the correlation was 0.27 (*p* = 0.01) for the horizontal and 0.28 (*p* = 0.007) for the vertical diameter, which means that for every 1 mm increase in the preoperative tumor size, the MOR was increased by 0.27 and 0.28 units (mm) for horizontal and vertical diameter, respectively.

When we plotted the ROC, there was a good suggestion that preoperative vertical tumor diameter of ≥6 mm is associated with MOR >4 mm, (area under the curve [AUC], 0.72; sensitivity, 0.66; specificity, 0.74) (Fig. 3A, 3B). For horizontal tumor diameter of 5 mm, it was slightly associated with MOR >4 mm (AUC, 0.65; sensitivity, 0.77; specificity, 0.44) (Fig. 3). There was no statistically significant association between the histology type or tumor site with MOR >4 mm in either horizontal or vertical tumor diameter (Table 2).

Among the 42 cases of WELR there was only one case (2.3%) with non-complete tumor excision histologically. This was a case of lower lid nodular type with 5 mm of MOR. A further 2 mm was excised from the positive margin during the reconstruction, which was confirmed to be clear by the pathologist, and there was no recurrence over a follow-up of 7 months.

Over the total follow-up period for the study, there was no case of recurrence in the WELR group, however there was one case of lower lid nodular BCC recurrence (8

Table 1. Patients demographic information

	MMS	Wide excision with later reconstruction
Site		
Lower lid	46 (46)	20 (47.6)
Medial canthus	33 (33)	9 (21.4)
Upper lid	8 (8)	4 (9.5)
Lateral canthus	4 (4)	5 (11.9)
Brow	8 (8)	4 (9.5)
Surgery		
Flap	77 (77)	25 (59.5)
Graft	5 (5)	0
Direct closure	17 (17)	5 (11.9)
Unknown	1 (1)	12 (5)
Histology		
Nodular	80 (80)	35 (83.3)
Morpheaphorm	20 (20)	4 (9.5)
Unknown	0	3 (7.14)

Values are presented as number (%).
MMS = Mohs micrographic surgery.

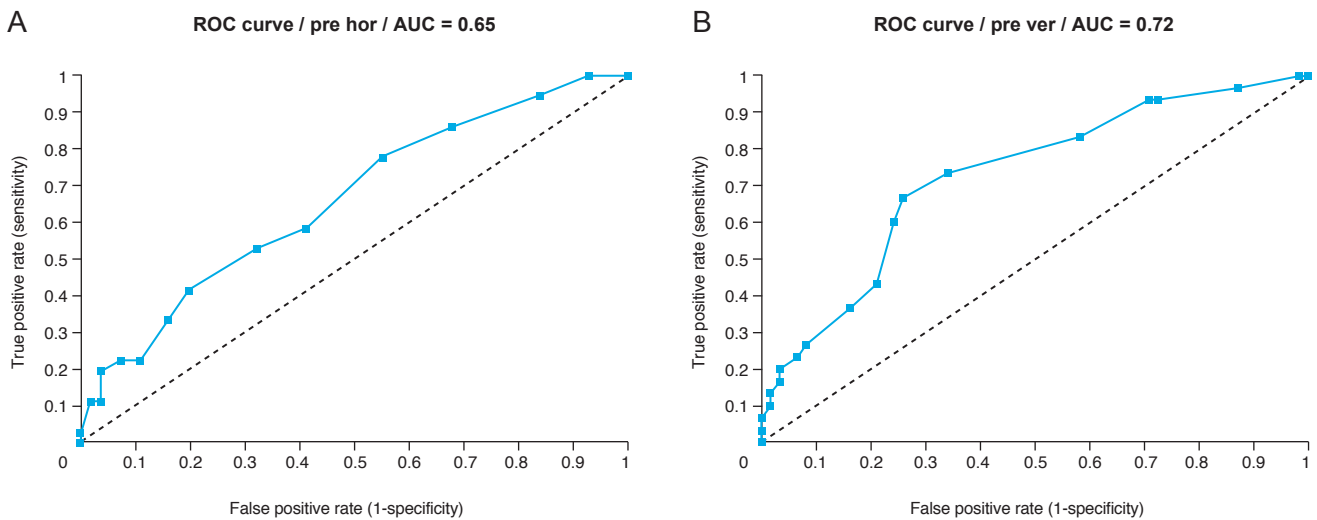


Fig. 3. Receiver operative characteristics curve (ROC) and area under the curve (AUC) for tumor diameter associated with margin of resection (MOR) >4 mm. (A) Horizontal diameter of 5 mm has the highest sensitivity (0.77) and specificity (0.44) for a MOR >4 mm (AUC, 0.65). (B) Vertical diameter of 6 mm has the highest sensitivity (0.66) and specificity (0.74) for a MOR >4 mm (AUC, 0.72). pre hor = preoperative horizontal diameter; pre ver = preoperative vertical diameter.

Table 2. Logistic regression of histology type and tumor site associated with horizontal and vertical margin of resection of >4 mm

	Horizontal margin		Vertical margin	
	Odds ratio	<i>p</i> -value	Odds ratio	<i>p</i> -value
Medial canthus	ND	ND	ND	ND
Lower lid	2.25	0.11	1.05	0.92
Lateral canthus	8.62	0.07	2.87	0.32
Upper lid	2.18	0.51	4.79	0.06
Brow	2.8	0.19	2.87	0.19
Nodular	ND	ND	ND	ND
Morpheaform	1.4	0.49	1.58	0.37

ND = not detected.

months postsurgery) in the MMS group, which was treated with another MMS and the last follow-up 2 years later showed no sign of recurrence.

Regarding other complications, there was one case of ectropion, two infections, and one case of necrosis in the MMS group. All the complications were mild and did not warrant secondary procedure. There were no complications in the WELR group.

Discussion

Our data confirm that histopathological tumor margins for BCCs can extend far beyond the clinical tumor margin. The average post-MMS defect area was 6.3 times greater than the tumor area for all BCC subtypes, 6.06 times for nodular subtypes and 7.38 times greater for the morpheaform type. This is greater than the difference found by Sines et al. [10], where the post-MMS area was 3.2 times greater than the preoperative area for all BCC subtypes and 3.9 times greater for morpheaform subtype, although, we used the same elliptical area measurements like in Sines et al. [10] series.

Our study further confirms previous findings that a standard 3–4 mm MOR may be insufficient to ensure clear margins for BCCs since the average MOR for the horizontal and vertical diameter were 4.3 and 3.5 mm, respectively. Hamada et al. [8] reported that a 4-mm MOR for BCCs resulted in incomplete tumor excision in 17% of cases, whilst Nemet et al. [11] found that a 3-mm MOR for BCCs resulted in incomplete excision in 25.4% of cases. This suggests that we need a new standard MOR for BCCs or a more tai-

lored approach to deciding on a safe MOR.

The required MOR is likely to vary depending on the characteristics of the tumor. For example, this study found that the average MOR required for the morpheaform tumor subtype was larger than the nodular subtype (5.3 vs. 3.9 mm for the horizontal diameter). This is supported by Sines et al. [10], who found that the MOR required for morpheaform tumors was up to 6.3 mm. In addition to tumor subtype, this study shows that the MOR required increases as the tumor size increases, with a correlation of 0.27 and 0.28 between the tumor horizontal and vertical diameters and the corresponding MOR. This is comparable to the correlation of 0.23 and 0.24 found by Sines et al. [10] between the MOR and the horizontal and vertical diameters, respectively. In addition to subtype and size, an additional feature of importance is tumor location, however, this area remains slightly controversial. It has been long recognized that medial canthal location imposes a higher risk because the medial canthus overlies an embryologic cleavage plane, which allows tumors to more easily invade the orbit and surrounding structures [12]. On the other hand, Batra and Kelley [13] reported that the risk of extensive subclinical spread of BCC tumors was highest in the lower eyelid (3× greater vs. 2.1× greater for medial canthus), whilst Sines et al. [10] found that tumors located at the lateral canthus required the largest MOR. Although, our study did not identify significant association between tumor site and the required MOR. Other features to consider include recurrent lesions and poor clinical definition of tumor margins [14].

Based on this study, both MMS and WELR had good outcomes. There was one case of incomplete tumor clearance in WELR group and although this does not represent statistical significance, it is clear that that MMS is superior to WELR in clearing the edge of a tumor [5]. In addition, it is a tissue-sparing technique, which aids in reconstruction and aesthetic outcome. However, MMS is time-consuming and expensive and could be not feasible to be used as the sole treatment option in some centers that have limited access to Mohs surgery. Therefore, MMS cannot replace WELR in treating BCCs yet. Considering the good outcomes overall for WELR and the fact that there were fewer complications compared to MMS in this study, WELR remains a safe treatment option.

The limitation of this study was the relatively small sample size and short follow-up period, and one should look at the recurrence rate cautiously as it could be under-

estimated.

In conclusion, we propose that it would be sensible to stratify patients into higher and lower risk groups based on the factors mentioned that make the subclinical tumor margins less predictable, such as tumor size, subtype, and location. Patients could then be allocated to MMS or WELR treatment based on this risk. Such a strategy would enable both MMS and WELR to be used more appropriately in one department as it would be safer, more cost-effective, and more time-effective compared to using either surgery alone. From the results of our study we can suggest that primary nodular BCC of less than 5 mm diameter, could be stratified to WELR with MOR 4 mm or less, depending on the remaining tissue for reconstruction, and to add 0.30 mm to the MOR for each 1mm increase in the tumor vertical or horizontal diameter, and although this would not guarantee 100% eradication of the tumor, it would cause less complications and help alleviating the pressure in a busy center, without adding significant risk to tumor recurrence.

Measuring the tumor and defect area with elliptical method is a well-recognized way and it was used in previous studies, which makes the comparison more realistic. Applying more advanced measuring tools, such as ImageJ tracing, might prove to be more accurate and would be the target of future studies [15]. From the clinical practice point of view, being able to predict the postoperative defect area, one can have a more detailed discussion regarding the plan of surgical reconstruction. Moving forward, it would be useful to do a prospective study with a larger cohort of patients. Using these MOR data it may be possible to develop an algorithm to predict the MOR based on preoperative tumor size and characteristics. In addition, with more data it should be possible to develop a more robust stratification algorithm or flow chart to aid the surgeon in making a choice between MMS and WELR for individual patients.

Conflict of Interest

No potential conflict of interest relevant to this article was reported.

References

1. Kleinstein RN, Lehman HF. Incidence and prevalence of eye cancer. *Am J Optom Physiol Opt* 1977;54:49-51.
2. Domonkos AN. Treatment of eyelid carcinoma. *Arch Dermatol* 1965;91:364-71.
3. Aurora AI, Blodi FC. Lesions of the eyelids: a clinicopathological study. *Surv Ophthalmol* 1970;115:94-104.
4. Tromovitch TA, Stegeman SJ. Microscopically controlled excision of skin tumors. *Arch Dermatol* 1974;110:231-2.
5. Malhotra R, Huilgol SC, Huynh NT, Selva D. The Australian Mohs database, part I: periocular basal cell carcinoma experience over 7 years. *Ophthalmology* 2004;111:624-30.
6. Wolf DJ, Zitelli JA. Surgical margins for basal cell carcinoma. *Arch Dermatol* 1987;123:340-4.
7. Chalfin J, Putterman AM. Frozen section control in the surgery of basal cell carcinoma of the eyelid. *Am J Ophthalmol* 1979;87:802-9.
8. Hamada S, Kersey T, Thaller VT. Eyelid basal cell carcinoma: non-Mohs excision, repair, and outcome. *Br J Ophthalmol* 2005;89:992-4.
9. Kakudo N, Ogawa Y, Suzuki K, et al. Clinical outcome of surgical treatment for periorbital basal cell carcinoma. *Ann Plast Surg* 2009;63:531-5.
10. Sines DT, Polomsky M, Dutton JJ. Predicting the surgical margin of resection in periocular cutaneous neoplasms and the significance of reconstruction following Mohs micrographic surgery. *Ophthalmic Plast Reconstr Surg* 2016;32:284-91.
11. Nemet AY, Deckel Y, Martin PA, et al. Management of periocular basal and squamous cell carcinoma: a series of 485 cases. *Am J Ophthalmol* 2006;142:293-7.
12. Leibovitch I, McNab A, Sullivan T, et al. Orbital invasion by periocular basal cell carcinoma. *Ophthalmology* 2005;112:717-23.
13. Batra RS, Kelley LC. Predictors of extensive subclinical spread in nonmelanoma skin cancer treated with Mohs micrographic surgery. *Arch Dermatol* 2002;138:1043-51.
14. Telfer NR, Colver GB, Morton CA; British Association of Dermatologists. Guidelines for the management of basal cell carcinoma. *Br J Dermatol* 2008;159:35-48.
15. Scofield-Kaplan SM, Jackson C, Gurney T, et al. Predictive value of preoperative periocular skin cancer measurements for final Mohs defect size. *Ophthalmic Plast Reconstr Surg* 2019;35:604-8.