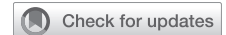

Long-term follow-up of Cabrol fistula for uncontrollable bleeding: A life-saving procedure



Akshay Raghuram, BA, Asanish Kalyanasundaram, MD, Maryann Babcock, RN, Mohammad A. Zafar, MD, Bulat Ziganshin, MD, PhD, and John Elefteriades, MD

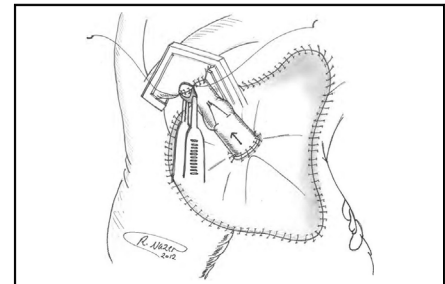
ABSTRACT

Objective: Surgeons shy away from using the Cabrol fistula (perigraft space to right atrium [RA] shunt) due to unfamiliarity, concern for persistent left-to-right shunting, and fear of “painting-over” anastomotic defects that will result in later problems. We review nearly 2 decades of experience with application of the Cabrol fistula in a large thoracic aortic practice, with emphasis on precise surgical techniques, early and late outcomes, and detailed radiographic analysis.

Methods: Operative records of all procedures in which the Cabrol fistula was used were retrieved and analyzed, with precise review of the details of construction of each Cabrol fistula and clinical and radiologic (echocardiographic and computed tomographic) patient follow-up.

Results: The Cabrol fistula successfully controlled the bleeding in all cases. There were no late false aneurysms at any anastomotic sites. There was no continued flow through any fistula. Good perioperative and long-term survival was achieved in these complex cases that found themselves at a very dangerous crux before application of the Cabrol fistula.

Conclusions: The Cabrol fistula is an important tool for the thoracic aortic surgeon to have in the toolbox. We found the Cabrol fistula to be extremely effective at controlling bleeding, with no late persistent fistula flow and no late false aneurysm formation. Without the fistula, outcome in these patients would likely have been lethal. We recommend the Cabrol fistula technique strongly for life-saving application in rare cases of bleeding uncontrollable by conventional methods. (JTCVS Techniques 2023;21:1-6)



Pericardial patch sewn in place with the inflow end of valved graft anastomosed to patch.

CENTRAL MESSAGE

The Cabrol fistula provides a safe and effective way to control intractable bleeding following aortic root, ascending aorta and/or arch operations.

PERSPECTIVE

Surgeons have previously been reluctant to use the Cabrol fistula procedure as a last-resort mechanism to control intractable bleeding following aortic root, ascending aorta, or aortic arch operations. We review 2 decades of favorable experiences using this procedure and find no long-term adverse complications.

Construction of an aorta-to-right atrium (RA) fistula, initially described by Cabrol in his 1981 report of the aortic root replacement procedure itself,¹ has since been supported by other authors as well for control of intractable bleeding at the time of aortic root, ascending aortic, and aortic arch surgery.²⁻¹⁰ In these cases, the Cabrol fistula

was applied for its often-remarkable potential to correct an unsustainable bleeding situation.¹ The technique involves capping the bleeding area with a patch (usually pericardium) and funneling the shed arterial blood from the perigraft space to the venous system (RA or innominate vein). The principle underlying this technique is to capture and return the shed blood automatically, anticipating spontaneous resolution of the bleeding site over time. The Cabrol fistula is applied only when full, careful, exhaustive conventional methods have been applied. Often, it is inaccessibility of the bleeding site (for inspection and suturing) that necessitates the Cabrol technique.

The original procedure, outlined by Cabrol and colleagues, calls for a patch of pericardium or prosthetic material to be sewn over the anterior perigraft space to collect any blood oozing from suture lines.^{1,3} A fistula (traditionally a Dacron graft) is then anastomosed to the patch in

From the Aortic Institute at Yale-New Haven Hospital, Yale University School of Medicine, New Haven, Conn.

Received for publication May 19, 2023; revisions received June 7, 2023; accepted for publication June 13, 2023; available ahead of print July 4, 2023.

Address for reprints: John Elefteriades, MD, Aortic Institute at Yale-New Haven, Yale University School of Medicine, Clinic Building CB 317, 789 Howard Ave, New Haven, CT 06519 (E-mail: john.elefteriades@yale.edu).

2666-2507

Copyright © 2023 The Author(s). Published by Elsevier Inc. on behalf of The American Association for Thoracic Surgery. This is an open access article under the CC BY-NC-ND license (<http://creativecommons.org/licenses/by-nc-nd/4.0/>).

<https://doi.org/10.1016/j.jtc.2023.06.010>

Abbreviations and Acronyms

CT	= computed tomography
ECHO	= echocardiography
RA	= right atrium

order to drain this periprosthetic space into a venous outlet. Thus, there is no longer any external blood loss, as the blood is instantaneously returned to the circulation. In most cases, these 2 steps are sufficient to achieve hemostasis, and the fistula is left to close spontaneously. Late follow-up to confirm fistula closure is poorly documented in the literature. In cases in which the heart is struggling, high right-sided pressures may actually exacerbate bleeding, retrogradely into the perigraft space.

In rare cases in which bleeding does not cease to flow, the fistula can, in principle, result in a significant left-to-right shunt. Late follow-up of use of the Cabrol fistula, examining for such complications, is scant. In order to avoid retrograde (right-to-left) flow, we described a valved-graft modification of the original Cabrol fistula technique to prevent this complication.³ We have applied a variety of valving techniques to assure and maintain unidirectional flow toward the RA. We have used bovine jugular vein grafts, with their contained native valves, and the Contegra Graft (Medtronic Inc, off-label use).³

In this study, we retrieved cases of Cabrol fistula use from our aortic surgery database. We evaluate and categorize the precise methods of construction. We evaluate for any undesired long-term patency of the fistula. We examine for evidence of persistent left-to-right shunting or right heart failure. We determine long-term clinical follow-up. We perform late radiographic follow-up by echocardiography (ECHO) and computed tomography (CT).

METHODS

This investigation was approved by the Human Investigation Committee of the Yale University School of Medicine (institutional review board #1609018416; date of approval: August 25, 2020). Patients' informed consent was waived due to the study being a medical record review.

From among ~1500 ascending, root, and arch open surgical procedures by a single surgeon between 2004 and 2020, we identified 17 surgical patients in whom a Cabrol fistula was used to control recalcitrant, life-threatening bleeding after aortic repair. Before fistula creation, all patients required continuous blood transfusion and could not otherwise be closed or leave the operating room. Exhaustive conventional methods were applied before resorting to a Cabrol fistula (exposure, suturing, packing, glue application, restoration of blood coagulation parameters). We reviewed operative notes and postoperative ECHO/CT scans in detail. We examined specifically for effectiveness in controlling bleeding, persistent left-to-right shunt, anastomotic pseudoaneurysm, and operative, hospital, and long-term survival.

The Cabrol fistulas were constructed with a pericardial patch sewn to the surrounding tissues in a rectangular configuration around the ascending aorta, using any connective tissues available (clockwise from the top: fatty tissues below innominate vein, fibrotic tissue at medial edge of main

pulmonary artery, right ventricular fatty tissue, and superior vena cava adventitia [delicate bites], as well as pericardium, where applicable; [Figure 1](#)). Although this technique is difficult to describe in specific terms, the surgeon uses any safe connective tissue that allows completion of the suturing of the roughly rectangular Cabrol patch to cardiac tissues in its perimeter. The goal is to form a seal that confines all excess bleeding under the patch. A small-caliber graft (Dacron, homograft vein, bovine vein, or Contegra valved graft) is then used to connect the center of the pericardial patch to the RA (or innominate vein). In addition to the conduits that we have used, the patient's own saphenous vein can also be effectively used for this purpose. Please see [Table 1](#) for a step-by-step description of our general construction of the Cabrol fistula.

In occasional cases, especially in patients with acutely high right-sided filling pressures, there occurred an initial large volume backflow from the RA to the perigraft space. This problem led to our modification of using a valved graft (homograft, bovine graft, or Contegra graft), which eliminated the problem of retrograde bleeding into the Cabrol patch zone.³

In a number of cases, we were able simply to create a stab-wound in the surface of the RA under the patch, allowing the flow of bleeding to enter the atrium directly, without an interposed graft. This technical modification was especially applicable in cases in which the RA pressure was low.

RESULTS

Patient Substrate

See [Table 2](#) and [Figure 2](#). The procedures in which the Cabrol fistula was applied included aortic root replacement (n = 8), ascending/arch replacement (n = 8), and apical-aortic conduit (n = 1). In total, 7 of 17 (41.2%) were reoperations. Mean patient age was 68 years. In total, 10 of 17 (59%) of patients underwent surgery under deep hypothermic circulatory arrest, and 3 of 17 (17.6%) of the procedures were done for acute type A dissection. (The patients who required a Cabrol procedure were often reoperation cases [42%]. This is a much greater rate of reoperations than in our general ascending aortic patient pool.)

Surgical Techniques

Bovine pericardium was used for the cap material in all 17 patients. A variety of options were used for the conduit itself: prosthetic Dacron graft in 7 and homograft in 3. In 7 patients, no conduit was required: in 5 of these, a simple direct opening (stab wound) into the RA sufficed, and in the other 2 bleeding stopped just from the tamponade effect of patch application, so no chamber drainage was required. Outflow drainage from the Cabrol fistula was directed to the RA in 8 cases (graft or direct puncture), the innominate vein in 6, and the left subclavian vein in 1. Two patients required no drainage site.

Outcomes

Recalcitrant bleeding was successfully controlled by the Cabrol fistula in all patients. In terms of major complications, 2 patients required re-exploration for clot evacuation, 1 patient (root replacement) was returned to the operating room for a supplementary saphenous vein graft to the right coronary artery, and 1 patient developed sepsis. These patients all survived to discharge. The average total number

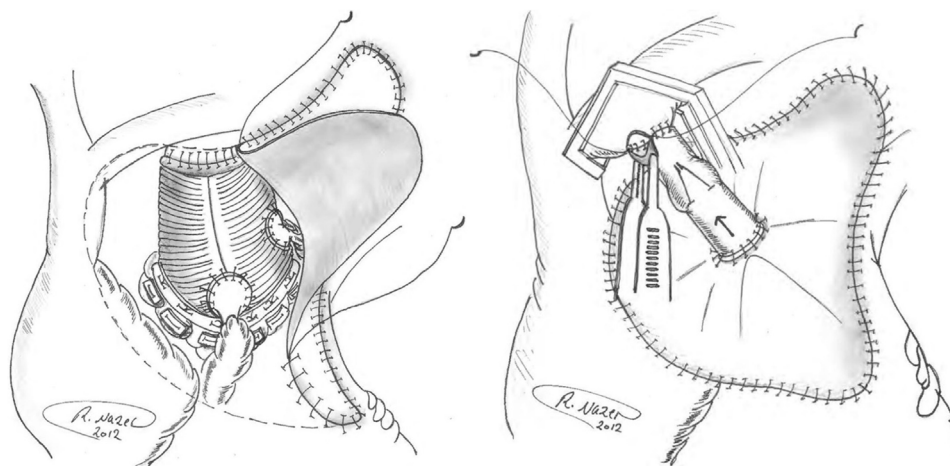


FIGURE 1. *Left*, a pericardial patch being sewn in place over the composite graft repair site. *Right*, the pericardial patch has been sewn in place. The outflow end of the Contegra valved graft has been anastomosed to the innominate vein under site biting-control. Reproduced with permission from Elefteriades and colleagues.³

of units of blood transfused in these Cabrol patients was 3.6 units of packed red blood cells intraoperatively and 1.2 units postoperatively.

Three patients did not survive the hospitalization. Causes of death in the 3 patients who died were multiple organ failure in 2 and intraoperative technical difficulties in 1; all 3

TABLE 1. Step-by-step construction of the Cabrol fistula

Step	Description
Pre-Cabrol	The aortic root, ascending, or arch procedure has been completed; protamine and coagulation factors have been given; and bleeding continues despite all conventional measures.
Pre-Cabrol	Often we wrap the distal anastomosis with a small-caliber graft to seal any bleeding from that area. (This wrap then provides secure “tissue” at the upper margin of a subsequent Cabrol fistula.)
Cabrol	<p>A pericardial patch is sewn to cover the entire site of the aortic replacement. We use running 4-0 PROLENE.</p> <ul style="list-style-type: none"> • This proceeds clockwise, from the left upper corner (patient’s left) of the surgical zone, down the right side, using connective tissue around the medial border of the PA. Note that there is usually a good edge of relatively strong tissue here, where the PA previously abutted the periaortic tissues. • The suture line continues horizontally toward the patient’s right, using the fibro-fatty tissue at or above the RV. • The suturing continues cephalad now, using any connective tissues found along the right atrium. This is the hardest site for finding good tissue. One can use the stump of the RA cannulation site as good tissue in this zone. Fortunately, the distance to be spanned here, on the patient’s right side of the Cabrol patch, is usually short—between the top of the RV and the pericardial reflection of the SVC. As one heads cephalad, the pericardial reflection along the SVC provides good tissue. • Finally, the upper horizontal portion of the anastomosis needs to be completed. One usually finds some suitable fibrofatty tissue underneath the innominate vein that serves well for suturing. <p>This completes the quasi-rectangular patch over the surgical zone. We often put some BioGlue around the edge of the patch, which will harden and seal while the patch is unpressurized.</p>
Temp vent	To decompress the patch at this point, before construction of the shunt, we make a tiny incision in the periphery of the patch and place a small vent catheter under the patch, which we then attach to strong suction from the cell saver. This pulls the patch into tight approximation to the tissues, like a “shrink wrap,” while simultaneously collecting the shed blood for retransfusion.
Shunt prox anast	We now construct the proximal anastomosis of the graft that will carry the blood to the RA. See text for details of conduit choices. We prefer a valved-conduit of some type, for unidirectional flow. We use 4-0 PROLENE.
Shunt distal anast	We now perform the distal anastomosis of the graft, to either the innominate vein (preferred) or the RA proper. (4-0 PROLENE). Note: The innominate vein is preferred, as raising the head of the bed can minimize the back pressure in the vein as needed.
Open shunt	The shunt is now opened and allowed to channel blood from the bleeding site under the patch back into the venous circulation.
Bleed control	Near-immediate control of hemorrhage is usually achieved.
Close Chest	We close the chest, in standard fashion.

(1) In some cases, the shrink wrap during construction of the Cabrol fistula leads to cessation of bleeding on its own, and there is no need at that point to complete the shunt. In such a case, we leave the large patch in place over the previous bleeding zone. (2) The Cabrol fistula is more easily accomplished effectively in reoperative cases, as the scarred tissues provide better substrate for suturing and there are intrinsically fewer degrees of freedom for shed blood to disperse. (3) We do not routinely re-explore patients the day after operation to decompress clot. We do so only if there is a pressure effect (rarely). PA, Pulmonary artery; RV, right ventricle; SVC, superior vena cava; RA, right atrium.

TABLE 2. Surgical details for Cabrol procedures

Patient number	Year	Operation	Cap material	Conduit used	Drainage site
1	2004	Apical aortic conduit	Bovine pericardium	Apical-aortic conduit (22 conduit, 21 CE valve) 10-mm Hemashield graft	Left subclavian vein
2	2006	Redo aortic root	Bovine pericardium	Direct opening under patch	Right atrium
3	2008	Redo aortic arch	Bovine pericardium	Tent only	No outflow required—patch provided adequate hemostasis
4	2008	Redo aortic arch	Bovine pericardium	Tent only	No outflow required—patch provided adequate hemostasis
5	2008	Redo aortic arch	Bovine pericardium	8-mm Dacron graft	Innominate vein
6	2010	Redo ascending replacement	Bovine pericardium	Direct opening under patch	Right atrium
7	2011	Aortic root	Bovine pericardium	Valved Contegra graft	Right atrium
8	2011	Aortic root	Bovine pericardium	Valved Contegra graft	Innominate vein
9	2013	Aortic root	Bovine pericardium	Valved Contegra graft	Innominate vein
10	2013	Redo aortic root	Bovine pericardium	Direct opening under patch	Right atrium
11	2013	Ascending replacement	Bovine pericardium	Cryopreserved homograft vein	Right atrium
12	2013	Aortic root	Bovine pericardium	Direct opening under patch	Right atrium
13	2016	Aortic root	Bovine pericardium	Cryopreserved homograft vein	Right atrium
14	2016	Aortic root	Bovine pericardium	6-mm Gore-Tex graft	Innominate vein
15	2016	Ascending replacement	Bovine pericardium	Direct opening under patch	Right atrium
16	2016	Redo ascending arch	Bovine pericardium	8-mm Hemashield graft	Innominate vein
17	2020	Ascending replacement	Bovine pericardium	Femoral vein homograft	Innominate vein

were very complex cases—2 were reoperative and the third was an acute aortic dissection. The Cabrol fistula itself could not be implicated in any of those cases. Nine of the

other 14 patients remain alive currently (6.76 mean postoperative years). In no case did ECHO identify sustained left-to-right shunting or any patent shunt beyond a few days

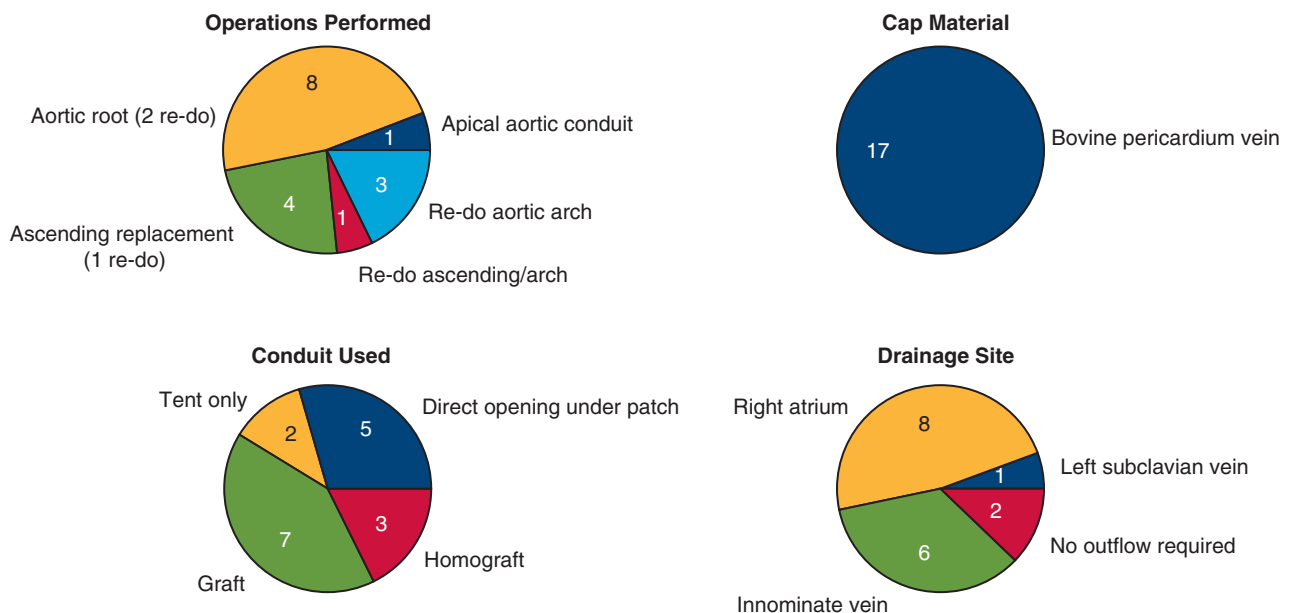
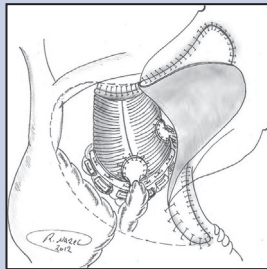


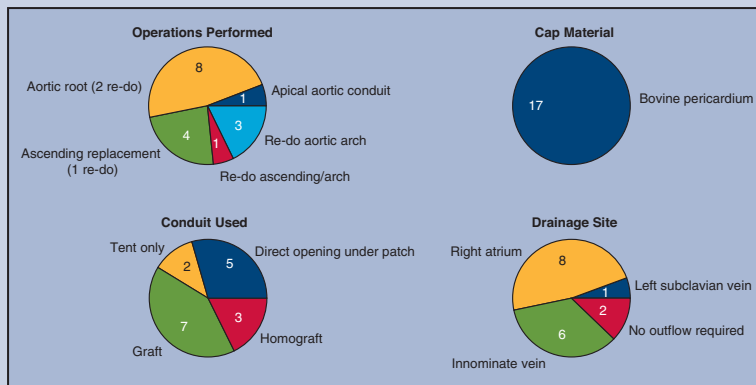
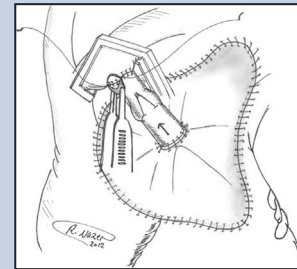
FIGURE 2. Surgical details for Cabrol procedures. *Upper Left*, main operative procedure; *lower left*, conduit used; *upper right*, cap material; *lower right*, drainage site (to which Cabrol fistula shunts blood).

Use of Cabrol Fistula for Uncontrollable Bleeding: A Life-Saving Procedure Without Adverse Consequences



2004 - 2020

- 17 patients (mean patient age of 68 years)
- Pulled from Aortic Institute at Yale's surgical database
- 8 aortic root replacement, 8 ascending/arch replacement, 1 apical-aortic conduit
- Examined effectiveness in bleeding control, persistent R-to-L shunt, anastomotic pseudoaneurysm, and survival



Recalcitrant bleeding was successfully controlled by the Cabrol fistula in all patients. Late post-op CT did not identify continued flow or evidence of anastomotic pseudoaneurysm in any of the 17 cases.

FIGURE 3. The Cabrol fistula for control of intractable intraoperative bleeding is a lifesaving procedure without adverse long-term consequences. CT, Computed tomography.

postoperatively. In no case did later CT scan identify continued flow via the Cabrol shunt or any evidence of anastomotic pseudoaneurysm.

DISCUSSION

The Cabrol fistula procedure is an infrequently used option for intractable bleeding after ascending aorta or aortic arch operations. Historically, leaving the chest packed and open has been a popular option (hoping for slow resolution of bleeding over time); however, this option allows for the grafts to be exposed to the environment, increasing the risk of infection. Some recent series have reported mortalities of 25% to 50% or greater when the chest is left open after open-heart surgery.¹¹⁻¹⁴

In this current report, we review our extremely favorable experience with the Cabrol fistula for control of intractable intraoperative bleeding in ascending surgery. These patients, after often-complex, extensive, or emergent procedures, manifested bleeding that would have proved lethal without some method of control.

In our directed review of 17 patients, we found that we had employed a variety of specific techniques (in a variety of clinical settings) in the construction of the Cabrol fistula. Also, after having been “burned” by opposite direction flow (backwards into the perigraft space from the RA) in patients with high RA pressure, we implemented “valving” of the conduit to obligate flow only in the desired direction.

Although we were pleased with our short-term outcomes with the rare use of the Cabrol fistula out of many thousands of cases, we had never rigorously examined our patients’ long-term experiences. This left us with 2 lingering concerns: (1) are we leaving the patient with a persistent left-to-right shunt? and (2) are we “painting over” an anastomotic defect that may result in a pseudoaneurysm over the long term?

Through our directed long-term analyses, we found that the Cabrol fistula was extremely effective at controlling intraoperative bleeding (100% success rate), there was no evidence of persistent left-to-right shunting from the aorta to RA on either ECHO or CT, and there was no evidence of

the development of a pseudoaneurysm on any of the anastomotic sites in any of these patients.

We have found the Cabrol fistula to be extremely effective, safe, and free of any significant long-term complications (Figure 3). In the high-jeopardy settings, the use of a Cabrol fistula facilitated survival in both the short and long term. No Cabrol fistula-related late complications (persistent fistula, pseudoaneurysm) were identified.

Although persistent fistula, congestive heart failure, and pseudoaneurysms have been noted by others,¹⁵⁻¹⁷ we identified no such cases in our own experience. Other centers as well have found their Cabrol experience to be extremely positive.¹⁸ We strongly recommend this procedure for control of intractable intraoperative bleeding when compared with the conventional method of packing an open chest.

CONCLUSIONS

We conclude that (1) The Cabrol fistula can be truly life-saving. (2) The valved modification of the Cabrol fistula completely eliminates the problem of retrograde filling of the perigraft space. (3) There were no late anastomotic problems that had been “obscured” or “covered over” by the Cabrol patch. (4) There were no sustained fistulae in the long-term. (5) Satisfactory short- and long-term survival were achieved, thanks to the Cabrol fistula, in these otherwise-desperate situations.

The Cabrol fistula, although so effective, should not be seen as a substitute for proper suture control of bleeding. The Cabrol fistula is most applicable for bleeding sites inaccessible to repair suturing. The brilliance of Dr Cabrol is reflected in the true life-saving ability of this technique.

Conflict of Interest Statement

Dr Elefteriades reported Principal of Coolspine. All other authors reported no conflicts of interest.

The *Journal* policy requires editors and reviewers to disclose conflicts of interest and to decline handling or reviewing manuscripts for which they may have a conflict of interest. The editors and reviewers of this article have no conflicts of interest.

References

1. Cabrol C, Pavie A, Gandjbakhch I, Villemot JP, Guiraudon G, Laughlin L, et al. Complete replacement of the ascending aorta with reimplantation of the coronary arteries: new surgical approach. *J Thorac Cardiovasc Surg.* 1981; 81:309-15.
2. Rosero H, Nathan PE, Rodney E, Vasavada B, Sacchi TJ. Aorta to right atrium fistula with congestive heart failure resulting from a patent Cabrol shunt after repair of aortic dissection. *Am Heart J.* 1994;128:608-9. [https://doi.org/10.1016/0002-8703\(94\)90637-8](https://doi.org/10.1016/0002-8703(94)90637-8)
3. Elefteriades JA, Youssef S, Rousou L, Nazer R. Novel valved graft modification of Cabrol fistula for bleeding after aortic root surgery. *Ann Thorac Surg.* 2012;94:1741-3.
4. Elefteriades JA. Mechanism to valve a Cabrol fistula for bleeding control. *Aorta (Stanford).* 2013;1:65-6.
5. Hoover EL, Hsu HK, Ergin A, Ketosugbo A, Webb H, Kharma B, et al. Left-to-right shunt in control of bleeding following surgery for aneurysms of the ascending aorta. *Chest.* 1987;91:844-9.
6. Estrera AL, Miller CC, Kaneko T, Lee TY, Walkes JC, Kaiser LR, et al. Outcomes of acute type A aortic dissection after previous cardiac surgery. *Ann Thorac Surg.* 2010;89:1467-74.
7. Vogt PR, Akinturk H, Bettex DA, Schmidlin D, Lachat ML, Turina MI. Modification of surgical aortoatrial shunts for inaccessible bleeding in aortic surgery: modification of the Cabrol-shunt technique. *Thorac Cardiovasc Surg.* 2001;49:240-2.
8. Nielson DH, Sutter FP, Goldman SM. Use of venous fistula technique for intraoperative cardiac hemorrhage. *J Card Surg.* 1993;8:558-61.
9. Maisano F, Lorusso R, Alfieri O. The periprosthetic sac innominate vein shunt: an effective way to control bleeding after aortic root operations. *J Thorac Cardiovasc Surg.* 1995;109:396-7.
10. Mehta ID, Elefteriades JA. Funnel graft to innominate vein to control epicardial bleeding. *Ann Thorac Surg.* 1998;66:1413-4.
11. Salerno TA, Carvalho EMF, Panos AL, Ricci M. Modified Cabrol shunt after complex aortic surgery. *Ann Thorac Surg.* 2008;86:669-70.
12. Bakaeen FG, Haddad O, Ibrahim M, Pasadyn SR, Germano E, Mok S, et al. Advances in managing the noninfected open chest after cardiac surgery: negative-pressure wound therapy. *J Thorac Cardiovasc Surg.* 2019;157:1891-903.e9. <https://doi.org/10.1016/j.jtcvs.2018.10.152>
13. Kurazumi H, Suzuki R, Nawata R, Yokoyama T, Tsubone S, Matsuno Y, et al. Feasibility of open chest management with modified negative pressure wound therapy immediately after cardiac surgery. *Interact Cardiovasc Thorac Surg.* 2022;35:ivac041. <https://doi.org/10.1093/icvts/ivac041>
14. Boeken U, Assmann A, Mehdiani A, Akhyari P, Lichtenberg A. Open chest management after cardiac operations: outcome and timing of delayed sternal closure. *Eur J Cardiothorac Surg.* 2011;40:1146-50. <https://doi.org/10.1016/j.ejcts.2011.02.047>
15. Savic V, Schmiady MO, Khargi K, Maisano F, Mestres CA. How does a Cabrol fistula look at reoperation? *Ann Thorac Surg.* 2019;108:e277. <https://doi.org/10.1016/j.athoracsur.2019.04.020>
16. Goossens D, Brutel de la Rivière A, Ernst S, Vermeulen F. Reoperative aortic root surgery late after use of histo-acryl. *Eur J Cardiothorac Surg.* 1997;11:194-5. [https://doi.org/10.1016/s1010-7940\(96\)01086-x](https://doi.org/10.1016/s1010-7940(96)01086-x)
17. Zhang B, Liu Y, Dun Y, Sun X. Early obliterated Cabrol shunt: culprit of aortopulmonary fistula in large pseudoaneurysm after Bentall procedure. *J Cardiovasc Dev Dis.* 2022;9:449. <https://doi.org/10.3390/jcdd9120449>
18. Zhang H, Wu X, Fang G, Qiu Z, Chen LW. Is it justified to apply a modified Cabrol fistula in surgical repair of acute type A aortic dissection? *J Thorac Cardiovasc Surg.* 2019;158:1307-14.e2. <https://doi.org/10.1016/j.jtcvs.2018.12.082>

Key Words: intractable bleeding, Cabrol fistula, aortic root surgery, ascending aortic surgery, aortic arch surgery, hemorrhage