

# Concept and Classification of a Derived Injury Resulting from a Primary Injury in Orthopedic Trauma

Wei Chen, Ying-Ze Zhang

Department of Orthopedic Surgery, The Third Hospital of Hebei Medical University, Shijiazhuang, Hebei 050051, China

**Key words:** Derived Injury; Fracture; Orthopedics; Primary Injury; Traumatology

A derived disaster is a common concept in natural emergencies, such as earthquakes. In recent years, the incidence of fractures caused by high-energy trauma has increased annually with socioeconomic development in China.<sup>[1-3]</sup> Accordingly, derived injuries resulting from primary injuries have also been increasing considerably. However, most surgeons in the field of orthopedics and traumatology do not yet have adequate knowledge of such kind of derived injuries. We summarized our experience in managing a patient who experienced reinjury caused by a primary injury over the last decade and proposed the concept of a derived injury. In addition, we aimed to introduce a classification of derived injuries, explore their significance in orthopedic trauma, and discuss methods to minimize their severity.

A derived injury is an injury directly caused by a primary injury that has already occurred to the body. Once a trauma occurs, a derived injury may be unavoidable. Based on their manifestation and characteristics, derived injuries can be categorized into three types: occult, apparent, or interventional derived injury.

In patients with a fracture, occult derived injuries are those such as friction, stabbing, or puncturing injuries of the surrounding tissues, including nerves, blood vessels, ligaments, muscles, tendons, and organs, by fracture fragments following the primary injury. Occult derived injuries often occur during postural changes, such as handling or turning patients, or manual reduction of a fracture. For example, pseudoaneurysm can be induced by a penetrating injury of the surrounding artery caused by fracture fragments during the transfer of a patient or manual reduction. Most occult derived injuries do not cause obvious clinical signs and symptoms, or they are overlooked because of the main signs and symptoms caused by the primary

injuries. Therefore, not all orthopedic surgeons are aware of the existence of occult derived injury; thus, they pay little attention to such an injury. Awareness of the potential occurrence of occult derived injury, careful observation, and essential examinations may help identify this kind of injury and provide proper management.

Apparent derived injuries are those of the organs, neurovascular bundles, or other tissues caused by the primary injury, and they have obvious clinical signs and symptoms. They can be further divided into acute and delayed derived injuries. The former refers to a derived injury occurring shortly after a primary injury. For instance, a 38-year-old male patient sustained a Type C pelvic fracture according to the AO Foundation and Orthopaedic Trauma Association classification [Figure 1a–1c], and associated injuries of the bladder and urethra. Operation was performed to repair the disrupted urethra and bladder at a local hospital. Subsequently, the patient was admitted to our hospital for treatment of the pelvic fracture. He was transferred to the operating room, and then, he was manually moved from the bed to the operative table. General anesthesia was performed. After sterilization and draping, his blood pressure decreased suddenly and rapidly, with the lowest pressure of 45–50/30–34 mmHg (1 mmHg = 0.133 kPa). Emergency resuscitation was performed until the patient's blood pressure became stable, and then, he was transferred to the intensive care unit. His blood pressure was maintained with the continuous use of epinephrine, a large amount of

**Address for correspondence:** Dr. Ying-Ze Zhang,  
Department of Orthopedic Surgery, The Third Hospital of Hebei Medical  
University, Shijiazhuang, Hebei 050051, China  
E-Mail: dryzzhang@126.com

This is an open access article distributed under the terms of the Creative Commons Attribution-NonCommercial-ShareAlike 3.0 License, which allows others to remix, tweak, and build upon the work non-commercially, as long as the author is credited and the new creations are licensed under the identical terms.

**For reprints contact:** reprints@medknow.com

© 2017 Chinese Medical Journal | Produced by Wolters Kluwer - Medknow

**Received:** 18-07-2017 **Edited by:** Yi Cui

**How to cite this article:** Chen W, Zhang YZ. Concept and Classification of a Derived Injury Resulting from a Primary Injury in Orthopedic Trauma. *Chin Med J* 2017;130:2632-4.

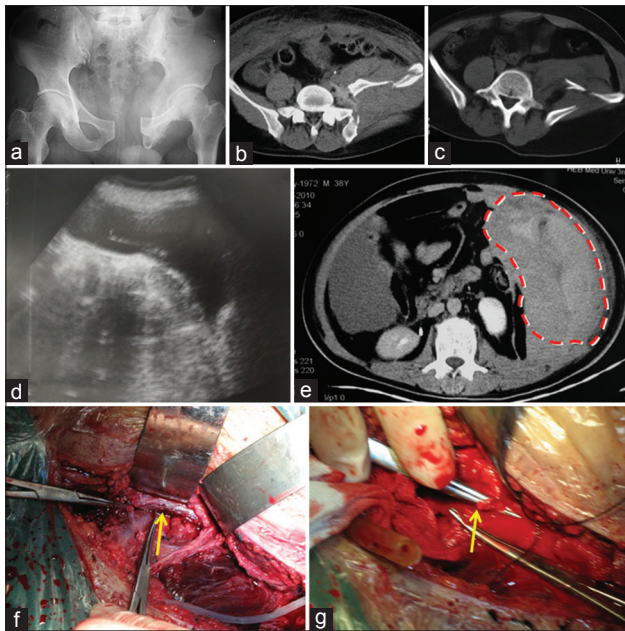
## Access this article online

### Quick Response Code:



**Website:**  
www.cmj.org

**DOI:**  
10.4103/0366-6999.217078



**Figure 1:** A 38-year-old man sustained a pelvic fracture. The anteroposterior radiograph shows separation of the symphysis pubis and disruption of left sacroiliac joint (a), and the axial view of the computed tomography scan demonstrates fracture dislocation of left sacroiliac joint (b), and sharp fracture fragment of the ilium (c). The ultrasonogram shows an obvious retroperitoneal hematoma (d), and axial computed tomography image illustrates a massive hematoma (e). An anonymous vein in the left abdominal is partially ruptured (f), and an anonymous artery above the sharp fracture fragment is disrupted (g).

fluid replacement, and a blood transfusion. The angiogram showed negative findings in the thoracic aorta, pulmonary vessels, abdominal aorta, superior mesenteric artery, inferior mesenteric artery, internal iliac artery, external iliac artery, renal artery, and testicular artery, as well as their main branches. The ultrasonogram showed an obvious retroperitoneal hematoma, and the computed tomography scan demonstrated a massive hematoma in the left abdominal wall [Figure 1d and 1e]. Abdominal laparotomy was suggested by the consulting surgeons. During the operation, 1800 g of blood clots and 4000 ml of blood were removed from the abdominal wall. The wall of an anonymous vein, the branch of the external iliac vein, was partially disrupted and ligated, and an anonymous artery just above the sharp fracture fragment of the ilium, the branch of the external iliac artery, was also disrupted and then ligated [Figure 1f and 1g]. The retroperitoneal hematoma and massive intraabdominal blood clot were detected and removed. Postoperatively, closed drainage was used for 3 days with no more than 10 ml of blood collected by the 3<sup>rd</sup> day. The drainage tube was removed, and the patient recovered from the derived injury. This patient's arterial injury was caused by puncture from the sharp fracture fragment of the ilium, which was a typical apparent derived injury. If a sliding sheet was used to transfer this patient from the bed to the operating table, this derived arterial injury might have been avoided.

In patients with a delayed derived injury, the clinical manifestations occur several weeks or months after the

primary fracture. For example, in a patient with a displaced proximal femoral fracture, the tunica adventitia of the femoral artery is not initially injured. However, a pseudoaneurysm of the femoral artery may occur if the fracture fragment penetrates the adventitia during the process of transferring the patient, and it may become symptomatic several weeks or months later.

Interventional derived injuries are caused by interventions performed by surgeons to save a patient's life or to treat a specific injury. Interventional derived injuries may have a minor or major effect on patients' physiological, immune, and mental statuses, which may impair their recovery from primary injuries. However, some surgeons have not attributed derived injuries to the invasive interventions they perform, and accordingly, few effective preventive measures are taken. In some cases, severe derived injuries may even occur following an intervention. For example, some surgeons, especially at a county-level hospital, treat a diaphyseal fracture of the femur by open reduction and internal fixation using a long plate by the long lateral approach. In such patients, the surgical intervention can cause derived injuries that are more severe than necessary, which results in massive injury to the surrounding soft tissues, and increases the risk of fracture nonunion and implant loosening or breakage. In this case, closed reduction and internal fixation using an intramedullary nail is a better alternative to treat a femoral shaft fracture to minimize the occurrence of an interventional derived injury. In brief, care should be taken during the treatment of initial fractures, such as manual fracture reduction, fixation using the plaster cast, or skeletal traction, to minimize derived injuries. For surgical intervention, a detailed intraoperative plan should be made to facilitate the operation, avoid additional injuries, and shorten the operative time.

Derived injuries after primary injury are different from associated injuries or multiple fractures. For example, hemopneumothorax, which does not initially occur after a rib fracture but is due to fracture fragments of the rib puncturing the lung and pulmonary vessels, is a derived injury. However, in a patient with associated injuries, the rib fractures and pneumothorax occur simultaneously after the same trauma. Multiple fractures are two or more fractures caused by one single cause, such as fractures of the humerus and femur due to a traffic crash. Subsequent injuries refer to two or more injuries that occur within a short period. For instance, a patient may sustain a pelvic fracture due to a fall from height, and be struck and injured shortly by a falling object. The latter is known as the subsequent injury. Secondary injury is a term used to describe the destructive and self-propagating biological changes in cells and tissues that lead to their dysfunction or death over hours to weeks after the primary injury.<sup>[4,5]</sup> To biomedical researchers, an example at the systemic and tissue level would be the development of hemorrhage, edema, or ischemia following multiple fractures. Derived injuries are also different from iatrogenic injuries. A tissue or organ injury caused directly by medical procedures is an iatrogenic injury. An example of this would be an injury

to the subclavian vein caused by screws inserted too deep during internal fixation of a clavicle fracture.

Since a derived injury resulting from a primary injury is often inevitable, prevention is particularly important. Although preventive measures may cause additional irritation or injury to the surrounding tissues and organs, there are more benefits than harm. The primary injury should be appropriately managed, for example, urgent hemostasis for a large blood vessel injury, cold compress for soft tissue contusion, traction reduction for overlapping fracture displacement, and fracture fixation with the use of an appropriate brace, plaster, splint, or external fixator, to lessen the severity of derived injuries. Efforts should also be made to reduce any irritation to the surrounding tissues and organs to maximize the benefits of the interventions. To minimize the interventional derived injury during the management of fractures, it is important for surgeons to be familiar with the anatomy and the trajectory of surrounding structures as well as mechanical axes of the limbs when performing operations. Any minor protective measure is important, and any additional injury should be avoided, if possible. Surgeons and their assistants should cooperate closely to perform the operation smoothly and to minimize any derived injury and shorten the operative time.

In summary, we propose the concept of a derived injury resulting from a primary injury, in an attempt to make clinicians pay more attention to this kind of injury. Derived injuries can be caused by various diagnostic and management

measures, and are therefore often inevitable. However, efforts should be made to lessen their severity.

### Declaration of patient consent

This study was approved by the Institutional Review Board of the Third Hospital of Hebei Medical University, and written informed consent was obtained from each participant before data collection.

### Financial support and sponsorship

This study was supported by grants from the National Natural Science Foundation of China (No. 81401789), and the Hebei National Science Foundation-Outstanding Youth Foundation (No. H 2017206104).

### Conflicts of interest

There are no conflicts of interest.

## REFERENCES

1. Zhang Y. *Clinical Epidemiology of Orthopedic Trauma*. 2<sup>nd</sup> ed. Stuttgart: Thieme; 2016.
2. Chen W, Lv H, Liu S, Liu B, Zhu Y, Chen X, *et al*. National incidence of traumatic fractures in China: A retrospective survey of 512 187 individuals. *Lancet Glob Health* 2017;5:e807-17. doi: 10.1016/S2214-109X(17)30222-X.
3. Zhang YZ. Minimally invasive reduction and fixation in orthopedic trauma. *Chin Med J* 2016;129:2521-3. doi: 10.4103/0366-6999.192773.
4. Borgens RB, Liu-Snyder P. Understanding secondary injury. *Q Rev Biol* 2012;87:89-127. doi: 10.1086/665457.
5. Merrick MA. Secondary injury after musculoskeletal trauma: A review and update. *J Athl Train* 2002;37:209-17.